

RESEARCH ARTICLE

Ponseti Casting Method in Idiopathic Congenital Clubfoot and Its Correlation with Radiographic Features

Taghi Baghdadi, MD; Nima Bagheri, MD; Arvin Najafi, MD; Pejman Mansouri, MD; Mahmoud Farzan, MD

Research performed at Tehran University of Medical Sciences, Joint Reconstruction Research Center, Imam Khomeini Hospital Complex Orthopedic Ward, Tehran, Iran

Received: 27 December 2016

Accepted: 03 April 2017

Abstract**Background:** The aim of this study was to evaluate the idiopathic congenital clubfoot deformity treated by Ponseti method to determine the different factors such as radiological investigations that may have relations with the risk of failure and recurrence in mid-term follow-up of the patients.**Methods:** Since 2006 to 2011, 226 feet from 149 patients with idiopathic congenital clubfoot were treated with weekly castings by Ponseti method. Anteroposterior and lateral foot radiographies were performed at the final follow-up visit and the data from clinical and radiological outcomes were analysed.**Results:** In our patients, 191(84.9%) feet required percutaneous tenotomy. The successful correction rate was 92% indication no need for further surgical correction. No significant correlation was found between the remained deformity rate and the severity of the deformity and compliance of using the brace ($P=0.108$ and 0.207 respectively). The remained deformity rate had an inverse association with the beginning age of treatment ($P=0.049$). No significant correlation was found between the percutaneous tenotomy and passive dorsiflexion range ($P=0.356$).**Conclusion:** According to our results treatment with the Ponseti method resulted in poor or no correlation. The diagnosis of clubfoot is a clinical judgment; therefore, the outcome of the treatment must only be clinically evaluated. Although the Ponseti method can retrieve the normal shape of the foot, it fails to treat the bone deformities and eventually leads to remained radiologic deformity. Further studies are suggested to define a different modification that can address the abnormal angles between the foot and ankle bones to minimize the risk of recurrence.**Keywords:** Club foot, Ponseti method, Radiologic evaluation**Introduction**

Idiopathic talipes equinovarus or clubfoot is one of the most common congenital orthopedic deformities that occurs approximately in one in every 1000 live births (1). Untreated club foot is a major disability due to congenital bone and joint deformities and may affect both patients' quality of life and the economic burden of health care systems (2). The treatment goals include normal gait functions, painless plantigrade foot, and wearing regular shoes. The traditional treatment modality has been a surgical release procedure that has some long-term disadvantages including deformity

recurrence, joint stiffness, and knee and/or thigh deformity or pain (3, 4). Nowadays, nonsurgical Ponseti casting method is considered as the choice treatment for clubfoot deformity among most orthopedic surgeons (5-7). Evaluation of short term outcomes of Ponseti method have reported failure due to errors in casting method, severity of the deformity, brace noncompliance, lack of parent's education, and cultural factors (8-10). According to Ponseti, plain radiographs cannot be used to evaluate the prognosis and severity of clubfoot; thus, imaging methods such as ultrasound, magnetic

Corresponding Author: Nima Bagheri, Orthopedic Surgery Ward, Imam Khomeini Hospital, Tehran, Iran
Email: nimab1360@gmail.com

THE ONLINE VERSION OF THIS ARTICLE
ABJS.MUMS.AC.IR

resonance imaging (MRI) and computed tomography (CT) have been suggested for more comprehensive assessment of the congenital clubfoot (11, 12). Although the use of plain radiography in clubfoot is not new, to the best of our knowledge, there is no study that on foot and ankle radiologic angles of the feet treated by the Ponseti method. Considering the disadvantages of other investigation methods and lack of studies one valuation of long term outcomes of Ponseti method particularly in plain radiographies, we decided to conduct this study. The aim of the current study was to evaluate the idiopathic congenital club foot deformity treated by Ponseti method, in order to determine different outcomes such as radiological investigations that may relate to the risk of failure and recurrence in long term follow-up.

Materials and Methods

All patients with idiopathic congenital clubfoot referring to the Imam Khomeini hospital from January 2006 to March 2011 were included in this prospective case series study. From a total of 149 patients, 77 cases (51.7%) had bilateral club foot, thus a total of 226 feet were treated with the Ponseti method by a single orthopedic surgeon. Children with non-idiopathic clubfoot or any concurrent congenital syndrome were excluded from the study. The Dimeglio score was used for severity classification (13). The treatment protocol included weekly casting followed by tenotomy and consequent three weeks casting if indicated. At the end of this period the patients were prescribed to use Denis Browne splint or reverse last shoes depending on children's walking ability (Dennis Browne splint in non-walking children

and reverse last shoes in walking child). The details of the study were explained to the parents, and informed consent was obtained. The study was approved by the ethical committee of Tehran University of Medical Sciences. All castings were conducted under a light oral sedation. At the end of casting, if the ankle dorsiflexion was less than 10° , tenotomy was performed under light sedation as an outpatient procedure and another casting was applied for 3 weeks. In this study, treatment failure was defined as failure to respond to Ponseti method and need for surgical intervention. At the final follow-up visit, standing anteroposterior and lateral view radiographies with dorsiflexed ankles were performed in 115 patients (173 feet) (The rest of patients refused to perform the radiographies). The talocalcaneal (TC), calcaneus-second metatarsal (CSM), and talus-first metatarsal (TFM) angles were measured in AP view [Figure 1], while the lateral view was used for tibio-calcaneal (TIC), talus-first metatarsal (TFM), calcaneus-first metatarsal (CFM) 4), and talocalcaneal (TC) angles measurements [Figure 2]. The measured angles were categorized according to the normal angles values as described by Vanderwilde R, et al (14).

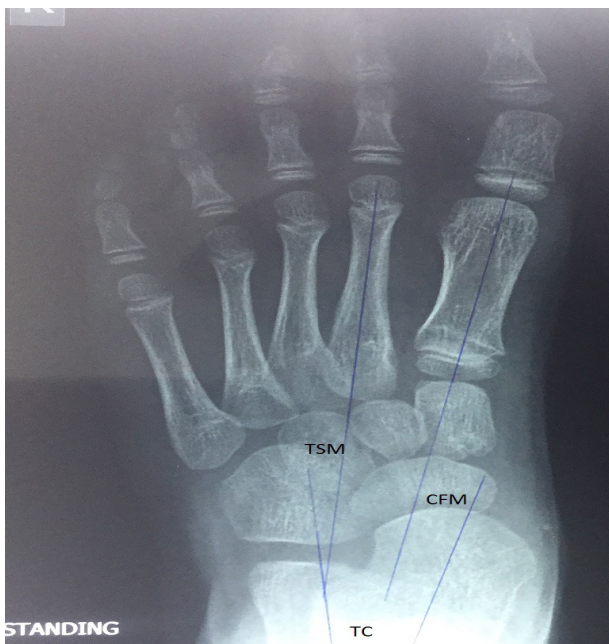


Figure 1. The measured angles in foot and ankle AP view.

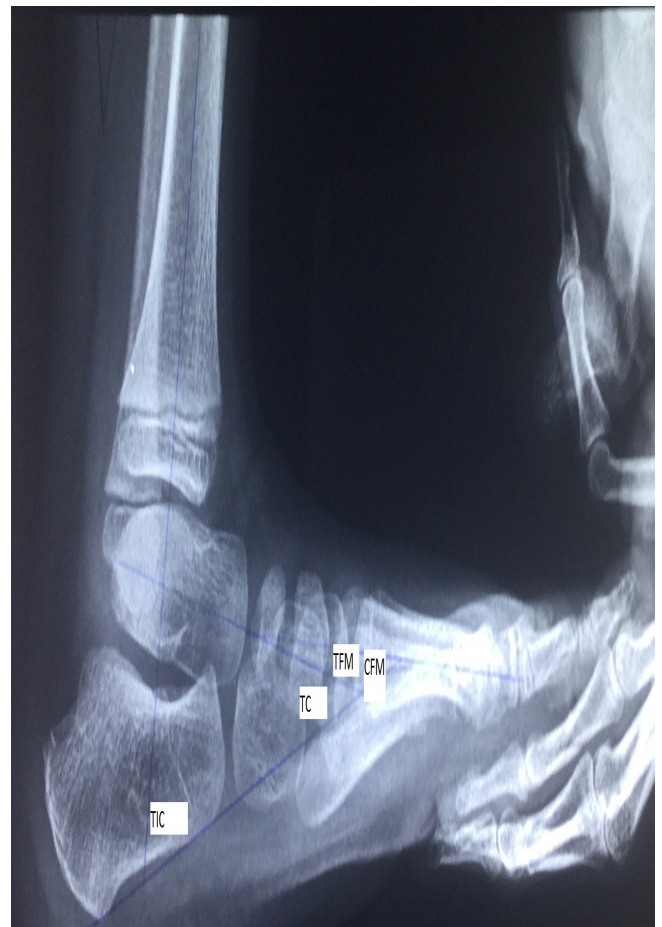

Figure 2. The measured angles in foot and ankle lateral view.

Table 1. Baseline characteristics of our patients

Characteristics	Value
Patients (n)	149
Male/female (n)	104/45
Age at beginning of casting (Weeks)	8.3±5.4 (1 to 41 Weeks)
Site of casting/ Laterality	
Right	42 (28%)
Left	30(20%)
Bilateral	77(52%)

Results

A total of 149 patients (226 feet; 70% male, 30% female; aged 8.3± 5.4 weeks) were treated by the Ponseti method; among whom 72 cases (48.3%) had unilateral (58.3% right foot) and 77 cases (51.7%) had bilateral clubfoot. The baseline characteristics of the patients are presented in table 1. According to the Dimeglio score, 55% of the children had grade IV (the most severe), 9% grade III, 6% grade II, 7% grade I, and 23% unidentified severity [Table 2]. Consequently 226 feet were treated with this method and 191 (84.9) feet required percutaneous tenotomy. The mean follow up duration was 43.4 months. The successful correction rate was 92%. The follow up findings are summarized in table 3. The mean number of casting times was 6.5±3.3, while 9 patients (6%) experienced casting related complications. The mean age of patients at the time of radiography was 46.7±20.9 months. The post treatment

Table 3. Follow up findings of the patients

Characteristics	Value
Number of casts (n)	6.5±3.3
Follow-up time (months)	43.4±7.2
Tenotomy(%)	191/226 (84.9%)
Treatment Success	
Yes (%)	208 (92%)
No (%)	18 (8%)
Recurrence (in 208 successful feet)	
Yes (%)	5 (2.5%)
No (%)	203 (97.5%)
Brace compliance (%)	126/149 (84.5%)
Residual deformity (in successful correction group)	
Varus (%)	63 (31.03%)
Adduction (%)	10 (4.9%)
Equinus(%)	10 (4.9%)
Cavus (%)	1 (0.5%)
No Deformity (%)	119 (58.62%)

Table 2. Club foot severity of our patients according to Dimeglio score

Primary severity	Numbers (%)
Mild	16 (7.1%)
Moderate	14 (6.2%)
Severe	20 (8.8%)
Very Severe	124 (54.9%)
Undetermined	52 (23%)

radiographic findings are shown in table 4. Among 98

Table 4. Shows patients' radiographic features after completing the treatment (Ranges according to Vanderwilde, et al (13))

Angle	prevalence (%)
Talocalcaneal angel in AP view	
<30°	93 (64.6)
30° -56°	51 (35.4)
>56°	0 (0)
Mean ± SD	25.99,4±
Talo-fist metatarsal angel in AP view	
<-9°	26 (18)
-9° -31°	115 (80)
>31°	3 (2)
Mean ± SD	16.4 ± 2.5
Talo-fistmetatarsal angel in AP view	
<5°	74 (51.4)
5° -15°	48 (33.3)
>15°	22 (15.3)
Mean ± SD	2.5 ± 16.4
Calcaneo-second metatarsal angel in AP view	
<12°	16 (11.1)
12° -18°	24 (16.7)
>18°	104 (72.2)
Mean ± SD	25.6 ± 12
Talocalcaneal angel in lateral view	
<25°	41 (28.5)
25° -55°	102 (70.8)
>55°	1 (0.7)
Mean ± SD	28.9 ± 9.5
Tibiocalcaneal angel in lateral view	
<25°	0 (0)
25° -73°	71 (49.3)
>73°	73 (50.7)
Mean ± SD	73 ± 15.8
Talo-first metatarsal angel in lateral view	
<-7°	20 (13.8)
-7° -39°	121 (84.1)
>39°	3 (2.1)
Mean ± SD	15.4 ± 7.7

Table 5. Comparison of clinical varus, adductus and equines and radiographic varus, adductus and equines

Variable	Number of patients With clinical varus (%)	Patients without clinical varus (%)
Talocalcaneal angel in AP view		
<30°	34 (36.6)	59 (63.4)
30 to 56°	12 (23.5)	39 (76.5)
>56°	0 (0)	0 (0)
	Number of patients with clinical adductus (%)	Patients without clinical adductus
Calcaneo-second metatarsal in AP view		
<12°	0 (0)	16 (100)
12 to 18°	0 (0)	24 (100)
>18°	7 (6.9)	97 (93.1)
	Number of patients with clinical equinus (%)	Patients without clinical equinus (%)
Tibiocalcaneal angle in lateral view		
<25°	0 (0)	0 (0)
25 to 73°	1 (1.1)	70 (98.59)
>73°	8 (9.5)	65 (90.5)

patients without clinical varus, radiologic varus (TCA<30°) was present in 59 patients (60%) [Table 5].

All seven patients with clinical adductus had calcaneo-second metatarsal angles above 18°, while 95 clinically adductus-free feet had radiologic adductus [Table 5].

The tibiocalcaneal angle in AP view was more than 73° in 8 out of 9 patients with clinical equinus, while the last patient had a TIC angle between 25°-73° in (88% of patients with clinical equinus had radiologic equinus, too. On the other hand radiologic equinus was present in 76 feet among 162 feet without clinical equinus [Table 5].

We found that passive dorsiflexion has a significant opposite association with the lateral tibiocalcaneal angle ($r=-0.466$, $P=0.000$). No significant correlation was found between the remained deformity rate and the severity of the deformity as well as the compliance of using brace and casting complication ($P=0.108$ and 0.207 , respectively). The beginning age of treatment and the remained deformity rate showed inverse association ($P=0.049$); also, there was no significant correlation between the percutaneous tetotomy and the passive dorsiflexion range ($P=0.356$).

Discussion

Club foot is a complex foot deformity that needs particular efforts of the orthopedic staff and the child's parents for correction. The Ponseti casting method (1, 2, 6, 7) for clubfoot correction needs serial casts along with long-term brace compliance for preserving the correction. Our study did not show any difference in results according to brace compliance; however, due to low number of noncompliant patients and less severe deformity in this group, this result cannot be generalized. The patient selection and management protocol guidelines vary between orthopedic surgeons (4, 7-12, 15) but generally the treatment must be started immediately and followed cautiously. Our mean follow-up period was 43.4 ± 7.2 months with a correction rate of 92% and in line with previous

reports with correction rates of 95 and 100% (16, 17). A casting method was introduced for the first time in 1950 for conservative management of clubfoot in order to achieve a plantigrade functional foot (18). The long-term positive outcomes of this method with a meticulously applied technique have been shown in different studies (9-12, 15-19).

Morcuende et al. had good outcomes in 98% of patients, with an 11% recurrence rate, mainly because of noncompliance with the Denis-Browne orthoses (20). Lehman et al. have reported satisfactory early outcomes in children younger than 7 months who were also prescribed the Denis-Browne orthoses (21). Ippolito et al. have reported encouraging long-term outcomes with the Ponseti method compared to other techniques (5). Some authors have stated substantial percutaneous Achilles tendon tenotomy rates (96%) among their cases (16, 17). In contrast, lower tenotomy rates (75% and 79%) have been reported in primary outcomes of the Ponseti casting method (22, 23). Ponseti casting method is a technique not only for deformity correction but also for preventing or treating relapses. Consistent with earlier reports, the relapse rate in our study was 2.5%. The Ponseti casting technique is not only safe but also efficient as a conservative management of clubfoot and reduces the number of surgical procedures required for the correction of the foot deformity.

The male/female ratio in our study was 7:3, while it has been reported as 4:1 and 3:1 in two former studies (20, 24). The mean age of starting the treatment was 5.4 weeks with a range of 1 to 44 weeks. In line with other studies almost half of our patients had bilateral club foot (25, 26). Our treatment success rate was also similar to other studies (15, 27, 28). According to the definition of recurrence 5 feet in our study required surgery after casting during follow up visits. Ponseti method is recommended to be started as soon as possible after birth while some studies have shown fair efficacy of treatments starting in older ages (15, 25, 29).

The remained deformity after treatment in our patients undergoing treatment at the first month of age was significantly more than those in older ages. This might be due to the higher flexibility of younger patients' feet being treated in shorter periods and fewer numbers of serial castings compared to the older children. As the Ponseti method cannot treat the pathology of club foot, there is more deformity recurrence by skeletal development in younger patients. During the treatment period, the mean number of casts per feet was 6.5 which was the same as other studies (25, 30). Achilles tenotomy in our study was performed after completing the serial casting for 84% of our patients ($<10^{\circ}$ passive dorsiflexion), while some studies have reported higher (96%) and lower frequencies (75% and 79% and) (16, 17, 22, 23, 26). No deformity was seen in 119 out of 203 feet at the final follow up while the rest of children had some degrees of clinical deformity, but not severe enough to need surgery. There was a significant correlation between the number of the serial castings and the remained deformity. This result is rational as the more severe the deformity the more the number of needed castings. At the end of the study, 185 feet (91%) were in stage 1 and 11 feet (5.4%) were in stage 2 and no foot were found in stages 3 & 4 according to the Dimeglio score. We have evaluated 3 radiologic parameters in AP and 4 in lateral views. There was a significant correlation between tibio-calcaneal angle and passive dorsiflexion. In another study, significant correlations were found between the clinical manifestations and

the first talo-metatarsus angle in AP view as well as the first calcano-metatarsus angle in lateral view (31). The authors believe that the abnormality in radiologic parameters does not indicate a clinical abnormality in physical examination; so, two results may be achieved: firstly, as the diagnosis of club foot is a clinical judgment, we may evaluate the treatment process only by the clinical presentations with no need for plain radiography; and secondly, the Ponseti method can only result in the foot normal shape but fails to treat the bone deformities (shown in radiographies), and may cause some long term problems. Hence, modifications in the Ponseti method for correction of bone deformities are suggested. Also, More studies using the clinical findings for diagnosis and follow up of club foot patients without radiographic imaging are needed.

Taghi Baghdadi MD
Nima Bagheri MD
Mahmoud Farzan MD
Arvin Najafi MD
Pejman Mansouri MD
Joint Reconstruction Research Center, Imam Khomeini Hospital, Tehran University of Medical Sciences, Tehran, Iran

References

1. Wynne-Davies R. Family studies and aetiology of club foot. *J Med Genet.* 1965; 2(4):227-32.
2. Saltzman HM. Foot focus: international initiative to eradicate clubfeet using the Ponseti Method. *Foot Ankle Int.* 2009; 30(5):468-71.
3. Dobbs MB, Morcuende JA, Gurnett CA, Ponseti IV. Treatment of idiopathic clubfoot: an historical review. *Iowa Orthop J.* 2000; 20(1):59-64.
4. Laaveg SJ, Ponseti IV. Long-term results of treatment of congenital club foot. *J Bone Joint Surg Am.* 1980; 62(1):23-31.
5. Ippolito E, Farsetti P, Caterini R, Tudisco C. Long-term comparative results in patients with congenital clubfoot treated with two different protocols. *J Bone Joint Surg Am.* 2003; 85-A(7):1286-94.
6. Herzenberg JE, Radler C, Bor N. Ponseti versus traditional methods of casting for idiopathic clubfoot. *J Pediatr Orthop.* 2002; 22(4):517-21.
7. Morcuende JA. Congenital idiopathic clubfoot: prevention of late deformity and disability by conservative treatment with the Ponseti technique. *Pediatr Ann.* 2006; 35(2):128-30.
8. Besse JL, Leemrijse T, Themar-Noel C, Tourne Y. Congenital club foot: treatment in childhood, outcome and problems in adulthood. *Rev Chir Orthop Reparatrice Appar Mot.* 2006; 92(2):175-92.
9. Cooper DM, Dietz FR. Treatment of idiopathic clubfoot. A thirty-year follow-up note. *J Bone Joint Surg Am.* 1995; 77(10):1477-89.
10. Beyaert C, Haumont T, Paysant J, Lascombes P, Andre JM. The effect of inturning of the foot on knee kinematics and kinetics in children with treated idiopathic clubfoot. *Clin Biomech (Bristol, Avon).* 2003; 18(7):670-6.
11. Roche C, Mattingly B, Talwalkar V, Tylkowski C, Stevens DB, Hardy PA, et al. Tarsal shape, size, and articulating surface morphology in adolescent surgically treated clubfoot and their contralateral normal foot. *J Pediatr Orthop.* 2006; 26(3):329-35.
12. Farsetti P, De Maio F, Russolillo L, Ippolito E. CT

- study on the effect of different treatment protocols for clubfoot pathology. *Clin Orthop Relat Res.* 2009; 467(5):1243-9.
13. Dimeglio A, Bensahel H, Souchet PH, Mazeau PH, Bonnet F. Classification of clubfoot. *J Pediatr Orthop B.* 1995; 4(2):129-36.
 14. Vanderwilde R, Staheli LT, Chew DE, Malagon V. Measurements on radiographs of the foot in normal infants and children. *J Bone Joint Surg Am.* 1988; 70(3):407-15.
 15. Spiegel DA, Shrestha OP, Sitoula P, Rajbhandary T, Bijukachhe B, Banskota AK. Ponseti method for untreated idiopathic clubfeet in Nepalese patients from 1 to 6 years of age. *Clin Orthop Relat Res.* 2009; 467(5):1164-70.
 16. Radler C, Mindler GT, Riedl K, Lipkowski C, Kranzl A. Midterm results of the Ponseti method in the treatment of congenital clubfoot. *Int Orthop.* 2013; 37(9):1827-31.
 17. Porecha MM, Parmar DS, Chavda HR. Mid-term results of Ponseti method for the treatment of congenital idiopathic clubfoot--(a study of 67 clubfeet with mean five year follow-up). *J Orthop Surg Res.* 2011; 6(1):3.
 18. Jowett CR, Morcuende JA, Ramachandran M. Management of congenital talipes equinovarus using the Ponseti method: a systematic review. *J Bone Joint Surg Br.* 2011; 93(9):1160-4.
 19. Ponseti IV. Treatment of congenital club foot. *J Bone Joint Surg Am.* 1992; 74(3):448-54.
 20. Morcuende JA, Dolan LA, Dietz FR, Ponseti IV. Radical reduction in the rate of extensive corrective surgery for clubfoot using the Ponseti method. *Pediatrics.* 2004; 113(2):376-80.
 21. Lehman WB, Mohaideen A, Madan S, Scher DM, Van Bosse HJ, Iannacone M, et al. A method for the early evaluation of the Ponseti (Iowa) technique for the treatment of idiopathic clubfoot. *J Pediatr Orthop B.* 2003; 12(2):133-40.
 22. Sætersdal C, Fevang JM, Fosse L, Engesæter LB. Good results with the Ponseti method: a multicenter study of 162 clubfeet followed for 2-5 years. *Acta Orthop.* 2012; 83(3):288-93.
 23. Matuszewski L, Gil L, Karski J. Early results of treatment for congenital clubfoot using the Ponseti method. *Eur J Orthop Surg Traumatol.* 2012; 22(5):403-6.
 24. Ostadal M, Chomiak J, Dungal P, Frydrychova M, Burian M. Comparison of the short-term and long-term results of the Ponseti method in the treatment of idiopathic pes equinovarus. *Int Orthop.* 2013; 37(9):1821-5.
 25. Faizan M, Jilani LZ, Abbas M, Zahid M, Asif N. Management of idiopathic clubfoot by Ponseti technique in children presenting after one year of age. *J Foot Ankle Surg.* 2015; 54(5):967-72.
 26. Cosma DI, Vasilescu DE. Ponseti treatment for clubfoot in Romania: a 9-year single-centre experience. *J Pediatr Orthop B.* 2014; 23(6):512-6.
 27. Khan SA, Kumar A. Ponseti's manipulation in neglected clubfoot in children more than 7 years of age: a prospective evaluation of 25 feet with long-term follow-up. *J Pediatr Orthop B.* 2010; 19(5):385-9.
 28. Lourenco AF, Morcuende JA. Correction of neglected idiopathic club foot by the Ponseti method. *J Bone Joint Surg Br.* 2007; 89(3):378-81.
 29. Alves C, Escalda C, Fernandes P, Tavares D, Neves MC. Ponseti method: does age at the beginning of treatment make a difference? *Clin Orthop Relat Res.* 2009; 467(5):1271-7.
 30. O'Halloran CP, Halanski MA, Nemeth BA, Zimmermann CC, Noonan KJ. Can radiographs predict outcome in patients with idiopathic clubfeet treated with the ponseti method? *J Pediatr Orthop.* 2015; 35(7):734-8.
 31. Abulsaad M, Abdelgaber N. Correlation between clinical outcome of surgically treated clubfeet and different radiological parameters. *Acta Orthop Belg.* 2008; 74(4):489-95.