

TECHNICAL NOTE

Collateral Ligament Tension Guided Medial Unicompartmental Knee Revision to a Kinematically Aligned Total Knee Arthroplasty

Giorgio Cacciola, MD; Daniele Vezza, MD; Luigi Sabatini, MD

Research performed at Humanitas "Gradenigo" Hospital in Turin (Italy)

Received: 17 March 2025

Accepted: 18 January 2026

Abstract

Objectives: This study presents a novel approach to revising failed medial unicompartmental knee arthroplasty into kinematically aligned total knee arthroplasty using an augmented reality (AR) system (NextAR by Medacta International). Traditional methods involve mechanically aligned total knee arthroplasty (TKA), which can be complex and often requires additional components like stems and augments. The proposed technique builds on the caliper-based manual method by integrating AR-based navigation to enhance precision during surgery, particularly in maintaining the patient's native joint line and soft tissue behavior. The procedure includes preoperative three-dimensional planning and intraoperative adjustments based on real-time data on collateral ligament elongation. This AR-assisted technique aims to reduce the technical challenges associated with unicompartmental knee arthroplasty (UKA) revisions, offering potential benefits for alignment accuracy and soft-tissue management.

Level of evidence: V

Keywords: Augmented reality, Kinematic alignment, Medial UKA, NextAR, Revision

Introduction

Unicompartmental knee arthroplasty (UKA) is considered a successful procedure with higher patient satisfaction compared to total knee arthroplasty (TKA).¹ This kind of implant is often chosen for younger patients with osteoarthritis confined to just one of the three compartments of the knee. Despite high patient satisfaction rates after UKA, the failure rate is approximately double that of TKA.² The main causes of UKA failure are osteoarthritis progression (37% and aseptic loosening (31%).³ For years, the gold standard for treating failed UKA has been revision to a mechanically aligned (MA) TKA.⁴ This technically complex procedure often requires the use of adjuncts such as augments, revision tibial plates with stems, and bone grafts (30-60% depending on different case series).⁵ Recently, Shelton and Howell published an interesting surgical technique that involves revising UKA to TKA using kinematic alignment (KA).^{6,7} Their technique involves performing femoral resurfacing under the assumption that the femoral component was correctly positioned without altering the

distal and posterior joint lines. In their series of 16 patients, all revisions were performed using primary implants without augments or stems, and the reported results were similar to the outcomes of primary KA-TKA.⁷

In this study, we will describe a variation of the calipered manual technique described by Shelton for UKA to TKA revisions using KA,⁶ evaluating the collateral ligament elongation provided by the NextAR TC-based augmented reality (AR) system (Medacta International, Castel San Pietro, Switzerland).^{8,9}

Surgical Technique

Considering that the primary objective of KA is to restore the patient's native joint line, it is essential to assess whether the UKA has been positioned while preserving the native LDFA and MPTA. If preoperative and postoperative weight-bearing long-leg radiographs are available, these values should be compared. If the values are identical, they should be maintained during planning. If they differ, the native LDFA values should be chosen during planning. In the

Corresponding Author: Giorgio Cacciola, University of Turin, Department of Orthopaedic and Traumatology, Turin, Italy

Email: giorgiocacciola@unito.it



THE ONLINE VERSION OF THIS ARTICLE
ABJS.MUMS.AC.IR



absence of preoperative radiographs (pre-UKA), a comparative analysis between the lateral distal femoral angle (LDFA) and the medial proximal tibia angle (MPTA) of the affected side and the contralateral side can be performed.^{8,9}

The NextAR system involves uploading a computed tomography (CT) scan of the lower limbs, from which a series of data on lower limb alignment is extracted, allowing for a three-dimensional planning of components and selection of the orientation and thickness of cuts. To maintain the distal femoral joint line, we planned a 9 mm cut on both the medial and lateral sides (the femoral component used in this study has a distal thickness of 9 mm). On the lateral side, the 9 mm consists of 6 mm of bone + 2 mm of cartilage + 1 mm of saw thickness, while on the medial side,

of the UKA + the underlying cancellous bone to reach a total thickness of 8 mm + 1 mm of saw thickness. For the posterior plane, a cut at 0° relative to the posterior condylar axis will be planned, removing 5 mm of bone, + 2 mm of cartilage in the lateral compartment + 1 mm of saw blade thickness on the lateral side, while on the medial side consisting of the distal thickness of the UKA + the underline cancellous bone to reach a total thickness of 7 mm + 1 mm of saw thickness (the prosthesis used in this study has a posterior thickness of 8 mm). Initially, the tibial cut will be planned to maintain the native MPTA and tibial slope (this value can be adjusted intraoperatively based on information acquired during evaluation of the collateral ligament elongation after femoral resurfacing).^{8,9} [Figure 1]

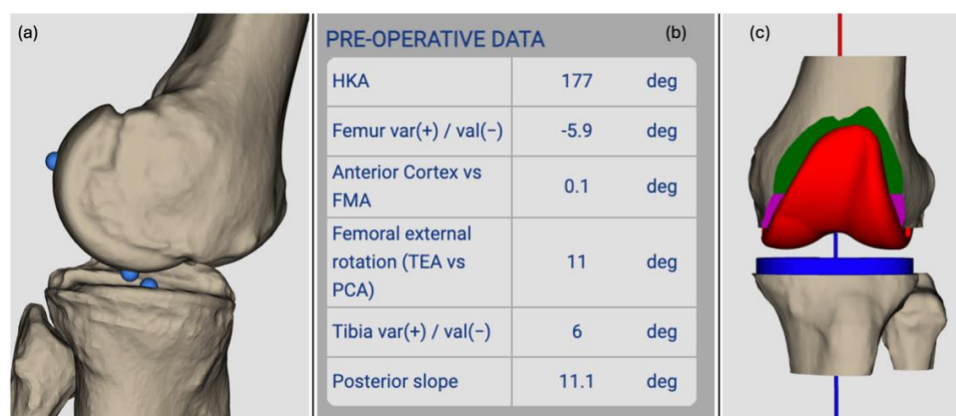


Figure 1. (a) Preoperative 3d medial side of the knee showing the femoral and tibial components. (b) Preoperative data provided by the software. (c) 3D model of the planned resection with implantation of the definitive component

After performing an extensive surgical approach on the previous scar and completing the arthrotomy, tibial and femoral pins will be placed to accommodate the infrared cameras as described in the previous study.^{8,9} During this phase, osteophytes should not be removed, nor should prosthetic components be taken out, to ensure accurate

registration between the bone surface and the CT scan. After completing the surface registration, we performed the navigation of the distal femoral cut. Before proceeding with distal resection, the femoral component and the insert should be removed. [Figure 2]

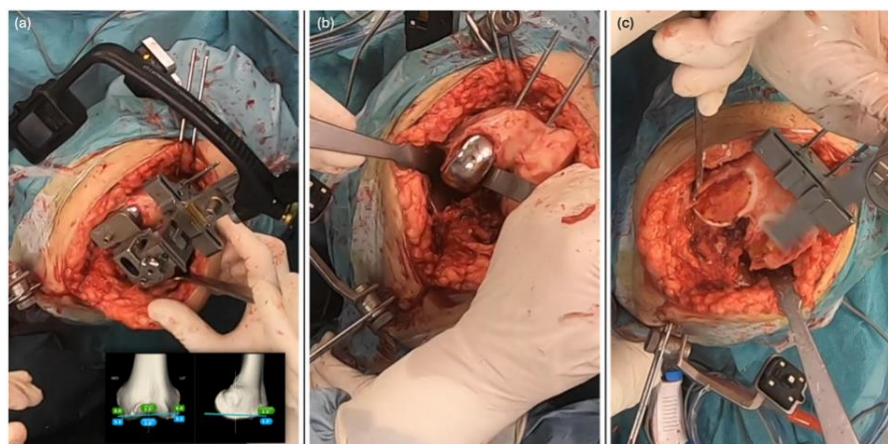


Figure 2. (a) Navigation of the distal cutting guide position with the femoral component in situ. (b) Pins of the distal cutting guide are placed, and the femoral component is removed before proceeding with the distal femoral resection. (c) The distal femoral resection is performed to achieve a 9 mm

thickness on both the medial and lateral sides, while maintaining the native (planned) LDFA

Then, proceed with the posterior femoral cut by navigating the four-in-one cutting guide position at 0° on the posterior condylar axis. [Figure 3]

At this point, the planned size femoral trial component will be positioned, and the liner of the UKA will be reinserted to assess the elongation of the collateral ligaments after femoral resurfacing. Our goal is to achieve an isometric

medial collateral ligament (MCL) and a lateral collateral ligament (LCL) that are taut in extension and shorten in flexion, allowing for medial pivot. Based on this information, the tibial resection plan will be adjusted until the desired soft-tissue elongation is achieved. [Figure 4]

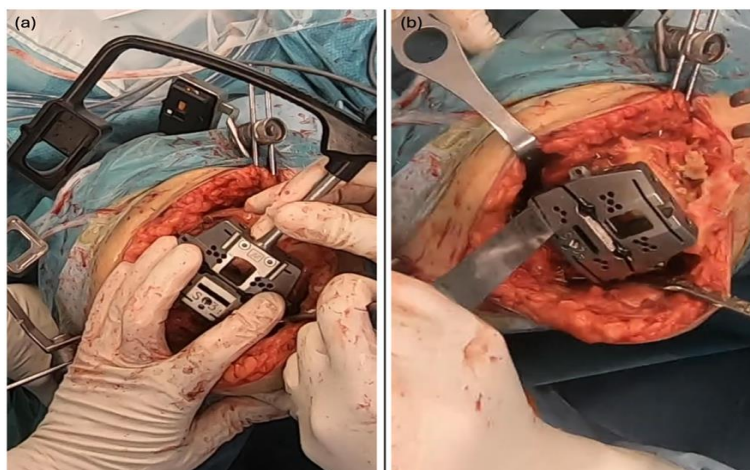


Figure 3. (a) Navigation of the four-in-one guide: the guide is positioned with a thickness of 8 mm and a rotation of 0° to the theoretically native posterior condylar axis. (b) Resection of the posterior medial condyle

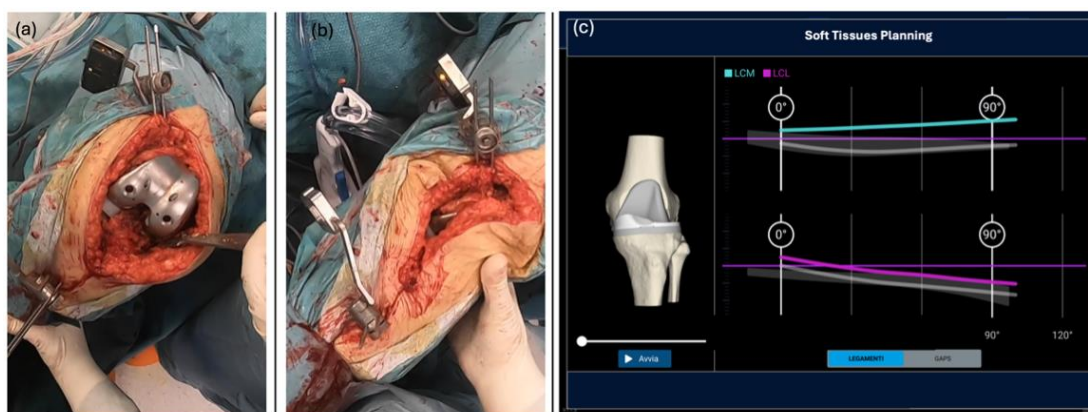


Figure 4. Knee stability and range of motion are evaluated with the femoral trial component and with the UKA tibial component and insert in situ. (a) The stability at 90° of flexion is assessed. (b) The stability at full extension is assessed. (c) By evaluating MCL and LCL behavior, the orientation of the tibial cut in the coronal and sagittal planes can be adjusted until the desired elongation is achieved. We aim for isometric behavior of the MCL throughout the whole range of motion (turquoise line at the top of the right image), and at an LCL that is stretched in extension and loose in flexion (purple line on the bottom of the right image)

Unlike the femoral cut, it is recommended to remove the tibial component using osteotomes, chisels, or saw blades before navigating the positioning of the tibial cutting guide. Considering the presence of the tibial component of the UKA, the tibial cut should be made just below the previous osteotomy plane, with a varus/valgus orientation to achieve the correct elongation of the ligaments. [Figure 5]

Next, we assessed the gaps during both flexion and

extension using spacer blocks — 10 mm for flexion and 12 mm for extension — to account for the missing posterior condyles. The final components are implanted if the extension gap shows balanced spacing (with less than 1 mm variation between the medial and lateral compartments) and the flexion gap appears trapezoidal with a lateral opening of 2-3 mm.^{8,9} [Figure 6]

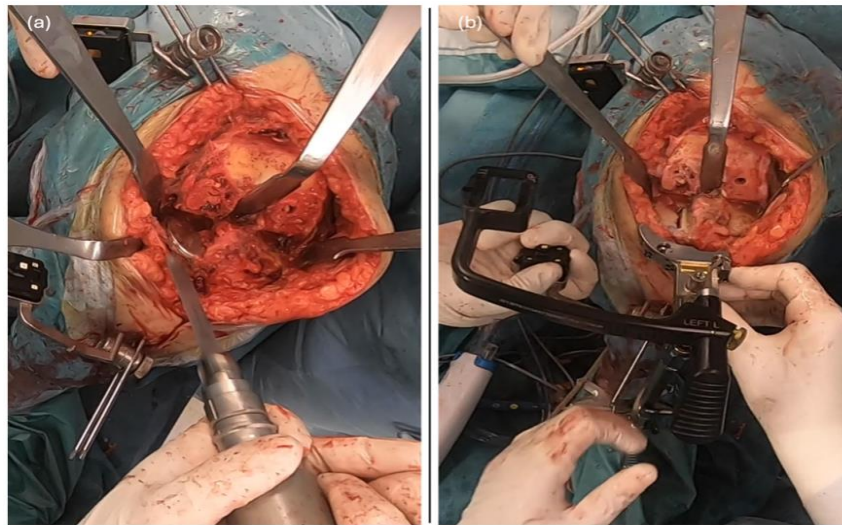


Figure 5. (a) The removal of the tibial component of the UKA is suggested before navigating the position of the tibial cutting height. (b) The proximal tibia cutting guide is navigated in the corrected position as planned after soft tissue behavior evaluation with the femoral trial component. Once the blue line (real-time position of the guide) is parallel to the green line (planned position of the guide)

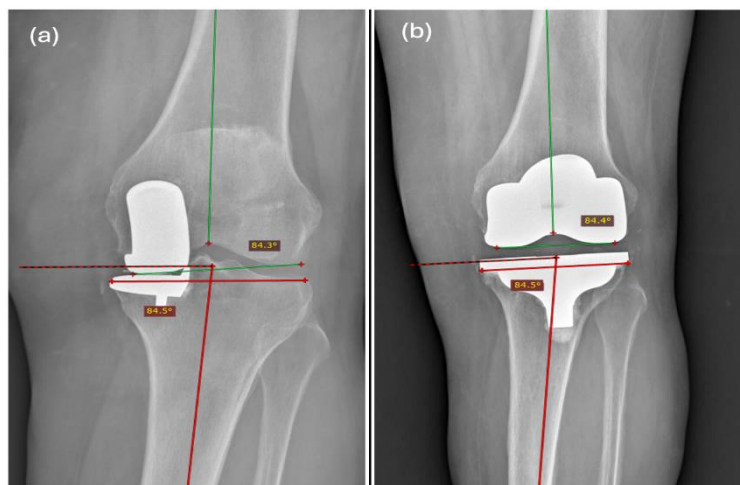


Figure 6. Preoperative and postoperative radiographs of the left knee of a 63-year-old woman. (a) Preoperative radiograph showing polyethylene wear diagnosed two years after primary unicompartmental knee arthroplasty (UKA). (b) Postoperative radiograph at one year following kinematically aligned total knee arthroplasty (KA-TKA) revision performed with NextAR assistance, demonstrating accurate restoration of the lateral distal femoral angle (LDFA) and medial proximal tibial angle (MPTA)

Discussion

This technique involves using a CT-based AR navigation system to revise a UKA to a KA-TKA. It is a variation of the standard manual technique described by Shelton and Howell in 2021,⁶ enhanced by the evaluation of soft tissue elongation using an AR-assisted navigation system.^{8,9}

Shelton and Howell were the first to describe a calibrated manual technique for revising UKA to KA-TKA. The strength of this procedure lies in simplifying the complex UKA revision process.⁶ In their series of 16 patients, they demonstrated that this technique resulted in no significant differences in postoperative lower limb alignment

parameters (hip-knee angle, LDFA, and MPTA) and postoperative clinical score between the UKA revisions and primary KA-TKAs. Moreover, there was no need for the use of augments, stems, or bone grafts in any case.⁶

The technique described in this study, supported by three-dimensional planning and detailed information on lower limb alignment, allows precise navigation of the cutting guides, effectively avoiding potential errors in the positioning of UKA components or discrepancies in the thicknesses of the lateral distal and posterior femoral cartilage.^{8,10} The main advantages are particularly evident in the placement of the distal cutting guide, which is based

on the LDFA and the desired bone thickness. Specifically, a 6 mm bone cut on the distal femoral condyle with native valgus alignment is planned. Similarly, by navigating the position of the four-in-one guide, the risk of positioning errors inherent in the manual technique—which relies on filling gaps with spacers or shims and may not always be precise—can be reduced.⁶ Another key advantage of using the NextAR system is the ability to assess collateral ligament elongation, enabling intraoperative planning of the tibial cut after femoral resurfacing to eventually compensate for a change in the varus/valgus orientation of the tibial component of the UKA.^{8,9}

Another important advantage of revising a UKA to a KA-TKA is that, by restoring the native femoral joint line and performing the tibial cut just below the previous position of the UKA tibial component while maintaining the native MPTA, neither the orientation nor the height of the joint line will be altered. To correctly restore the joint line, it will be sufficient to increase the insert thickness until proper knee stability is achieved in both extension and flexion. One limitation of this technique is the potential difficulty of accurately restoring the rotational alignment of the femoral component during UKA revision to KA-TKA. However, Shelton and Howell proposed a reproducible method to address this issue, which has demonstrated reliable results.⁶ Specifically, they adjusted the posterior medial foot of the referencing guide by an amount equal to the combined thickness of the posterior condyle of the unicondylar femoral component and the bone previously removed. Alternatively, they suggested inserting a spacer, corresponding to the estimated bone and cartilage loss, between the posterior bone surface and the referencing guide. By applying this technique, they achieved comparable femoral component rotational alignment in both revised and primary KA-TKA cases, as confirmed by postoperative CT assessment. Moreover, using navigation to control the positioning of the 'four-in-one' cutting block, based on the known position of the previous femoral component, further reduces potential alignment errors, increasing the accuracy and reproducibility of the procedure.⁶

Conclusion

In conclusion, the use of a CT-based AR system for revising UKA to KA-TKA offers significant potential advantages in planning and performing femoral and tibial resections compared to manual techniques. Building upon the work of Shelton and Howell, this technique refines the process by incorporating real-time evaluation of soft-tissue elongation and three-dimensional planning, thus addressing potential errors in component positioning inherent in manual methods. The advantages of this

approach are particularly notable in the accurate placement of the distal cutting guide, guided by the LDFA and desired bone thickness. Additionally, the ability to assess and adjust collateral ligament elongation intraoperatively allows for more tailored tibial resection. However, this technique is only one of several viable options for aseptic loosening of UKA. Depending on the specific clinical scenario, other strategies — such as complete conversion to TKA using a mechanical alignment approach, or even revision with a new UKA — may be considered. The choice of strategy should be based on the extent of loosening, bone stock quality, ligamentous integrity, and patient-specific factors.

Acknowledgement

N/A

Authors Contribution: Authors who conceived and designed the analysis: Giorgio Cacciola, Luigi Sabatini/Authors who collected the data: Daniele Vezza/Authors who contributed data or analysis tools: Giorgio Cacciola, Daniele Vezza/Authors who wrote the paper: Luigi Sabatini, Giorgio Cacciola

Declaration of Conflict of Interest: Luigi Sabatini is a paid consultant by Medacta International. Giorgio Cacciola and Daniele Vezza have no conflict of interest.

Declaration of Funding: No financial support was provided for the preparation, research, authorship, and publication of this manuscript.

Declaration of Ethical Approval for Study: Ethics committee approval was obtained for this study (Territorial Ethics Committee A.O.U. Citta della salute e della scienza, Turin, Italy 00025/2024).

Declaration of Informed Consent: The informed consent was acquired for the patient that underwent the surgical procedure described in this study and it is collected at our institution.

Giorgio Cacciola MD ¹

Daniele Vezza MD ²

Luigi Sabatini MD ²

1 University of Turin, Department of Orthopaedic and Traumatology, Turin, Italy

2 Humanitas "Gradenigo" Hospital, Department of robotic and mini invasive surgery, Turin, Italy

References

1. Patel KT, Lewis TL, Gill P, Chatterton M. The patient perspective, experience and satisfaction of day case unicompartmental knee arthroplasty: a short-term mixed-methods study. *Knee.* 2021;33:378-385.

doi:10.1016/j.knee.2021.10.022.

2. Morales-Avalos R, Perelli S, Raygoza-Cortez K, et al. Fixed-bearing unicompartmental knee arthroplasty provides a lower failure rate than mobile-bearing unicompartmental knee

- arthroplasty when used after a failed high tibial osteotomy: a systematic review and meta-analysis. *Knee Surg Sports Traumatol Arthrosc.* 2022;30(9):3228-3235. doi:10.1007/s00167-021-06707-4.
3. Tay ML, McGlashan SR, Monk AP, Young SW. Revision indications for medial unicompartmental knee arthroplasty: a systematic review. *Arch Orthop Trauma Surg.* 2022;142(2):301-314. doi:10.1007/s00402-021-03827-x.
 4. Lee JK, Kim HJ, Park JO, Yang JH. Inferior outcome of revision of unicompartmental knee arthroplasty to total knee arthroplasty compared with primary total knee arthroplasty: systematic review and meta-analysis. *Knee Surg Sports Traumatol Arthrosc.* 2018;26(11):3403-3418. doi:10.1007/s00167-018-4909-3.
 5. Chou DT, Swamy GN, Lewis JR, Badhe NP. Revision of failed unicompartmental knee replacement to total knee replacement. *Knee.* 2012;19(4):356-359. doi:10.1016/j.knee.2011.05.002.
 6. Shelton TJ, Gill M, Athwal G, Howell SM, Hull ML. Revision of a medial UKA to a kinematic aligned TKA: comparison of operative complexity, postoperative alignment, and outcome scores to a primary TKA. *J Knee Surg.* 2021;34(4):406-414. doi:10.1055/s-0039-1696734.
 7. Nedopil AJ, Howell SM, Hull ML. Kinematically aligned total knee arthroplasty using calipered measurements, manual instruments, and verification checks. In: Rivière C, Vendittoli PA, eds. *Personalized Hip and Knee Joint Replacement.* Springer; 2020. Chap 24.
 8. Sabatini L, Ascani D, Vezza D, Massè A, Cacciola G. Novel surgical technique for total knee arthroplasty integrating kinematic alignment and real-time elongation of the ligaments using the NextAR system. *J Pers Med.* 2024;14(8):794. doi:10.3390/jpm14080794.
 9. Fucetese SF, Koch PP. A novel augmented reality-based surgical guidance system for total knee arthroplasty. *Arch Orthop Trauma Surg.* 2021;141(12):2227-2233. doi:10.1007/s00402-021-04204-4.
 10. Giurazza G, Caria C, Campi S, et al. Femoral cartilage thickness measured on MRI varies among individuals: time to deepen one of the principles of kinematic alignment in total knee arthroplasty. A systematic review. *Knee Surg Sports Traumatol Arthrosc.* 2025;33(2):634-645. doi:10.1002/ksa.12408.