

RESEARCH ARTICLE**Combination of Arthroscopic Arthrolysis and Minimal Invasive Quadricepsplasty for Management of Stiff Knee: Our Experience**

Bushu Harna, MS; Shivali Arya, MD; Dinesh Sandal, MS

*Research performed at Joint Indus International Hospital, Derabassi, Panjab, India**Received: 01 September 2025**Accepted: 19 December 2025***Abstract**

Objectives: Knee stiffness following surgeries around the knee significantly limits functional mobility and quality of life. This study aimed to evaluate the clinical outcomes of arthroscopic arthrolysis combined with minimally invasive quadricepsplasty in the management of post-surgical knee stiffness

Methods: This retrospective study included 14 patients with knee stiffness persisting for at least one year despite implant removal. All patients underwent arthroscopic arthrolysis with modified quadricepsplasty through a small midline incision over the superior pole of the patella. The procedure involved isolation of the rectus femoris, release of medial and lateral adhesions, and elevation of the quadriceps from the underlying femur. A standardized aggressive postoperative rehabilitation protocol was followed. Patients were evaluated for demographic details, knee range of motion (ROM), Visual Analog Scale (VAS), and Knee Society Score (KSS) at a minimum follow-up of 12 months.

Results: The mean patient age was 34.7 ± 5.2 years, with a mean duration of knee stiffness of 1.4 ± 0.6 years from the index injury. Mean preoperative extension lag was 15° and flexion was 50° , which improved significantly to 3° and 115° , respectively, at final follow-up. Significant postoperative improvements were observed in both KSS and VAS scores. According to Judet's criteria, most patients achieved excellent outcomes. One patient developed minor wound complications, which resolved with conservative management.

Conclusion: Arthroscopic arthrolysis combined with minimally invasive quadricepsplasty is an effective and safe treatment for post-surgical knee stiffness, providing significant improvements in knee ROM, pain relief, and functional outcomes with minimal complications.

Level of evidence: IV

Keywords: Arthroscopic arthrolysis, Knee movement; Minimal invasive; Quadricepsplasty; Stiff knee

Introduction

Knee range of motion is crucial in maintaining functional mobility and overall quality of life.¹ A typical range of 0° to 125° is sufficient for most daily activities, with even minor reductions, such as a 5° loss of knee extension, which can significantly increase the energy demands of the quadriceps and alter gait mechanics.² Arthrofibrosis, a condition characterised by restricted

knee motion due to scar tissue formation, occurs after various orthopaedic injuries or surgeries, with reported incidence rates ranging from 0% to 4% following ligament reconstruction and up to 7% after high-energy tibial fractures.³

Several surgical techniques, such as quadricepsplasty, have been developed to address knee contractures resulting from arthrofibrosis. The Thompson⁴ and Judet⁵

Corresponding Author: Bushu Harna, Aero Homes, Zirakpur, Punjab, India

Email: bushu.edu@gmail.com



THE ONLINE VERSION OF THIS ARTICLE
ABJS.MUMS.AC.IR



quadricepsplasties have been widely employed but are associated with complications like skin necrosis, infection, and incomplete knee extension. Modifications of these techniques have been proposed to improve outcomes while minimising complications.^{6,7}

This study aims to evaluate the clinical outcomes of arthroscopic arthrolysis and minimal invasive quadricepsplasty for managing knee stiffness.

Materials and Methods

Patients

This was a retrospective study performed over 4 years in accordance with the Institute's Ethical Committee (IEC/IIH 03/2024), and informed consent was obtained from all patients to be part of the study as well as for the publication of their clinical data and photographs. Fourteen patients were included in the study with a minimum of 12 months of follow-up. The inclusion criteria included patients more than 18 years old of either gender with knee stiffness due to any previous surgery or trauma. All these patients had troublesome knee stiffness for at least 1 year. The hardware around the knee joint had already been removed for more than 1 year, but still had significant knee stiffness hindering the activities of daily living. The patients with age under 18 years, active infection, knee arthroplasty, knee stiffness but satisfactorily performing activities of daily living, osteoarthritis changes on radiographs, incongruent joint surfaces and history of patellectomy were excluded from the study.

Assessment

All the patients were assessed for demographic data, including age, sex, involved limb, index surgery and morphology of the trauma.

The skin and scar condition of the knee was examined, and the duration of stiffness, range of the knee motion, visual analogue score (VAS) and knee society score (KSS) were recorded.

All the patients were counselled, and surgical intervention was performed.

Surgical Technique

All patients were assessed for knee range of motion under anaesthesia [Figure 1]. All patients underwent arthroscopic arthrolysis first using standard anteromedial and anterolateral portals. The diagnostic arthroscopy was performed, and fibrotic bands were removed. The adhesions in the suprapatellar pouch and patellofemoral compartment were removed using a 4.5mm shaver in knee extension [Figure 2]. The infrapatellar fat pad was debrided. The adhesions in the medial and lateral gutters were also shaved off. The knee flexion was tried after the completion of the arthroscopic arthrolysis.

Afterwards, a 4-6 cm suprapatellar midline incision was given extending from the superior pole of the patella. The subcutaneous dissection was done to remove any adhesions. The quadriceps muscle was dissected from the lateral and medial tissue adhesions using sharp scissors.

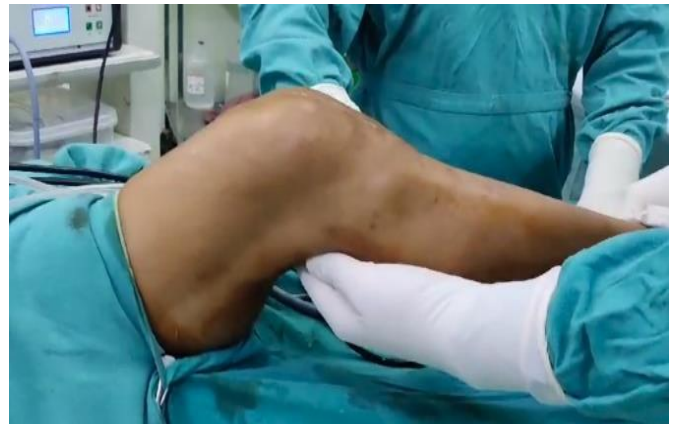

Figure 1. Clinical picture of the maximum knee flexion preoperatively.

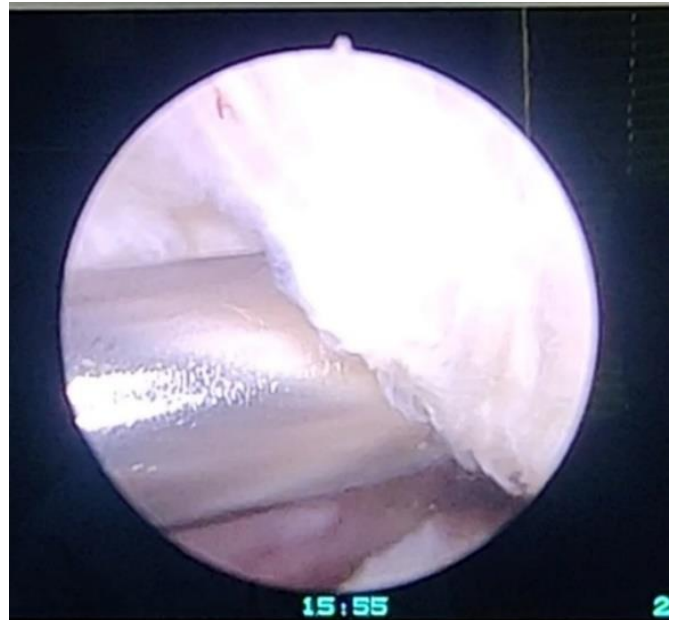


Figure 2. Arthroscopic arthrolysis depicting fibrosis in the suprapatellar pouch

The blunt dissection isolated the rectus femoris muscle from the vastus medialis, vastus lateralis, and vastus intermedius. The rectus tendon was separated from the rest using a long roller gauge [Figure 3]. The tendon of the vastus intermedius was then transected from the superior pole of the patella. The rest of the quadriceps muscle was erased from the femur using the osteotomes, saving the rectus femoris from any damage [Figure 4]. The tissues were erased from the lateral and medial aspects of the distal femur and proximally as far as possible with a sharp osteotome. The adhesions in the suprapatellar pouch and the patellofemoral compartment were broken using a small osteotome and blunt scissors. The medial and lateral retinaculum was incised using a sharp scissor from the superior pole of the patella, extending inferiorly [Figure 5]. The medial and lateral capsules were released from the

distal femoral condyles with the help of a sharp knife. The vastus lateralis was dissected from the iliotibial band. The hip and knee were flexed after every step of release to assess the knee flexion. At last, with the hip flexed, the knee was flexed until maximum flexion was achieved [Figure 6]. This manoeuvre was repeated 3-5 times slowly and cautiously. The endpoint was to achieve full knee flexion

with the hip flexed at 90 degrees. Caution was taken not to rupture the rectus femoris and patellar tendon or any other ligament. This was confirmed with the help of dry arthroscopy at the end of the procedure. The wound closure comprised of skin sutures with the knee in full flexion, 20 ml of 0.75% ropivacaine infiltration and dressing with the knee in flexion.

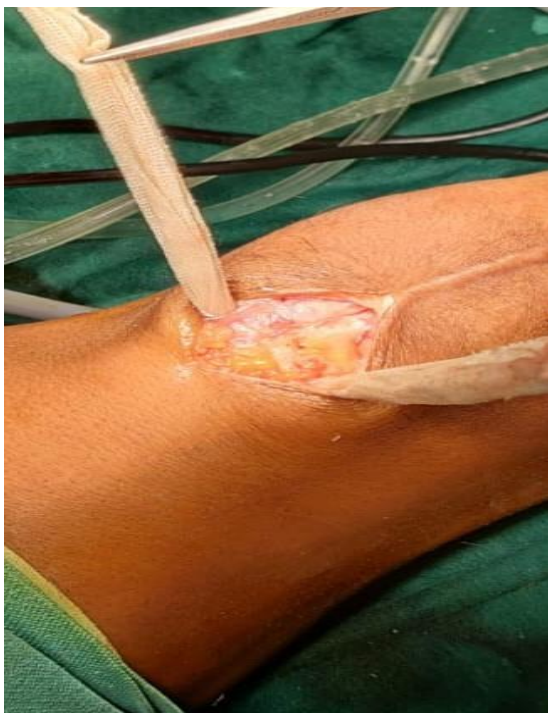

Figure 3. Isolation of the rectus femoris muscle from the adjacent adhesions.

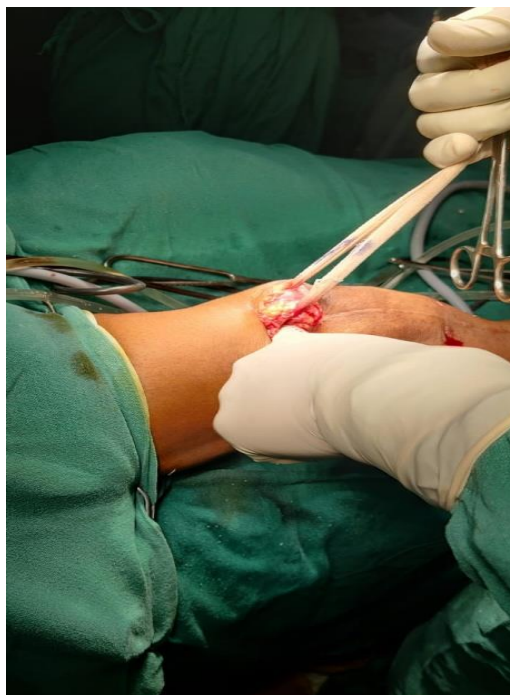

Figure 4. Erasing quadriceps muscle from the underlying femur.

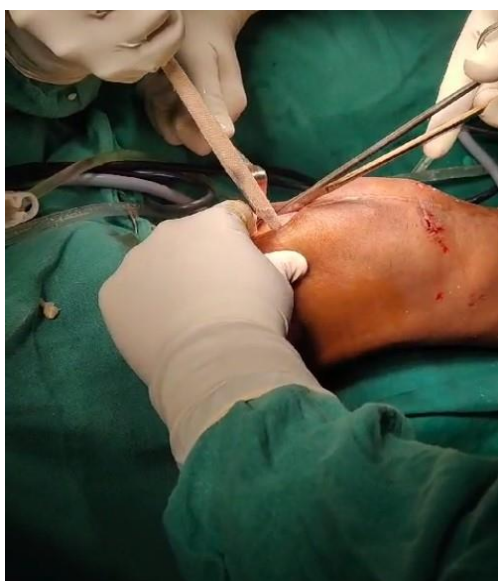

Figure 5. Dissection of the medial and lateral aspects of the knee

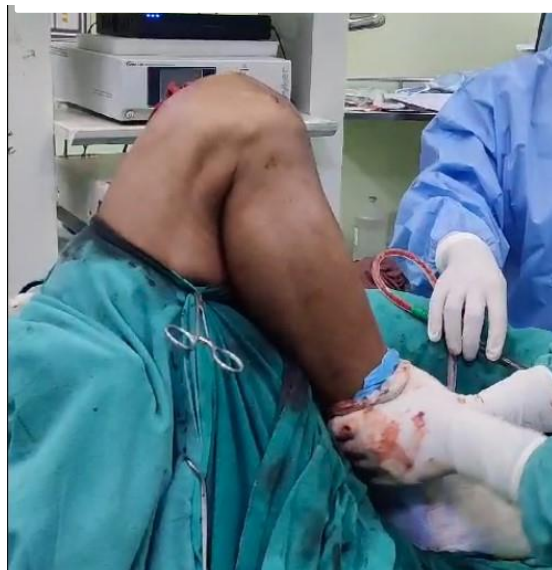

Figure 6. Clinical picture of the near-full range of knee motion in operation theatre

Rehabilitation

Postoperative analgesia was given, and knee motion was started on the 1st postoperative day using a continuous passive motion machine (model 325, Stryker) for 3 days. Active and passive exercises were started under the supervision of the physiotherapist. The patients were mobilised with the help of a stick from the 1st postoperative day and discharged on day 3 from the hospital. All the patients were mobilised thereafter without any walking aid with a long knee brace for 2 weeks.

Weekly follow-ups were done to assess the range of knee motion and the wound condition. In the case of wound dehiscence, wound suturing was performed under aseptic conditions. After 2 weeks, monthly follow-ups were done, and the range of motion and knee functional scores were assessed for at least 12 months [Figure 7]. None of the patients were lost to follow-up.

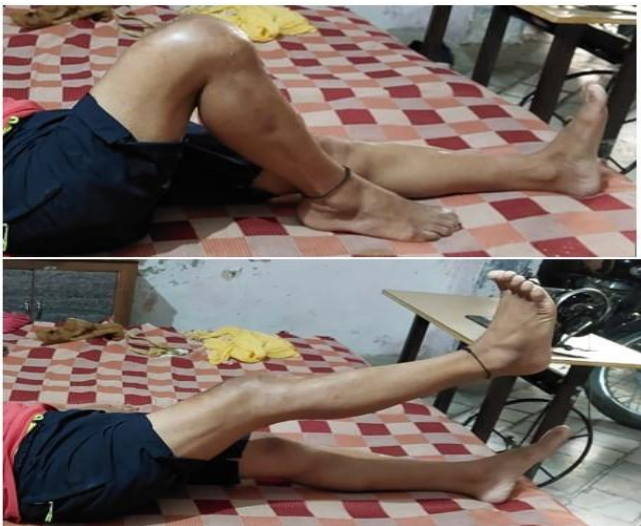

Figure 7. Clinical picture of the follow-up of the patient depicting knee flexion and extension.

Data Collection

Demographic and surgical data were recorded. The patients' minimum follow-up was 12 months. The VAS scores were recorded on days 1, 3, 7, and 14 in the postoperative period. The preoperative and postoperative KSS scores and range of motion were recorded at the last follow-up. A goniometer was used to assess the knee motion. Judet's criteria were used to assess and classify the outcomes after the procedure.⁵

Excellent outcome: knee flexion greater than 100°

Good outcome: knee flexion between 80° and 100°

Fair outcome: knee flexion between 50° and 80°

Poor outcome: knee flexion was less than 50°

Any wound complications and surgical interventions were also recorded.

Statistical analysis

The data was analysed using SPSS version 22 and

Microsoft Excel software. The mean and standard deviation of the quantitative data were calculated. The correlation between variables were analysed. A post-hoc sample-size justification was performed using the primary outcome of improvement in knee ROM. Based on published arthroscopic lysis and quadricepsplasty series reporting mean ROM gains of approximately 26–51° with standard deviations of 20–30°,^{4,5} the analysis was conducted using a conservative clinically meaningful difference of 20°, a within-patient standard deviation of 25°, $\alpha = 0.05$ and a power of 80%. Using the paired-t test approximation, these assumptions yield a required sample size of 13 patients; therefore, the present cohort of 14 patients meets the conservative power requirement and provides adequate statistical power to detect clinically relevant improvements in ROM.

Statistical analysis for this study was performed using paired pre- and postoperative comparisons to evaluate changes in knee flexion, extension lag, Knee Society Score (KSS), and pain scores (VAS). Continuous variables were expressed as mean \pm standard deviation, and paired t-tests were used to assess within-patient differences. Ninety-five per cent confidence intervals were computed using the corresponding t-distribution for 14 participants ($df = 13$). For outcomes with a smaller sample size or potential non-normal distribution, non-parametric testing (Wilcoxon signed-rank test) was planned. Statistical significance was defined at $p < 0.05$, and all analyses were interpreted with consideration of clinical as well as statistical relevance.

Results

Demography

A total of 14 patients were included in the study. There were 11 male and 3 female patients, with an average age of 34.7 ± 5.2 years (Range: 22–44 years). Five patients had left lower limb involvement, and 9 had right lower limb involvement. The average duration of knee stiffness was 1.4 ± 0.6 years (Range: 1–3.5 years), calculated from the index injury.

Morphology of Trauma

Seven patients had distal femur fractures managed with reduction and fixation using a distal femur locking plate and screws. Five patients had knee-spanning external fixators due to open distal femur fracture or open knee injury. One patient had a patella fracture managed with reduction and fixation using tension band wiring, and one patient had a traumatic partial quadriceps tendon injury managed with open repair using sutures. All patients had their implants removed after fracture union, and physiotherapy continued thereafter. At the time of quadricepsplasty, all patients had confirmed fracture union and healed scars with no discharge or active infection for at least 1 year (mean: 1.4 ± 0.6 years).

Functional Status

The average preoperative extension lag was 15° (range: 0–25°), and flexion was 50° (range: 10–80°). There was significant improvement in postoperative extension lag with an average of 3° (range: 0–5°; $p < 0.05$), corresponding to a mean improvement of 12° (95% CI 8.8–15.2). Similarly, the

average flexion improved to 115° (range: 100–135°; $p < 0.05$), representing a mean flexion gain of 65° (95% CI 56.9–73.2).

The mean preoperative KSS was 43.6 ± 3.2 and improved to 83.2 ± 3.2 at the follow-up of 1 year ($p < 0.05$), with a mean improvement of 39.6 points (95% CI 38.0–41.3). The average VAS preoperatively and at days 1, 3, 7, and 14 was 4.3 ± 2.2 , 7.8 ± 2.3 , 7.6 ± 1.4 , 4.8 ± 1.5 , and 2.8 ± 1.6 , respectively. There was a statistically significant reduction in VAS score from preoperative to day 14 (mean change -1.5 ; 95% CI -2.53 to -0.47 ; $p < 0.05$). At the follow-up of 1 year, no patient had significant knee pain, and all were performing daily activities comfortably.

According to Judet's criteria, 11 patients had excellent results, 2 patients had good results, and 1 patient had a fair result at 1-year follow-up [Table 1].

Variable	Preoperative (Mean \pm SD)	Postoperative / Follow-up (Mean \pm SD)	Mean Difference	p-value
Knee Flexion (°)	50 ± 18	115 ± 12	+65°	<0.001
Extension Lag (°)	15 ± 7	3 ± 4	-12°	<0.001
Knee Society Score (KSS)	43.6 ± 3.2	83.2 ± 3.2	+39.6	<0.001
VAS Score	4.3 ± 2.2	2.8 ± 1.6 (Day 14)	-1.5	0.003
Judet Outcome Distribution		Excellent 11, Good 2, Fair 1		0.41

The Shapiro–Wilk test confirmed the normality of paired differences for ROM, extension lag, and KSS ($p > 0.10$), while VAS showed mild deviation but remained consistent on non-parametric testing. Wilcoxon signed-rank tests for extension lag, flexion, KSS, and VAS all showed significant postoperative improvement (all $p < 0.01$), corroborating the paired t-test results. Repeated-measures ANOVA demonstrated a significant effect of time on VAS scores across the preoperative to day-14 interval ($F = 19.4$, $p < 0.001$), and the Friedman test similarly confirmed this trend ($\chi^2 = 26.1$, $p < 0.001$). Post-hoc comparisons with the Holm correction revealed significant reductions between the preoperative and day 7 ($p = 0.02$) and between the preoperative and day 14 ($p = 0.004$). Linear mixed-effects modelling showed time as a significant predictor of improvement in ROM ($\beta = +62.4$, $p < 0.001$), extension lag ($\beta = -11.6$, $p < 0.001$), KSS ($\beta = +39.1$, $p < 0.001$), and VAS ($\beta = -1.4$, $p = 0.01$), confirming consistent gains after surgery.

Complications

Wound dehiscence was observed in 1 patient, requiring resuturing. Knee swelling and effusion occurred in 6 patients and were managed conservatively with medications and ice packs. None of the patients experienced neurovascular injury, excessive bleeding, or tendon/ligament injury.

Discussion

Quadricepsplasty, particularly Judet's and Thompson's techniques, is frequently employed to manage severe knee extension contractures, debilitating sequelae of post-traumatic arthrofibrosis or prolonged immobilisation following complex periarticular fractures, surgeries, or external fixation. Judet⁵ and Nicoll⁸ highlighted key anatomical factors limiting knee flexion, including adhesions between the patella and femoral condyles, fibrosis of the lateral expansions of the vastus muscles, and shortening of the rectus femoris. These adhesions, along with vastus intermedius fibrosis, contribute to knee stiffness. Additionally, the deep skin adhesions on the distal thigh exacerbate this condition.

These anatomical and physiological abnormalities restrict knee flexion, severely impairing normal gait mechanics, causing a limp, and hindering functional activities of daily living (ADLs). In particular, flexion less than 70 degrees significantly hampers locomotion.¹ The Thompson procedure⁴, originally designed to liberate the rectus femoris from its tethering to the vasti, carried a significant risk of extensor lag due to quadriceps weakness. Whereas Judet's method⁵ entails the sequential release of the intrinsic (musculotendinous) and extrinsic (capsular and retinacular) structures in a stepwise manner, thereby affording surgeons the ability to terminate the procedure once adequate flexion is achieved, thus minimising the risk of iatrogenic extensor lag or rupture. Judet's technique preserves the integrity of the quadriceps extensor mechanism, reducing the incidence of postoperative extensor lag to less than 5%.⁵ Furthermore, meticulous intraoperative dissection, particularly the extraperiosteal excision of the vastus intermedius and rectus femoris release from the underlying femur, remains critical for achieving optimal knee flexion without necessitating tendon lengthening. The surgical management may be further complicated by the presence of fracture callus or scar tissue adhering skin to the underlying muscle, particularly in patients with a history of open fractures or prior external fixation. Judet et al.⁵ reported favourable outcomes in over 85% of cases, corroborated by subsequent studies like Daoud et al.,⁹ which documented an average postoperative flexion of 115 degrees. Nicoll⁸, in contrast, reported more variable outcomes, with only one-third of patients achieving satisfactory results, reflecting the variability in patient selection and adherence to rehabilitation protocols. Other reports, such as those by Sprague et al.¹⁰ and Wang et al.,¹¹ highlight the success of arthroscopic release techniques in selected cases of arthrofibrosis, though these less invasive methods are typically reserved for patients with less severe contractures. It is imperative to address both intra-articular and extra-articular adhesions, as joint adhesions

are universally observed in these cases.¹² Modified minimal invasive techniques were developed to prevent the extensiveness of these procedures. The combination of arthroscopic arthrolysis and modified minimal invasive procedures provided the best chance for good outcomes.¹³ The outcomes of the present study were consistent with these described mechanisms, as significant improvements were demonstrated across extension lag, flexion arc, KSS, and VAS scores following quadricepsplasty.

Khakharia et al.¹⁴ studied limited quadricepsplasty in 16 patients with femoral lengthening complications. The final mean flexion was 125° in the patients with a mean age of 23 years, though one case resulted in extensor lag, and the procedure was not recommended for chronic knee stiffness.

Wang et al.¹¹ developed a mini-incision technique for arthrofibrosis treatment in 22 patients with a mean age of 37 years. A mean flexion gain of 88° was achieved, but quadriceps tendon lengthening caused extension lag in all 16 cases, which resolved in 15 within 3-6 months.

Hahn et al.¹⁵ reported on a modified Thompson quadricepsplasty in 20 patients (mean age 37), showing a 67.6° mean ROM improvement. In four cases, a Z-plasty of the rectus femoris was performed, resulting in two extension lag cases. Kundu et al.¹⁶ depicted a successful increase in the range of knee flexion in 22 male patients with posttraumatic knee stiffness following distal femoral fracture underwent Thompsons quadricepsplasty. Twenty patients had excellent to good results, one patient had a perioperative patella fracture, and another had perioperative avulsion of the tibial tuberosity. In our series, the average preoperative extension lag of 15° improved to 3°, while flexion increased from 50° to 115°, representing substantial gains in ROM similar to those previously reported in the literature as described. These improvements, supported by statistically significant p-values and narrow confidence intervals, reaffirm the procedure's capacity to restore functional knee range in patients with long-standing stiffness.

Cerqueira et al.¹ described a minimally invasive quadricepsplasty technique involving the release of the adhesions, vastus muscles and patellofemoral compartment, providing good results. Similarly, the technique by Zhao J.¹⁷ used a minimally invasive quadricepsplasty technique for severe flexion impeding knee stiffness. This comprised of releases of the vastus lateralis, retinaculum and patellofemoral joint. The rectus femoris was dissociated from the patella along with proximal dissociation of vastus intermedius and overlapping Z-plasty of rectus femoris and vastus intermedius.

Postoperatively, early initiation of continuous passive motion (CPM) and rigorous active quadriceps exercises are

paramount in maintaining intraoperative gains in knee flexion, preventing reformation of adhesions, and countering postoperative quadriceps inhibition due to pain and swelling.¹⁸ The extent of knee flexion achieved intraoperatively may not always be sustained postoperatively, necessitating aggressive rehabilitation protocols and, in some cases, early postoperative manipulation under anaesthesia to maintain the gains. Superficial surgical site infections, hematoma formation, deep infection due to external fixator pins and wound dehiscence remain among the most frequently reported issues, often exacerbated by early initiation of physiotherapy before complete wound healing. Similar complications were encountered in our study, like wound dehiscence and knee swelling. Furthermore, serious complications such as quadriceps tendon rupture, skin necrosis, and even arterial embolisation requiring amputation have been documented, but are rare. The risk of re-contraction also remains a concern, with reports of patients requiring manipulation under anaesthesia or even reoperation due to recurrence of stiffness. The need for a multidisciplinary team approach, patient education, preoperative conditioning, and a rigorous, well-supervised rehabilitation regimen cannot be overstated in achieving favourable outcomes. Given the infrequency of the minimal invasive procedure and the complexity of cases requiring quadricepsplasty, the outcomes reported in the literature, while promising, must be interpreted in the context of small sample sizes and heterogeneous study populations.

Limitations

This study was limited by its small sample size and retrospective study design, which restricts the power and generalisability of the findings. The absence of a control group and the lack of long-term (>2 years) follow-up reduced the ability to assess sustained outcomes or late complications such as recurrence of stiffness. Radiological correlates and objective muscle strength testing were not included, which could have provided deeper insight into postoperative recovery and functional muscle restoration.

Future Prospects

Future studies should explore larger cohorts with multicentric participation to improve external validity. Incorporating objective functional assessments, such as isokinetic quadriceps strength testing, gait analysis, and MRI-based evaluation of muscle quality, may further elucidate recovery patterns. Comparative studies assessing Judet's technique versus minimally invasive or arthroscopic adhesiolysis may help optimize patient selection. Additionally, research into enhanced rehabilitation protocols, including neuromuscular re-education and early-motion strategies, may yield further gains in postoperative mobility and patient satisfaction.

Conclusion

This combined technique of arthroscopic arthrolysis and minimal invasive quadricepsplasty was a successful and safe surgical procedure. Patients with stiff knees, especially post-surgery, should be offered this procedure to provide functional knee movements. This technique was minimally damaging to the soft tissues in and around the knees, considering the arthroscopic visualisation of the intra-articular ligaments, cartilage and meniscus. This procedure was reproducible with similar ease and success in different etiologies of the stiff knee.

Acknowledgement

N/A

Authors Contribution: Authors who conceived and designed the analysis: Bushu Harna and Dinesh Sandal, Authors who collected the data: Shivali Arya and Dinesh Sandal, Authors who contributed data or analysis tools: Shivali Arya and Dinesh Sandal, Authors who performed the analysis: Bushu Harna, Authors who wrote the paper: Bushu Harna and Dinesh Sandal

Declaration of Conflict of Interest: The author(s) do NOT have any potential conflicts of interest for this manuscript.

Declaration of Funding: The author(s) received NO financial support for the preparation, research, authorship, and publication of this manuscript.

Declaration of Ethical Approval for Study: Ethical approval taken. IRB/Indus/05/24 on 16 Jan 2024

Declaration of Informed Consent: No information regarding patient identity in the manuscript.

Bushu Harna MS Orthopaedics ¹
Shivali Arya MD Radiodiagnosis ²
Dinesh Sandal MS Orthopaedics ³

1 Aero homes, Zirakpur, Punjab, India
2 Lifetree clinic, Zirakpur, Panjab, India
3 Neelam Hospital, Rajpura, Panjab, India

References

- dos Santos Cerqueira F, Motta GA, de Faria JL, da Motta DP, dos Santos Cerqueira F, Adolphson F. Minimally invasive quadricepsplasty. *Arthrosc Tech.* 2019;8(3):e343-7. doi: 10.1016/j.eats.2018.11.005.
- Magit D, Wolff A, Sutton K, Medvecky MJ. Arthrofibrosis of the knee. *J Am Acad Orthop Surg.* 2007;15(11):682-94. doi: 10.5435/00124635-200711000-00007.
- Egel KA, Tejwani NC, Capla EL, Wolinsky PL, Koval KJ. Staged management of high-energy proximal tibial fractures (OTA types 41): results of a prospective, standardised protocol. *J Orthop Trauma.* 2005;19(7):448-55. doi: 10.1097/01.bot.0000171881.11205.80.
- Thompson TC. Quadricepsplasty to improve knee function. *J Bone Joint Surg Am.* 1944;26(2):366-79. doi:10.2106/JBJS.26.2.366.
- Judet R. Mobilization of the stiff knee. *J Bone Joint Surg Br.* 1959;41(4):856-7. doi:10.1302/0301-620X.41B4.856.
- Hosalkar HS, Jones S, Chowdhury M, Hartley J, Hill RA. Quadricepsplasty for knee stiffness after femoral lengthening in congenital short femur. *J Bone Joint Surg Br.* 2003;85(2):261-6. doi: 10.1302/0301-620X.85B2.13144.
- Sulaiman S. Excellent outcome with modified thompson quadricepsplasty for knee extension contracture: Case report and review of the literature. *Journal of Musculoskeletal Surgery and Research.* 2021;5:67-74. doi:10.4103/jmsr.jmsr_84_20.
- Nicoll EA. Quadricepsplasty. *J Bone Joint Surg Br.* 1963;45(3):483-90. doi:10.1302/0301-620X.45B3.483.
- Daoud H, O'Farrell T, Cruess RL. Quadricepsplasty: the Judet technique and results of six cases. *J Bone Joint Surg Br.* 1982;64(2):194-7. doi: 10.1302/0301-620X.64B2.7068739.
- Sprague NF 3rd, O'Connor RL, Fox JM. Arthroscopic treatment of postoperative knee fibroarthrosis. *Clin Orthop Relat Res.* 1982;(166):165-72. doi:10.1097/00003086-198208000-00021.
- Wang JH, Zhao JZ, He YH. A new treatment strategy for severe arthrofibrosis of the knee. *Surgical technique. J Bone Joint Surg Am.* 2007;89 Suppl 2 Pt 1:93-102. doi: 10.2106/JBJS.F.00963.12. Luo Y, Li H, Mei L, Mao X. Effects of Judet quadricepsplasty in the treatment of post-traumatic extension contracture of the knee. *Orthop Surg.* 2021;13(4):1284-9. doi: 10.1111/os.12950.
- Kukreja M, Kang J, Curry EJ, Li X. Arthroscopic lysis of adhesions and anterior interval release with manipulation under anesthesia for severe post-traumatic knee stiffness: a simple and reproducible step-by-step guide. *Arthrosc Tech.* 2019;8(5):e429-35. doi: 10.1016/j.eats.2019.01.005.
- Khakharia S, Fragomen AT, Rozbruch SR. Limited quadricepsplasty for contracture during femoral lengthening. *Clin Orthop Relat Res.* 2009;467(11):2911-7. doi: 10.1007/s11999-009-0951-2.
- Hahn SB, Lee WS, Han DY. A modified Thompson quadricepsplasty for stiff knee. *J Bone Joint Surg Br.* 2000;82(7):992-5. doi:10.1302/0301-620X.82B7.11062.
- Kundu ZS, Sangwan SS, Guliani G, Siwach RC, Kamboj P, Singh R. Thompson's quadricepsplasty for stiff knee. *Indian J Orthop.* 2007;41(4):390-4. doi: 10.4103/0019-5413.37004.
- Zhao J. Mini-invasive quadricepsplasty for severe flexion-impeding knee stiffness. *Arthrosc Tech.* 2022;11(4):e645-53. doi: 10.1016/j.eats.2021.12.021.
- Pujol N, Boisrenoult P, Beaufils P. Post-traumatic knee stiffness: surgical techniques. *Orthop Traumatol Surg Res.* 2015;101(1 Suppl):S179-86. doi: 10.1016/j.otsr.2014.06.026. Epub 2015 Jan 9.