

## RESEARCH ARTICLE

# Coracoacromial Ligament Release Improves Internal Rotation in Reverse Total Shoulder Arthroplasty; a Cadaver Study

Feras Qawasmi, MD; Abrar Abuhamdia, MSc; Logan M. Andryk, MD; Steven Grindel, MD; Mustafa Yassin, MD

Research performed at Medical College of Wisconsin, WI, USA

Received: 1 December 2024

Accepted: 7 January 2025

## Abstract

**Objectives:** Evaluate the effect of Coracoacromial Ligament (CAL) release after Reverse shoulder arthroplasty (RSA) on range of motion (ROM), particularly on internal rotation (IR).

**Methods:** Ten Fresh Frozen cadavers underwent RSA followed by CAL release by a fellowship-trained surgeon. Shoulder ROM was measured by a goniometer pre- and post-CAL release. The IR to the back was measured as the distance between the posterior-lateral acromion and the highest point of thumb elevation behind the back. Measurements of ROM before and after CAL release were compared using a paired sample t-test.

**Results:** CAL release after RSA significantly increased ROM in all planes. The IR to the back improved by an average of four cm. Internal rotation in abduction, external rotation in abduction, external rotation at the side, forward elevation, abduction, and extension increased by 7°, 8°, 9°, 10°, 6°, 11°, respectively.

**Conclusion:** The CAL release following RSA significantly improved IR to the back and all other ROM. CAL release post-RSA could be a potential solution to the ROM deficits, particularly IR, post-RSA. Clinical studies are needed to assess the clinical application of this technique.

**Level of evidence:** IV

**Keywords:** Coracoacromial ligament, Internal rotation, Range of motion, Reverse total shoulder arthroplasty

## Introduction

Reverse shoulder arthroplasty (RSA) is widely used as a treatment for various shoulder conditions, including rotator cuff arthropathy, proximal humerus fractures, and advanced glenohumeral arthritis with significant glenoid deformity. Over recent years, the frequency of RSA procedures has dramatically increased, with one nationwide study reporting a 4,500% rise in such surgeries between 2004 and 2015, with further growth anticipated.<sup>1</sup> While RSA has been effective in enhancing patient-reported outcomes and alleviating pain, it is not without challenges. Complications such as infections, nerve injuries, component loosening, and modular stem-polyethylene dissociations have been reported. Modifications in implant design, surgical techniques, and

prosthetic advancements have helped reduce complications such as scapular notching. However, despite improvements in the range of motion (ROM), limitations persist, particularly in internal rotation (IR) to the back.<sup>2-5</sup>

Several factors contribute to limited shoulder rotation following RSA. These include the inherent constraints of the implant, surgical decisions such as subscapularis repair and implant positioning, and prosthetic characteristics like lateralization, glenosphere size, and humeral neck-shaft angle.<sup>6</sup> Efforts to address these limitations include tendon transfers (e.g., latissimus dorsi and teres major), which have been shown to improve external rotation and forward elevation but have had limited or even negative effects on IR.<sup>3,4</sup> Other strategies, such as modifying humeral neck-shaft

**Corresponding Author:** Feras Qawasmi, Medical College of Wisconsin, Department of Orthopaedic Surgery, Milwaukee, WI, USA

**Email:** ferasport@yahoo.com



THE ONLINE VERSION OF THIS ARTICLE  
ABJS.MUMS.AC.IR



angles, lateralizing the glenoid, increasing glenosphere diameter, reducing humeral retroversion, and repairing the subscapularis, have produced inconsistent results and, in some cases, improved IR at the expense of external rotation.<sup>6,7</sup>

A prior study by Qawasmi et al. demonstrated that lengthening the conjoint tendon improved IR and shoulder ROM following RSA in cadaveric models. However, the role of coracoacromial ligament (CAL) release in addressing these deficits has not been evaluated.<sup>8</sup>

The coracoacromial ligament, which stabilizes the shoulder girdle by connecting the lateral coracoid process to the underside of the acromion, plays a role in preventing superior migration of the humeral head. While CAL resection is commonly performed during procedures such as RSA, subacromial decompression, and tendon transfers, its necessity remains a topic of debate. Limited literature exists on the impact of CAL release on ROM, particularly on IR.

This study aims to investigate the effects of CAL release on shoulder ROM after RSA, with a primary focus on IR to the back and secondary measures, including other shoulder motions such as internal rotation in abduction, external rotation at the side and in abduction, forward elevation, abduction, and extension. We hypothesize that CAL release following RSA will enhance IR to the back.

## Materials and Methods

### Specimens

Ten fresh-frozen upper extremities from cadavers were utilized for this study. The specimens included the bony structure and the associated musculature. The samples were thawed at room temperature for 24 hours prior to shoulder implantation. All specimens exhibited normal shoulder anatomy without any prior injuries or previous implant

surgeries.

As this is a cadaveric study, institutional review board approval was deemed unnecessary. The study adhered to ethical guidelines outlined in the 1964 Declaration of Helsinki.

### Procedure

Each scapula was securely mounted to a custom-designed metal holder. Reverse total shoulder arthroplasty (RSA) was performed on all specimens by a single orthopedic surgeon using a standard deltopectoral approach. The procedure involved the implantation of a baseplate (Aequalis, Tornier, Stryker, Wisconsin, USA), a standard-size 36 mm glenosphere, and a press-fit onlay humeral stem with a 145° neck-shaft angle. The subscapularis tendon was not sutured after the prosthetic implantation in any specimen.

The same surgeon manually moved the arm to its maximum ROM in all directions, both before and after the coracoacromial ligament (CAL) release. Two additional surgeons observed the measurements, ensuring inter-observer agreement.

ROM was assessed with a goniometer, except for internal rotation (IR) to the back. For IR to the back, the distance between the tip of the posterior-lateral acromion and the tip of the thumb in full IR was recorded. After completing the RSA procedure, the CAL was identified and released from the lateral aspect of the coracoid. ROM measurements were then repeated and documented post-CAL release [Figure 1, 2].

The data consisted of continuous variables, represented as mean  $\pm$  standard deviation. Pre- and post-CAL release ROM measurements were compared using paired t-tests to assess significant improvements in motion across all planes. A p-value of  $\leq 0.05$  was considered statistically significant. All analyses were performed using Microsoft Excel (Microsoft, Redmond, WA, USA).

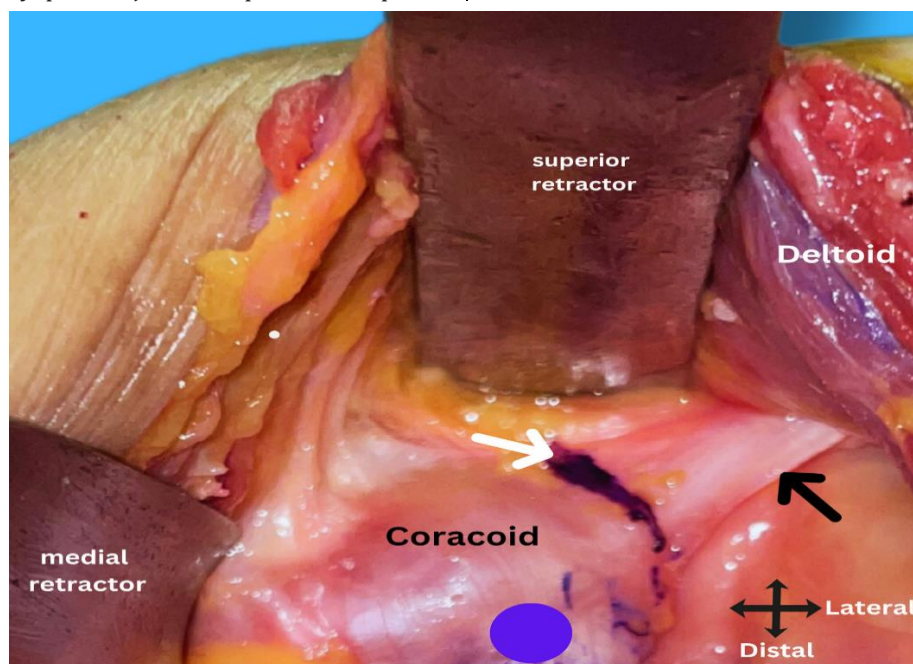


Figure 1. This figure shows the coracoacromial ligament pre-cut. The white arrow shows the marked area to be cut, the black arrow shows the CAL and the blue circle indicates the conjoint tendon

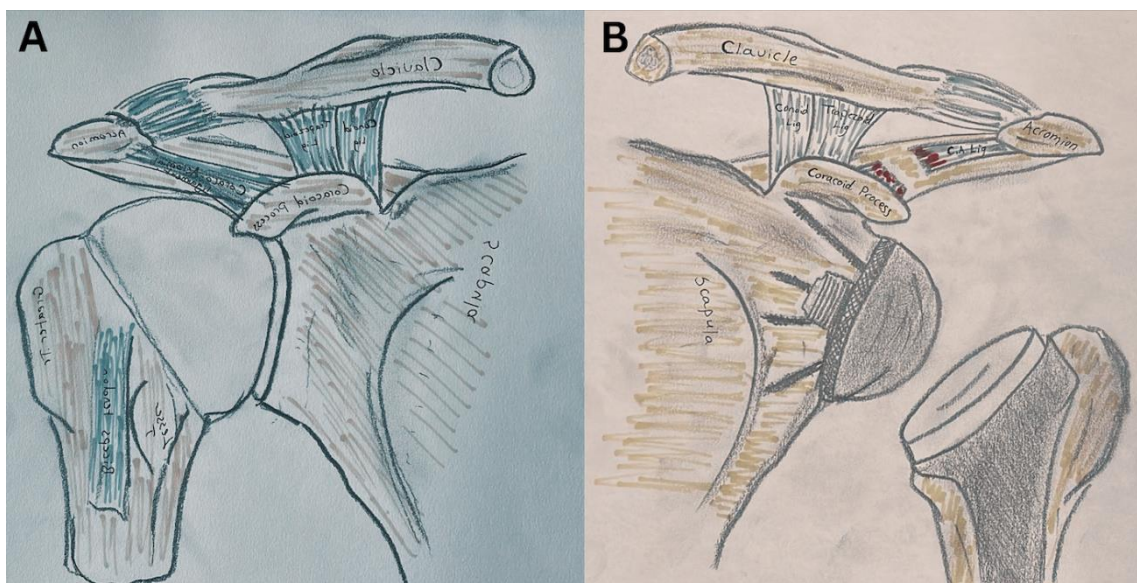


Figure 2. (A) Depicts the shoulder prior to shoulder arthroplasty, showing ligaments anatomy. (B) Illustrates the shoulder after reverse arthroplasty, highlighting the coracoacromial ligament (CAL) release site

## Results

Ten fresh-frozen cadaveric specimens (five males) with an average age of  $65.8 \pm 5.9$  years were included in this study. Changes in glenohumeral joint range of motion (ROM), including internal rotation (IR) to the back, internal rotation in abduction, external rotation at the side, external rotation in abduction, forward elevation, abduction, and extension, were measured before and after CAL release. These results are summarized in [Table 1].

Significant improvements in internal rotation and all other measured ROM parameters were observed following CAL release.

**Internal Rotation to the Back:** The average distance between the posterior-lateral acromion and the thumb decreased from 46 cm to 42 cm, indicating an average gain of 4 cm ( $p \leq 0.001$ ).

**Internal Rotation in Abduction:** Improved from  $54^\circ$  to  $61^\circ$ , with an average increase of  $7^\circ$  ( $p = 0.007$ ).

**External Rotation at the Side:** Increased from  $80^\circ$  to  $89^\circ$ , reflecting an average gain of  $9^\circ$  ( $p = 0.007$ ).

**External Rotation in Abduction:** Improved from  $90^\circ$  to  $98^\circ$ , with an average gain of  $8^\circ$  ( $p = 0.011$ ).

**Forward Elevation:** Increased by an average of  $10^\circ$  post-CAL release, from  $95^\circ$  to  $105^\circ$  ( $p = 0.009$ ).

**Abduction:** Improved by  $6^\circ$ , increasing from  $91^\circ$  to  $96^\circ$  ( $p = 0.007$ ).

**Extension:** Showed the greatest gain, increasing by  $11^\circ$ , from  $28^\circ$  to  $39^\circ$  ( $p = 0.005$ ).

Overall, these findings demonstrate that CAL release significantly enhanced shoulder range of motion in all tested directions, with internal rotation to the back showing marked improvement.

Table 1. The mean measurements of the range of motion (ROM) and overall motion improvements after the CAL release

Variables	Pre-CA Release	Post-CA Release	Improvement	P value
IR to Back**	$46 \pm 8$ cm	$42 \pm 10$ cm	4 cm	0.0001
IR Abducted**	$54^\circ \pm 25$	$61^\circ \pm 25$	$7^\circ$	0.007
ER at Side**	$80^\circ \pm 8$	$89^\circ \pm 13$	$9^\circ$	0.007
ER Abducted**	$90^\circ \pm 9$	$98^\circ \pm 21$	$8^\circ$	0.011
Flexion**	$95^\circ \pm 33$	$105^\circ \pm 44$	$10^\circ$	0.009
Abduction**	$91^\circ \pm 31$	$96^\circ \pm 39$	$6^\circ$	0.007
Extension**	$28^\circ \pm 7$	$39^\circ \pm 10$	$11^\circ$	0.005

Internal rotation to the back is in centimeters, while other measurements are in degrees.

IR: internal rotation

ER: external rotation

\*\* Indicates P value  $\leq 0.01$

## Discussion

This study evaluated the effect of coracoacromial ligament (CAL) release on shoulder range of motion (ROM) following reverse shoulder arthroplasty (RSA) using cadaveric specimens. The results demonstrated that CAL release significantly enhanced all measured ROM, including internal rotation (IR) to the back, which improved by an average of 4 cm. These findings support the hypothesis that CAL release following RSA improves shoulder mobility, particularly IR.

Several techniques have been explored to optimize RSA outcomes, especially with regard to improving shoulder ROM. While improvements in forward elevation and external rotation (ER) have been widely reported, internal rotation remains challenging, often showing limited or inconsistent gains.<sup>3,4,6,7</sup> Survey-based studies assessing activities of daily living (ADLs) after RSA revealed some improvement in tasks requiring IR, such as managing toileting or reaching a back pocket. However, more complex activities like washing the back or fastening a bra showed minimal improvement.<sup>9</sup> Our study's findings highlight the potential role of CAL release in addressing these deficits, with significant gains observed in IR to the back, IR in abduction, ER at the side, ER in abduction, forward elevation, abduction, and extension.

The CAL is a key component of the coracoacromial arch, which provides superior stability to the glenohumeral joint.<sup>5</sup> Impingement of soft tissues or bony structures under this arch has been linked to complications such as dislocation and mechanical failure after RSA.<sup>10</sup> Release is a commonly performed procedure during subacromial decompression, aimed at increasing subacromial space and reducing impingement.<sup>11</sup> However, its role during RSA has not been clearly established, and there is no consensus on whether it should routinely be released during the procedure.

Releasing the CAL may theoretically increase subacromial space, reduce impingement risk, and improve ROM, particularly in movements involving the rotator cuff tendons, such as IR and ER. Literature suggests that factors such as glenosphere size, lateralization, humeral neck-shaft angle, and subscapularis repair can influence shoulder mobility.<sup>6,7</sup> For example, Gruber et al. proposed that a reduced neck-shaft angle could improve IR by decreasing impingement in adduction. However, most of the studies included in their review were computational, lacking clinical or cadaveric validation.<sup>6</sup> Similarly, increasing glenosphere size has been reported to reduce bone impingement but may also increase soft tissue tension, potentially constraining ROM.<sup>12-15</sup> Our study provides direct cadaveric evidence that CAL release positively impacts IR and other shoulder motions following RSA.

Internal rotation to the back is a complex motion requiring a combination of glenohumeral abduction, extension, internal rotation, scapulothoracic retraction, and anterior tilt.<sup>16</sup> Previous studies emphasized the importance of shoulder extension in functional IR, as at least 40° of extension is necessary for tasks such as reaching behind the back.<sup>16</sup> In our study, shoulder extension improved significantly following CAL release, which likely contributed

to the observed gains in IR.

Soft tissue tensioning, in general, and CAL, in particular, probably explains why the literature has mixed results about glenosphere size and internal rotation. Increasing the glenosphere size would decrease humeral and glenoid impingement. However, distalization central of rotation increases soft tissue tension, which may potentially limit shoulder motion. Furthermore, the ability to increase glenosphere diameter is often limited by patient anatomy, overstuffing is a consideration, and a larger size may be detrimental due to an increased risk of anterior coracoid impingement.<sup>12-15</sup>

Budge et al.<sup>17</sup> demonstrated that increasing the retroversion of the baseplate reduces internal rotation (IR) and increases external rotation (ER). Conversely, Keener et al.<sup>18</sup> found that greater retroversion of the glenoid is associated with decreased external rotation but increased internal rotation and flexion. The discrepancies between these studies may be because soft tissue tensions were not considered in either study. The literature presents mixed results regarding the impact of subscapularis repair on internal rotation following reverse shoulder arthroplasty. Friedman et al.<sup>19</sup> reported significant improvements in internal rotation after subscapularis repair. Conversely, Vourazeris et al.<sup>20</sup> found no significant difference in internal rotation between patients with subscapularis repair and those who underwent reverse shoulder arthroplasty without subscapularis repair.

A cadaveric study found that CAL release significantly increased strain at the acromion but not at the scapular spine.<sup>16</sup> The effect of CAL release on the shoulder motion. Overall, the research on the relationship between CAL release and the integrity of the acromion, scapular spine, and shoulder motion is limited. Further research is needed to better understand this effect.

While this study provides new insights, it has several limitations. The reliance on a cadaveric model excludes biological factors such as soft tissue healing, muscle activation, and scarring, which could affect ROM in living patients. Furthermore, the sample size of ten specimens may not capture the full variability of shoulder biomechanics across different populations. The use of a single implant design and surgical technique may also limit the generalizability of the findings.

Future studies should evaluate the clinical significance of CAL release in live patients, including its long-term effects on shoulder function, ROM, and potential strain on the acromion and scapular spine. Additionally, studies involving varying implant designs, surgical approaches, and larger sample sizes would help further validate these findings.

## Conclusion

This study highlights the potential benefits of coracoacromial ligament (CAL) release in improving shoulder range of motion (ROM) following reverse shoulder arthroplasty (RSA). Significant improvements were observed in internal rotation (IR) to the back and other ROM parameters, including external rotation,

forward elevation, abduction, and extension. These findings suggest that CAL release may serve as an effective technique to address ROM deficits, particularly IR, after RSA.

However, further clinical research is necessary to validate these findings in live patients and to assess the long-term implications of CAL release on shoulder function, acromion and scapular spine strain, and overall surgical outcomes.

### Acknowledgement

We would like to express our appreciation to Dr. Fadi Shweiki for contributing the medical illustration featured in this manuscript.

**Authors Contribution:** Authors who conceived and designed the analysis: FQ, SG, MY/ Authors who collected the data: FQ, LA, SG, MY/Authors who contributed data or analysis tools: SG, MY/ Authors who performed the analysis: MY/ Authors who wrote the paper: AA, FQ

**Declaration of Conflict of Interest:** The authors do NOT have any potential conflicts of interest for this manuscript.

**Declaration of Funding:** The authors received NO financial

support for the preparation, research, authorship, and publication of this manuscript.

**Declaration of Ethical Approval for Study:** Ethical approval was not sought for the present study because this study was a case series of cadavers and the institutional board review has deemed that the ethical approval is not required. This study was completed in accordance with the Helsinki Declaration as revised in 2013.

**Declaration of Informed Consent:** This study does not include identifiable information.

Feras Qawasmi MD <sup>1</sup>

Abrar Abuhamdia MSc <sup>2</sup>

Logan M. Andryk MD <sup>1</sup>

Steven Grindel MD <sup>1</sup>

Mustafa Yassin MD <sup>1</sup>

1 Medical College of Wisconsin, Department of Orthopaedic Surgery, Milwaukee, WI, USA

2 Division of Genomics and Precision Medicine, College of Health and Life Sciences, Hamad Bin Khalifa University, Doha, Qatar

### References

1. Harjula JNE, Paloneva J, Haapakoski J, et al. Increasing incidence of primary shoulder arthroplasty in Finland - A nationwide registry study. *BMC Musculoskelet Disord*. 2018; 19(1). doi:10.1186/s12891-018-2150-3.
2. Rojas J, Joseph J, Srikumaran U, McFarland EG. How internal rotation is measured in reverse total shoulder arthroplasty: a systematic review of the literature. *JSES Int*. 2020; 4(1). doi:10.1016/j.jses.2019.10.109.
3. Boileau P, Chuinard C, Roussanne Y, Bicknell RT, Rochet N, Trojani C. Reverse shoulder arthroplasty combined with a modified latissimus dorsi and teres major tendon transfer for shoulder pseudoparalysis associated with dropping arm. *Clin Orthop Relat Res*. 2008; 466(3):584-93. doi:10.1007/s11999-008-0114-x.
4. Boughebi O, Kilinc A, Valenti P. Reverse shoulder arthroplasty combined with a latissimus dorsi and teres major transfer for a deficit of both active elevation and external rotation. Results of 15 cases with a minimum of 2-year follow-up. *Orthop Traumatol Surg Res*. 2013; 99(2):131-137. doi:10.1016/j.otsr.2012.11.014.
5. Elzanie A, Varacallo M, eds. *Anatomy, Shoulder and Upper Limb, Deltoid Muscle*. 1st ed. In: StatPearls [Internet]. Treasure Island (FL): StatPearls Publishing; 2025.
6. Gruber MD, Kirloskar KM, Werner BC, Lädermann A, Denard PJ. Factors Associated with Internal Rotation After Reverse Shoulder Arthroplasty: A Narrative Review. *JSES Rev Rep Tech*. 2022; 2(2):117-124. doi:10.1016/j.xrrt.2021.12.007.
7. Franceschi F, Giovannetti de Sanctis E, Gupta A, Athwal GS, Di Giacomo G. Reverse shoulder arthroplasty: State-of-the-art. *J ISAKOS*. 2023; 8(5):306-317. doi:10.1016/j.jisako.2023.05.007.
8. Qawasmi F, Andryk LM, Roge S, Wang M, Yassin M, Grindel SI. Conjoint tendon lengthening improves internal rotation following reverse total shoulder arthroplasty: a cadaveric study. *J Shoulder Elbow Surg*. 2024; 33(10):2230-2235. doi:10.1016/j.jse.2024.03.023.
9. Assenmacher AT, Alentorn-Geli E, Aronowitz J, et al. Patient-reported activities after bilateral reverse total shoulder arthroplasties. *J Orthop Surg (Hong Kong)*. 2019; 27(1):2309499018816771. doi:10.1177/2309499018816771.
10. Barco R, Savvidou OD, Sperling JW, Sanchez-Sotelo J, Cofield RH. Complications in reverse shoulder arthroplasty. *EFORT Open Rev*. 2016; 1(3):72-80. doi:10.1302/2058-5241.1.160003.
11. Baek, MD CH, Kim, MD JG, Lee, MD DH, Baek GR. Does Preservation of Coracoacromial Ligament Reduce the Acromial Stress Pathology Following Reverse Total Shoulder Arthroplasty? *J Shoulder Elb Arthroplast*. 2021; 5:247154922110221. doi:10.1177/24715492211022171.
12. Berhouet J, Garaud P, Favard L. Influence of glenoid component design and humeral component retroversion on internal and external rotation in reverse shoulder arthroplasty: A cadaver study. *Orthop Traumatol Surg Res*. 2013; 99(8):887-894. doi:10.1016/j.otsr.2013.08.008.
13. Langohr GDG, Giles JW, Athwal GS, Johnson JA. The effect of glenosphere diameter in reverse shoulder arthroplasty on muscle force, joint load, and range of motion. *J Shoulder Elbow Surg*. 2015; 24(6):972-979. doi:10.1016/j.jse.2014.10.018.
14. Werner BS, Chaoui J, Walch G. Glenosphere design affects

- range of movement and risk of friction-type scapular impingement in reverse shoulder arthroplasty. *Bone Joint J.* 2018; 100B (9). doi:10.1302/0301-620X.100B9.BJJ-2018-0264.R1.
15. Haislup BD, Ashmyan R, Johnston PS, Wright MA, Abbasi P, Murthi AM. Effect of glenosphere lateralization with and without coracoacromial ligament transection on acromial and scapular spine strain in reverse shoulder arthroplasty. *JSES Int.* 2022; 6(6):884-888. doi:10.1016/j.jseint.2022.08.010.
  16. Hochreiter B, Wyss S, Gerber C. Extension of the shoulder is essential for functional internal rotation after reverse total shoulder arthroplasty. *J Shoulder Elbow Surg.* 2022; 31(6):1166-1174. doi:10.1016/j.jse.2021.11.006.
  17. Budge M, Lewis G, Vannname J. The effect of glenoid version on internal and external rotation in reverse total shoulder arthroplasty. *Seminars in Arthroplasty: JSES.* 2021; 31(3):502-509. doi:https://doi.org/10.1053/j.sart.2021.02.005.
  18. Keener JD, Patterson BM, Orvets N, Aleem AW, Chamberlain AM. Optimizing reverse shoulder arthroplasty component position in the setting of advanced arthritis with posterior glenoid erosion: a computer-enhanced range of motion analysis. *J Shoulder Elbow Surg.* 2018; 27(2):339-349. doi:10.1016/j.jse.2017.09.011.
  19. Friedman RJ, Flurin PH, Wright TW, Zuckerman JD, Roche CP. Comparison of reverse total shoulder arthroplasty outcomes with and without subscapularis repair. *J Shoulder Elbow Surg.* 2017; 26(4). doi:10.1016/j.jse.2016.09.027.
  20. Vourazeris JD, Wright TW, Struk AM, King JJ, Farmer KW. Primary reverse total shoulder arthroplasty outcomes in patients with subscapularis repair versus tenotomy. *J Shoulder Elbow Surg.* 2017; 26(3). doi:10.1016/j.jse.2016.09.017.