

## RESEARCH ARTICLE

# A Novel Mini External Fixation Technique versus Percutaneous Pinning in the Treatment of Phalanx Fracture in Hand

Parviz Ahangar, MD; Mostafa Shahrezaee, MD; Reza Shahryar Kamrani, MD; Shamim Fattah Hesari, MD; Seyed Shahabeddin Banihashemian, MD; Soosan Alimohammadzadeh Taher, MD

Research performed at Imam Reza Hospital, Aja University of Medical Sciences, Tehran, Iran

Received: 28 October 2023

Accepted: 7 October 2024

## Abstract

**Objectives:** Hand fracture is one of the most common fractures in the skeletal system. The present study aimed to introduce a newly designed external fixator and assess the results of treatment of patients with unstable and complex fractures of the proximal and middle phalanges of the fingers with two treatment methods: "fixation with percutaneous pins (PCP) + splint" and "fixation with mini external fixator."

**Methods:** In this prospective cohort study, patients with acute unstable and complex fractures of the proximal and middle phalanges of the second to fifth fingers were treated with two treatment methods, including "fixation with PCP + splint" and "the use of mini external fixator." At the final follow-up visit, union, pain, function, finger range of motion (ROM), and possible complications were considered.

**Results:** Among 52 patients included in the study, 33 cases were treated with a mini external fixator, and 19 patients underwent fixation with PCP and splint. All patients in both groups had a union, and none of them complained of pain during the final visit. Functional outcomes were good, and there was no statistically significant difference between the two groups. The mini external fixator group had a significantly greater finger ROM ( $P=0.012$ ), with a lower number of physiotherapy sessions ( $P=0.018$ ). Moreover, patients returned to work more promptly ( $P=0.012$ ).

**Conclusion:** The treatment of unstable finger fractures with a mini external fixator had three advantages: the possibility of early initiation of finger movement and improvement of finger ROM, the need for fewer physical therapy sessions, and early return to work. It can be an effective treatment option for unstable and complex finger fractures.

**Level of evidence:** II

**Keywords:** Finger fractures, Hand injury, Mini external fixator, Pin fixation

## Introduction

Hand fractures rank among the most common fractures in the skeletal system, with finger fractures comprising 46% of these fractures.<sup>1-3</sup> Depending on the mechanism of injury, the fracture pattern, and the stability of the fracture site, this fracture can be treated operatively or non-operatively. Non-operative treatments, such as buddy-tapping and appropriate splinting, are suitable for reducible and stable fractures.<sup>4</sup> Nonetheless, surgical treatment is required in case of shortness, rotation, and angulation of the bone, displaced and

unstable fractures, as well as intra-articular and open fractures. Non-operative treatment for these fractures may lead to such complications as joint stiffness and osteoarthritis.<sup>5</sup>

Anatomical reduction, minimizing soft tissue injury, and early initiation of finger movement are crucial in the surgical treatment of finger fractures.<sup>1,6</sup> In this regard, there are different surgical techniques. Percutaneous pin fixation (PCP) is a common minimally invasive treatment method.<sup>7</sup> The main concern about pin fixation is that it often lacks

**Corresponding Author:** Soosan Alimohammadzadeh Taher, Department of Orthopaedic and Trauma Surgery, Imam Reza Hospital, Aja University of Medical Sciences, Tehran, Iran

**Email:** drs\_taher@yahoo.com



THE ONLINE VERSION OF THIS ARTICLE  
ABJS.MUMS.AC.IR



sufficient strength to allow early initiation of joint movement, which can ultimately lead to a limitation in joint range of motion (ROM).<sup>8</sup>

The use of miniature screws and plates can create a stronger fixation. Nevertheless, it requires extensive exposure during the operation, increasing the risk of some complications, including infection, nonunion, joint stiffness, and the possibility of device removal.<sup>9,10</sup> In cases of unstable open fractures, severe soft tissue injury, or significant comminution that precludes stable internal fixation, external fixation is an effective and acceptable treatment option that preserves the integrity of the articular surface through the mechanism of capsular ligamentotaxis and allows early initiation of joint motion.<sup>6,11-14</sup> There are two categories of external fixators: commercial external fixators and those made from the tools available in the operating room, with each having its own advantages and disadvantages.<sup>12,15-22</sup>

In this study, we introduced a newly designed external fixator (mini external fixator) and then investigated the results of treatment with unstable and complex fractures of the proximal and middle phalanges of the fingers with two treatment methods: group A: fixation with PCP + splint and group B: fixation with mini external fixator.

## Materials and Methods

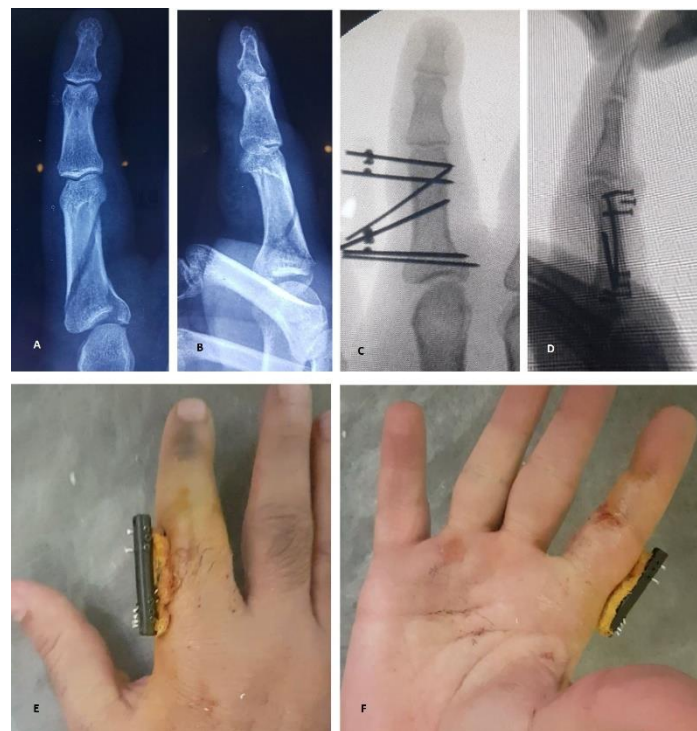### Study design

Patients with acute unstable and complex fractures of the proximal and middle phalanges of the second to fifth fingers who visited AJA 501 Hospital between November 2019 and December 2021 were included in this prospective cohort study. Complex fractures are those that have extended into the articular surface (except for PIP fracture-dislocation). Any displacement, angulation, or comminution is classified as an unstable fracture. The exclusion criteria were proximal inter-phalangeal joint fracture-dislocation, concomitant tendon and nerve injury of the finger, open fracture, and previous surgery of the involved finger. Two treatment methods, including "fixation with PCP + splint" and "using a mini external fixator," with their strengths and weaknesses, were explained to patients by the attending physician, allowing them to choose one of the treatment methods at their own discretion. Written informed consent was obtained from patients. Basic information about patients, including demographic information, type of fracture, involved finger and phalange, and the time between injury and surgery, were recorded.

### Surgical technique

After prepping and draping in sterile conditions, under local anesthesia and fluoroscopic guidance, the fracture was reduced and temporarily maintained with a reduction clamp. In the first group, the fracture was fixed by two or more 1 or 1.5 mm-diameter percutaneous K-wires. The number and direction of K-wires depend on the fracture morphology. Thereafter, a volar splint was applied from the fingertip to below the elbow. In the second group, first, a 1 or 1.5 mm-diameter K-wire was placed proximal or distal to the fracture site. To this end, we passed the K-wire through the hole of the rod and then inserted it into the bone. Depending on the fracture pattern and the degree of instability, the fixation was completed with a greater number of transverse or oblique pins perpendicular to the

fracture. We placed the rod at a distance of 5-7 mm from the surface of the skin. Following that, the pins were fixed to the rod using 1.4-mm metal screws. Finally, the pins which were fixed to the rod with screws were cut tangentially to the fixator. The pins which were not fixed to the rod with screws were cut a little longer, and the end of the pin was bent over the rod. In case of severe comminution and instability of middle phalanges, the bi-planar external fixator can be used. When the fixator was applied, the pins were wrapped with Vaseline gauze soaked in betadine, and finger movements were initiated in the operating room [Figure 1].



**Figure 1.** A and B: Anteroposterior and lateral radiographs of a proximal phalanx fracture with articular depression. C and D: Intra-operative anteroposterior and lateral fluoroscopy after the application of uni-planar mini external fixator. E: Third-week visit

After the surgery, the patients were visited by the physician at intervals of one week, three weeks, six weeks, and three months. Finally, we scheduled all patients for a final follow-up visit at the end of the study. Antero-posterior and lateral finger radiographs were taken during each visit. In the first group at the third-week visit, the splint and pins were removed without sedation, and finger movement was then started. In the second group, finger movement was initiated immediately after the surgery and was performed daily at home. In the sixth-week visit, the fixator was removed in the clinic without anesthesia, and the finger ROM was examined in both groups. If there was a limitation in finger ROM, physiotherapy was prescribed. Physiotherapy sessions continued until the full ROM of the finger was achieved or as long as the ROM of the finger did not change during a period of two months. In the final visit, pain and function were determined using the Visual Analog Scale (VAS) and Quick Disabilities of the Arm, Shoulder, and Hand score (Quick-DASH), respectively. Moreover, the total active motion

(TAM) of the finger was measured by examination and recorded as a percentage in relation to the healthy side. Finally, the condition of fracture union was considered in the anteroposterior and lateral radiographs of the finger. Complications, including nonunion, mal-union, nerve injury, pin tract infection, and limited ROM of adjacent fingers, were recorded if present. In addition, the duration from the surgery and return to work was recorded for each patient in both groups. All clinical outcomes were measured blindly.

### Statistical analysis

SPSS software (version 16.0) was used for statistical analysis. Continuous variables were presented as mean  $\pm$  standard deviation and were analyzed using the independent samples t-test. Categorical variables were reported as frequency and were analyzed using the Chi-square test. A P-value of less than 0.05 was considered to be statistically significant.

### Results

A total of 68 patients met the inclusion criteria. Among them, 12 patients were excluded from the study based on the exclusion criteria, and 4 patients were excluded due to lack of follow-up. Finally, 52 patients were included in the study, out of which 33 patients were treated with a mini external fixator, and 19 cases underwent fixation with PCP and splint. The mean follow-up period was  $26.42 \pm 11.49$  months in the

PCP group (group A) and  $26.58 \pm 12.58$  months in the mini external fixator group (group B). There was no significant difference between the two groups in terms of mean age, duration of follow-up, time interval between fracture and surgery, and gender. The summary of the basic information of the patients, including demographic information, type of fracture, involved finger, and phalange, is presented in [Table 1].

All patients in both groups had union at the sixth-week visit. In the final follow-up visit, none of the patients in either group complained of pain (VAS score=0). The Quick-DASH scores were  $3.74 \pm 6.51$  and  $1.91 \pm 3.76$  in the PCP and mini external fixator groups, respectively. There was no significant difference in Quick-DASH score between the two groups ( $P=0.204$ ). In the final visit, the ROM of the finger was significantly greater in the mini external fixator group (TAM= $0.97 \pm 0.06$ ) than in the PCP group (TAM= $0.90 \pm 0.12$ ) ( $P=0.012$ ). Furthermore, the number of physiotherapy sessions was significantly lower in the mini external fixator group ( $7.18 \pm 11.68$ ) than in the PCP group ( $15.58 \pm 12.30$ ) ( $P=0.018$ ). Finally, the time required to return to work was significantly shorter in the mini external fixator group ( $9.52 \pm 8.74$  days) than in the PCP group ( $35.89 \pm 14.21$  days) ( $P=0.001$ ).

Table 1. Basic information of the patients

Groups		Group A (Percutaneous pins+splint , n=19)	Group B (Mini external fixator, n=33)	P-value
Age (year)		$42.11 \pm 12.23$	$44.39 \pm 16.26$	0.597
Gender	Male	13	21	0.733
	Female	6	12	
Injured hand	Right	8	11	0.536
	Left	11	22	
Injured digit	2nd	2	1	0.152
	3rd	4	2	
	4th	5	14	
	5th	8	16	
Injured phalange	P1	15	27	0.805
	P2	4	6	
Fracture type	Oblique	8	13	0.710
	Spiral	1	0	
	Comminuted	10	20	
Follow-up (month)		$26.42 \pm 11.49$	$26.58 \pm 12.58$	0.965
Interval between injury and operation (day)		$4.53 \pm 1.98$	$5.15 \pm 3.56$	0.485

There were no significant complications in both groups. Only one patient in each group had a mild pin tract infection, which was resolved with conservative management. Furthermore, two patients in the mini external fixator group and one patient in the PCP group mentioned occasional mild pain during intensive activities or in cold exposure. The final functional outcomes are summarized in [Table 2].

### Discussion

Crockett introduced the technique of using pins that are connected by acrylic resin in hand surgeries in 1974.<sup>23</sup> Since then, other researchers have described various external fixators. In 1991, Sameer treated 19 metacarpal fractures and 11 finger fractures with an external fixator consisting of pins held together by methyl methacrylate cement, and finger movement started one week after the surgery.<sup>21</sup> The

average ROM in metacarpal fracture was 96%, and in finger fracture, it was 84% relative to the healthy side. In cement-based fixators, the surgeon manually stabilizes the fracture until the cement hardens, after which it is no longer possible to make changes or adjustments to the fixator.<sup>22</sup> Due to the radiopaque nature of the cement and metal clamps and their possible overlap with the fracture site in the radiograph, these fixators and those whose communication clamps are metal may lead to disturbance in the radiographs during and after the surgery. In 1994, Suzuki introduced a new skeletal traction system for the treatment of intra-articular fractures

and fracture dislocations of the hand, which consisted of two or three pins and an elastic band. In this study, seven patients with severe joint damage were effectively treated with this system.<sup>20</sup> Fixators based on rubber bands use traction for reduction and support of the fracture. To connect the rubber bands to the wires in these fixators, it is required to bend the wire several times, which makes the final structure bulky and difficult to use. Moreover, the rubber bands used in these fixators are the weakest part of the fixator and may be broken.<sup>18</sup>

Table 2. Final functional outcomes

Groups	Group A (Percutaneous pins+splint, n=19)	Group B (Mini external fixator, n=33)	P-value
VAS*	0.00±0.00	0.00±0.00	
Quick-DASH	3.74±6.51	1.91 ± 3.76	0.204
Total Active Motion**	0.90±0.12	0.97±0.06	0.012
Time to return to work (day)	35.89±14.21	9.52±8.74	0.001
Physiotherapy (session)	15.58±12.30	7.18±11.68	0.018
Pin tract infection (person)	1	1	0.694

\* Visual Analogue Scale

\*\* Relative to the healthy side

Fixators that are made from the tools available in the operating room have several advantages, including low cost, immediate access, and modular structure in some types.<sup>12,18-20</sup> However, the lack of specific tools and technical difficulties in making and using them are among their weaknesses. The most challenging drawback of these fixators is maintaining a stable and secure structure during the healing process.<sup>12,22</sup> A variety of commercial external fixators are currently available. Strong structure and standard application techniques are considered to be the positive points of this category of fixators. Nonetheless, these fixators are expensive and their availability is limited in centers where the number of patients is small.<sup>15-17</sup> Based on the aforementioned findings, the ideal characteristics of an external fixator for hand surgeries should include adequate strength while remaining delicate, easy to access, adjustable, easy to use, modular in design, radiolucent, and ultimately affordable.<sup>24</sup>

In the current study, we used a newly designed external fixator, "mini external fixator", which was invented by Dr. Parviz Ahangar. This mini external fixator consists of a 5 mm-diameter rod made of a type of polymer called polyoxymethylene (POM), which has multiple 1.5-mm holes for inserting the pin into the bone and 1-mm holes perpendicular to the previous holes to fix the pins in the rod using 1.4-mm screws [Figure 2]. The K-wire is available in diameters of 1 mm and 1.5 mm, with the appropriate size chosen according to the degree of fracture instability. The use and adjustment of this fixator is simple. The fact that the rod material is polymer does not negatively affect the evaluation of the reduction quality with radiography (unlike metal and cement types). In addition, it is possible to insert K-wire

through the rod in different directions according to the surgeon's discretion and the type of fracture, using drills with diameters of 1 mm and 1.5 mm [Figure 3]. Due to the high resistance of POM to heat and humidity, this external fixator can be sterilized in an autoclave.

After the application of this external fixator, patients can immediately start finger movement, which prevents possible future finger joint stiffness and subsequent dysfunction. It also allows patients to return to work and daily activities more quickly. Due to the delicacy of the external fixator, there is no interference in the movements of the adjacent fingers. Economically, this external fixator is more affordable than commercial ones.

In this study, we had a 100% union rate in both groups at the sixth-week visit, and the VAS score was 0 in all patients in both groups at a final follow-up visit. Two patients in the mini external fixator group and one patient in the PCP group mentioned occasional mild pain during intensive activities or in cold exposure. However, they did not complain of pain during usual daily activities. Both groups exhibited good functional outcomes. A similar result was obtained in a study that treated 12 phalangeal fractures using the Ichi-Fixator system.<sup>6</sup> Although the Quick-DASH score in the mini external fixator group (1.91±3.76) was slightly better than that in the PCP group (3.74±6.51), the difference was not clinically dramatic and statistically significant ( $P=0.204$ ).

In the final follow-up visit, the TAM of the finger was significantly higher in the mini external fixator group (0.97±0.06) than in the PCP group (0.90±0.12) ( $P=0.012$ ). This difference in TAM between the two groups was also clinically significant, which can be attributed to the early initiation of finger movement in patients treated with a mini



external fixator. Other studies have yielded similar results.<sup>1,6,21</sup> In addition, the number of physiotherapy sessions in the mini external fixator group ( $7.18 \pm 11.68$ ) was significantly lower than that in the PCP group ( $15.58 \pm 12.30$ ) ( $P=0.018$ ). The patients treated with mini external fixators returned to their jobs in a shorter period of time ( $9.52 \pm 8.74$  days) in comparison to patients in the PCP group ( $35.89 \pm 14.21$  days) ( $P=0.001$ ). In a study conducted by

Yamamoto in 2019, a similar result was obtained, and patients were able to return to work promptly after treatment.<sup>6</sup> In the current study, the patients chose the treatment method themselves. The lack of randomization of patients was one of the limitations of this study. In addition, the small number of patients in the PCP group (19 patients) reduced the power of the study.

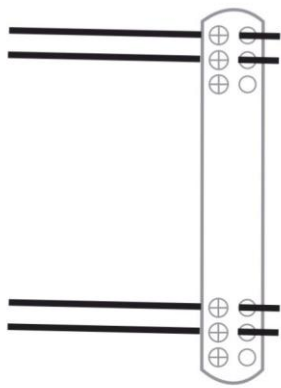


Figure 2. Schematic illustration of mini external fixator

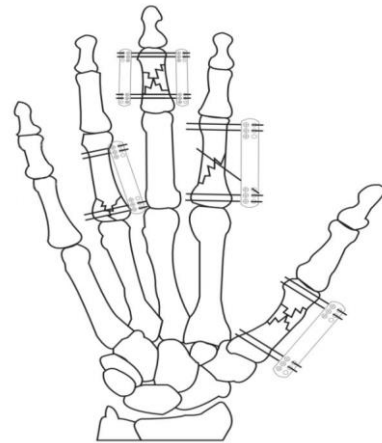


Figure 3. Schematic illustration of the implanted mini external fixator

### Conclusion

As evidenced by the results of the present study, the treatment of unstable finger fractures with a mini external fixator had three advantages over routine treatment with pins and splints. It allows for earlier finger movement and improved ROM, requires fewer physical therapy sessions, and facilitates a quicker return to work. This mini external fixator is easy to use, accessible, non-bulky, and cost-effective, and it can be an effective treatment option for unstable and complex finger fractures.

### Acknowledgement

N/A

### Authors Contribution:

1. Dr. Parviz AHANGAR: Invention of the device (mini external fixator) and performing surgeries.
2. Dr. Soosan ALIMOHAMMADZADEH TAHER: study desing and revising the manuscript.
3. Dr. Reza SHAHRYAR KAMRANI: study conception and revising the manuscript, data interpretation.
4. Dr. Mostafa SHAHREZAE: data acquisition.
5. Dr. Shamim FATTAH HESARI: data acquisition.
6. Dr. Seyed Shahabeddin BANIHASHEMIAN: data analysis and draft the manuscript.

**Declaration of Conflict of Interest:** The author(s) do NOT

have any potential conflicts of interest for this manuscript.

**Declaration of Funding:** The author(s) received NO financial support for the preparation, research, authorship, and publication of this manuscript.

**Declaration of Ethical Approval for Study:** Research Ethics committees of AJA university of Medical Sciences, IIRAJAUMS.REC.1402.038, 2023-05-15.

**Declaration of Informed Consent:** There is no information (names, initials, hospital identification numbers, or photographs) in the submitted manuscript that can be used to identify patients.

Parviz Ahangar MD <sup>1</sup>

Mostafa Shahrezaee MD <sup>1</sup>

Reza Shahryar Kamrani MD <sup>1</sup>

Shamim Fattah Hesari MD <sup>1</sup>

Seyed Shahabeddin Banihashemian MD <sup>2</sup>

Soosan Alimohammadzadeh Taher MD <sup>1</sup>

1 Department of Orthopaedic and Trauma Surgery, Imam Reza Hospital, Aja University of Medical Sciences, Tehran, Iran

2 Department of Rheumatology, Imam Reza Hospital, Aja University of Medical Sciences, Tehran, Iran

## References

1. Nagi A, Mubark I, Sarhan I, Ragab A. Management of Unstable Phalangeal Shaft Fractures Using External Minifixator. *Ortop Traumatol Rehabil.* 2019; 21(3):181-185. doi: 10.5604/01.3001.0013.2922.
2. Ghosh S, Sinha RK, Datta S, Chaudhuri A, Dey C, Singh A. A study of hand injury and emergency management in a developing country. *Int J Crit Illn Inj Sci.* 2013; 3(4):229-34. doi: 10.4103/2229-5151.124101.
3. Yoong P, Goodwin R, Chojnowski A. Phalangeal fractures of the hand. *Clin Radiol.* 2010; 65(10):773-80. doi: 10.1016/j.crad.2010.04.008.
4. Oetgen ME, Dodds SD. Non-operative treatment of common finger injuries. *Curr Rev Musculoskelet Med.* 2008; 1(2):97-102. doi: 10.1007/s12178-007-9014-z.
5. Bhatt RA, Schmidt S, Stang F. Methods and pitfalls in treatment of fractures in the digits. *Clin Plast Surg.* 2014; 41(3):429-50. doi: 10.1016/j.cps.2014.03.003.
6. Yamamoto Y, Ichihara S, Suzuki M, et al. Treatment of finger phalangeal fractures using the Ichi-Fixator system: A prospective study of 12 cases. *Hand Surg Rehabil.* 2019; 38(5):302-306. doi: 10.1016/j.hansur.2019.07.011.
7. Viegas SF, Ferren EL, Self J, Tencer AF. Comparative mechanical properties of various Kirschner wire configurations in transverse and oblique phalangeal fractures. *J Hand Surg Am.* 1988; 13(2):246-53. doi: 10.1016/s0363-5023(88)80059-5.
8. Gregory S, Lalonde DH, Leung LTF. Minimally invasive finger fracture management: wide-awake closed reduction, K-wire fixation, and early protected movement. *Hand Clin.* 2014; 30(1):7-15. doi: 10.1016/j.hcl.2013.08.014.
9. Page SM, Stern PJ. Complications and range of motion following plate fixation of metacarpal and phalangeal fractures. *J Hand Surg Am.* 1998; 23(5):827-32. doi: 10.1016/S0363-5023(98)80157-3.
10. Dohse NM, Jones CM, Ilyas AM. Fixation of hand fractures with intramedullary headless compression screws. *Arch Bone Jt Surg.* 2022; 10(12):1004-1012. doi: 10.22038/ABJS.2022.64506.3102..
11. Margić K. External fixation of closed metacarpal and phalangeal fractures of digits. A prospective study of one hundred consecutive patients. *J Hand Surg Br.* 2006; 31(1):30-40. doi: 10.1016/j.jhsb.2005.09.013.
12. Walter FL, Papandrea RF. A mini external fixator for hand and finger fractures constructed from readily available materials. *Tech Hand up Extrem Surg.* 2011; 15(4):215-8. doi: 10.1097/BTH.0b013e318217615f.
13. Ellis SJ, Cheng R, Prokopia P, et al. Treatment of proximal interphalangeal dorsal fracture-dislocation injuries with dynamic external fixation: a pins and rubber band system. *J Hand Surg Am.* 2007; 32(8):1242-50. doi: 10.1016/j.jhsa.2007.07.001.
14. Ahangar P, Rahimnia A, Mokhtari M, Rahimnia A. Treatment of Fracture-Dislocations of Proximal Interphalangeal Joint by Applying of Dynamic Mini External Fixator: Clinical and Radiographic Results. *Arch Bone Jt Surg.* 2021; 9(6):695-701. doi: 10.22038/ABJS.2021.54249.2709.
15. Ashmead IV D, Rothkopf DM, Walton RL, Jupiter JB. Treatment of hand injuries by external fixation. *J Hand Surg Am.* 1992; 17(5):954-64.
16. Kubitskiy A, Soliman BA, Dowd MB, Curtin P. External fixation of the hand: a simple approach to comminuted proximal interphalangeal joint fractures. *Hand Surg* 2014; 19(1):85-9. doi: 10.1142/S0218810414500142.
17. Seitz WH, Gomez W, Putnam MD, Rosenwasser MP. Management of severe hand trauma with a mini external fixateur. *Orthopedics.* 1987; 10(4):601-10. doi: 10.3928/0147-7447-19870401-11.
18. Badia A, Riano F, Ravikoff J, Khouri R, Gonzalez-Hernandez E, Orbay JL. Dynamic intradigital external fixation for proximal interphalangeal joint fracture dislocations. *J Hand Surg Am.* 2005; 30(1):154-60. doi: 10.1016/j.jhsa.2004.07.019.
19. Ruland RT, Hogan CJ, Cannon DL, Slade JF. Use of dynamic distraction external fixation for unstable fracture-dislocations of the proximal interphalangeal joint. *J Hand Surg Am.* 2008; 33(1):19-25. doi: 10.1016/j.jhsa.2007.07.018.
20. Suzuki Y, Matsunaga T, Sato S, Yokoi T. The pins and rubbers traction system for treatment of comminuted intraarticular fractures and fracture-dislocations in the hand. *J Hand Surg Br.* 1994; 19(1):98-107. doi: 10.1016/0266-7681(94)90059-0.
21. Shehadi SI. External fixation of metacarpal and phalangeal fractures. *J Hand Surg Am.* 1991; 16(3):544-50. doi: 10.1016/0363-5023(91)90030-f.
22. Wijffels M, Patel A, Bartlema K, Rahimtoola Z. A simple and low-cost external fixator for infected hand injuries. *J Hand Microsurg.* 2013; 5(2):89-91. doi: 10.1007/s12593-012-0069-8.
23. Crockett DJ. Rigid fixation of bones of the hand using K wires bonded with acrylic resin. *Hand.* 1974; 6(1):106-7. doi: 10.1016/0072-968x(74)90022-9.
24. Sraj S. A simple phalangeal external fixator using Kirschner wires and locking balls: no need for cement or rubber bands. *J Hand Surg Am.* 2016; 41(7):e217-21. doi: 10.1016/j.jhsa.2016.04.017.