

## RESEARCH ARTICLE

## Patient and Surgeon Variables Associated With a Diagnosis of Shoulder Periprosthetic Joint Infection

Richard Feng, MPH; Kacie Mitchell, MS; Shyam S. Ramachandran, BSA; Melle Broekman, MS; Anthony Johnson, MD; David Ring, MD, PhD; Sina Ramtin, MD

Research performed at the University of Austin, Austin, TX, USA

Received: 11 June 2024

Accepted: 9 September 2024

## Abstract

**Objectives:** There is no consensus reference standard for diagnosing prosthetic shoulder joint infection (PJI). There may be inadequate distinction between colonization and infection. It is not clear that culture of a common shoulder commensal organism can account for unexpected pain or stiffness after shoulder arthroplasty. In this survey-based experiment, we asked: 1) What patient and surgeon variables are associated with diagnosis of shoulder PJI? And 2) What is the surgeon interobserver agreement for diagnosis of shoulder PJI?

**Methods:** One hundred seven members of the Science of Variation Group reviewed ten hypothetical patient scenarios with five randomized variables: examination findings, serum markers, synovial fluid markers, histological assessment, and organism cultured from deep tissue specimens. Participants diagnosed the presence or absence of shoulder PJI. Mixed multilevel logistic regression sought variables associated with PJI diagnosis. Interobserver agreement was measured with Fleiss kappa.

**Results:** Surgeon diagnosis of shoulder PJI was independently associated with deep tissue culture growth of *C. acnes* (OR=235 [95% CI 19 to 2933];  $P < 0.01$ ), *S. epidermidis* (OR=147 [95% CI 8.4 to 2564];  $P < 0.01$ ), and *S. aureus* (OR=110 [95% CI 6.9 to 1755];  $P < 0.01$ ) much more so than presence of a sinus tract on examination (OR=43 [95% CI 3.7 to 505];  $P < 0.01$ ), inflammatory histology (OR=15 [95% CI 4.0 to 58];  $P < 0.01$ ), inflammatory synovial fluid markers (OR=13 [95% CI 3.9 to 45];  $P < 0.01$ ), and serum inflammatory markers (OR=5.8 [95% CI 2.0 to 17];  $P < 0.01$ ). The reliability of surgeon diagnosis for shoulder PJI was poor (Fleiss kappa = 0.013 [95% CI -0.0039 to 0.031]).

**Conclusion:** The observation that surgeons may not adequately distinguish colonization and infection – considering any positive culture as an infection – combined with the low reliability of diagnosis observed, suggests possible overdiagnosis and overtreatment of shoulder PJI.

**Level of evidence:** IV

**Keywords:** Arthroplasty, *C. Acnes*, Colonization, Infection, Prosthetic joint infection, Shoulder

## Introduction

Colonization is defined as the presence of bacteria without a host immune response.<sup>1,2</sup> Infection is defined by local and systemic host responses provoked by microorganisms.<sup>3</sup> Colonization is asymptomatic while shoulder infection may be accompanied by symptoms related to the inflammatory response.

It remains unclear whether the presence of *Cutibacterium*

*acnes* in cultures of shoulder tissue or implants represents infection or colonization. Current evidence suggests that *C. acnes* is both a common contaminant of bacterial cultures and also a commensal of the shoulder joint.<sup>4-7</sup> A review of 223 revision shoulder arthroplasties identified 137 with culture of *C. acnes* and created a “Propi score” that attempted to quantify the amount of bacterial growth, but could not identify a threshold at which *C. acnes* might be considered infection.<sup>8</sup> The Infectious Diseases Society of

**Corresponding Author:** David Ring, Department of Surgery and Perioperative Care, Dell Medical School, University of Texas at Austin, Austin, TX, USA

**Email:** david.ring@austin.utexas.edu



THE ONLINE VERSION OF THIS ARTICLE  
ABJS.MUMS.AC.IR



America (IDSA) recommends utilizing clinical signs (i.e., presence of sinus tract or purulence around prosthesis), laboratory results (i.e., histologic evidence of acute inflammation or positive intraoperative bacterial culture), and imaging findings (i.e., radiographic loosening) to support a diagnosis of infection.<sup>9</sup> The Musculoskeletal

Infection Society (MSIS) and the International Consensus Meeting (ICM) proposed pairing culture of organisms with a sinus tract or at least 3 signs of an inflammatory response.<sup>10,11</sup> The current clinical practice guidelines from the American Academy of Orthopaedic Surgeons (AAOS) for PJI diagnosis do not distinguish colonization from infection.<sup>12</sup>

### Rationale

Surgeons who ascribe ongoing pain and stiffness after technically adequate shoulder arthroplasty to cultured bacteria in the absence of a host response, might be overdiagnosing and overtreating prosthetic joint infection.<sup>13-16</sup> There is evidence that colonization – sometimes framed as “unexpected positive cultures” (UPC) in the setting of revision arthroplasty – does not benefit from treatment and does not adversely impact recovery or harm health.<sup>17,18</sup> In one study, there was no difference in mean Oxford Shoulder Score (OSS) and mean range of shoulder motion (ROM) two years after revision arthroplasty in patients with negative cultures and those with UPC (treated with up to 10 weeks of intravenous or oral antibiotics alone).<sup>17</sup> In another study, among people diagnosed with shoulder PJI, a positive *C. acnes* culture was associated with lower mortality when compared to other organisms and aseptic revisions.<sup>19</sup>

### Study Questions

To better understand whether surgeons currently distinguish infection from colonization, we conducted a survey-based experiment of variables associated with diagnosis of shoulder prosthesis infection and asked: 1) What patient variables or surgeon variables are associated with a diagnosis of shoulder PJI? 2) What is the interobserver agreement of diagnosis of a shoulder PJI?

## Materials and Methods

### Study Design and Setting

This was a survey-based experiment. Ten clinical vignettes were created with randomized aspects of hypothetical patient presentation that could influence surgeon diagnosis of shoulder PJI. We used SurveyMonkey (Palo Alto, California, United States) to distribute a survey with the clinical scenarios to surgeons of the Science of Variation Group (SOVG). The SOVG is an international collaboration of musculoskeletal surgeons who study the variation of interpretation and classification of injuries. Approximately 200 surgeons in the SOVG participate in at least one survey per year, and 107 surgeons responded to this survey. This participation rate is similar to prior SOVG studies.<sup>20-22</sup> We ask people to participate only if they frequently perform the procedure being addressed. We used randomization and measured associations based on variation, which depends on adequate variation in the sample, but not representative rates. The specific rates of categorizations and estimations may be unique to this sample, but the associations should be reproducible in any similar experiment with comparable

variation in opinions. Ninety-one percent of respondents (97) were men. Forty-five percent (48) were practicing in the United States. Seventy-nine percent (84) were supervising trainees. Fifty percent (54) specialized in upper extremity orthopedic surgery [Table 1].

**Table 1. Characteristics of Surgeons Who Participated in This Study**

Variables	Value, n (%)
<b>Total Participants</b>	107
<b>Gender</b>	
Male	97 (91%)
Female	10 (9%)
<b>Location of Practice</b>	
United States	48 (45%)
Europe	36 (34%)
Other	23 (22%)
<b>Years of practice</b>	
0 – 5 years	24 (23%)
6 – 10 years	23 (22%)
11 – 20 years	30 (28%)
21 – 30 years	29 (27%)
<b>Subspecialty</b>	
Fracture surgeons	35 (33%)
Upper extremity	54 (50%)
General and other	18 (17%)
<b>Supervising trainees</b>	84 (79%)

### Questionnaire

Participating surgeons were asked to determine whether a clinical vignette represented an absence or presence of an infected periprosthetic joint. The survey consisted of 10 different clinical vignettes with randomized variables [Appendix A]. The variables included sinus tract communication to the joint space (presence or absence), positive cultures of an organism isolated from the tissue or synovial fluid (presence or absence, with *S. aureus*, *C. acnes*, and *S. epidermidis* each variably represented), intraoperative biopsy demonstrating inflammation (presence or absence), lucency or loosening around the glenoid or humeral components on shoulder radiographs (presence or absence), elevation of D-dimer, C-reactive protein (CRP), erythrocyte sedimentation rate (ESR) (presence or absence), and aspirated joint fluid tests (leukocyte esterase [LE], alpha-defensin, CRP, elevated polymorphonuclear leukocytes [PMN]). At the end of the vignette, each surgeon was asked to grade each hypothetical case as infected or uninfected.

### Statistical Analysis

Descriptive statistics were performed on all participants, and we reported numbers and percentages for all discrete variables. Because each surgeon completed ten cases, responses were correlated among participants, and we performed multilevel modeling to account for nesting (intercorrelation). To identify patient variables associated with a diagnosis of shoulder PJI, a multilevel mixed-effects logistic regression model was

constructed, accounting for all randomized patient variables. In addition, we sought to identify variables associated with a diagnosis of shoulder PJI in a logistic regression multivariable analysis. Backward elimination was used based on the delta-Akaike Information Criterion (delta-AIC), omitting all patient and surgeon variables that did not improve model fit. Odds ratios (OR) were reported with 95% confidence intervals (CI), and alpha was set at 0.05. Interobserver agreement on diagnosis of shoulder PJI was determined by comparing surgeon responses to the survey-based scenarios. The interobserver agreement was measured with Fleiss kappa using a bootstrapping method to calculate the standard error and 95% confidence interval. Interpretation of the Fleiss kappa was based on a well-established system: slight agreement was defined by a Fleiss kappa value between 0.01 and 0.20, fair agreement between 0.21 and 0.40, moderate agreement between 0.61 and 0.80, and near perfect agreement for values greater than 0.81.<sup>23</sup>

## Results

### Patient and surgeon variables associated with a diagnosis of shoulder PJI

Accounting for potential confounding variables using

multivariable analysis, surgeon diagnosis of shoulder PJI was independently associated with deep tissue culture demonstrating growth of *C. acnes* (OR =235 [95% CI 19 to 2933];  $P < 0.01$ ), *Staphylococcus epidermidis* (OR=147 [95% CI 8.4 to 2564];  $P < 0.01$ ), and *Staphylococcus aureus* (OR=110 [95% CI 6.9 to 1755];  $P < 0.01$ ) much more so than presence of a sinus tract on examination (OR=43 [95% CI 3.7 to 505];  $P < 0.01$ ), positive histological assessment (OR=15 [95% CI 4.0 to 58];  $P < 0.01$ ), positive synovial fluid markers (OR=13 [95% CI 3.9 to 45];  $P < 0.01$ ), and elevated serum markers (OR=5.8 [95% CI 2.0 to 17];  $P < 0.01$ ) [Table 2]. Surgeon diagnosis of shoulder PJI was not associated with radiographic findings of lucency around the glenoid (OR = 2.5 [95% CI 0.96 to 6.3];  $P = 0.062$ ). In multivariable analysis, there were no surgeon characteristics or demographics (i.e., gender, continent of practice, length of practice, supervising status, or subspecialty) associated with the diagnosis of shoulder PJI.

### Interobserver Agreement

There was poor reliability of surgeon diagnosis of shoulder PJI (Fleiss kappa = 0.013 [95% CI -0.0039 to 0.031]).<sup>23</sup>

**Table 2. Mixed Multilevel Logistic Regression Analysis of Patient Factors Associated with the Likelihood of Surgeon Diagnosis of Periprosthetic Joint Infection**

	Odds Ratio (95% Confidence Interval)	Standard Error	P-value	Δ Akaike
<b>Lucency around glenoid</b>				2.7
No	Reference value			
Yes	2.5 (0.96 to 6.3)	1.2	0.062	
<b>Serum markers</b>				14
Normal	Reference value			
Elevated	<b>5.8 (2.0 to 17)</b>	<b>3.2</b>	<b>&lt;0.01</b>	
<b>Synovial fluid markers</b>				28
Negative	Reference value			
Positive	<b>13 (3.9 to 45)</b>	<b>8.3</b>	<b>&lt;0.01</b>	
<b>Histological assessment</b>				28
Negative	Reference value			
Positive	<b>15 (4.0 to 58)</b>	<b>10</b>	<b>&lt;0.01</b>	
<b>Deep tissue culture</b>				76
No positive culture	Reference value			
<i>C. Acnes</i>	<b>235 (19 to 2933)</b>	<b>301</b>	<b>&lt;0.01</b>	
<i>S. Aureus</i>	<b>110 (6.9 to 1755)</b>	<b>155</b>	<b>&lt;0.01</b>	
<i>S. Epidermidis</i>	<b>147 (8.4 to 2564)</b>	<b>214</b>	<b>&lt;0.01</b>	
<b>Examination</b>				82
Warmth and redness	Reference value			
Sinus tract	<b>43 (3.7 to 505)</b>	<b>54</b>	<b>&lt;0.01</b>	

Bold = statistically significant,  $P < 0.05$

## Discussion

Shoulder arthroplasty infection may be overdiagnosed and overtreated by virtue of the lack of a consensus reference

standard for diagnosis contributing to inadequate distinction of colonization and infection. In a survey-based experiment among an international group of surgeons, we found that

positive culture, especially that of *C. acnes*, was overemphasized in surgeon diagnosis of PJI relative to evidence of a host response and agreement on infection was poor. These findings emphasize the need for a reference standard in PJI diagnosis that makes a clear distinction between colonization and infection.

#### **Limitations**

One study limitation is that the majority of SOVG members are largely men in academic medicine. It is likely that their training and clinical practice patterns differ from that of the orthopedic surgeon community as a whole, and the rates of responses may not be representative. Because the experiment depends on adequate variation in responses to measure associations, the associations identified in this study should be reproducible in any sufficiently variable sample. A more diverse surgeon study population is desirable in many ways and all surgeons are encouraged to join at: <https://www.surveymonkey.com/r/IQGLKFZ>. Repeating this study with a more diverse group would help confirm the findings of this study. Second, participation in these surveys is left to the discretion of surgeons to decide whether they have the knowledge and experience needed to address the subject matter. A few surgeons stretching their field of expertise should not alter the results appreciably and all musculoskeletal surgeons consider implant infection vs. colonization. Third, online survey experiments cannot replicate the complexity of the interaction between a patient and a surgeon. Nevertheless, this approach is able to identify trends in thought and action when considering prosthetic joint infection. Studies of the care of actual patients could help confirm the findings.

#### **Patient and surgeon variables are associated with a diagnosis of shoulder PJI**

The finding that diagnosis of shoulder PJI is associated more strongly with positive deep tissue culture than with signs of a local host immune response (presence of a sinus tract, positive histological assessment, positive synovial fluid markers) or systemic immune response (elevated serum markers) suggests that surgeons may overemphasize positive cultures and may not adequately distinguish colonization from infection. A positive culture could be a contaminant (erroneous culture), colonization (accurate culture, little or no host response), or infection (accurate culture and harmful host response). A narrative review by Patel et al. made the case that *C. acnes* cultures of tissue and implants from revision shoulder arthroplasty cannot, in isolation, confirm infection.<sup>24</sup> Diagnosis of infection based on intraoperative *C. acnes* culture without making the distinction between colonization and infection is likely a form of overdiagnosis and subsequent overtreatment. It has been estimated that the rate of unexpected *C. acnes* from intraoperative revision shoulder arthroplasty cultures is between 24-50%, the rate of diagnosis of infection was only 5-25%, and the rate of host response—purulence or sepsis in particular—is unclear but seemingly much lower than the rate that infection is diagnosed.<sup>24,25</sup> This suggests that *C. acnes* is either often or always a contaminant or a colonizer rather

than the cause of an infection.<sup>24</sup> As further evidence of potential overdiagnosis, *C. acnes* is associated with lower mortality when considered the causative organism of shoulder PJI.<sup>19,26</sup>

#### **Interobserver agreement of diagnosis of a shoulder periprosthetic infection**

The finding that surgeons have poor agreement on the diagnosis of PJI may be due, in part, to variation in distinction between colonization and infection. Shoulder surgeons often attribute greater pain intensity, greater magnitude of incapability, and unexplained stiffness to potential infection in the absence of evidence of a local or systemic host response.<sup>27,28</sup> The limited reliability of diagnosis of infection observed in this study suggests that nonspecific pain after arthroplasty may be misattributed to colonization contributing to misdiagnosis and overtreatment of infection.<sup>29</sup> Given the evidence that pain is a complex biopsychosocial phenomenon, and that pain intensity correlates more strongly to mindset variables than to pathophysiology, perhaps pain is not a useful indicator of a potential sign of a host response,<sup>30</sup> and we might rely instead on reproducible experimental evidence of a host response.

#### **Conclusion**

Our results suggest that surgeon diagnosis of shoulder PJI is based more on positive culture than on evidence of a host inflammatory response, and surgeons often disagree. This suggests inadequate distinction of colonization and infection, and the possibility of inappropriate use of pain as a sign of a host response. When patients experience greater pain intensity, incapability, and stiffness after arthroplasty, a technical or biomedical explanation is often sought. When the examination and radiographs do not identify technical deficiencies, infection may be considered even in the absence of fever, abscess, or a sinus tract.<sup>31,32</sup> The concept is that a low-grade infection could cause unexpected discomfort, incapability, or stiffness.<sup>33</sup> Varied, imprecise, and unreliable diagnosis of infection exposes patients to potential harms from overdiagnosis and overtreatment of infection. The removal of a well-fixed shoulder prosthesis is a destructive procedure that should be avoided if possible.<sup>34</sup> If colonization is adequately distinguished from infection, and we might argue, if we err towards colonization being a benign condition that cannot account for discomfort and incapability, then our treatment strategies might evolve to the benefit of patients.

#### **Acknowledgement**

N/A

**Authors Contribution:** Authors who conceived and designed the analysis: Shyam Ramachandran, Sina Ramtin, David Ring/ Authors who collected the data: David Ring, Sina Ramtin/Authors who contributed data or analysis tools: David Ring, Sina Ramtin, Melle Broekman/Authors who performed the analysis: Melle Broekman/Authors who wrote the paper: Richard Feng, Kacie Mitchell, Anthony Johnson, Sina Ramtin, David Ring/Other contribution: Sina Ramtin, David Ring, Anthony Johnson, Shyam

Ramachandran, Richard Feng, Kacie Mitchell - Review and editing of manuscript draft

**Declaration of Conflict of Interest:** Anthony Johnson: Dr. Johnson is an editorial board member of JAMA Surgery, AAOS Now, and the Texas Orthopaedic Journal. He has stock in Pfizer. He is the Chair of the AAOS Diversity Advisory Board. David Ring: Dr. Ring receives royalties from Skeletal Dynamics. He receives royalties from Wolters Kluwer Health for an Up-to-date chapter. He is a paid consultant for Premier Healthcare Solutions. He is a paid consultant for Everus. He has stock options in MyMedicalHub. He receives research support from the National Institutes for Health (RO1 multi-site trial of mental health toolkit for optimal recovery from trauma). He is the Deputy Editor for Clinical Orthopaedics and Related Research and receives a stipend.

**Declaration of Funding:** The author(s) received NO financial support for the preparation, research, authorship, and publication of this manuscript.

**Declaration of Ethical Approval for Study:** Ethical Approval: University of Texas at Austin Health Science

Institutional Review Board (IRB #: 2020-05-0040). Approved 5/27/2020

**Declaration of Informed Consent:** The authors declare there is no information (names, initials, hospital identification numbers, or photographs) in the submitted manuscript that can be used to identify patients.

Richard Feng MPH<sup>1</sup>  
Kacie Mitchell MS<sup>1</sup>  
Shyam S. Ramachandran BSA<sup>1</sup>  
Melle Broekman MS<sup>2</sup>  
Anthony Johnson MD<sup>3</sup>  
David Ring MD, PhD<sup>2</sup>  
Sina Ramtin MD<sup>2</sup>

1 Texas A&M Health Science Center, School of Medicine, Dallas, TX, USA

2 Department of Surgery and Perioperative Care, Dell Medical School, University of Texas at Austin, Austin, TX, USA

3 Orthopaedic Surgery Residency Program, Dell Medical School at the University of Texas, Austin, TX, USA

## References

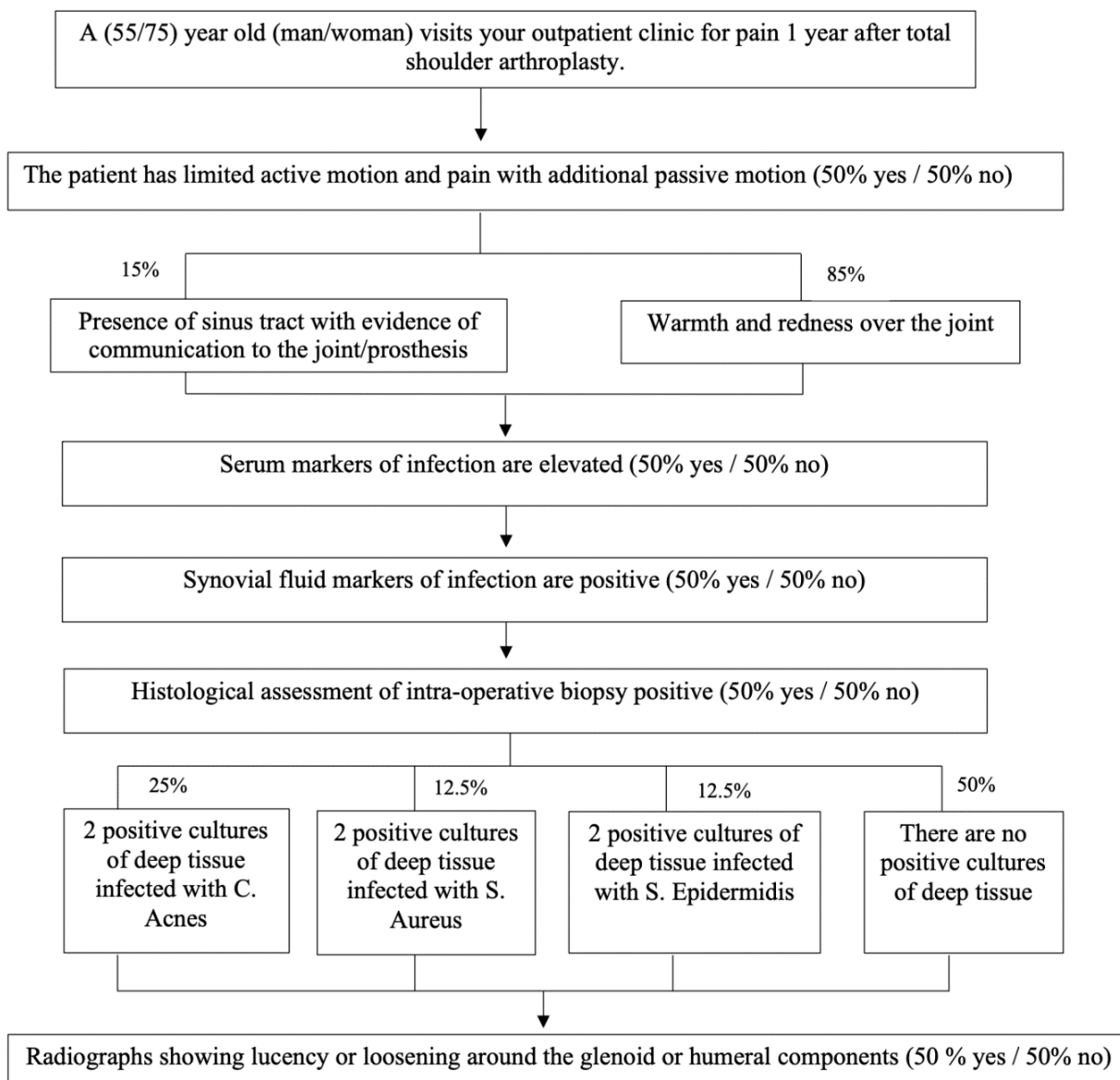
- Malone M. The microbiome of diabetic foot ulcers and the role of biofilms. In: The Microbiology of Skin, Soft Tissue, Bone and Joint Infections. 2th ed. Kon K, Rai M, eds. Academic Press: UK; 2017.
- Robinson J. Colonization and infection of the respiratory tract: What do we know? Paediatr Child Health. 2004; 9(1):21-24. doi:10.1093/pch/9.1.21.
- Bowler PG, Duerden BI, Armstrong DG. Wound Microbiology and Associated Approaches to Wound Management. Clin Microbiol Rev. 2001; 14(2):244-269. doi:10.1128/CMR.14.2.244-269.2001.
- Falconer TM, Baba M, Kruse LM, et al. Contamination of the Surgical Field with Propionibacterium acnes in Primary Shoulder Arthroplasty. JBJS. 2016; 98(20):1722. doi:10.2106/JBJS.15.01133.
- Hudek R, Brobeil A, Brüggemann H, Sommer F, Gattenlöhner S, Gohlke F. Cutibacterium acnes is an intracellular and intra-articular commensal of the human shoulder joint. J Shoulder Elbow Surg. 2021; 30(1):16-26. doi:10.1016/j.jse.2020.04.020.
- Qiu B, Al K, Pena-Diaz AM, et al. Cutibacterium acnes and the shoulder microbiome. J Shoulder Elbow Surg. 2018; 27(10):1734-1739. doi:10.1016/j.jse.2018.04.019.
- Singh AM, Sethi PM, Romeo AA, Anakwenze OA, Abboud JA, Namdari S. Strategies to decolonize the shoulder of Cutibacterium acnes: a review of the literature. J Shoulder Elbow Surg. 2020; 29(4):660-666. doi:10.1016/j.jse.2019.11.037.
- Ahsan ZS, Somerson JS, Matsen FAI. Characterizing the Propionibacterium Load in Revision Shoulder Arthroplasty: A Study of 137 Culture-Positive Cases. J Bone Joint Surg Am. 2017; 99(2):150. doi:10.2106/JBJS.16.00422.
- Osmon DR, Berbari EF, Berendt AR, et al. Diagnosis and Management of Prosthetic Joint Infection: Clinical Practice Guidelines by the Infectious Diseases Society of America. Clin Infect Dis. 2013; 56(1):e1-e25. doi:10.1093/cid/cis803.
- Parvizi J, Zmistowski B, Berbari EF, et al. New Definition for Periprosthetic Joint Infection: From the Workgroup of the Musculoskeletal Infection Society. Clin Orthop Relat Res. 2011; 469(11):2992-2994. doi:10.1007/s11999-011-2102-9.
- Parvizi J, Gehrke T, Chen AF. Proceedings of the International Consensus on Periprosthetic Joint Infection. Bone Joint J. 2013; 95-B(11):1450-1452. doi:10.1302/0301-620X.95B11.33135.
- Tubb CC, Polkowksi GG, Krause B. Diagnosis and Prevention of Periprosthetic Joint Infections. J Am Acad Orthop Surg. 2020; 28(8):e340-e348. doi:10.5435/JAAOS-D-19-00405.
- Fink B, Sevelde F. Periprosthetic Joint Infection of Shoulder Arthroplasties: Diagnostic and Treatment Options. Biomed Res Int. 2017; 2017:4582756. doi:10.1155/2017/4582756.
- McGoldrick E, McElvany MD, Butler-Wu S, Pottinger PS, Matsen FA. Substantial cultures of Propionibacterium can be found in apparently aseptic shoulders revised three years or more after the index arthroplasty. J Shoulder Elbow Surg. 2015; 24(1):31-35. doi:10.1016/j.jse.2014.05.008.
- Zeller V, Ghorbani A, Strady C, Leonard P, Mamoudy P, Desplaces N. Propionibacterium acnes: An agent of prosthetic joint infection and colonization. J Infect. 2007; 55(2):119-124. doi:10.1016/j.jinf.2007.02.006.
- Do DH, Mounasamy V, Sambandam S. Predictors of Higher Costs Following Reverse Total Shoulder Arthroplasty. Arch Bone Jt Surg. 2024; 12(7):469-476. doi:10.22038/ABJS.2024.77124.3564.
- Falstie-Jensen T, Lange J, Daugaard H, et al. unexpected positive cultures after revision shoulder arthroplasty: does it affect outcome? J Shoulder Elbow Surg. 2021; 30(6):1299-1308. doi:10.1016/j.jse.2020.12.014.

18. Hodakowski AJ, Cohn MR, Mehta N, Menendez ME, McCormick JR, Garrigues GE. An evidence-based approach to managing unexpected positive cultures in shoulder arthroplasty. *J Shoulder Elbow Surg.* 2022; 31(10):2176-2186. doi:10.1016/j.jse.2022.03.019.
19. Austin DC, Townsley SH, Rogers TH, et al. Shoulder Periprosthetic Joint Infection and All-Cause Mortality: A Worrisome Association. *JB JS Open Access.* 2022; 7(1):e21.00118. doi:10.2106/JBJS.OA.21.00118.
20. Sarwar F, Teunis T, Ring D, et al. Surgeon Ratings of the Severity of Idiopathic Median Neuropathy at the Carpal Tunnel Are Not Influenced by Magnitude of Incapability. *Clin Orthop Relat Res.* 2022; 480(6):1143-1149. doi:10.1097/CORR.0000000000002062.
21. Lin E, Crijns TJ, Ring D, Jayakumar P, The Science of Variation Group. Imposter Syndrome Among Surgeons Is Associated With Intolerance of Uncertainty and Lower Confidence in Problem Solving. *Clin Orthop Relat Res.* 2023; 481(4):664-671. doi:10.1097/CORR.0000000000002390.
22. Ramachandran SS, Ring D, Crijns TJ, Science of Variation Group. Upper Extremity Surgeon Recommendations for Imaging Do Not Correspond with Imaging Appropriateness Guidelines. *J Hand Microsurg.* 2024; 16(1):100012. doi:10.1055/s-0042-1758670.
23. Landis JR, Koch GG. The measurement of observer agreement for categorical data. *Biometrics.* 1977; 33(1):159-174.
24. Patel MS, Singh AM, Gregori P, Horneff JG, Namdari S, Lazarus MD. Cutibacterium acnes: a threat to shoulder surgery or an orthopedic red herring? *J Shoulder Elbow Surg.* 2020; 29(9):1920-1927. doi:10.1016/j.jse.2020.02.020.
25. Ahmadi S, Lawrence TM, Sahota S, et al. Significance of Perioperative Tests to Diagnose the Infection in Revision Total Shoulder Arthroplasty. *Arch Bone Jt Surg.* 2018; 6(5):359-364.
26. Chen RE, Vaughan AK, Cox RM, Alfonsi S, Belden KA, Namdari S. Shoulder periprosthetic joint infection is associated with increased mortality. *J Shoulder Elbow Surg.* 2023; 32(6S):S1-S7. doi:10.1016/j.jse.2023.02.004.
27. Millett PJ, Yen YM, Price CS, Horan MP, van der Meijden OA, Elser F. Propionobacter acnes Infection as an Occult Cause of Postoperative Shoulder Pain: A Case Series. *Clin Orthop Relat Res.* 2011; 469(10):2824-2830. doi:10.1007/s11999-011-1767-4.
28. Shields MV, Abdullah L, Namdari S. The challenge of Propionibacterium acnes and revision shoulder arthroplasty: a review of current diagnostic options. *J Shoulder Elbow Surg.* 2016; 25(6):1034-1040. doi:10.1016/j.jse.2016.01.009.
29. Patel VV, Ernst SMC, Rangarajan R, Blout CK, Lee BK, Itamura JM. Validation of new shoulder periprosthetic joint infection criteria. *J Shoulder Elbow Surg.* 2021; 30(7, Supplement):S71-S76. doi:10.1016/j.jse.2021.04.009.
30. Kopp B, Furlough K, Goldberg T, Ring D, Koenig K. Factors associated with pain intensity and magnitude of limitations among people with hip and knee arthritis. *J Orthop.* 2021; 25:295-300. doi:10.1016/j.jor.2021.05.026.
31. Elston MJ, Dupaix JP, Opanova MI, Atkinson RE. Cutibacterium acnes (formerly Propionibacterium acnes) and Shoulder Surgery. *Hawaii J Health Soc Welf.* 2019; 78(11 Suppl 2):3-5.
32. Kadler BK, Mehta SS, Funk L. Propionibacterium acnes infection after shoulder surgery. *Int J Shoulder Surg.* 2015; 9(4):139-144. doi:10.4103/0973-6042.167957.
33. Foruria AM, Fox TJ, Sperling JW, Cofield RH. Clinical meaning of unexpected positive cultures (UPC) in revision shoulder arthroplasty. *J Shoulder Elbow Surg.* 2013; 22(5):620-627. doi:10.1016/j.jse.2012.07.017.
34. Rahmi H, Jawa A. Management of complications after revision shoulder arthroplasty. *Curr Rev Musculoskelet Med.* 2015; 8(1):98-106. doi:10.1007/s12178-014-9249-4.

**APPENDIX**

**Appendix A. Survey Algorithms Evaluating Surgeon Diagnosis of Shoulder Periprosthetic Joint Infection in Randomized Clinical Scenarios**

Survey Algorithm Including External Evidence of Infection (40%)



Survey Algorithm Without External Evidence of Infection (60%)

