

TECHNICAL NOTE**Management of Infected Segmental Bone Defects with Antibiotic-Cement-Coated Nails in the First Stage of the Masquelet Technique. Implantation and Removal of the Cement Spacer around the Nail: A Technical Note**

Germán Garabano, MD; Gonzalo M. Viollaz, MD; Cesar Angel Pesciallo, MD

*Research performed at Orthopaedic and Trauma Surgery Department, British Hospital of Buenos Aires, Argentina**Received: 8 June 2023**Accepted: 20 July 2024***Abstract**

Infected segmental bone defects (ISBD) of the femur and tibia pose a significant challenge. Traditionally, bone fixation in the first stage of the Masquelet technique involves external fixation, but intramedullary nail fixation has recently gained popularity. Despite this, little attention has been focused on the elaboration, implantation, and removal of the spacer around the nail. In this technical note, we present gentamicin cement-coated rigid nails as definitive fixation in the first stage. We also detail the technique for placing and removing the one-piece dyed antibiotic spacer around the nail. We highlight its potential benefits in one of the critical steps of this versatile technique.

Level of evidence: IV**Keywords:** Antibiotic-coated nail, Femur, Infected segmental bone defect, Masquelet technique, Tibia**Introduction**

The induced membrane technique (IMT), also called the Masquelet technique, represents a reliable approach to dealing with infected segmental bone defects (ISBD).¹⁻³ Since its original description, different modifications have been reported, including definitive fixation in the first stage.^{2,4-6}

Little has been reported on antibiotic-cemented coated nails in treating ISBD,^{5,6} and the method of placing and removing the cement spacer around the antibiotic cement-coated nail has scars described.⁶ Therefore, this technical note aims to describe our technique for making, placing, and removing the cement spacer after definitive fixation with a gentamicin-cement-coated rigid nail in the first stage of the IMT in treating infected segmental bone defects of the femur and tibia.

Surgical Technique

After two free weeks of antibiotics (ATB), the first stage removes all previous osteosynthesis and thoroughly debrides all devitalized soft tissues. Bone resection is performed until the bleeding bone ends, and the medullary is reamed and washed.^{5,6} Samples are sent to microbiology

culture (at least 5) and histological analysis (at least 3). To achieve definitive fixation, we ream the medullary until two reamers reach the cortex and implant a gentamicin-cement-coated nail (Synicem Clous, Synimed) 1.5mm narrower than the last reamed. After implantation, we lock the nail with two proximal bolts, tract from the distal, check the length, alignment, and rotation, and perform distal lock using (at least) two distal bolts [Figure 1 a,b]. To make the spacer, we add two grams of vancomycin per dose of cement (Simplex, Stryker Mahwah NJ, USA—40g) and stain it with methylene blue. To avoid the cement adhesion to the nail, placing the cement when it has reached a consistency that does not adhere to the surgical gloves is essential.

The soft tissues around the defect are protected with sleeves, and the cement is placed around the nail in one block, overlapping the bony ends of the defect by 1cm. We irrigated the spacer with a saline solution sparingly during its polymerization to avoid thermal damage to the surrounding tissues [Figures 1 c-h]. We then proceed to soft tissue closure. If any soft tissue coverage procedure is required, we perform it at this point.

Corresponding Author: Germán Garabano, Orthopaedic and Trauma Surgery Department, British Hospital of Buenos Aires, Argentina

Email: ggarabanohbritanico.com.ar/ ggarabano@gmail.com



THE ONLINE VERSION OF THIS ARTICLE
ABJS.MUMS.AC.IR



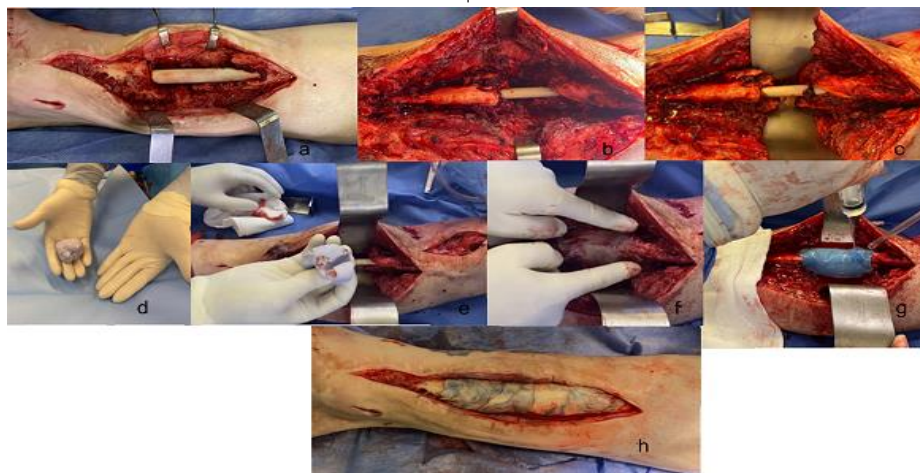


Figure 1. a-b: Intraoperative image showing (in two different patients) fixation during the first stage with the gentamicin-cement-coated nail after debridement. c: Protection of the soft tissues around the bony defect with the sleeves. d: Image showing the consistency of the cement to avoid its adhesion to the nail. Manipulation of the cement with antibiotics without adhering to the gloves. e: Demonstrate that after compression against the nail, the cement does not adhere to the surface (note the imprint on the cement). f: Placement of the cement in the defect overlapping the bone defect. g: Sparingly irrigation with a saline solution during the cement polymerization to avoid potential thermal damage to the surrounding soft tissue. h: Another example image of the placed spacer; note that depending on the amount of methylene blue, the staining of the spacer differs

Postoperative first stage and time between stages

Systemic ATB therapy is administered (first intravenous and then oral) according to the microorganism and antibiogram obtained from intraoperative samples. During the postoperative period, partial weight bearing is allowed immediately until full weight bearing without assistance is achieved according to tolerance.

Second stage

A two-week ATB-free window is prescribed before this stage. The membrane is open carefully in one longitudinal incision. [Figure 2 a] We then remove the spacer around the coated nail by gently tapping it with a bone chisel at 45° concerning the longitudinal axis to avoid damage to the

coated nail [Figures 2 b-f].

If necessary, we repeat the resection of residual non-vital tissues and send samples for microbiological culture. We then curetted the bony ends of the defect to bleeding. After that, we fill the defect with cortico-cancellous autograft (harvested from the anterior iliac crest) and bone allografts (morselized, nonirradiated, frozen). Before grafting, we added 1 gram of vancomycin powder per 50cc of graft [Figure 2 g-j]. The procedure ends with an airtight membrane closure and careful soft tissue closure.

In the postoperative period, partial weight bearing with crutches is allowed. Weight-bearing progresses after the first month, depending on the bone healing of the defect and tolerance.

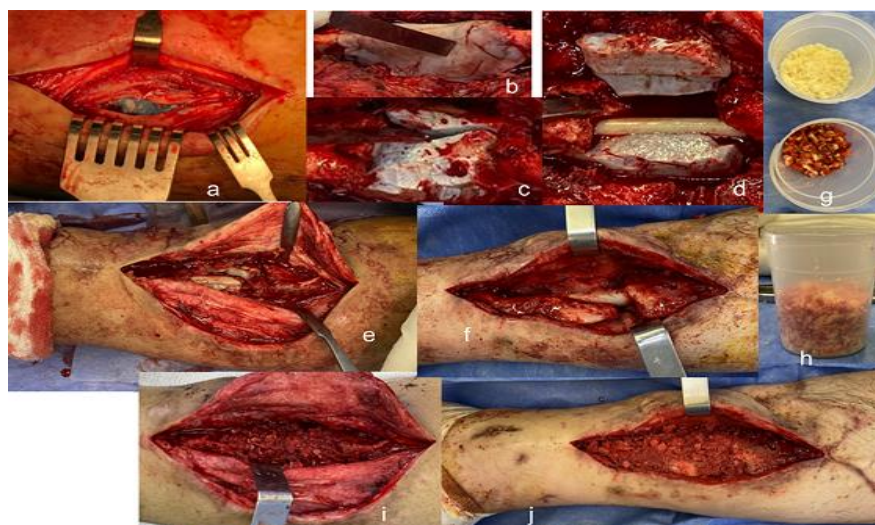


Figure 2. a: Longitudinal opening of the induced membrane, showing the stained spacer underneath. b-c-d-e-f: Resection of the spacer using chisels, gently tapping at 45° from the limb axis. In images d-e, fragmentation of the spacer is observed (in two different patients). Note that in none of the cases is the cement-coated nail damaged. g: Preparation of the auto-allograft by measuring its proportions. h: Mixing of the allografts with the vancomycin powder before grafting. i-j: Intraoperative images of the defect grafting in two different patients

Discussion

In this technical note, we present our technique for making, placing, and removing the spacer around an ATB-cement-coated rigid nail using the induced membrane technique. While the use of intramedullary nails for temporary or definitive fixation in the first stage of the IMT has been reported,^{4,5} detailed guidance on spacer placement or removal remains limited. Hoit et al.⁷ describe the placement of the spacer in two half-circumferential pieces to facilitate its extraction in the second stage. However, we contend that constructing it as a single block offers certain advantages, including enhanced structural integrity and reduced risk of cement fragmentation. Moreover, individual pieces simplify the overlapping of bone defects, streamlining grafting in the second stage and preventing graft creep when the patient stands or walks.

Furthermore, we find dyeing the spacer with methylene blue during the first stage to be a valuable strategy for differentiating it from the nails' cement, the bone defect's ends, and the surrounding tissue during extraction.⁶ Indeed, the described removal technique preserves the cement nail coating and, more importantly, in our experience, does not compromise the induced membrane, thereby safeguarding subsequent bone healing.

Herein, we describe the use of gentamicin-cement-coated rigid nails in the first stage of the IMT. Antibiotic-cement-coated nails have been used for many years in treating long bone infections, offering benefits such as dead space obliteration and targeted ATB delivery to the infection site, avoiding systemic toxicity.⁸⁻¹⁰ In the IMT, both the ATB-coated nail and spacer fulfill this role. By incorporating gentamicin within the nail and vancomycin in the spacer, we ensure comprehensive coverage against both gram-positive and gram-negative microorganisms.¹¹ Additionally, using rigid and locked nails with a single-piece spacer imparts necessary mechanical stability crucial for infection control and bone healing.^{5,8-10} This enhanced stability allows full weight bearing between stages and has enhanced and accelerated patients' return to daily activities after the second stage.¹²

The outcomes using this implant have been widely reported in treating chronic osteomyelitis and infected nonunion, showing lower reoperation rates and shorter operative times than those custom-made in the operation room.⁸⁻¹⁰ Implementing this technique in 11 consecutive patients, comprising seven tibial and four femoral infected bone defects with a length defect of 6.23cm (range 3.5-12), yielded promising outcomes. Following both stages, all patients could be fully weight-bearing without assistance and showed bone healing at the end of the follow-up.

The limitations of this technical note stem from representing the initial experience of a single surgical team

conducted in a limited number of cases. Its strengths lie in providing a detailed and reproducible account of some modifications to a well-established technique, such as IMT. It is the first to detail the step-by-step placement and removal of the cement spacer around a gentamicin-cement-coated nail.

Conclusion

In summary, this technical note shows modifications to the IMT described by Masquelet for managing infected segmental bone defects. Our description may prove beneficial for surgeons using intramedullary nails in the first stage of the technique, offering a straightforward approach to placing and extracting the spacer around an ATB cement-coated nail and highlighting its potential advantages.

Acknowledgement

N/A

Authors Contribution:

German Garabano: Conceived and designed the analysis; collected the data; Contributed data or analysis; wrote the paper.

Gonzalo M. Viollaz: Contributed data; wrote the paper.

Cesar A. Pesciallo: Collected data; wrote the paper.

Declaration of Conflict of Interest: The authors do NOT have any potential conflicts of interest for this manuscript.

Declaration of Funding: The authors received No financial support for the preparation, research, authorship, and publication of this manuscript

Declaration of Ethical Approval for Study: All procedures performed in studies involving human participants were in accordance with the ethical standards of the British Hospital and/or national research committee and with the 1964 Helsinki Declaration and its later amendments or comparable ethical standards. (Project number 9908)

Declaration of Informed Consent: Informed consent was obtained from all individual participants included in the study. There is no information in the submitted manuscript that can be used to identify patients.

Germán Garabano MD ¹

Gonzalo M. Viollaz MD ²

Cesar Angel Pesciallo MD ¹

1 Orthopaedic and Trauma Surgery Department, British Hospital of Buenos Aires, Argentina

2 Orthopaedic and Trauma Surgery; and Ortho-Plastic Department, British Hospital of Buenos Aires, Argentina

References

1. Masquelet AC, Fitoussi F, Begue T, Muller GP. Reconstruction

of the long bones by the induced membrane and spongy

- autograft. *Ann de Chir Plast Esthet* 2000; 45(3):346-353.
- 2- Masquelet A, Kanakaris NK, Obert L, Stafford P, Giannoudis P V. Bone repair using the Masquelet technique. *J Bone Joint Is Masquelet technique a successful viable treatment in reconstructing large tumor bone gaps in adolescent and adult? Arch Bone Jt Surg.* 2023; 11(5):348-355.
 - 4- Pesciallo CA, Garabano G, Dainotto T, Ernst G. Masquelet technique in post-traumatic infected femoral and tibial segmental bone defects. Union and reoperation rates with high proportions (up to 64%) of allograft in the second stage. *Injury.*2021; 52(11):3471-3477. doi: 10.1016/j.injury.2021.08.031.
 - 5- Garabano G, Pesciallo CA. Definitive fixation in the first stage of the induced membrane technique for septic segmental bone defects. Why not? *J Clin Orthop Trauma.*2022;37:102089. doi: 10.1016/j.jcot.2022.102089.
 - 6- Ahmadi N. Effects of combination of BMP7, PGF, and autograft on healing of the experimental critical radial bone defect by induced membrane (Masquelet) technique in rabbit. *Arch Bone Jt Surg.*2021; 9(5):585-597. doi: 10.22038/abjs.2020.50852.2532.
 - 7- Hoit G, Kain MS, Sparkman JW, et al. The induced membrane technique for bone defects: Basic science, clinical evidence, and technical tips. *OTA Int.* 2021; 4(2 Suppl):e106 (1-5). doi: 10.1097/OI9.000000000000106.
 - 8- Garabano G, Pereira S, Alamino LP, et al. Antibiotic cement-
Surg Am. 2019; 101(11):1024–1036. doi: 10.2106/JBJS.18.00842.
 - 3- Sharma A, Sharma A, Tomar S, Mishra A, Kashyap A, Maini L. coated rigid locked nail in infected femoral and tibial nonunion. Reoperation rates of commercial versus custom-made nails. *Injury.*2023;54 Suppl 6:110650. doi: 10.1016/j.injury.2023.02.033.
 - 9- Walter N, Rupp M, Kruckel J, Alt V. Individual and commercially available antimicrobial coatings for intramedullary nails for the treatment of infected long bone non-unions – a systematic review. *Injury.*2022;53 Suppl 3:S74-S80. doi: 10.1016/j.injury.2022.05.008.
 - 10- Lopas LA, Albertson S, Solomon E, et al. Outcomes of various antibiotic cement-coated intramedullary implants on the treatment of long bone septic nonunion. *J Orthop Trauma.*2022; 36(2):44-50. doi: 10.1097/BOT.0000000000002215.
 - 11- Metsemakers WJ, Morgenstern M, Senneville E, et al. General treatment principles for fracture-related infection: recommendations from an international expert group. *Arch Orthop Trauma Surg.*2020; 140(8):1013-1027. doi: 10.1007/s00402-019-03287-4.
 - 12- Ayoub G, Lemonne F, Kombate NK, Bakriga B, Yaovi Edem J, Andre-Pierre Max U. Interest of nailing associated with the Masquelet technique in reconstruction of bone defect. *J Orthop.*2019;20:228-231. doi: 10.1016/j.jor.2019.12.014.