

RESEARCH ARTICLE

Effect of Axillary Radiograph Rotation and Medial Scapular Visualization on Glenoid Retroversion Measurement

Liam T. Kane, MD; Alayna Vaughan, MD; Surena Namdari, MD, MSc; Eitan Kohan, MD

Research performed at Rothman Orthopaedic Institute, Thomas Jefferson University Hospitals, PA, USA

Received: 17 June 2023

Accepted: 26 March 20214

Abstract

Objectives: Axillary radiographs enable the measurement of glenoid retroversion, which is associated with worsened clinical outcomes and glenoid loosening following total shoulder arthroplasty. Due to the variability in radiographic technique, this study aims to determine if the accuracy of retroversion measured by axillary radiograph is affected by 1) scapular rotation and/or 2) proper visualization of the medial scapula.

Methods: Using five cadaveric scapulae, investigators obtained axillary radiographs in true neutral position as well as in 10° and 20° of anterior and posterior rotation. For each radiograph, two fellowship trained shoulder surgeons measured glenoid retroversion with complete visualization of the scapula (Technique 1) and with visualization limited to the lateral half of scapula (Technique 2). The observers also measured glenoid retroversion by CT scan to use as a gold standard technique. Spearman's Rho was used to assess agreement between measurements.

Results: Average glenoid retroversion of the five scapulae assessed by CT scan was 3.8° (R: 1.5-6.9). Measurements obtained using Technique 1 demonstrated improved levels of interobserver agreement (ICC: 0.412) compared to measurements obtained with Technique 2, which demonstrated no agreement (ICC: 0.103). Scapular rotation was inconsistently associated with agreement using both techniques.

Conclusion: The reliability of glenoid retroversion measurements was limited by incomplete visualization of the medial scapular spine. When measuring retroversion to the base of the scapular spine, improved agreement and accuracy were seen with various degrees of scapular rotation.

Level of evidence: IV

Keywords: Axillary, Glenoid retroversion, Radiograph, Scapula

Introduction

Glenoid retroversion has become an important radiographic marker in the clinical management of patients with glenohumeral arthritis. The degree of glenoid retroversion and associated posterior glenoid wear has been associated with component malposition and early loosening in total shoulder arthroplasty, which are among the most common complications requiring revision surgery.¹⁻⁵ Furthermore, the magnitude of glenoid retroversion may affect the need for surgical correction as well as the type and size of glenoid component used in both anatomic and reverse shoulder arthroplasty.⁶⁻¹²

Consequently, surgical planning relies heavily on accurate assessment of glenoid morphology via preoperative imaging.

Historically glenoid retroversion has been determined using computed tomography (CT) via axial plane imaging. This is performed by measuring the angle of the line connecting the anterior and posterior edges of the glenoid relative to a line joining the midpoint of the glenoid to the medial border of the scapula (i.e. Friedman's line).¹³ Certain authors have advocated for the use of CT for accurate preoperative assessment of glenoid pathology for patients

Corresponding Author: Liam T. Kane, Rothman Orthopaedic Institute, Thomas Jefferson University Hospitals, Philadelphia, PA, USA

Email: Liamkanemd@gmail.com



THE ONLINE VERSION OF THIS ARTICLE
ABJS.MUMS.AC.IR

undergoing shoulder arthroplasty.¹⁴⁻¹⁷ Alternatively, Matsen *et al.* demonstrated that the axillary radiograph view can be a practical, reliable modality for accurately measuring glenoid retroversion that is less expensive than CT and spares patients from increased radiation exposure.¹⁸ In their study, scapulae were positioned in neutral rotation to perform axillary radiographs, which were deemed adequate if the spinoglenoid notch was clearly visible. However, there may be a high degree of variability of axillary view quality and scapular rotation relative to a neutral plane, which becomes problematic when reviewing radiographs retrospectively either for clinical or research purposes.

The goal of this study is to determine whether the accuracy of common measuring techniques are influenced by axillary radiographic variables, namely 1) scapular rotation and 2) medial scapula visualization. The determination of any such effect may provide valuable insight into the reliability of axillary radiographs for the purpose of retrospective radiograph review and preoperative glenoid retroversion assessment.

Materials and Methods

This is a bio-anatomic study involving the radiographic analysis of five cadaveric scapulae. Once obtained, all specimens were stripped of musculotendinous and soft tissue attachments. Upon gross inspection, none of the specimens demonstrated significant glenoid wear or pathology. For each scapula, a series of radiographs was performed. The scapulae were held with a Kelly clamp at the medial scapular border, just below the scapular spine. Investigators first obtained a perfect axillary radiograph with the scapula in neutral rotation by positioning the radiographic beam parallel to the plane of the scapula, with a confirmed spinoglenoid notch clearly visible on the plain film [Figure 1]. Subsequent radiographs were obtained by placing the clamp and scapula against two precut blocks of wood (10° and 20°) to obtain radiographs of the scapula rotated 10° and 20° anteriorly and posteriorly relative to the fixed position of the beam [Figure 2]. With radiographs obtained in each position, a total of five radiographs (including neutral) were completed per scapula. Finally, a CT scan was performed to provide a three-dimensional rendering of each specimen.

The radiographs were uploaded onto our institution's Picture Archiving and Communication System (PACS) and measurements were made using software Sectra UniView Version 22.1 (© Sectra AB, Sweden, 2020). Two fellowship trained shoulder surgeons measured glenoid retroversion for each radiograph (25 total) using two separate techniques. With Technique 1, the observers had complete visualization of the scapula and measured version as the angle formed between the line connecting the anterior and posterior glenoid rims and the line connecting the central glenoid to the base of medial scapular spine. With Technique 2, each observer was blinded to the medial spine with visualization limited to the lateral half of the scapula. The observers measured version relative to a line extending from the central glenoid down the presumed glenoid vault due to an inability to connect with the medial spine (see Figures I and II). With both techniques used for each radiograph, this resulted in 50 total measurements by each

observer. Finally, each observer measured glenoid retroversion for each scapula by CT scan as a gold standard technique.

Each observer was kept blinded to the specimen of each radiograph as well as to each other's measurements. Interobserver agreement was assessed by Spearman's Rho test. Correlations were determined between retroversion measurements for each scapula as well as for the full cohort using Technique 1, Technique 2, and CT scan. Strength of relationship between measurements was inferred based on the rank correlation coefficient value for each Spearman's Rho test (ICC: 0-0.3, No Agreement; ICC: 0.3-0.5, Weak Agreement; ICC: 0.5-0.7, Moderate Agreement; ICC: 0.7-1, Strong Agreement).

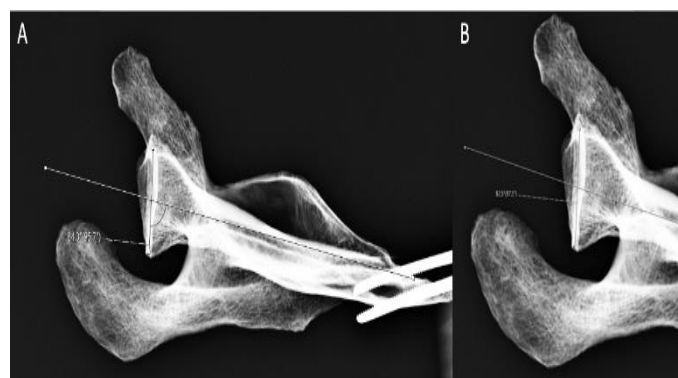


Figure 1. Glenoid retroversion measurements with scapula in neutral rotation A) Technique 1: With full visualization of the scapula, the observer measures the angle formed by a line connecting the anterior and posterior edges of the glenoid and a line from the midpoint of the glenoid to the medial base of the scapula spine. B) Technique 2: Blinded to the medial scapula, the observers measure the angle formed by the same line connecting the anterior and posterior edges of the glenoid and a line down the presumed glenoid vault

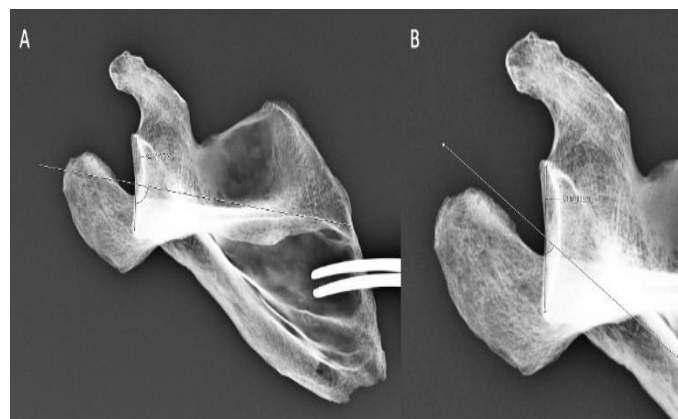


Figure 2. Glenoid retroversion measurements with scapula in 20 degree of posterior tilt. Kelly clamp and scapula placed against precut 20-degree block of wood to obtain radiograph in rotation. A) And B) demonstrate the differences between Technique 1 and Technique 2, respectively, precisely as outlined in Figure I

Results

The average glenoid retroversion of the five scapulae assessed by CT scan was 3.8° (R: 1.5-6.9). Strong interobserver agreement was seen with CT scan measurements of

retroversion for the full cohort of five scapulae (ICC: 0.935). Correlation values quantifying the agreement between measurements by technique are demonstrated in [Table 1] for Technique 1 and [Table 2] for Technique 2. The full cohort of Technique 1 radiographs demonstrated weak inter-observer agreement (ICC: 0.412) whereas the cohort of Technique 2 demonstrated no agreement (ICC: 0.103).

Technique 1 demonstrated moderate levels of inter-observer agreement with scapulae in neutral rotation (ICC: 0.622), 20° of anterior rotation (ICC: 0.644), and 20° posterior rotation (ICC: 0.693). Technique 2 only achieved weak agreement (0.332) with scapulae in 20° anterior rotation and no agreement with all other rotational positions.

Table 1. Agreement of Retroversion Measurements Obtained via Technique 1. Intraclass correlation coefficient (ICC) values quantify agreement between measurements of glenoid retroversion obtained between two observers with full visualization of medial scapular spine in each radiograph

Variable	ICC Value	Agreement
Full Cohort	0.412*	Weak Agreement
20 degrees Anterior XR	0.644**	Moderate Agreement
10 degrees Anterior XR	0.370*	Weak Agreement
Neutral	0.622**	Moderate Agreement
10 degrees Posterior XR	0.267	No True Agreement
20 degrees Posterior XR	0.693**	Moderate Agreement

Table 2: Agreement of Retroversion Measurements Obtained via Technique 2. Intraclass correlation coefficient (ICC) values quantify agreement between measurements of glenoid retroversion obtained between two observers blinded to the medial scapular spine on radiographs

Variable	ICC Value	Agreement
Full Cohort	0.103	No True Agreement
20 degrees Anterior XR	0.332*	Weak Agreement
10 degrees Anterior XR	0.224	No True Agreement
Neutral	0.051	No True Agreement
10 degrees Posterior XR	0.209	No True Agreement
20 degrees Posterior XR	0.230	No True Agreement

Correlation values for agreement between measurements obtained by CT scan versus various degrees of scapular rotation are provided in [Table 3], separated by Technique 1 and 2. Ultimately, agreement of retroversion with CT scan was largely inconsistent throughout the cohort of scapular positions measured using either technique. Technique 1 demonstrated strong agreement between CT scan and XR measurements with scapulae in 20° of anterior rotation (ICC: 0.720), moderate agreement with scapulae in 20° of posterior rotation (ICC: 0.529), and weak agreement with scapulae in 10° posterior rotation.

Technique 2 measurements were only weakly correlated with CT scan with scapulae in neutral (ICC: 0.462), 10° posterior rotation (ICC: 0.419), and 10° anterior rotation (ICC: -0.413).

Discussion

Axillary radiographs possess characteristic variables that affect quality, and understanding how these variables impact the accuracy of glenoid retroversion measurements can be important for both clinical care and research. The results of this study suggest that reliability of glenoid retroversion measurements by axillary radiographs were limited by incomplete visualization of the medial scapular spine, and that measuring version to the base of the scapular spine (rather than along the presumed glenoid vault or to the presumed medial border of the scapula) may increase accuracy in measuring glenoid version. We form this conclusion based on the significantly higher pattern of agreement seen between measurements with observers using Technique 1, in which they were able to visualize the full medial scapula and therefore could use the base of the

medial spine as a reference point. The retroversion measurements taken by observers blinded to the medial scapula (Technique 2), in which the presumed glenoid vault was used as the reference point, demonstrated significantly less inter-observer agreement and lower correlation with CT scan measurements. Therefore, clinicians should be wary of

retroversion measurements on axillary radiographs with inadequate scapular spine visualization where the medial end point of the glenoid vault is unclear. In cases of poorer quality radiographs without a fully visualized medial scapula we recommend reviewers use the scapular spine as an estimation for the medial base of the scapula.

Table 3: Agreement between Retroversion measured by CT scan and Axillary XRs with Varying Degrees of Scapular Rotation. Values are the intraclass correlation coefficients (ICC) assessing agreement between measurements obtained via gold standard CT scan and radiographs using both techniques; * indicates weak agreement; ** indicates moderate agreement; * indicates strong agreement**

	20 degrees Anterior XR	10 degrees Anterior XR	Neutral	10 degrees Posterior XR	20 degrees Posterior XR
Technique 1	0.720***	0.234	-0.036	0.438*	0.529**
Technique 2	-0.107	-0.413*	0.462*	0.419*	0.188

It is important to recognize that our conclusions were formed based on a pattern of results, with recognizable outliers present within those patterns. For example, while Technique 1 demonstrated a higher pattern of agreement, the ICC value for the cohort of radiographs still fell short of "moderate" or "strong" agreement. Additionally, there was no agreement seen between observers with the series of radiographs taken in 10 degrees of posterior rotation using Technique 1. These outliers within the patterns may be due to smaller sample size of cadavers, and our results may have been further born out with greater power. Nevertheless, we believe that the patterns of agreement seen in the study suggest that, whenever possible, clinicians utilize the medial scapular spine to guide the medial reference point to maximize likelihood of retroversion measurement accuracy.

The scapula consists of a characteristically complex and irregular bony morphology, which prioritizes the need for reliable anatomic landmarks in radiographic measurements. We suspect based on our findings that the direction of the glenoid vault, or at least the radiographic interpretation of such, has an inconsistent co-linear relationship with the base of the medial scapular spine in the axial plane. The vault has been described as a highly fluted structure in this plane with variation in points along the endosteal surface, affecting the feasibility of various implant designs and screw placement techniques in shoulder arthroplasty.¹⁹⁻²² It is reasonable to posit that the narrowness and irregularity of this structure is also what makes it difficult to find its true plane of direction, particularly with limited visualization.

It should be noted that while our study investigates factors related to two dimensional imaging of the glenoid, recent studies have highlighted three dimensional software as a potentially more accurate method for preoperative glenoid version measurements.²³⁻²⁵ Reid et al recently compared 2D versus 3D techniques and found excellent reproducibility of both techniques with no differences in degree of error observed, however did show 3D measurements returned on average greater degrees of retroversion.²⁶ We purposefully studied axillary radiographs given that they have still desirable advantages over CT and three dimensional

software by saving patients added cost and radiation, as well as providing utility for research purposes. For example, in their retrospective cohort Ko et al used axillary radiographs to demonstrate glenoid retroversion improvement in shoulders with posterior bone loss managed with asymmetric reaming or augmented glenoid components.²⁷ It has been demonstrated that without standardized patient positioning technique, which is impossible to achieve in the retrospective setting, measurements on axillary radiographs can be inconsistent across observers.²⁸ Our study highlights important characteristics that can help determine sufficiency of axillary radiographs performed without standardized technique, and gives retrospective reviewers insight on how to increase the reliability of their measurements.

This study has several limitations that warrant consideration. First, by nature of being a purely anatomic and radiographic study, there are no relevant clinical correlations to be made. Second, the sample size of scapulae utilized was determined primarily by cadaveric availability rather than a strict power analysis, which could have impacted the statistical strength of our results. It is also worth mentioning that while most glenoids being measured in the clinical setting have deformity or wear, none of the scapulae assessed in this study demonstrated deformity. Additionally, no radiographs were measured following surgical treatment, which is often a clinically relevant assessment. Instead, all of the glenoid retroversion measurements by CT scan fall within normal range of anatomic variability. However, we expect the same takeaway principles of using static reliably anatomic markers for measurement would similarly apply to glenoids with abnormal deformity. Future studies should repeat these measurements in glenoids with bony deformity and implants to determine the validity of our conclusions in those settings.

Conclusion

This study was an analysis of axillary radiographs of five cadaveric scapula to determine the effect of scapular rotation and medial scapula visualization on the reliability of glenoid retroversion measurements. The results

demonstrated that adequate medial scapular spine visualization on axillary radiographs correlated with greater levels of agreement between observers as well as with CT scan measurements, while scapular rotation demonstrated no consistent correlation with agreement. These findings should help clinicians who rely upon radiographs for glenoid retroversion measurements for preoperative planning and retrospective research applications.

Acknowledgement

Not applicable

Authors Contribution:

Study conception and design: Namdari S, Kohan E; data collection: Kane LT, Vaughan A, Kohan E; analysis and

interpretation of results: Kane LT, Vaughan A, Kohan E; draft manuscript preparation: Kane LT, Vaughan A, Namdari S, Kohan E. All authors reviewed the results and approved the final version of the manuscript.

Conflict of interest: N/A

Funding: N/A

Liam T. Kane MD ¹

Alayna Vaughan MD ¹

Surena Namdari MD, MSc ¹

Eitan Kohan MD ¹

1 Rothman Orthopaedic Institute, Thomas Jefferson University Hospitals, Philadelphia, PA, USA

References

- Bitzer A, Rojas J, Patten IS, Joseph J, McFarland EG. Incidence and risk factors for aseptic baseplate loosening of reverse total shoulder arthroplasty. *J Shoulder Elbow Surg.* 2018; 27(12):2145-2152. doi:10.1016/j.jse.2018.05.034.
- Farron A, Terrier A, Büchler P. Risks of loosening of a prosthetic glenoid implanted in retroversion. *J Shoulder Elbow Surg.* 2006; 15(4):521-526. doi:10.1016/j.jse.2005.10.003.
- Gallusser N, Farron A. Complications of shoulder arthroplasty for osteoarthritis with posterior glenoid wear. *Orthop Traumatol Surg Res.* 2014; 100(5):503-508. doi:10.1016/j.otsr.2014.06.002.
- Gerber C, Costouros JG, Sukthankar A, Fucentese SF. Static posterior humeral head subluxation and total shoulder arthroplasty. *J Shoulder Elbow Surg.* 2009; 18(4):505-510. doi:10.1016/j.jse.2009.03.003.
- Habermeyer P, Magosch P, Luz V, Lichtenberg S. Three-Dimensional Glenoid Deformity in Patients with Osteoarthritis: A Radiographic Analysis. *J Bone Joint Surg Am.* 2006; 88(6):1301-1307. doi:10.2106/JBJS.E.00622.
- Boileau P, Morin-Salvo N, Gauci MO, et al. Angled BIO-RSA (bony-increased offset-reverse shoulder arthroplasty): a solution for the management of glenoid bone loss and erosion. *J Shoulder Elbow Surg.* 2017; 26(12):2133-2142. doi:10.1016/j.jse.2017.05.024.
- Friedman RJ, Sun S, She X, Esposito J, Eichinger J, Yao H. Effects of Increased Retroversion Angle on Glenoid Baseplate Fixation in Reverse Total Shoulder Arthroplasty: A Finite Element Analysis. *Semin Arthroplasty.* 2021; 31(2):209-216. doi:10.1053/j.sart.2020.11.014.
- Hsu JE, Ricchetti ET, Huffman GR, Iannotti JP, Glaser DL. Addressing glenoid bone deficiency and asymmetric posterior erosion in shoulder arthroplasty. *J Shoulder Elbow Surg.* 2013; 22(9):1298-1308. doi:10.1016/j.jse.2013.04.014.
- Nowak DD, Bahu MJ, Gardner TR, et al. Simulation of surgical glenoid resurfacing using three-dimensional computed tomography of the arthritic glenohumeral joint: The amount of glenoid retroversion that can be corrected. *J Shoulder Elbow Surg.* 2009; 18(5):680-688. doi:10.1016/j.jse.2009.03.019.
- Sandow M, Schutz C. Total shoulder arthroplasty using trabecular metal augments to address glenoid retroversion: the preliminary result of 10 patients with minimum 2-year follow-up. *J Shoulder Elbow Surg.* 2016; 25(4):598-607. doi:10.1016/j.jse.2016.01.001.
- Sandow MJ, Tu CG. Porous metal wedge augments to address glenoid retroversion in anatomic shoulder arthroplasty: midterm update. *J Shoulder Elbow Surg.* 2020; 29(9):1821-1830. doi:10.1016/j.jse.2020.01.101.
- Sears BW, Johnston PS, Ramsey ML, Williams GR. Glenoid Bone Loss in Primary Total Shoulder Arthroplasty: Evaluation and Management. *J Am Acad Orthop Surg.* 2012; 20(9):604-613. doi:10.5435/JAAOS-20-09-604.
- Friedman RJ, Hawthorne KB, Genez BM. The use of computerized tomography in the measurement of glenoid version. *J Bone Joint Surg Am.* 1992; 74(7):1032-1037.
- Bokor DJ, O'Sullivan MD, Hazan GJ. Variability of measurement of glenoid version on computed tomography scan. *J Shoulder Elbow Surg.* 1999; 8(6):595-598. doi:10.1016/S1058-2746(99)90096-4.
- Hoenecke HR, Hermida JC, Flores-Hernandez C, D'Lima DD. Accuracy of CT-based measurements of glenoid version for total shoulder arthroplasty. *J Shoulder Elbow Surg.* 2010; 19(2):166-171. doi:10.1016/j.jse.2009.08.009.
- Nycz BT, Dominguez SR, Friedman D, et al. Evaluation of bloodstream infections, Clostridium difficile infections, and gut microbiota in pediatric oncology patients. *PLoS One.* 2018; 13(1):e0191232. doi:10.1371/journal.pone.0191232.
- Nyffeler RW, Jost B, Pfirrmann CWA, Gerber C. Measurement of glenoid version: conventional radiographs versus computed tomography scans. *J Shoulder Elbow Surg.* 2003; 12(5):493-496. doi:10.1016/S1058-2746(03)00181-2.
- Matsen FA, Gupta A. Axillary View: Arthritic Glenohumeral Anatomy and Changes after Ream and Run. *Clin Orthop Relat Res.* 2014; 472(3):894-902. doi:10.1007/s11999-013-3327-6.
- Bicknell RT, Patterson SD, King GJW, Chess DG, Johnson JA. Glenoid vault endosteal dimensions: An anthropometric

- study with special interest in implant design. *J Shoulder Elbow Surg.* 2007; 16(3):S96-S101. doi:10.1016/j.jse.2006.03.008.
20. Codsí MJ, Bennetts C, Gordiev K, et al. Normal glenoid vault screw fixation beyond the glenoid vault for fixation of glenoid implants into the scapula: An anatomic study. *J Shoulder Elbow Surg.* 2007; 16(3):S84-S89. doi:10.1016/j.jse.2006.07.009.
22. Strauss EJ, Roche C, Flurin PH, Wright T, Zuckerman JD. The glenoid in shoulder arthroplasty. *J Shoulder Elbow Surg.* 2009; 18(5):819-833. doi:10.1016/j.jse.2009.05.008.
23. Boileau P, Cheval D, Gauci MO, Holzer N, Chaoui J, Walch G. Automated Three-Dimensional Measurement of Glenoid Version and Inclination in Arthritic Shoulders. *J Bone Joint Surg Am.* 2018; 100(1):57-65. doi:10.2106/JBJS.16.01122.
24. Moineau G, Levigne C, Boileau P, Young A, Walch G, French Society for Shoulder & Elbow (SOFEC). Three-dimensional measurement method of arthritic glenoid cavity morphology: feasibility and reproducibility. *Orthop Traumatol Surg Res.* 2012; 98(6 Suppl):S139-145. doi:10.1016/j.otsr.2012.06.007.
25. Werner BS, Hudek R, Burkhart KJ, Gohlke F. The influence of anatomy and validation of a novel glenoid implant shape. *J Shoulder Elbow Surg.* 2008; 17(3):471-478. doi:10.1016/j.jse.2007.08.010.
21. Codsí MJ, Bennetts C, Powell K, Iannotti JP. Locations for three-dimensional planning on decision-making in total shoulder arthroplasty. *J Shoulder Elbow Surg.* 2017; 26(8):1477-1483. doi:10.1016/j.jse.2017.01.006.
26. Reid JJ, Kunkle BF, Greene AT, Eichinger JK, Friedman RJ. Variability and reliability of 2-dimensional vs. 3-dimensional glenoid version measurements with 3-dimensional preoperative planning software. *J Shoulder Elbow Surg.* 2022; 31(2):302-309. doi:10.1016/j.jse.2021.07.011.
27. Kevin Ko JW, Syed UA, Barlow JD, et al. Comparison of Asymmetric Reaming versus a Posteriorly Augmented Component for Posterior Glenoid Wear and Retroversion: A Radiographic Study. *Arch Bone Jt Surg.* 2019; 7(4):307-313.
28. Ho JC, Youderian A, Davidson IU, Bryan J, Iannotti JP. Accuracy and reliability of postoperative radiographic measurements of glenoid anatomy and relationships in patients with total shoulder arthroplasty. *J Shoulder Elbow Surg.* 2013; 22(8):1068-1077. doi:10.1016/j.jse.2012.11.015.