

**RESEARCH ARTICLE**

# Distal Femoral Valgus Resection Angle in Conventional Total Knee Arthroplasty - a CT Scanogram Study

Praveen L. Basanagoudar, MS, DNB, MRCS; Bhava R.J. Satishkumar, MS, DNB; Kirubakaran Pattabiraman, MS, DNB, MRCS; Dinesh Kamath, MS; Ranganadham AV, MS

Research performed at Sagar Hospital, DSI institutions, India

Received: 2 October 2022

Accepted: 12 November 2022

**Abstract**

**Objectives:** In conventional total knee arthroplasty (TKA), the distal femur valgus resection angle (DFVA) is decided either by measuring the specific resection angle for each patient on preoperative anteroposterior hip-knee-ankle (HKA) weight-bearing radiograph or using a fixed resection angle of five to seven degrees, when such facilities are not available. This study aims to measure the DVFA in TKA patients using preoperative HKA non-weight-bearing computerized tomography (CT) scanogram scout films and determine its relation with preoperative coronal plane lower-limb deformities.

**Methods:** In this retrospective radiological study, various measurements were performed on bilateral, preoperative hip-knee-ankle CT scanograms of 73 knee osteoarthritis patients who had presented for total knee replacement surgery using a standard protocol. The angle between the femoral anatomical axis and femoral mechanical axis was measured as the femoral mechanical anatomical angle (FMAA), which corresponds to the surgical DFVA. The angle between the femoral and tibial mechanical axes was measured as mechanical femorotibial angle (MFTA). The correlation between FMAA and MFTA was studied.

**Results:** The mean FMAA for the study group was 6.45° (range 3° to 11°, SD 1.17°). The MFTA for the study group ranged from 24° varus to 14° valgus. The alignment was valgus in 14.4% (n=21), varus in 84.2% (n=123), and "0 degrees" in 1.3% (n=2). With valgus coronal alignment taken as positive and varus as negative, the Pearson's correlation coefficient for MFTA with FMAA was  $r = -0.5183$  ( $p < 0.001$ ), indicating that valgus knees tended to have a smaller FMA angle and varus knees tended to have a larger FMA angle.

**Conclusion:** In the non-availability of individualized measurements, in primary TKA, we recommend setting DFVA as five degrees for valgus deformities, six degrees for mild/moderate varus deformities (MFTA <15°) and seven degrees for severe varus deformities (MFTA > 15°).

**Level of evidence:** III

**Keywords:** CT study, Distal femur, Knee arthroplasty, Knee osteoarthritis, Resection angle, Valgus cut angle

**Introduction**

Total knee arthroplasty (TKA) is one of the most successful orthopedic procedures performed in patients with end-stage knee osteoarthritis for alleviating the symptoms and correcting deformity, with satisfactory long-term survival rates. Common causes for failure of TKA include aseptic loosening, malalignment, instability, and infection.<sup>1</sup> Proper limb alignment and implant component positioning are critical to the long-term survivorship of TKA.<sup>2</sup> Incorrect mechanical alignment is related to early implant wear, loosening, and prosthesis

instability.<sup>1, 3</sup> Proper mechanical alignment of the lower limb is achieved by appropriate bone cuts and soft tissue balancing. To achieve mechanical alignment, the distal femur and proximal tibia are cut at right angles to their mechanical axes.<sup>4,5</sup> Postoperative alignment within a range of +/- 3 degrees (coronal "safe zone") from the mechanical axis is aimed for, which is associated with better outcomes.<sup>2,6,7,8</sup> However, some clinical studies could not correlate better alignment with better implant survivorship on long-term follow-up.<sup>4,5,9,10</sup> Despite the

**Corresponding Author:** Praveen L. Basanagoudar, Sagar Hospitals, India

Email: praveen.ortho@gmail.com



THE ONLINE VERSION OF THIS ARTICLE  
ABJS.MUMS.AC.IR

controversy, one of the goals of conventional TKA is to aim for coronal “safe zone” postoperative lower limb alignment by reducing the outliers for postoperative mechanical axis correction. This is achieved in TKA by time-tested conventional methods and, more recently, by assistive devices like computer navigation, patient-specific instrumentation, or robotics.<sup>11-13</sup>

In conventional TKA using the mechanical alignment method, an intramedullary (IM) guide is used for performing the distal femoral cut. To achieve a distal femur cut perpendicular to the femoral mechanical axis, the distal femoral cutting guide over the IM guide is set to five or six degrees of valgus. This method assumes that the femoral anatomical axis is five or six degrees valgus in relation to the femoral mechanical axis, which may be appropriate for the majority of the patients.<sup>14,15</sup> Using a fixed valgus angle may result in either mal-alignment of the femoral component or outliers in the correction of coronal plane deformity outside the acceptable range, in 10% to as high as 30 % of patients undergoing TKA.<sup>16-18</sup>

Studies on healthy non-arthritic populations have found the angle between the femoral mechanical axis and femoral anatomical axis (FMAA) to be in the range of 5.1 to 5.8 degrees.<sup>19,20</sup> Ideally, pre-operative weight-bearing anteroposterior long leg Hip-Knee-Ankle radiographs (HKA-WBR) need to be done in each patient to determine FMAA, which can be used as distal femur valgus resection angle (DFVA) or valgus cut angle (VCA) for that specific patient. However, considerable variations in FMAA values

in the knee osteoarthritis population have been noted. A review of the recent literature shows evidence in favor of patient-specific DFVA with a significant decrease in the percentage of postoperative outliers for mechanical axis correction [Table 1].

In the Indian setup, many hospitals do not have facilities for HKA-WBR to determine preoperative patient-specific FMAA. Many surgeons rely on fixed FMAA/ DFVA/VCA values of either five or six degrees for all TKAs. While weight-bearing lower limb radiograph is considered the gold standard, Computed tomography (CT) scanograms are also used to calculate FMAA. CT scanograms are quite popular, given lower radiation exposure, speed of data acquisition, and convenient supine positioning.<sup>11,21</sup> CT values were reported to be more accurate and reproducible than the plain radiographs.<sup>21, 22</sup> Previous studies in the Indian population using HKA-WBR have found wide variation in FMAA values ranging as low as 1.4 to as high as 11.4 degrees, the mean varying from 5.9 to 6.9 degrees.<sup>17, 23</sup> Our study aims to assess the natural distribution of the FMAA in an Indian osteoarthritic population presenting for TKA, using preoperative supine CT scanograms and to find any correlation between FMAA and the preoperative lower limb coronal plane deformity as measured by mechanical femorotibial angle (MFTA).

**Table 1. Literature review of studies involving the measurement of FMAA / DFVA/ VCA**

Author,Year Country	Number OA Knees / Patients	Mean FMAA degrees	SD	Range (in degrees)	Study method	Recommended DFVA	Other significant findings of study
Kharwadkar, 14 2005, UK	83 patients	5.4°	0.9°	3.3 –7.6	CT Scan scout film	Fixed	FMAA 5 or 6° is safe for uncomplicated TKA
Bardakos 16 2007, USA	174 Knees 141 patient	5.1°	1.4°	2 -10	Long leg radiograph	Variable	Atleast 30% outliers for VCA < 5° or > 6°, VCA varies with hip offset
Deakin 30 2012, UK	174 knees	5.7°	1.2°	2 -9	HKA-WBR	Variable	FMAA varies with sex and preoperative MFTA
Rezende 29 2013, Brazil	99 knees 66 patients	6.05°	1.3°	3 -9	HKA-WBR	Variable	19.7% outliers for FMAA 5 or 6 degrees
Mullaji 23 2013, India	503 knees 393patient	6.9°	1.6°	7.6 -11.4	HKA-WBR	Variable	Preoperative deformity has significant correlation to VCA
Costa 15 2014, Brazil	107 knees 79 patients	6.3°	NA	4.2 -8.6	HKA-WBR	Fixed	FMAA varies inversely with neck shaft angle. Mean coronal plane deformity (MFTA) was less.

Table 1. Continued

Jingjit <sup>26</sup> 2014 Thailand	80 knees 50 patients	6.46°	1.26°	4-10	HKA-WBR	Variable	In 15%, FMAA either < 5° or > 7°. VCA 7° recommended for varus deformity
Curtin <sup>27</sup> 2014, USA	250 knees	5.35°	NA	1-10	HKA-WBR	Variable	Fixed resection angle could result in malalignment in 10% of patients.
Lee <sup>18</sup> 2015, Taiwan	952 knees 526 patient	7°	2°	4-14	HKA-WBR	Variable	DFVA outliers outside 5° + / - 2° were 32%
Meric <sup>28</sup> 2015, USA	13,546 knees	5.7°	2.3°	1-16	CT Scan 3D Reconstruct	Variable	13.8% outliers for DFVA
Palanisami <sup>17</sup> 2015, India	227 limbs	5.9°	1.4°	1.8-10.7	HKA-WBR	Variable	VCA varies with offset, femoral bow & preoperative deformity.
Present study, 2022, India	73 patients 146 limbs	6.45°	1.2°	3-11	HKA-CTS	Variable	FMAA correlates with MFTA

## Materials and Methods

The local research ethics committee was approached and considered that institutional review board approval (EC/NEW/INST/2021/1922) for this retrospective radiological study was unnecessary. The compliance with ethical standards in the 1964 Declaration of Helsinki was followed. All patients who presented to our institute with end-stage osteoarthritis for TKA between August 2010 and May 2018 and had undergone a preoperative hip-knee-ankle CT scanogram (HKA-CTS) scout film of the lower limb, preoperatively, after informed consent, were included in this study. HKA-CTS was performed by a set protocol. The patient assumed a supine position with the feet internally rotated by five degrees (to bring the intercondylar line parallel to the plane of the detector). The scan table was raised so the vertical height positioning light was midway through the patient's leg before entering the CT scanner (Siemens Somatom Definition AS) to obtain an HKA-CTS of both lower limbs. Antero-posterior scanning was performed from the highest part of the iliac crests to the feet, including the hip, knee, and ankle joints. These radiographs were then stored in the Synapse (Fujifilm) Picture Archiving Communications System, and the FMAA and MFTA were measured for each limb, respectively [Figure 1, Figure 2].

All angles and line measurements for the HKA-CTS were done using onscreen cursors by the lead author (PB). The hip, knee, and ankle centers were defined as the center of the femoral head, the apex of the intercondylar notch, and the center of the talar dome, respectively. The femoral head center was identified using the Mose circle.<sup>24</sup> the line joining the hip and knee centers was defined as the femoral mechanical axis, and the line joining the knee and ankle centers were defined as the tibial mechanical axis. The femoral anatomic axis was described as a straight line joining the mid-diaphyseal path of the femur to the knee center. The FMAA was defined as the angle between the femoral anatomic and mechanical axes. The MFTA was defined as the angle between the femoral and tibial mechanical axes. The FMAA and MFTA were measured in

146 lower limbs per the above protocol during the study period.

On a randomly selected subset of 30 HKA-CTS, FMAA and MFTA were measured again by the set protocol on a different occasion by the lead author to determine intra-observer variations, if any. On the same subset, the measurements were performed by another author (DK) to determine inter-observer variations, if any.

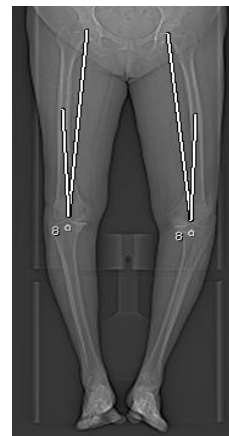


Figure 1. Preoperative CT Scanogram showing hip centre, knee centre and femoral mechanical axis, femoral anatomical axis and measurement of FMAA, in a patient undergoing bilateral total knee replacement surgery

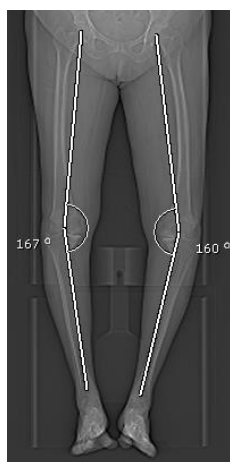


Figure 2. Preoperative CT Scanogram showing the femoral mechanical axis, tibial mechanical axis and measurement of MFTA in the same patient

**Results**

During the study period, 300 patients underwent TKA, among which 79 patients who had preoperative HKA-CTS were included. Six patients were further excluded for the following reasons: different race Afro-Caribbean (two), underwent visco-supplementation (one) or had surgery canceled due to nonmedical reasons (three). This left 73 patients who underwent TKA (27 bilateral TKA) with 146 HKA-CTS for final analysis. There were 44 women and 29 men, with a mean age of 62.3 years (range 44–81 years). The mean FMAA for the study group was 6.45° (range 3° to 11°, SD 1.17°) [Table 2]. The 95% confidence interval of the sample was 6.26° - 6.64°. The median and mode for the cohort were six degrees. The mean FMAA for the males and females were 6.48° + 0.82° and 6.43°+1.35° respectively. There was no statistically significant difference between the FMAA for males and females or between the right and left knees (P=0.15) (2 sample T-test). The FMAA variation followed a Gaussian distribution pattern [Figure 3].

**Table 2.** Limits, characters of the clusters, FMAA measurements and numbers in each subgroup for the study cohort

MFTA	MFTA	Number	Lowest	Highest	Median	FMAA distribution		
Sub	range	of limbs	FMAA	FMAA	FMAA	(Numbers)		
groups						< 6°	6°	> 6°
Varus	16 to	14	6°	9°	7.5°	0	2	12
>15°	24°							
Varus	0 to	111	4°	11°	6°	8	56	47
≤15°	15°							
Valgus	2 to	21	3°	8°	5°	14	4	3
	16°							

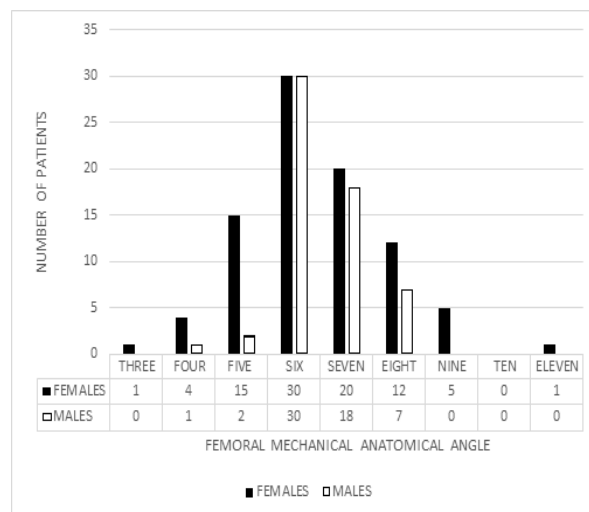


Figure 3. Histogram showing distribution of FMAA for study cohort

The MFTA for the study group ranged from 24° varus to 14° valgus. The coronal alignment was valgus in 14.4% (n=21) and varus in 85.6% (n=125) (including two cases with “0” degrees) [Figure 4]. The visual analysis identified three sub-groups in MFTA measurements; cluster analysis further identified the boundaries of each sub-group; severe varus (16°-24°), mild/moderate varus (0°-15°), and valgus [Table 2].

The median FMAA was higher for the severe varus group (7.5°) and lower for the valgus group (five degrees) when compared to the mild/moderate varus group (six degrees). The proportion of patients having an FMAA greater than or less than the medial value of six degrees in each group varied, with the majority of the severe varus group having an FMAA of seven or eight degrees and the majority of the valgus group having an FMA angle of fewer than six degrees. With valgus coronal alignment taken as positive and varus as negative, the

Pearson's correlation coefficient for MFTA with FMAA was -0.5183 (P<0.001), indicating that valgus knees tended to have a smaller FMA angle and varus knees tended to have a larger FMAA [Figure 5].

The inter-observer comparison showed an intra-class correlation coefficient (ICC) of 0.898 for the FMAA and 0.972 for the MFTA. Intra-observer and inter-observer variations of FMAA varied within one degree in 29 and 28 HKA-CT, respectively. There was a variation of 2° in one intra-observer reading and two inter-observer readings for FMAA. Intra-observer and inter-observer variations of the MFTA angle were within one degree in 29 and 27 HKA-CT respectively. There was a variation of 2° in one intra-observer reading and two inter-observer readings for MFTA. One patient with severe varus knee deformity and knee joint subluxation showed an inter-observer variation of 3°.

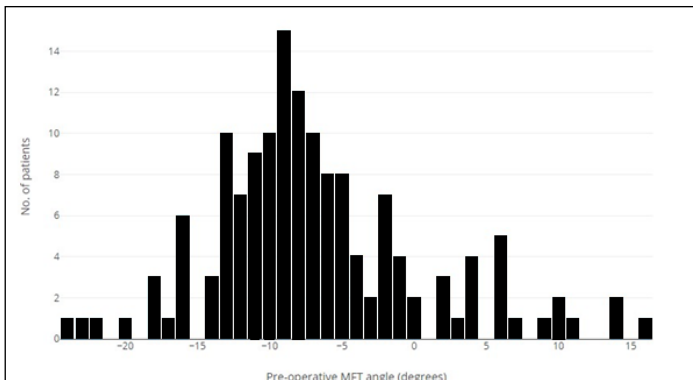


Figure 4. Histogram showing distribution of pre-operative MFTA for study cohort

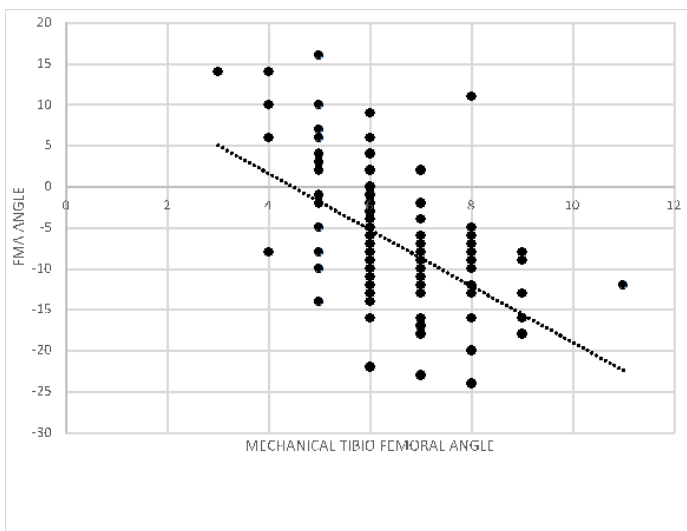


Figure 5. Correlation between FMAA and MFTA for study cohort

## DISCUSSION

Restoration of a neutral mechanical axis has been the long-standing principle of TKA over the last four decades. The post-operative alignment following TKA should be within three degrees of a neutral mechanical axis called the “coronal safe zone.”<sup>3,5,25</sup> Although many studies have shown a weak relationship between coronal alignment and component survivorship,<sup>3,4,8,9</sup> until further evidence suggests a more accurate method to determine the ideal postoperative alignment, a neutral mechanical axis should be considered as the “standard” and “aimed for” as the alignment target.<sup>4,25</sup>

Our study cohort, although comparable in size with earlier studies<sup>14,15,26,27</sup> but less compared to more recent studies,<sup>17,18,23,28,29</sup> revealed many similarities with respect to wide distribution pattern, mean FMAA, and range, as well as its correlation with MFTA, when compared to reviewed literature using various panoramic hip-knee-ankle (HKA-WBR/ HKA-CTS) and CT imaging modalities, the salient features, and differences of which have been summarized [Table 1].

The mean FMAA in the current study was 6.45 (SD 1.2) with 47.3% outliers to the “fixed DFVA rule” if we include all FMAA measurements of five and six degrees. These outliers will reduce to 32.9% if we include all limbs with FMAA measurements of six and seven degrees. The “DFVA outliers” for the “fixed VCA rule” in other studies ranged from as low as 10% to as high as 32% of the study groups.<sup>26-29</sup> All studies with either mean FMAA > 6 or a standard deviation  $\geq 1.2$  showed “significant outliers” to the “fixed DFVA rule” (five or six degrees) when data for both FMAA as well as SD were available. This observation holds good for all studies recommending a variable DFVA, except the study by Bardakos<sup>16</sup> *et al.*, where the mean FMAA was 5.6 degrees, and SD was 1.0.

The key finding in the current study is the relationship between FMAA and MFTA, despite the non-weight-bearing nature of supine HKA-CTS. Although Costa<sup>15</sup> *et al.* did not observe this correlation, our study is in agreement with the previous studies<sup>17,23,30</sup> which have recognized this significant correlation and have recommended rules of thumb for varying the DFVA.<sup>30</sup>

Supine CT scanograms undertaken in the current study may not affect the FMAA, as the full-length femoral image is not affected by weight-bearing status. However, the supine preoperative coronal plane deformity may be underrepresented for the varus / valgus subgroups in the current study, considering a previous study by Brouwer<sup>31</sup> *et al.* They found an average of two degrees more varus deviation in the standing than in the supine position. Another study by Gbejuade<sup>32</sup> *et al.* Comparing weight-bearing radiographs and supine CT Scanograms found a good agreement in the mechanical axis between the two imaging modalities in non-deformed knees. In cases of malaligned limbs, using a CT Scanogram led to under-detection of the malalignment compared to the “gold standard” HKA-WBR.

Despite this limitation of supine HKA-CT scout films, our study found a significant correlation between FMAA and supine preoperative coronal plane deformity, with increasing mean FMAA values from the severe valgus to severe varus deformity spectrum [Figure 5]. This assumes relevance for most surgeons worldwide performing conventional TKA, where facilities for pre-operative HKA-WBR, or HKA-CT, or navigation techniques do not exist. With the growing evidence of literature supporting the use of variable DFVA for conventional TKA, the results of the current study do support the “rule of thumb” for the different subgroups recommended by Deakin<sup>30</sup> *et al.* In the current study, the lower median FMAA for severe valgus group and higher median FMAA for severe varus group is in agreement with recommendations from earlier studies.<sup>23,26,30</sup>

A fixed valgus resection angle of five or six degrees was found safe in some studies,<sup>14,15</sup> where the mean FMAA for the whole study group was either lower than 5.5 degrees in



uncomplicated TKA<sup>14</sup> or when the mean preoperative coronal plane deformity was less than eight degrees for both varus and valgus subgroups.<sup>15</sup> Our study revealed that the median FMAA and mode is six. Besides, the mean FMAA for the mild to moderate varus subgroup is six. This may explain why the recommended safe VCA of five or six degrees may be appropriate for uncomplicated TKA with mild to moderate deformities.<sup>14,15</sup> However, the recommended fixed valgus resection angle of five or six degrees may not apply to TKA patients with severe varus (MFTA  $\geq 16^\circ$ ) or valgus deformities, who may be the outliers to the generally recommended five or six degrees valgus resection angle thumb rule for uncomplicated TKA.

Ranawat<sup>33</sup> *et al.* have recommended adjusting the FMAA between three to five degrees while performing valgus deformity corrections during conventional TKA.<sup>33</sup> As a thumb rule, the valgus resection angle should not be more than five degrees (the mean FMAA in the valgus subgroup) for valgus knees when preoperative FMAA and MFTA measurements are not available.

A bone cut of five, six, and seven degrees to the anatomical axis of the femur in the study population would fail to achieve a cut within the +/- one degree perpendicular to the mechanical axis of the femur in 44%, 21% and 20 % of the patients respectively. Considering the male and female subgroups of the populations, a bone cut of five, six, or seven degrees to the anatomical axis of the femur in the study population would fail to achieve a cut within the +/- one degree perpendicular to the mechanical axis of the femur in 43.1%, 13.8 % and 5.2% percent of the male subgroup and 44.31%, 26.13% and 29.54% of the female subgroup respectively [Table 2].

In the valgus group of 21 HKA-CT scanograms, a distal femoral valgus cut of four, five, and six degrees valgus to the anatomical axis of the femur would fail to achieve a cut within the +/- one degree perpendicular to the mechanical axis of the femur in 29 %,14% and 29% of valgus knees respectively. The median FMAA for this group is five degrees.

In the mild to moderate varus deformity ( $0^\circ$  to  $15^\circ$  varus) group of 111 patients, a distal femoral valgus cut at five, six, and seven degrees to the anatomical axis of the femur in this group would fail to achieve a cut within the +/- one degree perpendicular to the mechanical axis of the femur in 44.4%, 16.21% and 11% of the individuals, with the median FMA angle of this group being six degrees.

In the severe varus deformity ( $16^\circ$  to  $24^\circ$  varus) group of 14 patients, a distal femoral valgus cut at six, seven, and eight degrees to the femoral anatomical axis would give a perpendicular bone cut to the femoral mechanical axis at 50%, 86% and 86 % of the individuals, with the median FMA angle of this group being 7.5 degrees.

This analysis is likely to help the surgeons performing conventional total knee replacement arthroplasty to reduce the number of outliers for mechanical axis correction by

preoperative planning on less expensive HKA-CTS scout films when facilities for more expensive, labor or time-intensive equipment like computer navigation, patient-specific instrumentation and robotics do not exist.<sup>13</sup>

Several limitations in this study must be acknowledged. This retrospective study captures radiological data on a supine HKA-CTS scout film in a predominantly South Indian ethnic population with end-stage osteoarthritis knees undergoing TKA in a hospital setting where facilities for the 'gold standard' HKA-WBR were not available. One of the possible weaknesses of our study is that it does not measure the post-operative coronal plane lower limb alignment. Still, based on previous similar studies,<sup>17, 34</sup> it is expected that choosing the better DFVA resection for the femur will result in a better overall post-operative coronal plane deformity correction and a better long leg alignment.<sup>34</sup> This study does not assess any correlation to functional or postoperative outcomes following TKA. The study by design is limited to TKA patients of Indian ethnicity. Hence, despite their similarities to previous studies, the results may not be fully applicable to other ethnic populations. The supine HKA-CTS measures two parameters, the FMAA and MFTA. Since FMAA is limited to the femur only, the effect of weight bearing may not affect its measurement. However, the coronal plane deformity (MFTA) may be underreported on the non-weight bearing HKA-CTS images.

## CONCLUSION

In conclusion, for the majority of knee surgeons performing primary TKA by mechanical alignment method, in the non-availability of individualized DFVA measurements either pre-operatively or intra-operatively, we recommend setting DFVA at five degrees for valgus deformities, six degrees for mild/moderate varus deformities (MFTA  $\leq 15^\circ$ ) and seven degrees for severe varus deformities.

## Acknowledgement

Department of Radiology, Sagar Hospitals, Bangalore

**Conflict of interest:** The authors declare that they do NOT have conflict of interest for this manuscript.

**Funding:** The authors received NO financial support for the preparation, research, authorship and publication of this manuscript.

Praveen L. Basanagoudar MS, DNB, MRCS <sup>1</sup>  
Bhava R.J. Satishkumar MS, DNB <sup>2</sup>  
Kirubakaran Pattabiraman MS, DNB, MRCS <sup>2</sup>  
Dinesh Kamath MS <sup>1</sup>  
Ranganadham AV MS <sup>3</sup>

<sup>1</sup> Department of Orthopedics, Sagar Hospitals , Bangalore, India

2 Department of Orthopaedics, BRJ & MAK hospital, Coimbatore, Tamil Nadu, India

3 Sree Orthopedic Clinic, Behrampore, Orissa, India

## REFERENCES

- Sharkey PF, Hozack WJ, Rothman RH, Shastri S, Jacoby SM. Insall Award paper. Why are total knee arthroplasties failing today? *Clin Orthop Relat Res.* 2002 ;( 404):7-13. doi:10.1097/00003086-200211000-00003
- Lotke PA, Ecker ML. Influence of positioning of prosthesis in total knee replacement. *J Bone Joint Surg Am.* 1977; 59(1):77-79.
- Fang DM, Ritter MA, Davis KE. Coronal alignment in total knee arthroplasty: just how important is it? *J Arthroplasty.* 2009; 24(6 Suppl):39-43. doi:10.1016/j.arth.2009.04.034
- Jeffery RS, Morris RW, Denham RA. Coronal alignment after total knee replacement. *J Bone Joint Surg Br.* 1991; 73(5):709-714. doi:10.1302/0301-620X.73B5.1894655
- Parratte S, Pagnano MW, Trousdale RT, Berry DJ. Effect of postoperative mechanical axis alignment on the fifteen-year survival of modern, cemented total knee replacements. *J Bone Joint Surg Am.* 2010; 92(12):2143-2149. doi:10.2106/JBJS.I.01398
- Lombardi AV Jr, Berend KR, Ng VY. Neutral mechanical alignment: a requirement for successful TKA: affirms. *Orthopedics.* 2011; 34(9):e504-e506. doi:10.3928/01477447-20110714-40
- Choong PF, Dowsey MM, Stoney JD. Does accurate anatomical alignment result in better function and quality of life? Comparing conventional and computer-assisted total knee arthroplasty. *J Arthroplasty.* 2009; 24(4):560-569. doi:10.1016/j.arth.2008.02.018
- Bargren JH, Blaha JD, Freeman MA. Alignment in total knee arthroplasty. Correlated biomechanical and clinical observations. *Clin Orthop Relat Res.* 1983 ;( 173):178-183.
- Matziolis G, Adam J, Perka C. Varus malalignment has no influence on clinical outcome in midterm follow-up after total knee replacement. *Arch Orthop Trauma Surg.* 2010; 130(12):1487-1491. doi:10.1007/s00402-010-1064-9
- Bellemans J. Neutral mechanical alignment: a requirement for successful TKA: opposes. *Orthopedics.* 2011; 34(9):e507-e509. doi:10.3928/01477447-20110714-41
- Mohanlal P, Jain S. Assessment and validation of CT scanogram to compare per-operative and post-operative mechanical axis after navigated total knee replacement. *Int Orthop.* 2009; 33(2):437-439. doi:10.1007/s00264-008-0639-3
- Bäthis H, Perlick L, Tingart M, Lüring C, Zurakowski D, Grifka J. Alignment in total knee arthroplasty. A comparison of computer-assisted surgery with the conventional technique. *J Bone Joint Surg Br.* 2004; 86(5):682-687. doi:10.1302/0301-620x.86b5.14927
- Thienpont E, Fennema P, Price A. Can technology improve alignment during knee arthroplasty? *Knee.* 2013; 20 Suppl 1:S21-S28. doi:10.1016/S0968-0160(13)70005-X
- Kharwadkar N, Kent RE, Sharara KH, Naique S. 5 degrees to 6 degrees of distal femoral cut for uncomplicated primary total knee arthroplasty: is it safe? *Knee.* 2006; 13(1):57-60. doi:10.1016/j.knee.2005.07.001
- Costa MA, Mozella Ade P, Cobra HA. Distal femoral cut in total knee arthroplasty in a Brazilian population. *Rev Bras Ortop.* 2015; 50(3):295-299. doi:10.1016/j.rboe.2015.05.007
- Bardakos N, Cil A, Thompson B, Stocks G. Mechanical axis cannot be restored in total knee arthroplasty with a fixed valgus resection angle: a radiographic study. *J Arthroplasty.* 2007; 22(6 Suppl 2):85-89. doi:10.1016/j.arth.2007.04.018
- Palanisami D, Iyyampillai G, Shanmugam S, Natesan R, S R. Individualised distal femoral cut improves femoral component placement and limb alignment during total knee replacement in knees with moderate and severe varus deformity. *Int Orthop.* 2016; 40(10):2049-2054. doi:10.1007/s00264-016-3123-5
- Lee CY, Huang TW, Peng KT, Lee MS, Hsu RW, Shen WJ. Variability of distal femoral valgus resection angle in patients with end-stage osteoarthritis and genu varum deformity: Radiographic study in an ethnic Asian population. *Biomed J.* 2015; 38(4):350-355. doi:10.4103/2319-4170.151030
- Hsu RW, Himeno S, Coventry MB, Chao EY. Normal axial alignment of the lower extremity and load-bearing distribution at the knee. *Clin Orthop Relat Res.* 1990 ;( 255):215-227.
- Tang WM, Zhu YH, Chiu KY. Axial alignment of the lower extremity in Chinese adults. *J Bone Joint Surg Am.* 2000; 82(11):1603-1608. doi:10.2106/00004623-200011000-00014
- Farrar MJ, Newman RJ, Mawhinney RR, King R. Computed tomography scan scout film for measurement of femoral axis in knee replacement. *J Arthroplasty.* 1999; 14(8):1030-1031. doi:10.1016/s0883-5403(99)90021-9
- Henckel J, Richards R, Lozhkin K, et al. Very low-dose computed tomography for planning and outcome measurement in knee replacement. The imperial knee protocol. *J Bone Joint Surg Br.* 2006; 88(11):1513-1518. doi:10.1302/0301-620X.88B11.17986
- Mullaji AB, Shetty GM, Kanna R, Vadapalli RC. The influence of preoperative deformity on valgus correction angle: an analysis of 503 total knee arthroplasties. *J Arthroplasty.* 2013; 28(1):20-27. doi:10.1016/j.arth.2012.04.014
- Mose K. Methods of measuring in Legg-Calvé-Perthes disease with special regard to the prognosis. *Clin Orthop Relat Res.* 1980 ;( 150):103-109.
- Abdel MP, Oussedik S, Parratte S, Lustig S, Haddad FS. Coronal alignment in total knee replacement: historical review, contemporary analysis, and future direction. *Bone Joint J.* 2014; 96-B (7):857-862. doi:10.1302/0301-620X.96B7.33946.
- Jingjit W, Poomcharoen P, Limmahakhun S, Klunklin K, Leerapun T, Rojanasthien S. Femoral mechanical-anatomical angle of osteoarthritic knees. *J Med Assoc Thai.* 2014; 97(12):1314-1318.
- Rezende FC, de Castro Ferreira M, Debieux P, da Silveira Franciozi CE, Luzo MVM, Carneiro M. Is it safe the empirical distal femoral resection angle of 5° to 6° of valgus in the Brazilian geriatric population? *Rev Bras Ortop.* 2013;

- 48(5):421-426. doi:10.1016/j.rboe.2012.08.009
28. Curtin B, Fehring TK, Lauber J. Errors in knee alignment using fixed femoral resection angles. *Orthopedics*. 2014; 37(7):e644-e648. doi:10.3928/01477447-20140626-56
29. Meric G, Gracitelli GC, Aram LJ, Swank ML, Bugbee WD. Variability in Distal Femoral Anatomy in Patients Undergoing Total Knee Arthroplasty: Measurements on 13,546 Computed Tomography Scans. *J Arthroplasty*. 2015; 30(10):1835-1838. doi:10.1016/j.arth.2015.04.024
30. Deakin AH, Basanagoudar PL, Nunag P, Johnston AT, Sarungi M. Natural distribution of the femoral mechanical-anatomical angle in an osteoarthritic population and its relevance to total knee arthroplasty. *Knee*. 2012; 19(2):120-123. doi:10.1016/j.knee.2011.02.001
31. Brouwer RW, Jakma TS, Bierma-Zeinstra SM, Ginai AZ, Verhaar JA. The whole leg radiograph: standing versus supine for determining axial alignment. *Acta Orthop Scand*. 2003; 74(5):565-568. doi:10.1080/00016470310017965
32. Gbejuade HO, White P, Hassaballa M, Porteous AJ, Robinson JR, Murray JR. Do long leg supine CT scanograms correlate with weight-bearing full-length radiographs to measure lower limb coronal alignment? *Knee*. 2014; 21(2):549-552. doi:10.1016/j.knee.2013.05.009
33. Ranawat AS, Ranawat CS, Elkus M, Rasquinha VJ, Rossi R, Babhulkar S. Total knee arthroplasty for severe valgus deformity. *J Bone Joint Surg Am*. 2005; 87 Suppl 1(Pt 2):271-284. doi:10.2106/JBJS.E.00308
34. Deakin AH, Sarungi M. A comparison of variable angle versus fixed angle distal femoral resection in primary total knee arthroplasty. *J Arthroplasty*. 2014; 29(6):1133-1137. doi:10.1016/j.arth.2013.11.009