

RESEARCH ARTICLE

Clinical Outcome of Femoral Osteotomy in Patients with Legg-Calve'-Perthes Disease

Mohammad Hallaj Moghadam, MD; Ali Moradi, MD; Farzad Omidi-Kashani, MD

Research performed at Orthopaedic Research Center, Mashhad University of Medical Sciences, Mashhad, Iran

Received: 14 September 2013

Accepted: 21 December 2013

Abstract

Background: Legg-Calve'-Perthes disease is a juvenile idiopathic osteonecrosis in which the blood supply of femoral head is not sufficient and the bone dies provisionally. The aim of this study is to evaluate outcome of Femoral osteotomy in children with LCPD in our University Hospital.

Methods: In a descriptive analytic study, between 2008 and 2013, patients with the diagnosis of Legg-Calve'-Perthes confirmed with lateral pillar classification of B and B/C were entered and patients were encouraged to come to an outpatient clinic for follow-up. Descriptive analysis of the demographics was performed and relation between variables was tested using a two-sided Student's t test with statistical significance set at 0.05.

Results: Mean age of patients was 9 ± 1.3 years, with the range of 4 to 12 years old. 25 patients (86.2%) were male and 4 patients (13.4%) female. There was no positive family history in patients. 17 patients (58.6%) had history of trauma. Duration of symptom presentation was 7 ± 6.3 months, with the range of 3 to 36 months. In 20 of patients (69%) left hip and in 12 (41.4%) right hip was involved. There was significant relation between femoral head asymmetry, trochanter enlargement ($P=0.04$), acetabulum changes ($P<0.001$), femoral neck shortening ($P<0.001$). There was no relation between age ($P=0.28$) and duration of disease ($P=0.8$) with femoral neck shortening.

Conclusion: Intertrochanteric osteotomy led to improvement in pain, limping and increased range of motion. Subluxation before surgery is one of the criteria, which could influence further prognosis. Acetabulum changes and femoral neck shortening are two factors seriously affect hip ROM.

Keywords: Hip, Intertrochanteric osteotomy, Legg-Calve'-Perthes disease

Introduction

Legg-Calve'-Perthes disease is a juvenile idiopathic osteonecrosis in which the blood supply of femoral head is not sufficient and the bone dies provisionally (1). It is a major precipitant of premature osteoarthritis of the hip, and frequently necessitates hip replacement in early adulthood. Also this may lead to irritability of the hip joint and, depending on the severity, deformation of the head of the femur (2). It is one of the most common, but most poorly understood, disorders encountered by pediatric orthopedic surgeons. Legg-Calve'-Perthes disease occurs primarily in boys between 4 and 8 years old and has been associated with socioeconomic disadvantage in a number of small hospital-based studies. Incidence differs in different countries and is also dependant on race (10.8 per 100,000 Caucasian, 0.45 Negroid children) (3). The incidence of Legg-Calve'-Perthes disease is particularly high in the UK, the Faroe Islands, and Norway. While incidence rates vary considerably between countries, there is also significant variation within countries and even within regions (4, 5).

Corresponding Author: Ali Moradi, Orthopedic Research Center, Ghaem Hospital, Mashhad University of Medical Sciences, Ahmad-Abad Street, Mashhad, Iran.
Email: moradial@mums.ac.ir

Theories on the etiology of Legg-Calve'-Perthes disease include exposure to tobacco smoke, hyperactivity, an undetermined coagulopathy, and dietary deficiencies. The disease mechanism is uncertain but is likely to be multifactorial and may be of genetic or deprivation influence. None of these theories has been satisfactorily resolved (6). The only consistent finding is that affected children have disproportionate skeletal growth, with short hands and feet relative to the head and trunk size (7). This growth abnormality remains after controlling for deprivation status, which suggests that it is a true growth abnormality among affected children, and not simply an associated effect of deprivation. Problems associated with LCPD include decreased hip joint range of motion, especially abduction, and alternation in the growth of femoral bone which may lead to pain while walking. Long term outcomes include instability or reduced range of motion of the hip joint and increased incidence of osteoarthritis (8).

A variety of treatment methods are used in Legg-Calve'-Perthes disease to maintain hip joint range of motion and



THE ONLINE VERSION OF THIS ARTICLE
ABJS.MUMS.AC.IR

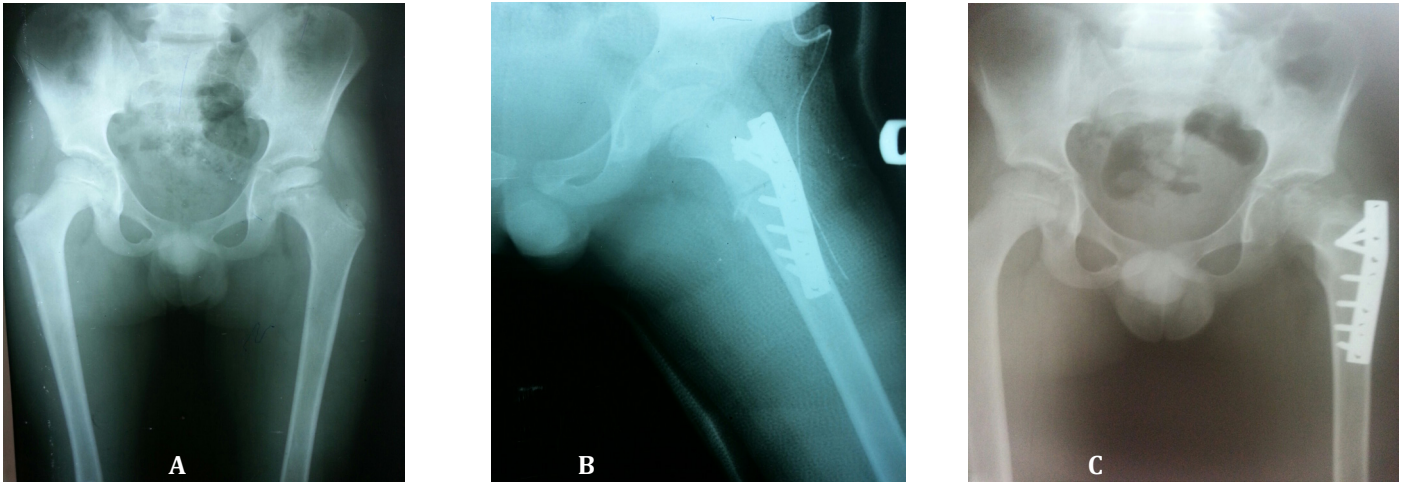


Figure 1. A 9-year-old boy with left hip presented with 4 months history of pain and limping.
A: Left hip involvement with Legg-Calve´-Perthes disease, Lateral pillar B
B: Post-operative X-ray, Intertrochanteric Osteotomy and plating
C: One year follow-up x-ray

aim to relieve clinical symptoms (especially pain) and contain the hip joint. Treatments may be classified as operative and nonoperative methods. Treatment of Legg-Calve-Perthes disease in older children with greater involvement of the femoral head remains uncertain. Innominate, femoral or combined osteotomies are generally providing more coverage of the femoral head by the acetabulum with the objective of achieving a more spherical head and congruent joint.

In the 1980s, operative methods (femoral and innominate osteotomy) to offer containment became more popular for these patient groups. Advocates of femoral varus osteotomy reported 70–90% satisfactory results. Limited studies compare conservative treatment regime(s) with femoral varus osteotomy and report variable results (9).

The aim of this study was to evaluate outcome of femoral osteotomy in children with LCPD in Mashhad.

Materials and Methods

Study population

In a descriptive analytic study, between 2008 and 2013, patients with Legg-Calve´-Perthes at department of orthopedic surgery in Imam Reza Hospital, Mashhad, Iran, diagnosis were entered. Our criteria for operation was patient with lateral pillar calcification of B and B/C border and age of more than 8 years old or not responding to conservative treatment. After obtaining approval of ethic committee of Mashhad University of Medical Sciences, 30

patients, and 34 effected hips were selected. 13.3% of cases were bilateral. In order to avoid a reporting bias caused by consideration of bilateral presentations, patients with bilateral hip involvement were considered as one patient, and the function of the worst hip was evaluated.

Operative Technique

Varus femoral osteotomy was performed with lateral approach in supine position. Osteotomy was done at the lesser trochanter level in such a way that the greater trochanteric apophysis did not disturb. Plate was used for internal fixation. Surgical aim was to achieve a neck-shaft angle of 110 to 115 degrees to confirm the femoral head is centered concentrically in the acetabulum. Six weeks spica casting was performed in all patients as part of standard postoperative treatment after surgery. After this period, partial weight bearing was allowed until osteotomy united (10) (Figure 1).

Radiography

As the primary radiologic outcome parameter, most recent anteroposterior and frog-leg lateral radiographs were reviewed. The parameters which were evaluated include: flattening of femoral head, acetabular changes, femoral neck shortening, trochanter enlargement, abnormal femoral neck angel and femoral head enlargement. Osteoarthritis signs were considered as secondary outcome parameter (11). Radiologic evaluation was performed by a experienced radiologist.

Clinical parameters

Prior to follow-up, the study was explained and informed consent obtained from parents. Criteria such as demographic data, pain (according to VAS), Limb shortening, any range of motion limitation, limping, trendelenberg test were evaluated before and after surgery.

Statistical analysis

SPSS 11.5 was applied for statistical analysis. Descriptive analysis of the demographics was performed. Relation between variables was tested using a two-sided Student's t test with statistical significance set at 0.05.

Table 1. Clinical parameter

	Surgery		P value
	Before	After	
VAS score	7.3	2.8	<0.05
Limited ROM	100%	7(24.1%)	<0.05
Subluxation	24.1%	13.8%	<0.05
Limb shortening	55.2%	51.7%	>0.05
Limping	96.6%	24.1%	<0.05
Positive Trendelenberg Test	17.2%	17.2%	1

Results

Mean age of patients at the beginning of the study was 9 ± 1.3 years, with the range of 4 and 12 years old. 25 patients (86.2%) were male and 4 patients (13.4%) were female. There was no positive family history in patients. 17 patients (58.6%) had history of trauma. Duration of symptom presentation was 7 ± 6.3 months, with the range of 3 and 36 months. In 20 of patients (69%) left hip and in 12 (41.4%) right hip was involved.

In Table 1 clinical parameter was showed before and after surgery.

Various radiologic signs was appeared in patients such as: flattening of femoral head in 6 patients (20.7%), acetabular changes in 4 patients (13.8%), femoral neck shortening in 10 patients (34.5%), trochanter enlargement in 6 patients (20.7%), abnormal femoral neck angle in 22 patients (75.9%) and femoral head enlargement in 8 patients (27.6%).

There was significant relation between trauma history and femoral head enlargement ($P=0.01$).

There was significant relation between limited range of motion after surgery, limping after surgery ($P<0.01$), positive trendelenberg ($P=0.02$), acetabulum changes ($P=0.04$) and femoral neck shortening ($P=0.01$).

There was significant relation between subluxation before surgery, limping after surgery ($P<0.01$), positive trendelenberg test ($P<0.001$), femoral neck shortening ($P=0.01$), limping ($P=0.01$), femoral head enlargement ($P=0.04$), positive trendelenberg ($P=0.02$) and acetabulum changes ($P<0.001$).

There was significant relation between femoral head asymmetry, trochanter enlargement ($P=0.04$), acetabulum changes ($P<0.001$), femoral neck shortening ($P<0.001$). There was no relation between age ($P=0.28$) and duration of disease ($P=0.8$) with femoral neck shortening.

Discussion

Legg-Calve-Perthes disease has no clear etiologic explanation. Management of LCPD is difficult in older children and in condition associated with articular stiffness.

In our study 20 of patients (69%) left hip and in 12 (41.4%) right hip was involved. In Wagenaar study involvement ratio in both sides was the same (12). Besides, intrtrochantric varus femoral osteotomy did not show better outcome as compared to conservative treatment (prolonged traction in abduction).

Legg-Calve-Perthes disease prognosis and treatment indications recently have been delineated with consideration of patient age and the severity of femoral head involvement.

In our study acetabulum changes ($P=0.04$) and femoral neck shortening ($P=0.01$) had a direct relation with range of motion.

Hailer showed that Patients with LCPD are at a higher risk of traumatic injuries, in our study 17 patients (58.6%) had history of trauma (13). Problems associated with Legg-Calve-Perthes disease are decreased hip joint range of motion particularly abduction, this condition

might lead to increased incidence of osteoarthritis, and growth problems of femoral bone which might induce pain in walking (14). Long term outcomes include instability or reduced range of motion of the hip joint. There are different treatment methods in Legg-Calve-Perthes disease which could maintain hip joint range of motion and improve clinical symptoms (15). Treatments may be divided into surgical and non-operative. There are various treatment modalities in different countries in a way that making a decision about comparison of the outcome of different treatment methods might be difficult (16).

Our result revealed that 25 patients (86.2%) were male and 4 patients (13.4%) were female. Females with Legg-Calve-Perthes disease have a worse prognosis than males and females with Legg-Calve-Perthes disease suffer from more severe disease and may be more susceptible to complications (17).

In our study duration of symptom presentation was 7 ± 6.3 months, with the range of 3 and 36 months. Regarding to Stulberg assessments, skeletal maturity and epiphyseal plate injury should evaluate, because it may lead to deformity at the time of skeletal growth (18). Unfortunately, it is impossible to avoid the degenerative modifications, which is the conclusive treatment aim of Legg-Calve-Perthes disease, when damage to the growth plate of the femoral head is connived, might lead to secondary changes (19).

There were some limitation in our study. The number of patients was limited only to 29 ones. Descriptive studies like ours have a retrospective nature and although follow up was performed by a single surgeon, all patients were not operated by the same surgeon, too.

On the other hand sample size was very small in this study and the surgery outcome might not be the reflex of surgery outcome in all patients with Legg-Calve-Perthes disease in our community.

One other limitation of this study was that the age at surgical intervention in patients varied which might had a dramatic influence on disease presentation and the outcome.

According to our study, Intrtrochantric Varus Femoral Osteotomy is an acceptable method for management of patients with Legg-Calve-Perthes disease. This surgery led to decrease in pain, limping and increase range of motion. Subluxation before surgery is one of the criteria, which could influence prognosis. Acetabulum changes and femoral neck shortening are two factor seriously effect hip range of motion.

Mohammad Hallaj Moghadam MD

Ali Moradi MD

Farzad Omidi-Kashani MD

Orthopedic Research Center, Ghaem Hospital
Mashhad University of Medical Sciences
Ahmad-Abad Street, Mashhad, 91799-9199 Iran

References

1. Millis MB, Lewis CL, Schoenecker PL, Clohisy JC. Legg-Calvé-Perthes disease and slipped capital femoral epiphysis: major developmental causes of femoroacetabular impingement. *J Am Acad Orthop Surg*. 2013; 21:59-63.
2. Tannast M, Macintyre N, Steppacher SD, Hosalkar HS, Ganz R, Siebenrock KA. A systematic approach to analyse the sequelae of LCPD. *Hip Int*. 2013; 23:61-70.

3. Novais EN. Application of the surgical dislocation approach to residual hip deformity secondary to Legg-Calvé-Perthes disease. *J Pediatr Orthop.* 2013;33:62-9.
4. Park KW, Jang KS, Song HR. Can residual leg shortening be predicted in patients with legg-calvé-perthes' disease? *Clin Orthop Relat Res.* 2013;471:2570-7.
5. Javid M, Wedge JH. Radiographic Results of Combined Salter Innominate and Femoral Osteotomy in Legg-Calvé-Perthes Disease in Older Children. *IJOS.* 2012; 10:106-13.
6. Eamsobhana P, Kaewpornawan K. Combined osteotomy in patients with severe Legg-Calve-Perthes disease. *J Med Assoc Thai.* 2012;95:128-34.
7. Moya-Angeler J, Abril JC, Rodriguez IV. Legg-Calvé-Perthes disease: role of isolated adductor tenotomy? *Eur J Orthop Surg Traumatol.* 2013; 23:921-5.
8. Thompson GH, Choi IH. Legg-Calve-Perthes disease centenary. *J Pediatr Orthop.* 2011;31:129.
9. Costa CR, Johnson AJ, Naziri Q, Mont MA. Review of total hip resurfacing and total hip arthroplasty in young patients who had Legg-Calvé-Perthes disease. *Orthop Clin North Am.* 2011;42:419-22.
10. Joseph B, Price CT. Principles of containment treatment aimed at preventing femoral head deformation in Perthes disease. *Orthop Clin North Am.* 2011; 42:317-27.
11. Neyt JG, Weinstein SL, Spratt KF, Dolan L, Morcuende J, Dietz FR, et al. Stulberg classification system for evaluation of Legg-Calvé-Perthes disease: intra-rater and inter-rater reliability. *J Bone Joint Surg Am.* 1999; 81:1209-16.
12. Wagenaar FB, Maathuis CG, van Erve RH. Treatment outcome in the most severely affected Legg-Perthes patients, comparing prolonged traction in abduction with femoral varus derotation treatment. *J Child Orthop.* 2011;5:89-95.
13. Hailer YD, Montgomery S, Ekblom A, Nilsson O, Bahmanyar S. Legg-Calvé-Perthes disease and the risk of injuries requiring hospitalization: a register study involving 2579 patients. *Acta Orthop.* 2012;83:572-6.
14. Loder RT, Browne RH, Millis A, Kim WC, Shah H, Cosgrove AP, et al. The time of the insult/triggering event in Legg-Calvé-Perthes' disease determined by incubation period modeling and the age distribution of children with Perthes'. *Iowa Orthop J.* 2012;32:69-75.
15. Perry DC, Bruce CE, Pope D, Dangerfield P, Platt MJ, Hall AJ. Legg-Calvé-Perthes disease in the UK: geographic and temporal trends in incidence reflecting differences in degree of deprivation in childhood. *Arthritis Rheum.* 2012;64:1673-9.
16. Wiig O, Svenningsen S, Terjesen T. Legg-Calvé-Perthes disease. *Tidsskr Nor Laegeforen.* 2011;131:946-9.
17. Herring JA, Kim HT, Browne R. Legg-Calve-Perthes disease. Part I: Classification of radiographs with use of the modified lateral pillar and Stulberg classifications. *J Bone Joint Surg Am.* 2004;86:2103-20.
18. Terjesen T, Wiig O, Svenningsen S. The natural history of Perthes' disease: risk factors in 212 patients followed for 5 years. *Acta Orthop.* 2010; 81:708-14.
19. Canavese F, Dimeglio A. Perthes disease. Prognosis in children under six years of age. *J Bone Joint Surg Br.* 2008; 90: 940-5.