

RESEARCH ARTICLE

Treatment of Pediatric Open Femoral Fractures with External Fixator Versus Flexible Intramedullary Nails

Hossein Aslani Hossein, MD; Ali Tabrizi, MD; Ali Sadighi, MD; Ahmad R Mirbolook, MD

*Research performed at Shohada Teaching Hospital, Tabriz University of Medical Sciences, Tabriz, Iran**Received: 14 September 2013**Accepted: 9 December 2013***Abstract**

Background: In children, inappropriate treatment of open femoral fractures may induce several complications. A few studies have compared the external fixator with flexible intramedullary nails in high-grade open femoral fractures of children. The present study aims at comparing results of these two treatment methods in open femoral fractures.

Methods: In this descriptive analytical study, 27 patients with open femoral fractures, who were treated using either the external fixator (n=14) or TEN nails (n=13) method from 2006-2011, were studied. Some patients were treated with a combination method of TEN and pin. The results were evaluated considering infection, union, malunion, and refracture and the patients were followed up for two years.

Results: Mean time required for fracture union was 3.89 (range: 2-5.8) and 3.61 (range: 2-5.6) months for the external fixator and TEN groups, respectively. The difference was not statistically significant and there was not any significant difference between the two groups considering infection of the fractured area. Osteomyelitis was not observed in any group. There was an infection surrounding the external fixator pin in 4 cases (28.5%) and so this required changing the location of the pin. In the TEN group, one case (7.6%) of painful bursitis was observed at the entry point of TEN and so the pin was removed earlier than usual. There were two cases (14.2%) of femoral refracture in the external fixator group. Malunion requiring correction was not observed in any of the groups. There were no complications observed in five patients treated with a combined method of pin and flexible intramedullary nails.

Conclusion: Both external fixator and intramedullary nail methods are effective ways in treating high grade open femoral fractures in children and final treatment results are similar. Combining pins and flexible intramedullary nails is effective in developing more stability and is not associated with more complications.

Keywords: Children, Diaphyseal open fractures, External fixator, Flexible intramedullary nail, Fracture fixation

Introduction

Pediatric femoral fracture is one of the most prevalent kinds of fractures with an incidence rate of 1.6% and about 4% of them are open fractures and most of these fractures (90%) result from high energy trauma (1). Studies also show that these fractures are associated with more complications (1, 2).

In children, femoral shaft fractures are traditionally treated through immobilization using the spica cast following a traction treatment period. However, children with open fractures, multi-trauma damages and simultaneous head trauma are treated surgically (3-8). Recently, the tendency towards the use of different surgical methods in pediatric femoral fractures and the indication of using surgical methods has widely increased. Surgical methods include external fixator and flexible and hard intramedullary nails (TEN) (8, 9). Short-term immobilization, returning joint

range of motion, lack of any stiff joint, short-term hospitalization, and low costs are regarded as advantages of the flexible nails. External fixators are used in open complex fractures resulting from high energy trauma as well as cases of several damages. However, they are associated with some complications including pin tract infection and scar at the pin site (10). There are a few studies comparing the results of these two surgical methods in grade III open femoral fractures of pediatric lower extremities. Therefore, in this study we have compared the results of these two mentioned methods.

Materials and Methods

This retrospective descriptive-analytical study was conducted at the Trauma Center of Northwestern Iran (Shohada Hospital affiliated with the Tabriz University of Medical Sciences, Tabriz, Iran) from 2006 to 2011. In this study, 27

Corresponding Author: Ali Tabrizi, El-goli Ave, Shohad Teaching Hospital, Tabriz University of Medical Sciences, Tabriz, Iran.
Email: Ali.Tab.ms@gmail.com



THE ONLINE VERSION OF THIS ARTICLE
ABJS.MUMS.AC.IR

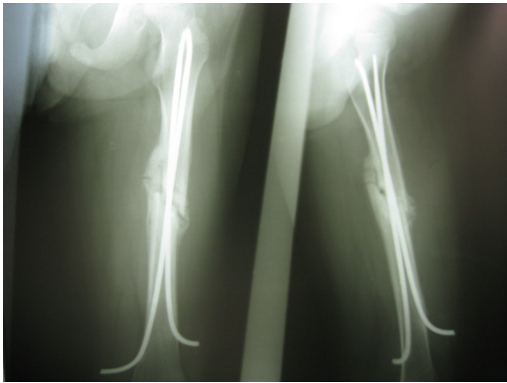


Figure 1. Fixation of femoral open fracture with flexible intramedullary nail.

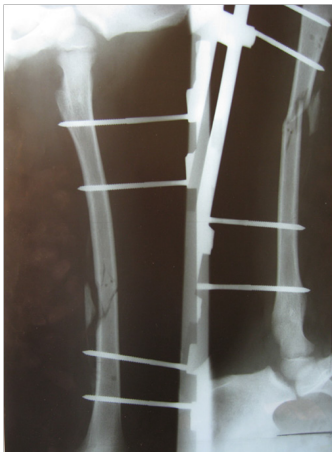

Figure 3. Fixation with external fixator in an open femoral fracture.

children (younger than 12 years) suffering from Gustilo grade A and B III open femoral fractures were admitted to the emergency department of the center and evaluated.

The patients were followed up for at least one year. Children with open femorals (from 3 cm distal to the lesser trochanter to 3 cm proximal to the distal physis) were selected. Children with a history of lower extremity fractures, systemic and metabolic diseases, and skeletal congenital diseases were excluded. The fractures often resulted from high energy motor vehicle accidents. The children were matched considering age, gender, damage mechanism. Furthermore, open fracture type (grade III) and associated damages as well as neurovascular complications were recorded in all patients. After the children were admitted to the emergency department of the center, they received prophylaxis using the first generation antibiotic

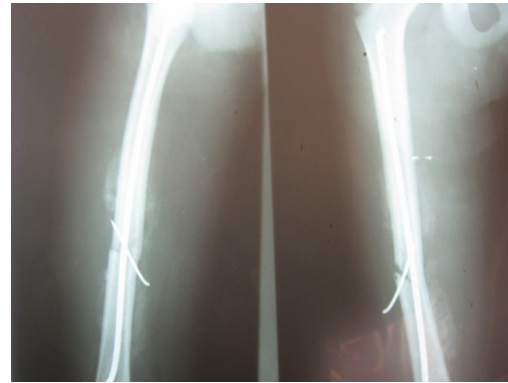


Figure 2. Fixation with a combination of a pin and flexible intramedullary nail.

cephalosporin (cefazolin 100mg/kg/day) and gentamicin. In severe cases, a third antibiotic (penicillin Crystal) was added to the treatment regime. All patients underwent washing and a primary debridement operation within the initial six hours of admission at the emergency department. According to the attending surgeon, the patients were treated either using external fixator or intramedullary nails during the first day of hospitalization. We tried to match two groups according to age, sex and type of fractures. Eligible patients whose guardians agreed to sign the informed consent were included in the study. The Ethics Committee of Tabriz University of Medical Sciences approved the study and the study conforms to the ethical principles contained in the Declaration of Helsinki.

Assessment of fracture union was through clinical examinations such as lack of pain, tenderness, crepitation at the fractured area as well as using radiographies of both lateral and profile views during the follow up period. Delayed union was regarded as non-union for more than six months. When intramedullary nails were inserted, surgical treatment was controlled through fluoroscopy. In some cases, pins were used to fix the fractured area (Figure 1, 2). The unilateral Monotube system was used to stabilize the fracture in the external fixation method (Figure 3).

Statistical analysis

The data was analyzed using SPSS16 statistical software and chi-square and the Fisher's exact test was used to analyze qualitative variables. Also, the independent t-test was used to analyze the quantitative variables. In this study, $P < 0.05$ was regarded as significant.

Results

In this study, 27 children with open femoral fractures,

Table 1. Comparing demographic findings and other associated complications between two groups treated with external fixator and intramedullary nails

Variable	External fixator group (n=14)	Flexible nails group (n=13)	P Value
Age (year)	9.5±3.2	8.7±3.7	0.1
Female/male	8/6 (57.1%/42.8%)	9/4 (69.2%/30.7%)	0.2
Head closed damage	3 (21.4%)	2 (15.3%)	0.09
Thorax and abdomen damage	1 (7.1%)	0	-
Pelvic fracture	1 (7.1%)	0	-

Table 2. Comparing complications between the two treatment methods of external fixator and intramedullary nails

Variable	External fixator group (n=14)	Flexible nails group (n=13)
Infection surrounding pins	4 (28.5%)	0
Painful bursitis	0	1 (7.6%)
Refracture	2 (14.2%)	0
Malunion	0	0
Limb length difference >1cm	1 (7.1%)	0

who were treated using the external fixator method (n=14) and flexible intramedullary nails (n=13) were compared. Pins were used to increase stability of the fractured area in five patients (38.4%) treated with flexible intramedullary nails. Demographic findings of the children studied and the associated damages are shown in Table 1.

Mean union time was 3.8 (range: 2-5.8) and 3.6 (range: 2-5.6) months in the external fixator and flexible intramedullary nailing groups, respectively. There was not any meaningful difference in this regard. Children of both groups were allowed to walk 4-10 days after treatment, such that the children of the external fixator group could walk with partial or complete weight bearing, but members of the flexible nails group were permitted to walk without weight bearing or partial weight bearing using crutches depending on the stability of the fractured area. Hospitalization days varied from 8 to 6.5 days in the external fixator and flexible nails groups, respectively. No difference was observed in this regard. Children whose femoral fracture was treated with the external fixator method had a normal knee range of motion with a mean of 20 weeks after treatment (8-34 weeks) and returned to school within 12 weeks (6-24 weeks). The external fixator was removed after 2.5 months. Children treated with flexible nails had normal knee range of motion within 10 weeks (6-14 weeks) and they returned to school within four weeks (2-10 weeks). There was a statistically meaningful difference between the two groups considering the ability to return to school and time required to obtain normal knee range of motion in femoral fractures treated with the above-mentioned methods.

Follow up results have been summarized in Table 2. There was not any meaningful difference between the two groups considering infection of the fractured area and osteomyelitis was not observed in any group. Infection surrounding pins created some problems in four cases (28.5%) and so it was necessary to change the place of the pins. In the TEN group, one case (7.6%) of painful bursitis was observed at the entry point of TEN and the pin was removed earlier than usual. There were two cases (14.2%) of femoral re-fracture in the external fixator group. There was not any report of malunion requiring correction in any of the groups. No infection was seen in those patients treated with a combined method of pin and flexible intramedullary nails.

Discussion

Femoral shaft fractures of children are generally treated with nonsurgical methods such as through traction and the spica casting for children 5-15 years old (11). Surgical treatment is used in cases with multiple traumas and damage of soft tissues, open fractures, and head trauma (12).

Developing flexible intramedullary nails have brought large developments in treating pediatric long bone fractures and several advantages have been mentioned for using the technique in treating these types of fractures (2). Intramedullary nails make alignment and appropriate rotation possible in treating the fractures. In addition to elasticity and appropriate stability, they result in micromotion at the fractured area, strengthening osseous calculus formation, and finally, acceleration of the union process. A small incision is used in surgical treatment and there is a very weak probability of infection (13, 14).

Abdel Razak *et al* studied children with an open femoral shaft fracture of Gustilo grade II resulting from motor vehicle accidents and who were treated with the flexible intramedullary nail technique and concluded that the method is associated with short hospitalization time and quick patient recovery (15). Hence, this technique has been stated as an acceptable way to treat open femoral shaft fractures of children (15). According to their observations, excellent treatment results were obtained in 71.4% of cases and union time was about 7.4 weeks and there was a weak probability of limb length discrepancy (15). The study introduced the flexible intramedullary nail technique as a preferred way to treat open femoral shaft fractures of 5-15 years old children (15). Comparing the two methods of surgical treatment of external fixator and flexible intramedullary nails in pediatric femoral shaft fractures, Barles *et al* stated that children in the flexible intramedullary nail group returned to school and previous activities and obtained normal joint motion range within a short time (11). While it is believed that there are more complications associated with the external fixator technique, for this reason, it is said that the intramedullary nail method is an appropriate way to treat children femoral shaft fractures if surgical treatment is required. External fixator is appropriate only in severe crush fractures. However, contrary to the mentioned studies, the study conducted by Allison *et al* showed that the external fixator treatment method resulted in quick stability in high grade open fractures of the femoral shaft (10). It makes treatment of other damages possible and is associated with earlier walking of children. In this study, union time has been reported to be about 7.2 months in femoral shaft fractures treated with the external fixator method (10).

According to the results of our study, mean union time was almost the same in the two treatment methods and there was not any difference in this regard. Like the study conducted by Barles *et al*, our study showed that children returned quickly to school and their previous normal activities and obtained normal joint range of motion when treated with flexible intramedullary nailing (11). There was not any case of nonunion in the patients treated with

any of the methods and infection of the fractured area was not a prevalent problem. Bursitis requiring device removal is the main complication of the flexible intramedullary nail technique. Also, refracture was regarded as the main complication observed in the external fixator method, although it was seen less in the previous studies. However, the external fixator was associated with quick stability of long bone fractures. External fixator is an effective way in treating open fractures with severe damage of soft tissues. It is used as a temporary method in adults due to more complications (nonunion, malunion, and infection surrounding the pins) (12). The complications are less seen in children and so it is used as a definite treatment method in children. In our study, external fixator was an effective definite treatment. TEN nails method is an effective method comparable with the external fixator in treating open fractures when fracture features allow its use (there was at least 25% cortical contact between the main parts). It lacks some complications of the fixator such as infection surrounding the pin, need for care, and refracture. In our study, the combination of the pin with flexible intramedullary nails developed maximum stability in severe crush cases. This is a new point, considering the previously conducted studies and may be helpful in appropriately treating open fractures. Contrary to the fixator method, complications such as infection surrounding the pin, as well as the need to care for the patients in two refracture intervals

was not observed in the TEN nails method. A combination of the pin with the TEN nails result in more stability of the fracture and is not associated with more complications.

Acknowledgments

This study was financially supported by the Tabriz University of Medical Sciences.

Conflict of interest

There is no conflict of interest on the part of the authors.

Hossein Aslani MD
Tehran University of Medical Science, Tehran, Iran

Ali Tabrizi MD
Shohada Teaching Hospital
Tabriz University of Medical Sciences, Tabriz, Iran

Ali Sadighi MD
Shohada Teaching Hospital
Tabriz University of Medical Sciences, Tabriz, Iran

Ahmad R Mirbolook MD
Poursina Teaching Hospital
Guilan University of Medical Sciences, Guilan, Iran

References

- Hutchins C, Sponseller P, Sturm P, Mosquero, R. Open femur fractures in children: treatment, complications, and results. *J Pediatr Orthop.* 2000; 20:183-8.
- Wright JG, Wang EL, Owen LJ, Stephens D, Graham KH, Hanlon M, et al. Treatments for paediatric femoral fractures: a randomized trial. *Lancet.* 2005; 365: 1153-8.
- Canale ST, Tennessee M, Tolo VT. Fractures of the femur in children. *J Bone Joint Surg Am.* 1995; 77:294-315.
- Levy J, Ward WT. Pediatric femur fractures: an overview of treatment. *Orthopedics.* 1993; 16:183-90.
- Gregory RJ, Cubison TC, Pinder IM, Smith SR. External fixation of lower limb fractures in children. *J Trauma.* 1992;33:691-3.
- Krettek C, Haas N, Walker J, Tscherne H. Treatment of femoral shaft fractures in children by external fixation. *Injury.* 1991;22:263-6.
- Skak SV, Overgaard S, Nielsen JD, Andersen A, Nielsen ST. Internal fixation of femoral shaft fractures in children and adolescents: a ten to twenty one year follow up of 52 fractures. *J Pediatr Orthop.* 1996;5:195-9.
- Ward WT, Levy J, Kaye A. Compression plating for child and adolescent femur fractures. *J Pediatr Orthop.* 1992; 12:626-32.
- Beatty JH, Austin SM, Warner WC, Canale ST, Nichols L. Interlocking intramedullary nailing of femoral-shaft fractures in adolescents: preliminary results and complications. *J Pediatr Orthop.* 1994; 14:178-83.
- Allison P, Dahan-Oliel N, Jando VT, Su Yang S, Hamdy RC. Open fractures of the femur in children: analysis of various treatment methods. *J Child Orthop.* 2011; 5:101-8.
- Barlas K, Beg H. Flexible intramedullary nailing versus external fixation of paediatric femoral fractures. *Acta Orthop Belg.* 2006; 72:159-63.
- Griffet J, Leroux J, Boudjouraf N, Abou-Daher A, Hayek T. Elastic stable intramedullary nailing of tibial shaft fractures in children. *J Child Orthop.* 2011; 5:297-304.
- Ligier JN, Metaizeau JP, Prevot J. Closed flexible medullary nailing in pediatric traumatology. *Chir Pediatr.* 1983; 24:383-5.
- Pankovich AM, Tarabishy IE, Yelda S. Flexible intramedullary nailing of tibial shaft fractures. *Clin Orthop.* 1981; 160:185-95.
- Abdel Razak MY, El Karef EA, Soleiman AS, Tanagho A. Results of flexible intramedullary nailing in paediatric femoral fractures. *Bull Alex Fac Med.* 2008;44:729-35.