

## RESEARCH ARTICLE

# Minimally Invasive Repair of Acute Achilles Tendon Rupture Using Gift Box Technique

Mohammadhossein Chegini Kord, MD; Adel Ebrahimpour, MD; Mehrdad Sadighi, MD; Mohammadreza Chehrassan, MD; Leili Nazari, MD; Arvin Najafi, MD; Mohammadreza Minator Sajjadi, MD

Research performed at Taleghani Hospital, Atieh Hospital, Tehran, Iran

Received: 15 July 2019

Accepted: 09 August 2019

## Abstract

**Background:** This study aimed to introduce a modified technique for minimally invasive Achilles tendon (AT) rupture repair using gift box sutures. The preliminary clinical and functional outcomes were investigated among a number of patients.

**Methods:** In a consecutive case series study, 24 patients with acute AT rupture underwent modified minimally invasive AT repair using two mini-incisions and gift box sutures. The patients were followed up for 24 months. The AT rupture score (ATRS) and the American Orthopedic Foot and Ankle Society (AOFAS) measure score were obtained from all patients. The other measured variables included pain intensity and satisfaction using a visual analog scale (VAS), calf atrophy, the range of sagittal ankle motion, development of wound complications, sural nerve injury, and re-rupture.

**Results:** After two years, the mean scores of AOFAS and ATRS were obtained at  $83\pm 4$  and  $81.9\pm 6.3$ , respectively. Approximately 87.5 % of the patients regained their previous level of activity. The mean VAS score was  $7.7\pm 0.9$  regarding the satisfaction with the outcomes. Moreover, isokinetic testing of plantar flexion and dorsiflexion strength were  $82.7\pm 5.8$  and  $87.7\pm 4.1\%$ , respectively, compared to those of the normal side. The calf atrophy was not statistically significant. In total, five patients reported pain during their activities. The range of operated ankle motion decreased significantly, compared to that of the other side; however, the differences were not significant functionally. There was no patient with wound complications, nerve injury, or complaint about problem with footwear.

**Conclusion:** Minimally invasive repair of acute AT rupture using two mini-incisions and gift box sutures offers good functional and clinical outcomes without wound complications which can be usually observed following open repair of AT ruptures.

**Level of evidence:** III

**Keywords:** Achilles tendon rupture, Complications, Gift box technique, Infection, Minimally invasive surgery, Wound dehiscence

## Introduction

The Achilles tendon (AT) is the primary plantar flexor of the ankle and considered as the most powerful tendon all over the body (1). The AT rupture most commonly occurs in the third to fourth decade of life, specifically in males, with an annual rate of 18 to 37 cases per 100,000 individuals (2). In spite of the current popularity of the surgical management of Achilles ruptures, the best approach of these injuries, including surgical versus non-operative treatment

remains controversial.

Non-operative treatment has generally been associated with re-rupture rates of 13% to 30%. The operative management has the benefit of early mobilization, lower re-rupture rates (<6%), and earlier return to sports activities (3). On the other hand, the wound complication rate related to surgical management varies from 0% to 21% (2, 4). The surgical options consist of percutaneous, classic open, limited open, and endoscopic-assisted

**Corresponding Author:** Adel Ebrahimpour, Department of Orthopedic Surgery, Shahid Beheshti University of Medical Sciences, Tehran, Iran

Email: a.ebrahimpour@sbmu.ac.ir



THE ONLINE VERSION OF THIS ARTICLE  
ABJS.MUMS.AC.IR

techniques (5). Despite the fact that all of them have the benefits of operative treatment, they differ regarding the re-rupture rate. Although the percutaneous treatment decreases wound complication rate, sural nerve injury rate increases as high as 16.7% (6, 7). The aim of the surgical approach is the early mobilization and a better healing potential leading to an earlier return to pre-injury level of activity and sport (8, 9).

To date, tendon repair using the Krackow locking loop has been successful regarding the early range of motion and stable fixation (10). However, the gift box technique for AT repair has been recently proved to be biomechanically stronger than traditional Krackow repairs in cadaver studies (11). It is hypothesized that a new modification of a minimally invasive approach using the gift box technique would result in comparable patient satisfaction with minimal wound issues. The present study aimed to investigate the preliminary clinical and functional results of acute AT rupture repair using a new modified technique.

### Materials and Methods

After obtaining the required approval from the institutional review boards of prospective case series, this study was conducted on patients with acute AT rupture (<30 days) referred to Taleghani and Atieh private hospitals, Tehran, Iran, from January to April 2015. The participants underwent modified minimally invasive repair using gift box sutures. In addition, written informed consent was obtained from the participants. The study protocol was approved by the Ethics Committee of Shahid Beheshti University of Medical Sciences, Tehran, Iran (13, 14, 16). The corresponding author performed all the repairs. The exclusion criterion was the patients with re-rupture, previous ankle surgery, inflammatory disorders, as well as the history of radiotherapy, chemotherapy, and systemic steroid administration. None of the patients could stand on tiptoe. The AT rupture was diagnosed using a palpable gap in the tendon trajectory and positive Thompson squeeze test. Furthermore, the test was confirmed using Magnetic Resonance Imaging (MRI).

### Surgical technique

The surgery was performed with the patient kept under spinal anesthesia. Before the operation, the rupture site was located using preoperative MR images and physical examination followed by mapping the tendon and site of incisions [Figure 1; Figure 2a]. In total, two longitudinal incisions were made with a 2.5 cm distance from the rupture site. The sural nerve was explored, and the proximal and distal parts of tendon were pulled out gently using a tendon clamp [Figure 2b]. There is usually no need for debridement of the stumps in acute AT ruptures.

The locking sutures were run the same as traditional Krackow technique using Ethibond 2.0. It is important to note that in the gift box technique, the transverse limb should be placed in the middle of the tendon, while it is transitioning from one side to another. The distal and proximal suture strings were pulled in opposite directions to ensure that two stumps reach each other outside the skin (the kissing test) [Figure 2c]. This test

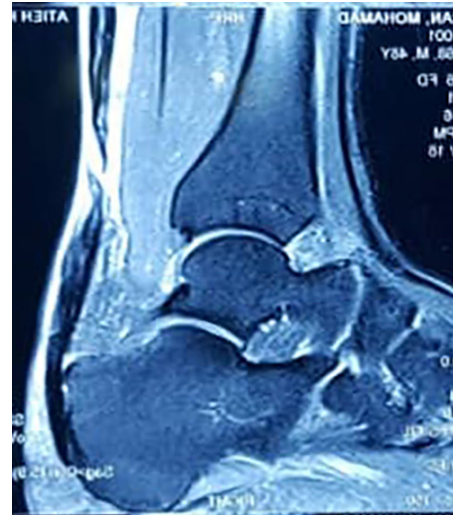


Figure 1. Preoperative MRIs locating the rupture site of the Achilles tendon.

helps to determine how much tension is needed to compress two ends of the rupture site.

After finding the lumen of paratenon, the suture strings were passed through the lumen in opposite directions parallel to each other. Subsequently, the free strings were crossed over the rupture site and run into the opposite stumps using a straight needle [Figure 2d]. Generally, four strings were crossed over the rupture site. The strings were tied in a manner that the knots were placed with 2.5 cm distance from the tip of the stumps. Finally, the palpation of the suture site with a feeling of minimal or no gap between two ends of the ruptured tendon helped the surgeon to be ensured about the success of the procedure. The knee was flexed to evaluate foot plantar flexion and enough resistance against passive foot dorsiflexion. Additionally, Thompson test was employed to ensure the appropriate tendon repair.

The paratenon was sutured, and the wounds were closed and dressed. The ankle was immobilized in 20° of plantar flexion using a short leg cast. After the operation, weight-bearing ambulation was not allowed for 4 weeks. At the 5th postoperative week, the cast was changed to immobilize the ankle in a neutral position and full-weight-bearing was allowed for two weeks followed by cast removal. Afterward, the rehabilitation program was started in this study.

It should be noted that before the main study, MRIs were performed on the first two patients at the end of the second postoperative week to ensure the appropriate approximation of the tendon stumps which resulted in acceptable findings. The patients were followed up for 2 years. At the last visit, the American Orthopaedic Foot and Ankle Society (AOFAS) measures, Ankle/Hindfoot scale, and Achilles Tendon Total Rupture Score (ATRS) were completed for all the patients. Furthermore, the range of dorsi- and plantar-flexion of both ankles was measured using a goniometer by the same orthopedic surgeon.

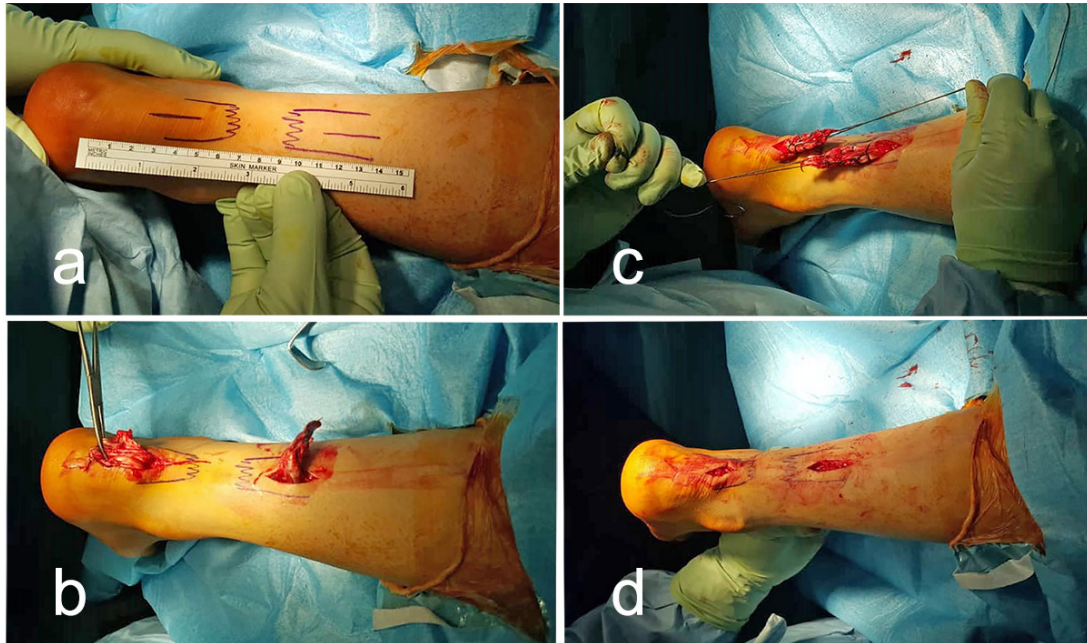


Figure 2. a Rupture site and incision mapping before the operation.

Figure 2. b Pulling two stumps out.

Figure 2. c Kissing test. The proximal and distal stumps pulling in opposite directions to ensure that two stumps reach each other.

Figure 2. d Free strings crossing the rupture site through the lumen of paratenon and running into the opposite stumps using a straight needle.

The measurements were repeated three times and the average was recorded as the range of motion (ROM).

The pain intensity was measured using a visual analog scale (VAS) in which 0 represented no pain and 10 indicated the most intensive imaginable pain. Furthermore, satisfaction with surgical outcomes was investigated using VAS. In this scale, 0 and 10 indicated no and maximal level of satisfaction, respectively. The calf circumference of both operated and healthy limbs was measured at 15 cm below the patella and compared in this study.

In addition, the isokinetic strength of plantar- and dorsiflexion of the operated ankle was measured and presented as the percentage of the strength of the healthy one. The patients were asked about limitations with footwear and returning to the pre-injury level of activity based on the Tegner activity scale. Tegner activity scale shows the patient's activity level from 0 representing disable patients to 10 representing national elite athletes.

#### Statistical Analysis

The data were analyzed in SPSS software (version 16.0; SPSS, Chicago, IL) through independent samples t-test to compare the range of injured and healthy ankles as well as calf circumferences. *P-value* less than 0.05 was considered statistically significant.

#### Results

This study included 27 patients with acute AT rupture (<30 days) from January to April 2015. Totally, three

Table 1. General characteristics of patients

No. Patients		24
Age (Y)		38±7
Gender	Male	17
	Female	7
Body mass index (kg/m <sup>2</sup> )		27.5±2.7
Mechanism	Falling down	2
	Slipping on the floor	3
	Sport injury (Jumping running, etc.)	19
Diabetes mellitus		3
Smoking		8
Side of injury	Right	13
	Left	11
Time interval between injury and surgery (d)		5.7±3

patients were missed in follow up visits and the study was completed with other 24 patients. Table 1 summarizes the characteristics of the patients. The mean duration of the



**Table 2. The comparison of sagittal ankle range of motion and calf circumference between operated and non-operated side**

Parameter	Operated side	Non-operated side	P-value
Plantar flexion	39.5±5	43.5±5.1	0.01
Dorsiflexion	19.3±2.9	23.7±2.9	<0.001
Calf Circumference	37.3±3.9	38±3.8	0.492

operation and hospital stays were 41±3 min and 0.9±0.3 days, respectively. At the last visit, the mean scores of AOFAS and ATRS were obtained at 83±4 and 81.9±6.3, respectively. Only three patients had experienced mild pain in their daily activities (VAS 1 or 2).

In addition, two patients reported mild pain (VAS 3) while contributing to heavy sporting activities, such as playing football. However, they stated that the pain did not disturb their activity level within sporting activities. Based on the Tegner activity scale, 21 patients achieved their pre-injury level of activity within 6 months after the surgery (87.5%). The mean satisfaction with surgical outcomes was estimated at 7.7±0.9. Furthermore, isokinetic plantar- and dorsiflexion strength were 82.7±5.8 and 87.7±4.1%, compared to the normal side.

The range of ankle sagittal motion decreased significantly in operated patients [ $P<0.05$ , Table 2]. The mean of calf atrophy was 0.7±0.6 cm and there was no significant difference between the healthy and operated limbs regarding the calf circumferences [ $P<0.05$ , Table 2]. No patients developed deep venous thrombosis, deep or superficial infection, wound dehiscence or adhesion, or pericalcaneal paresthesia. Sural nerve injury and re-rupture were not found in our patient population. No patient had difficulty with footwear.

### Discussion

The high rate of re-rupture after non-operative treatment of AT ruptures and considerable incidence of wound complications in open surgical treatment encouraged the surgeons to find a technique that concurrently includes the advantages of operative and non-operative treatment and overcome the disadvantages (12, 13). In recent years, surgeons have made an attempt to use minimally invasive surgeries (MIS) to repair AT ruptures the same as those performed on other body regions. These surgeries are believed to be associated with good functional and clinical outcomes and lower incidence of surgical wound complications (14).

Achillon device is a new device utilized for the MIS repair of AT, and several studies have shown fewer rates of complications with this device (15, 16). In a study, Calder and Saxby treated 46 patients with AT rupture using mini-open surgery and reported satisfying functional and clinical outcomes (17). All of the patients returned to their pre-injury level of activity within 6 months. However, in their study, one patient developed superficial infection and two others experienced temporary altered sensation in the distribution of the sural nerve.

Although various AT repair techniques have been introduced, the gift box technique has worthy technical

advantages. First of all, this method increases the strands across the repair site and improves tendon repair strength which may decrease gap formation. In addition, the stress riser as a nidus for early failure at the repair site may be prevented via tying sutures far from the rupture site (18, 19). Finally, repair strength may be improved by passing sutures around the transverse limb of the counter suture (11).

As a final point, these features create a twofold stronger repair, compared to the classic Krackow repair technique (11). The most important finding of the present study was the association between the repair of acute AT rupture using a minimally invasive gift box method and favorable functional and clinical outcomes in addition to lack of any major complications. According to the results, the mean AOFAS (83±4) and ATRS (81.9±6.3) are sufficiently acceptable and good. Totally, 87.5% of the patients achieved their pre-injury level of activity within 6 months after the surgery. In a study conducted by Bhattacharyya and Gerber, the outcomes of open repair and minimally invasive surgery for AT rupture using Achillon device were compared and no evidence of wound complications was found in the MIS group, compared to 20.6% infection in the open group (16).

In the present study, there was no infection, compared to the results of the study performed by Bhattacharyya. However, the device is not easily available in many hospitals and can increase the cost of surgery which propelled the authors to find a new technique without the need for such devices. The incidence rate of re-rupture in percutaneous techniques ranges from 2.6% to 16.7% (15, 20). Although several studies reported lower re-rupture rates in percutaneous techniques, most surveys found that open methods led to lower rates (20).

No re-ruptures was observed in patients who completed the survey in this study. Additionally, this strong repair method has the advantage of early mobilization with no occurrence of early failure or gap formation. Unfortunately, open surgical techniques have the potential of wound complications, including delayed wound healing, sinus tract formation, deep infections and adhesions have all been documented (3, 21).

The rate of wound complication ranges from 6.7% to 16% (3). The infection rate as the most prevalent problem has been reported to range from 3.2% in larger studies to 8.7% in smaller series (3). In a recent review, wound complication rates of 4.9% and 5.3% reported for the percutaneous method with immobilization and open technique approach with early mobilization, respectively (21). The most important complication in MIS and percutaneous repair of AT is the injury of sural nerve

(3, 22). In the same line, Tejwani et al. reported a rate of sural nerve injury (12.9%) as compared to no sural nerve injury in mini-open and open repair, respectively (22). With the aim of minimizing the rate of sural nerve injury, Chen et al. utilized a new device designed for suturing the AT leading to channel-assisted minimally invasive repair and minimized sural nerve injury (23). Regarding the technique described in the present study, the sural nerve injury did not occur in any patient without using any special device, such as the device used by Chen et al.

Some authors suggested the use of some implants to improve the biomechanical properties of minimally invasive repaired AT leading to the decreased risk of re-rupture. In a biomechanical study, Huri et al. described a new technique for minimally invasive AT repair using a button implant and modified Bunnell suture technique (24). They showed that endobutton-assisted modified Bunnell suture provided more reliable biomechanical properties, compared to the conventional Krackow technique. He et al. employed percutaneous Kirschner wire leverage to improve the AT repair (25). Although these authors reported good outcomes, as stated previously- in the technique described in the present study, no special devices or implants were required which can be associated with lower surgical cost.

As mentioned earlier, there are several techniques for percutaneous or minimally invasive AT repair confusing the surgeons to select the appropriate method. Recently, Labib et al. introduced the "Gift Box Technique" as a modification of the Krakow technique for AT repair. They compared the mechanical properties of the gift box repair with those of traditional Krakow technique and concluded that the new sutures were more than twice as strong as Krakow technique (11). These findings make the gift box technique valuable for the minimally invasive repair of the AT rupture since some previous studies have shown that minimally invasive repair can be associated with a decrease in the mechanical properties of the tendon. With the favorite mechanical properties of the gift box technique and the need for a technique to minimize the postoperative complications of the AT repair, the authors were encouraged to use the gift box sutures in the minimally invasive repair of the acute AT rupture.

Furthermore, making two small incisions rather than a midline longitudinal incision can provide the advantages of minimally invasive surgery, and consequently, prevent the wound healing complications. When this technique is used, the tendon sheath which includes the supply of microvascular network remains intact in the rupture site leading to healing augmentation. In the present study, there was no case of re-rupture and wound

complications, and most of the patients regained their previous level of activity. The functional outcomes were favorable based on the ATRS and AOFAS scores, and no soft tissue complication was observed in the patients. It is important to note that despite the significantly decreased range of ankle motion after the operation, about 4° limitation may not disturb the daily activities, which is not a considerable issue for the patients.

Although this study paved the way on the utilization of the gift box technique, it suffers from some limitations, including the small sample size. Furthermore, the authors did not compare the results obtained from the utilization of this technique with those of other conventional open or minimally invasive techniques. It seems that long-lasting comparative studies with more patients including clinical, functional, and biomechanical evaluations, especially gait analysis can result in more reliable and applicable findings.

A minimal invasive open technique was described using a gift box suturing technique by a single surgeon at a single academic center. Not only no re-ruptures were observed, but also the complication rate was low in this study. Additionally, this technique resulted in an acceptable level of patient satisfaction with a partial or complete resumption of preoperative sports activities. These findings were also revealed in AOFAS and ATRS scores, which are trustworthy foot and ankle scoring systems.

**Conflict of Interest:** The authors declare that they have no conflict of interest regarding the publication of the study.

**Ethical Considerations:** All procedures performed in this study were in accordance with the ethical standards of the institutional and/or national research committee and the 1964 Helsinki declaration and its later amendments or comparable ethical standards. Informed consent was obtained from all participants included in the study.

Mohammadhossein Chegini Kord MD  
Adel Ebrahimpour MD  
Mehrdad Sadighi MD  
Mohammadreza Chehrassan MD  
Leili Nazari MD  
Mohammadreza Minator Sajjadi MD  
Department of Orthopedic Surgery, Shahid Beheshti  
University of Medical Sciences, Tehran, Iran

Arvin Najafi MD  
Department of Orthopedic Surgery, Alborz University of  
Medical Sciences, Tehran, Iran

## References

1. Weinfeld SB. Achilles tendon disorders. *Med Clin North Am.* 2014; 98(2):331-8.
2. Bruggeman NB, Turner NS, Dahm DL, Voll AE, Hoskin TL, Jacofsky DJ, et al. Wound complications after open Achilles tendon repair: an analysis of risk factors. *Clin Orthop Relat Res.* 2004; 427(1):63-6.
3. Cetti R, Christensen SE, Ejsted R, Jensen NM, Jorgensen U. Operative versus nonoperative treatment of

- Achilles tendon rupture: a prospective randomized study and review of the literature. *Am J Sports Med.* 1993; 21(6):791-9.
4. Bhandari M, Guyatt GH, Siddiqui F, Morrow F, Busse J, Leighton RK, et al. Treatment of acute Achilles tendon ruptures: a systematic overview and metaanalysis. *Clin Orthop Relat Res.* 2002; 400(1):190-200.
  5. Chan KB, Lui TH, Chan LK. Endoscopic-assisted repair of acute Achilles tendon rupture with Krackow suture: an anatomic study. *J Foot Ankle Surg.* 2009; 15(4):183-6.
  6. Khan RJ, Fick D, Keogh A, Crawford J, Brammar T, Parker M. Treatment of acute Achilles tendon ruptures: a meta-analysis of randomized, controlled trials. *J Bone Joint Surg Am.* 2005; 87(10):2202-10.
  7. Buchgraber A, Passler HH. Percutaneous repair of Achilles tendon rupture: immobilization versus functional postoperative treatment. *Clin Orthop Relat Res.* 1997; 341(1):113-22.
  8. Sorrenti SJ. Achilles tendon rupture: effect of early mobilization in rehabilitation after surgical repair. *Foot Ankle Int.* 2006; 27(6):407-10.
  9. Majewski M, Schaeren S, Kohlhaas U, Ochsner PE. Postoperative rehabilitation after percutaneous Achilles tendon repair: early functional therapy versus cast immobilization. *Disabil Rehabil.* 2008; 30(20-22):1726-32.
  10. Krackow KA, Thomas SC, Jones LC. Ligament-tendon fixation: analysis of a new stitch and comparison with standard techniques. *Orthopedics.* 1988; 11(6):909-17.
  11. Labib SA, Rolf R, Dacus R, Hutton WC. The "Giftbox" repair of the Achilles tendon: a modification of the Krackow technique. *Foot Ankle Int.* 2009; 30(5):410-4.
  12. Cretnik A, Kosanovic M, Smrkolj V. Percutaneous versus open repair of the ruptured Achilles tendon: a comparative study. *Am J Sports Med.* 2005; 33(9):1369-79.
  13. Chana JS, Chen HC, Jain V. A new incision for surgery on tendo Achillis using a distally-based fasciocutaneous flap. *J Bone Joint Surg Br.* 2002; 84(8):1142-4.
  14. Chan SK, Chung SC, Ho YF. Minimally invasive repair of ruptured Achilles tendon. *Hong Kong Med J.* 2008; 14(4):255-8.
  15. Assal M, Jung M, Stern R, Rippstein P, Delmi M, Hoffmeyer P. Limited open repair of Achilles tendon ruptures: a technique with a new instrument and findings of a prospective multicenter study. *J Bone Joint Surg Am.* 2002; 84(2):161-70.
  16. Bhattacharyya M, Gerber B. Mini-invasive surgical repair of the Achilles tendon--does it reduce post-operative morbidity? *Int Orthop.* 2009; 33(1):151-6.
  17. Calder JD, Saxby TS. Early, active rehabilitation following mini-open repair of Achilles tendon rupture: a prospective study. *Br J Sports Med.* 2005; 39(11):857-9.
  18. Winters SC, Gelberman RH, Woo SL, Chan SS, Grewal R, Seiler JG III. The effects of multiple-strand suture methods on the strength and excursion of repaired intrasynovial flexor tendons: a biomechanical study in dogs. *J Hand Surg Am.* 1998; 23(1):97-104.
  19. Jaakkola JI, Hutton WC, Beskin JL, Lee GP. Achilles tendon rupture repair: biomechanical comparison of the triple bundle technique versus the Krakow locking loop technique. *Foot Ankle Int.* 2000; 21(1):14-7.
  20. Lim J, Dalal R, Waseem M. Percutaneous vs. open repair of the ruptured Achilles tendon da prospective randomized controlled study. *Foot Ankle Int.* 2001; 22(7):559-68.
  21. Wong J, Barrass V, Maffulli N. Quantitative review of operative and nonoperative management of Achilles tendon ruptures. *Am J Sports Med.* 2002; 30(4):565-75.
  22. Tejwani NC, Lee J, Weatherall J, Sherman O. Acute achilles tendon ruptures: a comparison of minimally invasive and open approach repairs followed by early rehabilitation. *Am J Orthop.* 2014; 43(10):E221-5.
  23. Chen H, Ji X, Zhang Q, Liang X, Tang P. Channel-assisted minimally invasive repair of acute Achilles tendon rupture. *J Orthop Surg Res.* 2015; 10(1):167.
  24. Huri G, Bicer OS, Ozgozen L, Ucar Y, Garbis NG, Hyun YS. A novel repair method for the treatment of acute Achilles tendon rupture with minimally invasive approach using button implant: a biomechanical study. *Foot Ankle.* 2013; 19(4):261-6.
  25. He ZY, Chai MX, Liu YJ, Zhang XR, Zhang T, Song LX, et al. Percutaneous repair technique for acute achilles tendon rupture with assistance of kirschner wire. *Orthop Surg.* 2015; 7(4):359-63.