

**RESEARCH ARTICLE**

# Effectiveness of Methylene Blue in the Prevention of Stifle Joint Arthrofibrosis in Rabbit Models

Hamid Namazi, MD; Mohammad J. Emami, MD; Fatemeh Dehghani Nazhvani, DVSc; Ali Dehghani Nazhvani, MSc; Zeinab Kargarshouroki, MS

*Research performed at Comparative and Experimental Medicine Center of Shiraz University of Medical Sciences, Shiraz, Iran*

Received: 12 August 2017

Accepted: 04 April 2018

**Abstract**

**Background:** One of the major challenges in orthopedic surgery is the prevention of arthrofibrosis, which can be successfully alleviated in its early stages. Many studies suggest the administration of methylene blue (MB) as an accessible and effective agent for the prevention of post-operation adhesions. The purpose of this study was to evaluate the efficacy of MB in the prevention of arthrofibrosis.

**Methods:** This study was conducted on 18 New Zealand white female mature rabbits. The anterior cruciate ligament of the left stifle joint of each animal was cut during aseptic surgery. In the next step, the rabbits were divided into three groups based on their treatments. The rabbits in the first, second, and third groups were subjected to the injection of normal saline, 1% MB solution, and 2% MB solution into their synovial space, respectively. The postoperative stifle range of motion was measured every week. After 4 weeks, the animals were euthanized and all joints were dissected for histopathology.

**Results:** The histopathological evaluation of tissues indicated the presence of fibrotic connective tissue as a sign of fibrosis in all groups. The fibrosis rate, inflammatory rate, tissue disarrangement, fibroblastic cellularity, and granulation tissue formation were at their highest levels in the 1% MB group. The integrity of articular cartilage in the 2% MB group was lower than the other groups. The level of bone degeneration was similar in both MB groups; however, it was more than the control saline group. The range of motion was reduced during the first week, then increased in the second and third weeks, and finally decreased in the fourth week.

**Conclusion:** The MB was not an effective method regarding the prevention or treatment of arthrofibrosis and the subsequent osteoarthritis. In contrast with previous studies, fibrosis was lower in the high dose MB group, compared to the low dose MB group. The alterations in the range of motion were related to the reduced movement caused by the pain and stiffness of the operated joints. The current study can be considered as the first report addressing the adverse effect of MB on synovial components.

**Level of evidence:** I

**Keywords:** Anterior cruciate ligament, Arthrofibrosis, Fibrosis, Methylene blue, Stifle joint

**Introduction**

Arthrofibrosis can be initiated due to primary injury or surgical complications. One of the main complications of post anterior cruciate ligament

(ACL) surgery or arthroplasty is arthrofibrosis, which is difficult to treat (1, 2). The excess scar tissue limits the range of motion (ROM) and can provoke extreme pain,

**Corresponding Author:** Fatemeh Dehghani Nazhvani, Bone and Joint Diseases Research Center, Shiraz University of Medical Sciences, Chamran Hospital, Shiraz, Iran  
Email: f.dehghani135n@gmail.com



THE ONLINE VERSION OF THIS ARTICLE  
ABJS.MUMS.AC.IR

immobility, and arthritis in the joints. Arthrofibrosis can be successfully alleviated in case it is treated in its early stages. Depending on the operative procedure type, patients should be able to demonstrate the normal progression of motion after approximately 2-3 weeks. However, when arthrofibrosis triggers, the normal progression of motion does not occur in 2 weeks. In some cases, the joint may do well for the first few weeks following the injury or surgery; however, it may later lead to a limited range of motion. It is difficult to detect the onset of arthrofibrosis before this two-week turnaround since the features are similar to normal responses. On the other hand, 6 weeks after the surgery, the process is quite advanced and the complications are more difficult to be successfully treated (1, 2).

When joint adhesions occurs, the main problem that can severely affect the daily activities is the loss of joint mobility along with articular pain (3, 4). The primary factor in loss of extension and flexion is the presence of fibrous connective tissue near the cruciate ligaments, tibiofemoral joint, fibrosis formation (FF) around the patellofemoral articulation and subsequent adherence of the patella to the trochlear groove, respectively. Many attempts have been done to reduce arthrofibrosis after knee surgery by applying biochemical agent including corticosteroids, non-steroidal anti-inflammatory drugs, botulinum toxin, mitomycin C, rapamycin, and monoclonal antibodies such as bevacizumab (5-9). Although these agents reduce abnormal proliferation of FF, collagen synthesis around the connective tissues of the joint, need for further operation, and hard physical therapy regime for treatment; the need for more accessible and lower treatment cost is still felt.

Recent studies have suggested the intraperitoneal application of methylene blue (MB) as an effective medication in the prevention of postoperative adhesions (3-8). The low doses of MB may be effective in preventing peridural fibrosis formation after lumbar laminectomy in rabbits (9). The MB [C<sub>16</sub>H<sub>18</sub>ClN<sub>3</sub>S] (molecular weight~320 g/mol) is a compound consisting of dark green crystalline powder, with a bronze-like luster and slight odor, melting point of 100-110 °C, water solubility at 25 °C, vapor pressure of 1.30X10<sup>-7</sup> mm Hg at 25 °C, light sensitivity, and stability in air. Solutions in water (43600 mg/L) or alcohol (ethanol 2%) have a deep blue color (21-25). Since its synthesis in 1876, the MB has been used for therapeutic purposes ranging from psychosis to cancer chemotherapy (26-34). Moreover, the MB formed the basis of antimicrobial chemotherapy and eventually led to the discovery of the neuroleptic drug families.

The range of MB activities is mainly based on the combination of its simple chemical structure and facility for oxidation-reduction reactions in situ. The MB inhibits the formation of superoxide by competing with oxygen in the electron transfer from flavoenzymes, primarily xanthine oxidase, and thus inhibits the generation of oxygen radicals. Several inflammatory mediators are betokened in adhesion formation, including locally generated free

radicals (e.g., superoxides, peroxides, and hydroxyl radicals), that could induce adhesions by damaging cellular membranes (8, 35). It can be noted that as an experimental study, the MB reduced myeloperoxidase activity and lipid peroxidation by decreasing both oxidative stress and nitrous oxide over-production and sepsis in the damaged lung of rat models (27). Moreover, the MB reduced oxidative, inflammatory, myocardial, and neurological injuries in the porcine model of cardiac arrest (29). It is also possible that the MB has a protective role in oxidative renal tissue damage (26). Furthermore, many studies suggest the use of MB in the prevention of postoperative adhesions as an accessible and effective agent (3-8).

Due to the reduced quality of life in patients with arthrofibrosis, this study aimed to evaluate the effect of MB on the arthrofibrosis prevention of stifle joints using rabbits as an experimental model of arthrofibrosis. Rabbits are feasible and easy handling animals for experiments; they are also better for measuring ROM degree due to their size and anatomy, compared to the rats and guinea pigs.

### Materials and Methods

This experimental study was approved by the Research Ethics Committee of Shiraz University of Medical Sciences, Shiraz, Iran (no. IR.SUMS.REC.1395.S1082). It was conducted on 18 mature New Zealand white female rabbits (weighing 2.00±0.56 Kg and with a mean age of 20±4 weeks). The rabbits were housed (22 °C, 12 h light and 12 h darkness) with a sufficient amount of food and water. Due to the financial constraints, 6 rabbits were selected for each group of the present study.

### Surgery

The rabbits were prepared for aseptic surgery. They were anesthetized by Ketamine (40mg/kg) and Xylazine (5mg/kg). The skin incision was made over the anterolateral of the patella on the left stifle joint of each animal. The patella was displaced laterally in order to expose the synovial cavity. The ACL was exposed by flexing the joint, which was transected by the scalpel (10-13). The synovial capsule and the skin were sutured by polydioxanone 4-0 and silk 2-0, respectively. A 20 gauge angiocatheter was installed into the synovial space leaving its end out of the incision prior to the joint capsule and skin suture. Subsequently, the rabbits were randomly divided into three groups based on their medical regimen.

Group I: In this group, the synovial space was injected with 1 ml of normal saline (0.9%) before angiocatheter removal

Group II: In this group, the synovial space was injected with 1 ml of 1.0% MB solution before angiocatheter removal

Group III: In this group, the synovial space was injected with 1 ml of 2.0% MB solution before angiocatheter removal

The animals received antibiotics, anti-inflammatory, and analgesic medication for 5 days after the operation.

The rabbits had good postoperative recovery and were housed separately during the study.

#### Preparation of Methylene blue solutions

For the preparation of MB solutions at the concentrations of 1% and 2%, 1 g and 2 g of MB powder were respectively dissolved in 99 ml distilled water and 1 ml acetic acid. The solutions were sterilized by autoclave at 20 lb (1.5 kg/cm<sup>2</sup>) pressure and 125 °C for 1 h. According to the National Toxicology Program, the MB concentrations of 1% and 2% doses (1.6 and 3.3 mg/kg) were considered safe (14).

#### ROM

The ROM of the operated and non-operated stifle joints of cases was measured by a goniometer for all groups every week after the surgery.

#### Histopathological study

After 4 weeks, the animals were euthanized by thiopental (30 mg/kg) injection to their heart and the whole joint was dissected for microscopic evaluation. The samples were kept in 10% buffered formalin solution, embedded in paraffin, sectioned, and stained by Hematoxylin and Eosin (15). The cases were examined through an Olympus microscope BX41 in a single-blind manner by a pathologist. Degree of inflammation, fibroblastic cellularity, connective tissue maturation, and arrangement of collagen fibers (scored as 1+, 2+, 3+ positive, and 0 as negative), tissue arrangement (scored 0 as regular and 1 as irregular) and presence of granulation tissue (scored 1 as present and 0 as absent) were examined in the ACL site for all groups. Moreover, the measured features of the whole synovial space included the extent of fibrosis and cartilage integrity (scored 0 as absent, 1 as local and 2 as generalized), fibroblastic cellularity, granulation tissue, bone resorption (scored 1 as present and 0 as absent) and tissue arrangement.

#### Statistical analysis

The non-parametric histopathological data were analyzed using Kruskal Wallis and Mann-Witney U tests. The analysis of variance (ANOVA) was performed for parametric ROM data and means were compared by Duncan's multiple range tests. Moreover, paired t-test analysis was used for the comparison of the ROM data between the operated and non-operated stifle joints in different groups per week. *P-values* less than 0.05 was considered statistically significant. The data analysis was performed using SPSS package (version 16 for Windows; SPSS Inc, Chicago, IL, USA).

#### Results

During the postoperative supportive medication, the rabbits were fresh and in good general condition although they felt pain in the operated stifle joint. Generally, the placebo group had the best locomotion condition. The histopathological results showed fibrotic connective tissue as the sign of fibrosis in all groups [Figure 1]. The degree of inflammation, tissue

arrangement, fibroblastic cellularity, connective tissue maturation, arrangement of collagen, and granulation tissue in ACL site of all groups are shown in Figure 2. The extent of fibrosis, cartilage integrity, fibroblastic cellularity, granulation tissue, bone resorption, and tissue arrangement in whole synovial space of all groups are reported in Figure 3.

Histopathologic results in group III showed sporadic findings, including one case of joint capsule inflammation and its extension into the synovial space, one case of joint surface necrosis, and one case of subchondral bone necrosis [Figure 4]. The subchondral bone necrosis was also observed in one case in group II.

Kruskal Wallis and Mann-Witney U tests of non-parametric histopathological data in ACL site indicated no significant statistical difference among the groups in terms of inflammation ( $P=0.076$ ), tissue arrangement ( $P=0.504$ ), fibroblastic cellularity ( $P=0.052$ ), granulation tissue ( $P=0.253$ ), and connective tissue maturation ( $P=0.053$ ). The obtained result of the Kruskal Wallis test was indicative of a significant statistical difference among the three groups regarding the arrangement of collagen fibers ( $P=0.047$ ). Mann-Witney test showed significant statistical difference between group II and III in terms of the arrangement of collagen fibers ( $P=0.016$ ); however, there was no significant statistical difference between group I and group II. Moreover, this difference was statistically significant between group I and group III ( $P=0.018$ ).

Kruskal Wallis and Mann-Witney U tests of non-parametric histopathological data in whole synovial space showed no significant statistical difference among the three groups in terms of cartilage integrity ( $P=0.175$ ), fibroblastic cellularity ( $P=0.433$ ), granulation tissue ( $P=0.253$ ), tissue arrangement ( $P=0.889$ ), and bone resorption ( $P=0.253$ ). The results of the Mann-Witney U test showed a significant statistical difference with regard to fibrosis in group I, compared to group

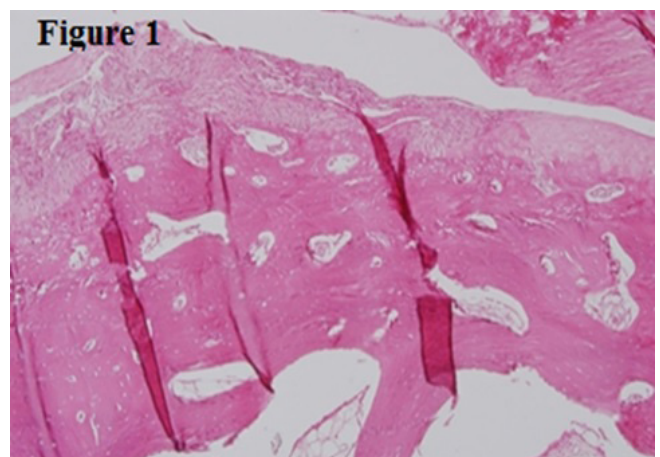


Figure 1. Fibrosis of the joint head with no inflammation (matured and organized collagen fibers; Haematoxylin and Eosin staining, 100X).

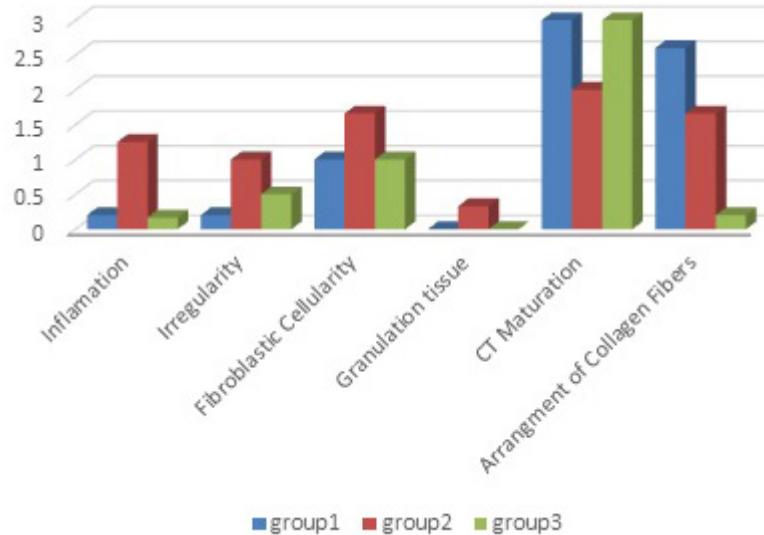


Figure 2. Differences in the degree of inflammation, tissue arrangement, fibroblastic cellularity, granulation tissue, fibrous connective tissue maturation, and arrangement of collagen fibers in ACL site between different groups of study.

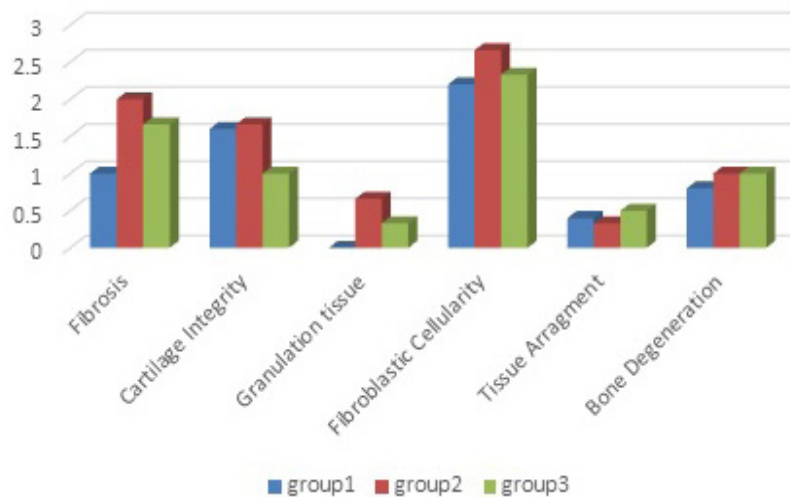


Figure 3. Differences in the presence of fibrosis, cartilage integrity, fibroblastic cellularity, granulation tissue, tissue arrangement, and resorption of the joint head in whole synovial space between different groups of study.

II and III ( $P=0.018$ ). However, there was no significant statistical difference between group II and III in this regard.

The ROM of the operated stifles (ROM-O) increased in all groups during the second week. The ROM-O elevated in groups I and III until the third postoperative week and

decreased afterward. The ROM-O increased in group II during the first and second postoperative weeks then it decreased until the fourth postoperative week. The smallest ROM-O was observed in group III during the fourth postoperative week, which was similar to the first week [Figure 5].

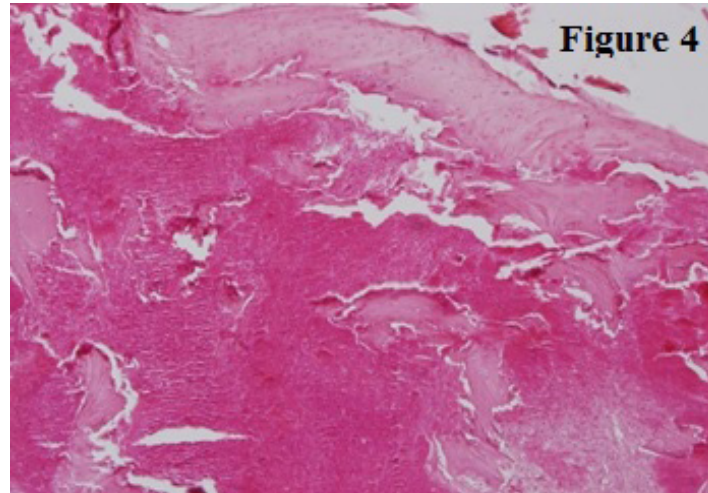


Figure 4. Sub-chondral necrosis of the joint head (Haematoxylin and Eosin staining, 200X).

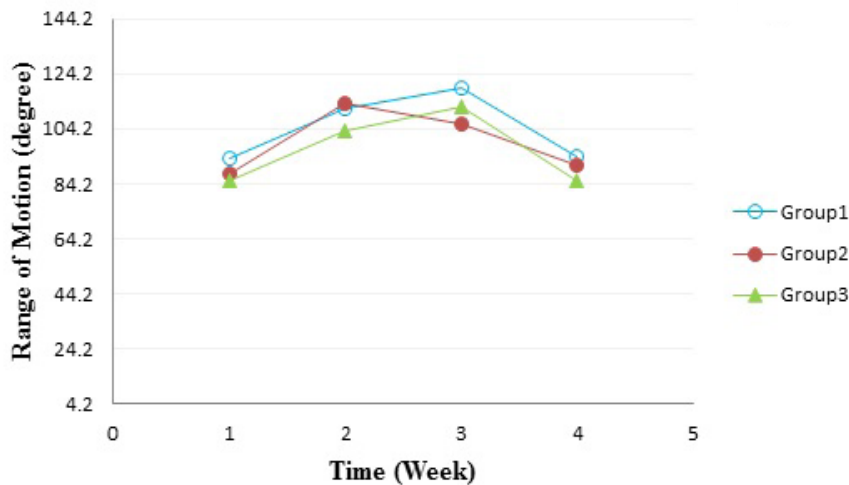


Figure 5. Changes in the range of motion of the operated stifle joints in different groups.

The analysis of ANOVA and post hoc Duncan test for the intergroup comparison of the ROM-O data during different weeks showed that the changes of the group I during the first postoperative week had a significant statistical difference, compared to the second and third weeks ( $P=0.000$ ). Moreover, there was no significant statistical difference between the first and fourth postoperative weeks. The ROM-O changes of group II showed no significant statistical difference during different weeks ( $P=0.293$ ). The ROM-O changes of the group III during the first postoperative week had a significant statistical difference, compared to the second and third weeks; however, there was a significant difference between the first and third postoperative

weeks ( $P=0.031$ ). The ROM-O changes of the group III revealed no significant statistical difference between the second and the third postoperative weeks. The ANOVA analysis and post hoc Duncan test for the ROM-O data comparison among the groups during different weeks showed that the ROM-O had no significant statistical difference among different groups in the first, second, third, and fourth postoperative weeks ( $P=0.538$ ,  $P=0.556$ ,  $P=0.590$ ,  $P=0.667$ , respectively).

Paired t-test analysis was used for the comparison of the ROM data between the operated (ROM-O) and non-operated (ROM-NO) stifle joints in different groups during the four postoperative weeks [Table 1]. The ROM-NO were higher in all groups and all postoperative

**Table 1. Comparison of the ROM data between operated (O) and non-operated (NO) stifle joints during different weeks (4 postoperative weeks) and different groups in all groups of study**

Group	Stifle ROM (degree)		Stifle ROM (degree)		Stifle ROM (degree)		Stifle ROM (degree)	
	1 <sup>st</sup> Week		2 <sup>nd</sup> Week		3 <sup>rd</sup> week		4 <sup>th</sup> Week	
	O	NO	O	NO	O	NO	O	NO
Group1	93.66±10.76a	129.33±10.85b	111.33±7.76a	124±9.69a	119.33±12.37a	120.33±6.37a	94.16±2.04a	110.33±7b
Group2	87.80±16.85a	132.16±7.92b	113.40±22.64a	142±8.48b	105.80±31.83a	124±7.61a	91±19.18a	107.40±10.57a
Group3	85.16±12.04a	125.50±8.06b	103.17±17.09a	143.5±6.62b	112.33±17.86a	131±2.09a	85.66±21.03a	109.17±15.47b

weeks, compared to the ROM-O; however, this difference was not statistically significant during the second and fourth weeks in the groups I and II, respectively ( $P=0.058$  and  $P=0.055$ ), as well as the third week for all groups ( $P=0.884$ ,  $P=0.293$ , and  $P=0.055$ ).

### Discussion

The present study was an attempt to compare the fibrosis formation and early evidence of osteoarthritic changes in the rabbits divided into three different groups during four postoperative weeks. The inflammatory rate, tissue disarrangement, fibroblastic cellularity, and granulation tissue formation were observed at their highest level in the ACL site of the 1% MB group. The overall evaluation of the joint capsule revealed that the fibrosis rate, granulation tissue formation and fibroblastic cellularity had their highest levels in the 1% MB and 2% MB groups, respectively. The integrity of articular cartilage in the 2% MB group was lower than the other two groups. Bone degeneration was similar in both 1% and 2% MB groups and it was more than the normal saline group; however, none were statistically significant except for fibrosis. Microscopically, the highest rate of fibrosis formation was found in the 1% MB group and in the 2% MB group, compared to normal saline group, which was statistically significant ( $P<0.05$ ). However, the difference between the 1% and 2% MB groups were insignificant. The results of the present study showed a slight suppression in the onset of fibrosis (as the early phase of the OA) in normal saline and then in high-dose MB intra-articular injection. This finding was in contrast with the previous studies on other tissues supporting the lower rate of adhesions or fibrosis formation following MB treatment (3, 6, 7).

A large number of studies have documented the potential advantages of MB; however, the effects of MB on postoperative fibrosis vary according to the administered dose. These studies reported that optimal effective MB concentrations are within the range of 1–2% (5, 7). Although in the case of the rat uterine horn model, the biochemical findings did not support the ameliorating effects of MB on the development of abdominal postoperative adhesion formation (8). In the present study, the intra-articular

injection of low-dose and high-dose MB solutions right after the surgical resection of ACL could not prevent the development of the fibrosis as compared to the normal saline-treated animals. It seems that due to the possible interference of MB with synovial fluid lubrication properties and its adverse effects on synovial component, fibrosis was eminent in the MB-treated groups, compared to the normal saline treated group.

According to the findings of the current study, the smallest arrangement of collagen fibers was observed in 2% MB group followed by 1% MB group, compared to the normal saline group that had the most organized collagen fibers. Regarding the biomechanical values of ACL, one of the important factors in ligament failure is the geometrical arrangement of collagen fibers (36). Particularly after injury or grafting, the ligaments do not gain the mechanical properties of indigenous tissue. The more perfectly arranged collagen fibers, there would be the most biomechanical tensile strength (37). These biomechanical properties and the significant status of collagen fibers arrangement at the ACL site may also indicate the theory of irritancy of MB on the synovial components. Therefore, biochemical studies must be carried out to support the adverse effects of MB. Some other studies have also shown the negative effects of MB; for example, the obtained results revealed the significant impairment of anastomotic bursting pressure by the intraperitoneal application of MB during the early phases of the wound healing process, which was due to its transient inhibitory effect on the nitric oxide pathway (4).

It is obvious that osteoarthritis progresses after the surgical resection of ACL, leading to the changes in bone and soft tissue as well as the occurrence of vascular invasion. Moreover, the advancement of the osteoarthritic zone of calcified cartilage into the articular cartilage further contributes to a decrease in articular cartilage thickness, resulting in an unhealthy joint over a period of time (38). In spite of the histopathologic support of the mentioned factors, the individual findings of MB groups (especially high-dose MB group) suggest that MB might be an irritant for synovial components.

The ROM alteration in the operated stifle joints

(ROM-O) can be related to the pathological changes, especially fibrosis formation in different groups. The significant results of paired t-test for ROM-O and ROM-NO data after the first postoperative week (1% MB,  $P=0.001$ ; 2% MB  $P=0.004$ ; normal saline  $P=0.000$ ) supported the ROM reduction following the first postoperative week, compared to the pre-surgical status. The ROM-O reduction during the first postoperative week meant that the operated stifle joints were in pain due to the surgical wound or manipulation of joints and ACL resection. During the first postoperative week, the ROM-O in the normal saline group was better than the MB groups, which further supported the theory of irritant nature of MB on the joint surface and its interference with the lubrication properties of the synovial fluid.

The ROM data evaluation confirmed the harmful effect of MB on synovial components. During the second and third postoperative weeks, the ROM-O alterations were considerable in MB groups, compared to the normal saline group. This issue resulted from the nature, concentration, the MB clearance process, and its interference with the joint synovial fluid. The ROM-O during the second and third postoperative weeks was better than the first postoperative week, indicating the anti-fibrosis formation of the MB treated groups. Moreover, there was a possibility that MB treatment after ACL transection may decrease pain via its anti-inflammatory effects.

In all groups, the ROM-O was reduced following the third postoperative week; therefore, it reached the pain level of the first postoperative week in the fourth week [Figure 5]. The increase in the ROM-O during the second and third postoperative weeks indicated an improvement in the locomotion system due to the repaired surgical wound and pain reduction. However, there is a need to support this finding through the provision of histopathological evidence. The reduction of ROM-O during the fourth postoperative week could result from the clearance of the treatment agents from the joint fluid (joint space), reduced effects of these agents, and the initiation of the histopathologic alteration of OA induced by ACL resection.

According to the histopathologic and ROM findings, the MB was not a beneficial medication for the prevention or treatment of fibrosis and subsequent OA. The obtained results also indicated that 2% MB (high dose MB) led to better outcomes, compared to 1% MB (low dose MB), which was in contrast with previous studies. Moreover, the pain in the operated joints led to the reduced movement resulting in ROM alterations.

It was concluded that although MB might affect the prevention of fibrosis, its potential harm to articular cartilage outweighs any possible benefit it might have. Based on the available information, this study was the first report addressing the injurious effect of MB on the synovial components and the mechanisms of action, which was left unclear in the literature.

**Funding:** This study was financially supported by the Vice Chancellor of Research, Shiraz University of Medical Sciences, Shiraz, Iran (Grant no. 94-01-56-11223).

**Ethical Approval:** All applicable guidelines for the care and use of animals were followed in the current study. It was approved by the institutional ethical committee of the Shiraz University of Medical Sciences, Shiraz, Iran (11223).

**Conflicts of Interest:** All authors declare that they have no conflicts of interest.

Hamid Namazi MD  
Mohammad J. Emami MD  
Fateme Dehghani Nazhvani DVSc  
Zeinab Kargarshouroki MS  
Bone and Joint Diseases Research Center, Shiraz  
University of Medical Sciences, Shiraz, Iran

Ali Dehghani Nazhvani MSc  
Department of Oral and Maxillofacial Pathology, School of  
Dentistry, Shiraz University of Medical Sciences, Shiraz,  
Iran

## References

1. Noyes FR, Mangine RE, Barber S. Early knee motion after open and arthroscopic anterior cruciate ligament reconstruction. *Am J Sports Med.* 1987; 15(2):149-60.
2. Noyes FR, Wojtys EM, Marshall MT. The early diagnosis and treatment of developmental patella infera syndrome. *Clin Orthop Relat Res.* 1991; 265(1):241-52.
3. Cetin M, Duran B, Demirkoprulu N, Guvenal T, Erden O, Cetin A. Effects of diazeniumdiolates (NONOates) and methylene blue on the reduction of postoperative adhesion in rats. *Gynecol Obstet Invest.* 2004; 57(4):186-90.
4. Dinc S, Ozaslan C, Kuru B, Karaca S, Ustun H, Alagol H, et al. Methylene blue prevents surgery-induced peritoneal adhesions but impairs the early phase of anastomotic wound healing. *Can J Surg.* 2006; 49(5):321-8.
5. Galili Y, Ben-Abraham R, Rabau M, Klausner J, Kluger Y. Reduction of surgery-induced peritoneal

- adhesions by methylene blue. *Am J Surg.* 1998; 175(1):30-2.
6. Heydrick SJ, Reed KL, Cohen PA, Aarons CB, Gower AC, Becker JM, et al. Intraperitoneal administration of methylene blue attenuates oxidative stress, increases peritoneal fibrinolysis, and inhibits intraabdominal adhesion formation. *J Surg Res.* 2007; 143(2):311-9.
  7. Kluger Y, Weinbroum A, Ben-Avraham R, Galili Y, Klausner J, Rabau M. Reduction in formation of peritoneal adhesions by methylene blue in rats: a dose response study. *Eur J Surg.* 2000; 166(7):568-71.
  8. Yildiz H, Durmus AS, Simsek H, Yaman I. The comparison of methylene blue and vitamin E in prevention of abdominal postoperative adhesion formation in rat uterine horn models: biochemical and histopathologic evaluation. *Acta Cir Bras.* 2011; 26(1):51-7.
  9. Farrokhi MR, Vasei M, Fareghbal S, Farrokhi N. The effect of methylene blue on peridural fibrosis formation after laminectomy in rats: an experimental novel study. *Spine J.* 2011; 11(2):147-52.
  10. Namazi H. Botulinum toxin as a novel addition to anti-arthritis armamentarium: an experimental study in rabbits. *Int Immunopharmacol.* 2006; 6(11):1743-7.
  11. Namazi H, Torabi S. Novel use of botulinum toxin to ameliorate arthrofibrosis: an experimental study in rabbits. *Toxicol Pathol.* 2007; 35(5):715-8.
  12. Seydi N, Dehghani S. Radiological study of the effect of Platelet Rich Plasma (PRP) on experimentally induced osteoarthritis in Guinea Pig's stifle joint. *J Animal Poultry Sci.* 2013; 2(3):73-8.
  13. Toghraie FS, Chenari N, Gholipour MA, Faghih Z, Torabinejad S, Dehghani S, et al. Treatment of osteoarthritis with infrapatellar fat pad derived mesenchymal stem cells in Rabbit. *Knee.* 2011; 18(2):71-5.
  14. National Toxicology Program. Toxicology and carcinogenesis studies of methylene blue trihydrate (Cas No. 7220-79-3) in F344/N rats and B6C3F1 mice (gavage studies). *Natl Toxicol Program Tech Rep Ser.* 2008; 540(1):1-224.
  15. Luna LG. Manual of histologic staining methods of the armed forces institute of pathology. 3rd ed. New York: Blakiston Division, McGraw-Hill; 1968.
  16. Aydin E, Uckan S, Ozdemir BH, Uyar P. Mitomycin C effect on fibrous adhesions of rabbit temporomandibular joint. *Otolaryngol Head Neck Surg.* 2005; 133(5):672-6.
  17. Brunelli G, Longinotti C, Bertazzo C, Pavesio A, Pressato D. Adhesion reduction after knee surgery in a rabbit model by hyaloglide®, a hyaluronan derivative gel. *J Orthop Res.* 2005; 23(6):1377-82.
  18. Emami MJ, Jaberi FM, Azarpira N, Vosoughi AR, Tanideh N. Prevention of arthrofibrosis by monoclonal antibody against vascular endothelial growth factor: a novel use of bevacizumab in rabbits. *Orthop Traumatol Surg Res.* 2012; 98(7):759-64.
  19. Kocaoglu B, Akgun U, Nalbantoglu U, Poyanlı O, Karahan M. Adhesion reduction after knee surgery in a rat model by mitomycin C. *Knee Surg Sports Traumatol Arthrosc.* 2011; 19(1):94-8.
  20. Zhao S, Sun Y, Li X, Wang J, Yan L, Chen H, et al. Reduction of intraarticular adhesion of knee by local application of rapamycin in rabbits via inhibition of fibroblast proliferation and collagen synthesis. *J Orthop Surg Res.* 2016; 11(1):45.
  21. Johnson R, Zenhausen A, Zollinger H, Mark H, Mcketta J. *Krik-Othmer encyclopedia of chemical technology.* New York: Wiley, Hoboken; 1978. P. 379.
  22. Lide DR. *CRC handbook of chemistry and physics.* Florida: CRC Press; 2004.
  23. Osol A, Remington JP. *Remington's pharmaceutical sciences.* North Carolina: Mack; 1980.
  24. American Society of Hospital Pharmacists. *American hospital formulary service drug information.* Maryland: Authority of the Board of Directors of the American Society of Hospital Pharmacists; 1994.
  25. Sunshine I. *Handbook of analytical toxicology.* Florida: CRC Press; 1969. P. 77.
  26. Aksu B, Inan M, Kanter M, Oz Puyan F, Uzun H, Durmus-Altun G, et al. The effects of methylene blue on renal scarring due to pyelonephritis in rats. *Pediatr Nephrol.* 2007; 22(7):992-1001.
  27. Demirbilek S, Sizanli E, Karadag N, Karaman A, Bayraktar N, Turkmen E, et al. The effects of methylene blue on lung injury in septic rats. *Eur Surg Res.* 2006; 38(1):35-41.
  28. Mentese BB, Akin M, Leventoglu S, Gultekin FA, Oguz M. Intradermal methylene blue injection for the treatment of intractable idiopathic pruritus ani: results of 30 cases. *Tech Coloproctol.* 2004; 8(1):11-4.
  29. Miclescu A, Basu S, Wiklund L. Methylene blue added to a hypertonic-hyperoncotic solution increases short-term survival in experimental cardiac arrest. *Crit Care Med.* 2006; 34(11):2806-13.
  30. O'Neil MJ. *The merck index an encyclopedia of chemicals, drugs and biologicals.* Cambridge: RSC Publishing; 2006.
  31. Peng B, Zhang Y, Hou S, Wu W, Fu X. Intradiscal methylene blue injection for the treatment of chronic discogenic low back pain. *Eur Spine J.* 2007; 16(1):33-8.
  32. Sharr MM, Weller RO, Brice JG. Spinal cord necrosis after intrathecal injection of methylene blue. *J Neurol Neurosurg Psychiatry.* 1978; 41(4):384-6.
  33. Sutherland AD, Faragher IG, Frizelle FA. Intradermal injection of methylene blue for the treatment of refractory pruritus ani. *Colorectal Dis.* 2009; 11(3):282-7.
  34. Wainwright M, Crossley K. Methylene blue--a therapeutic dye for all seasons? *J Chemother.* 2002; 14(5):431-43.
  35. Salaris SC, Babbs CF, Voorhees WD 3rd. Methylene blue as an inhibitor of superoxide generation by xanthine oxidase. A potential new drug for the attenuation of ischemia/reperfusion injury. *Biochem Pharmacol.* 1991; 42(3):499-506.
  36. Noyes FR, DeLucas JL, Torvik PJ. Biomechanics of anterior cruciate ligament failure: an analysis of strain-rate sensitivity and mechanisms of failure in



primates. J Bone Joint Surg Am. 1974; 56(2):236-53.  
37. Weiler A, Förster C, Hunt P, Falk R, Jung TM, Unterhauser FN, et al. The influence of locally applied platelet-derived growth factor-BB on free tendon graft remodeling after anterior cruciate ligament reconstruction. Am J Sports Med. 2004;

32(4):881-91.  
38. Kalbkhani M, Dehghani S, Najafpour A, Ghorbanzadeh N. The effect of autogenous platelet rich plasma on experimentally induced osteoarthritis in rabbit's stifles joint: a radiological assessment. J Animal Poultry Sci. 2013; 2(1):27-38.