

RESEARCH ARTICLE

The Incidence of Ossified Superior Transverse Scapular Ligament during Nerve Transfer through Posterior Shoulder Approach

Masoud Yavari, MD; Seyed Esmaeil Hassanpour, MD; Hamidreza Alizadeh Otaghvar, MD; Hossein A. Abdolrazaghi, MD; Amir R. Farhoud, MD

Research performed at 15th Khordad Hospital, Shahid Beheshti University of Medical Sciences, Tehran, Iran

Received: 19 December 2017

Accepted: 26 April 2018

Abstract

Background: The purpose of this study was to assess the incidence and importance of bony bridge that covers the supra scapular notch during posterior approach to transfer accessory nerve to suprascapular nerve.

Methods: Between 2010 and 2015, the frequency and importance of suprascapular bony bridge instead of transverse ligament was assessed among patients with brachial plexus injury candidate to shoulder function restoration by accessory to suprascapular nerve transfer through posterior approach.

Results: Forty three patients, 41 male and 2 female, (mean age: 32.5 years, range 14 to 36) were included in this study. Five male patients (11.6%) had a complete bony rim on the superior scapular notch. Suprascapular nerve release needed osteotomy of the bony bridge and related equipment.

Conclusion: Although all previous cadaveric studies among different ethnic groups had reported the prevalence between 0.3 to 30% of suprascapular canal, this in vivo study showed the incidence of 11.6%. Preoperative alertness about this variation could make the exploration and release of the suprascapular nerve easier and reduce the risk of nerve injury or failing to anatomize it.

Level of evidence: IV

Keywords: Brachial plexus, Nerve transfer, Superior transverse scapular ligament, Suprascapular notch

Introduction

Reinnervation of the suprascapular nerve (SSN) for shoulder reanimation is one of the corner stones of management of brachial plexus injuries. The most popular donor nerve for this transfer is the accessory nerve (ACN) (1). The classic anterior supraclavicular approach is usually applied to transfer the ACN to SSN (2-4). In severe injuries the plexus may retract distally, make finding the distal stump of SSN and suturing it

to donor ACN impossible. Solutions for this problem could be applying a posterior approach to SSN (5-7) or releasing the superior transverse scapular ligament (STSL) through a standard anterior plexus exposure (8).

Suprascapular notch roofed by STSL is located in the lateral part of the superior border of scapula and medial to the base of the coracoids process (9). Several classifications suggested for morphology of

Corresponding Author: Amir R. Farhoud, Department of Orthopedics, Tehran University of Medical Sciences, Imam Hospital Complex, Joint Reconstruction Research Center, Tehran, Iran
Email: am_farhoud@yahoo.com



THE ONLINE VERSION OF THIS ARTICLE
ABJS.MUMS.AC.IR

suprascapular notch and STSL because the SSN passes below the STSL and its narrowing plays the main role in etiology of SSN entrapment (9, 10). A variation of suprascapular notch that associates with SSN entrapment is complete ossification of the STSL and having suprascapular foramen instead of a notch (11-13). The prevalence of completely ossified STSL has been variable in previous cadaveric or radiological studies of different ethnic groups and world areas by reported rates between 0.3% in Eskimos to 30.7% in Brazilians (11, 14, 15). Its prevalence is more common in men and right side and may have a genetic predisposition. The role of factor of age is not clear and was reported differently in previous studies (11). This anatomical variation could be clinically important intraoperatively during arthroscopic decompression of an entrapped SSN, transferring of ACN to SSN through a dorsal approach, or when decompression of SSN is implemented by releasing the STSL through a standard brachial plexus supraclavicular approach. The aim of this study was to assess the incidence of completely ossified STSL detected intraoperatively in patients with injured brachial plexus who were operated to transfer ACN to SSN through a posterior approach.

Materials and Methods

Between September 2005 to September 2011, any patient with brachial plexus injury selected for ACN to SSN transfer in 15th Qordad University Hospital, Tehran, was operated through a posterior approach by a single surgeon (M. Y). The exclusion criteria were duration of more than 12 months from injury, age under 12, injured ACN and non-acceptance of the patient. The study was approved by the institutional review committee of Shahid Beheshti University of Medical Sciences. Simple X-ray (true anteroposterior and lateral Y view) was performed preoperatively. The patient was prepared and draped in prone position under general anesthesia. No muscle relaxing agent was applied until suturing the nerves. Marking of SSN and ACN was performed on the skin. The ACN was marked at a point approximately 70% of the distance from the acromion to the dorsal midline angle. The SSN was marked at a point approximately 30% of the distance from angle between the acromion to the scapula medial border (16). Adrenaline 1/10000 (5 ml) was injected around the incision. An incision was made parallel to the spine of scapula. The trapezius muscle was elevated from the spine of scapula and the trapezius muscle was retracted proximally. A thin layer of adipose tissue separates trapezius from the underlying supraspinatus. The ACN was found on the undersurface of trapezius beneath the surface marking, dissected, and looped by a silastic tape. Electrical stimulation of ACN could lead to contractions of the trapezius muscle. The upper border of scapula was palpated with the index finger for suprascapular notch. A downward traction on the upper border of supraspinatus muscle revealed the glistening white STSL overlying the notch. The STSL that was clearly characterized by the suprascapular artery and vein crossing over it. Both vessels were ligated superficial to the ligament and the ligament was sectioned by protecting

the underlying SSN. The SSN was also looped by a silastic tape. After sectioning the donor ACN and recipient SSN in optimal length, they were sutured under a microscope using 10-0 polypropylene suture (Prolene, Ethicon). The trapezius was then reattached to the scapular spine and the surgical incision was closed in the routine manner. A sling was applied for 3 weeks postoperatively.

Finding the STSL and suprascapular notch including SSN might not be easy always. If the superior border of scapula was all bony, the exploration of the SSN needed osteotomy of this border beneath the path of ligated suprascapular vessels and medial to the base of the coracoids process. Osteotomy of the ossified STSL was not only complicated and time consuming, but this procedure seemed risky to damage the SSN and even to fail finding the nerve.

Results

Forty three shoulders in 43 (41 male and 2 female) patients were operated through posterior approach to transfer ACN to SSN. The right side was involved in 18 patients and left side in 25. The average age was 32.5 years (range: 14 to 36). The mechanism of the brachial plexus injury was traction injury due to motor vehicle accident as well as falling in 32 and 8 patients, respectively. Three patients had brachial plexus injury due to penetrating injuries. Thirty eight patients (88.4%) had clear suprascapular notches covered with STSL. The STSL was totally ossified in 5 male patients, so that the SSN passed through a bony canal. The bony STSL was in right side in 3 and in left side in 2 patients [Table 1]. Finding the nerve distal to the canal was impossible and the risk of damaging the nerve existed throughout the bony bridge removal. Ultimately, the nerve was anatomized in these 5 patients by meticulous and difficult osteotomy and removal of the bony bridge. The presence of osteotomy equipment and adequate knowledge about the possible anatomical variations seemed necessary during the SSN release at the upper border of scapula.

Table 1. Data of gender, age and side of surgery of all, 43 shoulders operated posteriorly to transfer ACN to SSN and of 5 patients with ossified STSL. (ACN: accessory nerve; SSN: suprascapular nerve; STSL: superior transverse scapular ligament)

	Total	Ossified STSL
Gender		
Male	41	5
Female	2	0
Age		
Mean	32.5	27.6
Range	14-36	19-35
Side		
Right	18	3
Left	25	2

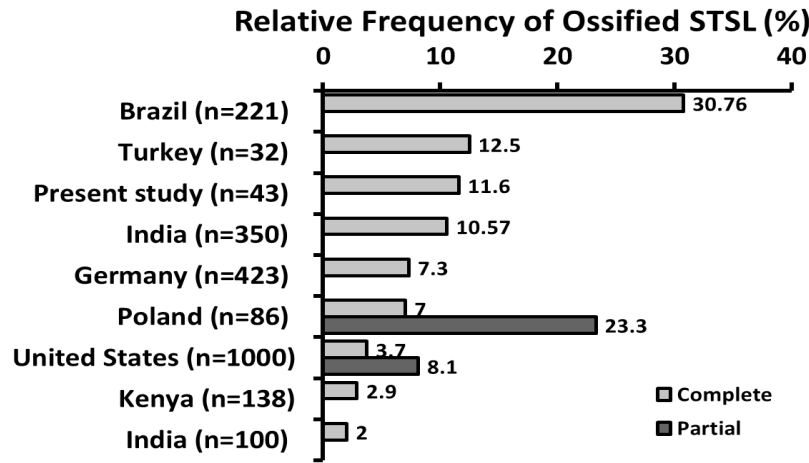


Figure 1. Relative frequency of ossified STSL (complete and partial) in different studies from Brazil, Turkey, India, Germany, Poland, the United States, Kenya, and India (1, 2, 8, 15, 17-23).

Discussion

Different frequency rates of bony STSL, ranging from 0.3% in Eskimos to 30.7% in Brazilians, have been reported in previous studies [Figure 1] (1, 2, 8, 11, 15, 17-23). The different rates were attributed to genetic backgrounds (9, 11). This frequency was between 6-12.5% in studies from Turkey that is comparable to the result of 11.4% of our study from Iran (17). All previous studies were performed on dried samples, cadavers, or reviewing the radiological assessments. Also, the previous studies considered the importance of this anatomical variation only in the etiology of SSN entrapment (12, 24). This study reflects an intraoperative observation and its related considerations about exploration of SSN for being recipient of nerve transfer from ACN in posteriorly approached patients with brachial plexus injuries. The dorsal approach for ACN to SSN transfer requires SSN release in the notch by cutting the STSL as a bony STSL causes some problems. First, Osteotomy of the upper border of scapula at the medial side of coracoids base is necessary. It necessitates the use of devices for a delicate osteotomy. Inappropriate technique or equipment could injure the buried nerve in the bony canal. Reviewing 812 samples, Polguy et al. found complete bony STSL in 44 scapulae (5.4%) and classified it to fan-shaped and bond-shaped bony STSL. The bond-shaped bony ligament was more frequent and reduced the surface area of the bony canal more than the other type (11). Although, in line with our findings, Polguy demonstrated a higher frequency of bony STSL in men and right side. Because our study is about brachial plexus patients not normal population, no judgment about these variables (gender and the side) is possible. Another problem is the possibility of inability to find the nerve when the STSL is completely bony. This would be more complicated when a suprascapular notch is coexisting with an underlying bony suprascapular foramen that contains SSN. Although this variation occurs very rarely (even less frequent than bony STSL) and was not detected in our study, it could be actually confusing when the suprascapular notch is empty

and the bony canal space is small (13, 18, 25, 26). Several etiologies have been suggested for this condition among which, an ossified anterior coracoscapular ligament seems to be the most possible (18). Other rare variations (not found in this study) like bifid and trifid STSL seem important during the exploration of SSN (19, 27).

In-vivo observation was the advantage of this study that could detect the potential problems about an anatomical variation for operation thought to be straightforward. Limited number of patients as well as the bias in estimating of frequency of dependent variables changed under the effect of brachial plexus injury is the disadvantage of this type of study.

Adequate knowledge about the possible anatomical variation of suprascapular notch and use of proper osteotomy equipment seems necessary during SSN release at scapula upper border of.

Masoud Yavari MD

Seyed Esmail Hassanpour MD

Department of Plastic Surgery, Shahid Beheshti University of Medical Sciences, Tehran, Iran

Hamidreza Alizadeh Otaghvar MD

Iran University of Medical Sciences, & Fellow of Plastic and Reconstructive Surgery, Department of Plastic Surgery, Shahid Beheshti University of Medical Sciences, Tehran, Iran

Hossein A. Abdolrazaghi MD

Department of Hand Surgery, Tehran University of Medical Sciences, Tehran, Iran

Amir R. Farhoud MD

Department of Orthopedics, Tehran University of Medical Sciences, Imam Hospital Complex, Joint Reconstruction Research Center, Tehran, Iran

References

1. Kostas-Agnantis I, Korompilias A, Vekris M, Lykissas M, Gkiatas I, Mitsionis G, et al. Shoulder abduction and external rotation restoration with nerve transfer. *Injury*. 2013; 44(3):299-304.
2. Rinker B. Nerve transfers in the upper extremity: a practical user's guide. *Ann Plast Surg*. 2015; 74(Suppl 4):S222-8.
3. Bertelli JA, Ghizoni MF. Reconstruction of C5 and C6 brachial plexus avulsion injury by multiple nerve transfers: spinal accessory to suprascapular, ulnar fascicles to biceps branch, and triceps long or lateral head branch to axillary nerve. *J Hand Surg Am*. 2004; 29(1):131-9.
4. Midha R. Nerve transfers for severe brachial plexus injuries: a review. *Neurosurg Focus*. 2004; 16(5):E5.
5. Emamhadi M, Chabok SY, Samini F, Alijani B, Behzadnia H, Firozabadi FA, et al. Anatomical variations of brachial plexus in adult cadavers; a descriptive study. *Arch Bone Jt Surg*. 2016; 4(3): 253-8.
6. Bhandari PS, Deb P. Dorsal approach in transfer of the distal spinal accessory nerve into the suprascapular nerve: histomorphometric analysis and clinical results in 14 cases of upper brachial plexus injuries. *J Hand Surg Am*. 2011; 36(7):1182-90.
7. Bhandari P, Deb P. Posterior approach for both spinal accessory nerve to suprascapular nerve and triceps branch to axillary nerve for upper plexus injuries. *J Hand Surg Am*. 2013; 38(1):168-72.
8. Elzinga KE, Curran MW, Morhart MJ, Chan KM, Olson JL. Open anterior release of the superior transverse scapular ligament for decompression of the suprascapular nerve during brachial plexus surgery. *J Hand Surg Am*. 2016; 41(7):e211-5.
9. Toneva D, Nikolova S. Morphology of suprascapular notch in medieval skeletons from Bulgaria. *Folia Morphol*. 2014; 73(2):210-5.
10. Rengachary SS, Burr D, Lucas S, Hassanein KM, Mohn MP, Matzke H. Suprascapular entrapment neuropathy: a clinical, anatomical, and comparative study: part 2: anatomical study. *Neurosurgery*. 1979; 5(4):447-51.
11. Polguy M, Sibiński M, Grzegorzewski A, Waszczykowski M, Majos A, Topol M. Morphological and radiological study of ossified superior transverse scapular ligament as potential risk factor of suprascapular nerve entrapment. *Biomed Res Int*. 2014; 2014(1):613601.
12. Tubbs RS, Nechtman C, D'Antoni AV, Shoja MM, Mortazavi MM, Loukas M, et al. Ossification of the suprascapular ligament: a risk factor for suprascapular nerve compression? *Int J Shoulder Surg*. 2013; 7(1):19-22.
13. Jangde S, Arya RS, Paikra S, Basan K. Bony suprascapular foramen, a potential site for suprascapular nerve entrapment: a morphological study on dried human scapulae. *Int J Anat Res*. 2015; 3(3):1316-20.
14. Hrdlička A. The adult scapula. Additional observations and measurements. *Am J Phys Anthropol*. 1942; 29(3):363-415.
15. Silva J, Abidu-Figueiredo M, Fernandes RM, Aureliano-Rafael F, Sgrott E, Silva S, et al. High incidence of complete ossification of the superior transverse scapular ligament in Brazilians and its clinical implications. *Int J Morphol*. 2007; 25(4):855-9.
16. Bhandari PS, Sadhotra LP, Bhargava P, Singh M, Mukherjee MK, Bhatore HS. Dorsal approach in spinal accessory to suprascapular nerve transfer in brachial plexus injuries: technique details. *Indian J Neurotrauma*. 2010; 7(1):71-4.
17. Bayramoğlu A, Demiryürek D, Tüccar E, Erbil M, Aldur MM, Tetik O, et al. Variations in anatomy at the suprascapular notch possibly causing suprascapular nerve entrapment: an anatomical study. *Knee Surg Sports Traumatol Arthrosc*. 2003; 11(6):393-8.
18. Rengachary SS, Neff JP, Singer PA, Brackett CE. Suprascapular entrapment neuropathy: a clinical, anatomical, and comparative study: part 1: clinical study. *Neurosurgery*. 1979; 5(4):441-6.
19. Polguy M, Jędrzejewski K, Majos A, Topol M. Coexistence of the suprascapular notch and the suprascapular foramen-a rare anatomical variation and a new hypothesis on its formation based on anatomical and radiological studies. *Anat Sci Int*. 2013; 88(3):156-62.
20. Badagabettu S, Kumar N, Patil J, Sirasanagandla SR, Shetty SD, Shanthakumar SR, et al. Existence of suprascapular notch and foramen in the same scapula. *J Morphol*. 2005; 23(2):121-2.
21. Nayak SB, Kumar N, Patil J, Rao SS, Shetty SD, Shanthakumar S, et al. Existence of suprascapular notch and foramen in the same scapula. *OA Case Rep*. 2014; 3(4):1-3.
22. Polguy M, Jędrzejewski K, Majos A, Topol M. Variations in bifid superior transverse scapular ligament as a possible factor of suprascapular entrapment: an anatomical study. *Int Orthop*. 2012; 36(10):2095-100.
23. Polguy M, Jędrzejewski K, Majos A, Topol M. The trifid superior transverse scapular ligament: a case report and review of the literature. *Folia morphol*. 2012; 71(2):118-20.
24. Sinkeet S, Awori K, Odula PO, Ogeng'o JA, Mwachaka PM. The suprascapular notch: its morphology and distance from the glenoid cavity in a Kenyan population. *Folia Morphol*. 2010; 69(4):241-5.
25. Thounaojam K, Karam R, Singh NS. Ossification of transverse scapular ligament. *J Evolut Med Dent Sci*. 2013; 2(12):1790-91.
26. Natsis K, Trifon T, Ioannis G, Konstantinos V,

Efthymia P, Prokopios T. A bony bridge within the suprascapular notch. Anatomic study and clinical relevance. Aristotle Univ Med J. 2008; 35(1):204-11.
27.Natsis K, Totlis T, Tsikaras P, Appell H, Skandalakis

P, Koebke J. Proposal for classification of the suprascapular notch: a study on 423 dried scapulas. Clin Anat. 2007; 20(2):135-9.