

**LETTER TO THE EDITOR****Intrapelvic Protrusion of a Broken Guide Wire Fragment during Fixation of a Femoral Neck Fracture**

We read with great interest the paper by Ahmadreza Afshar about intrapelvic protrusion of a broken guide wire fragment during fixation of a femoral-neck fracture and its removal by ilioinguinal extraperitoneal approach (1). We share our experience of a similar case wherein we used an 'iliofemoral' approach to successfully remove the broken transfixing guidewire from the hip joint. Although iliofemoral approach is similar to the lateral window of conventional ilioinguinal approach, yet it is less invasive, has lesser complications, requires less expertise and is easily reproducible by an average orthopaedic trauma surgeon (2). Ilioinguinal approach has fair chances of surgical wound infection, iatrogenic nerve palsy and vascular injury, significant ectopic bone formation, and death from pulmonary embolus even in hands of experts (3).

A 32-year old male was referred to us for broken guide wire removal from the hip joint. He had sustained right-sided sub-trochanteric femur fracture after a road-side accident. While he was undergoing fracture fixation at a local hospital dynamic hip screw (DHS) guide wire broke and migrated into the pelvis transfixing the hip joint. On presentation to our hospital radiograph [Figure 1A] and

computed tomography (CT) scan [Figure 1B] of the hip joint done and confirmed the exact position and point of exit of the guide wire. We used the aforementioned iliofemoral approach [Figure 1D]. Iliac blade osteotomy was done starting from the summit of the iliac crest to midway between anterior superior iliac spine and anterior inferior iliac spine along with attached tensor fascia lata muscle. As the wire was very deep in the pelvis, this approach allowed good exposure and manipulation under direct vision and minimised the chances of injury to intra pelvic contents. Wire was removed in one piece without any complications [Figure 1C].

Breakage of DHS guide wire during surgery and its migration into the pelvis through the hip joint is a rare complication and its removal can be very challenging for the surgeon. We have previously reported a series of 4 cases with technical note for wire removal and recommended that the surgical approach to the wire should be individualized depending upon exact location of wire tip in the hip joint or pelvis (4). We recommend that surgical approaches for removal of these broken or migrated wires should be individualized depending upon

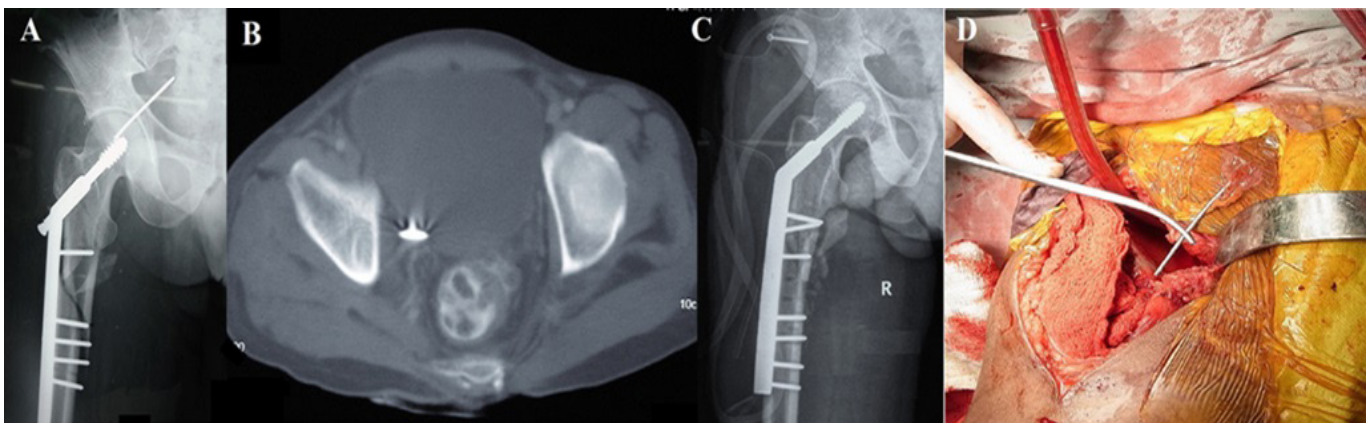


Figure 1A-D. (A) Antero-posterior radiograph of hip and proximal femur showing broken transfixing guidewire (B) Computed tomography scan of pelvis axial section showing guidewire tip exiting from quadrilateral plate (C) Postoperative radiograph of hip and proximal femur after removal of guidewire from hip joint showing iliac bone osteotomy fixed with screw (D) Intra operative clinical photograph of the surgical site showing the exposure with broken guidewire.

the exact location of the wire tip in the hip joint or pelvis and need for exposure.

In the index case, the iliofemoral approach with iliac blade osteotomy provided an excellent exposure and space to manipulate the wire exiting from the quadrilateral plate even though it was deep inside the pelvis.

Uttam Chand Saini MS  
Nirmal Raj Gopinathan MS  
Sameer Aggarwal MS  
Ramesh Sen MS PhD  
Department of Orthopedics, Postgraduate Institute of  
Medical Education and Research, Chandigarh, India

### References

1. Afshar A. Intrapelvic protrusion of a broken guide wire fragment during fixation of a femoral neck fracture. Arch Bone Jt Surg. 2017; 5(1):63-5.
2. Sen RK, Tripathy SK, Aggarwal S, Goyal T, Meena DS, Mahapatra S. A safe technique of anterior column lag screw fixation in acetabular fractures. Int Orthop. 2012; 36(11):2333-40.
3. Matta JM. Operative treatment of acetabular fractures through the ilioinguinal approach: a 10-year perspective. J Orthop Trauma. 2006; 20(1 Suppl):S20-9.
4. Sen RK, Tripathy SK, Aggarwal S, Agarwal A, Goyal T, Tahasildar N, et al. Broken Kirschner or guide-wire retrieval: a report of 4 cases. Hip Int. 2010; 20(4):551-4.