

CASE REPORT

Complicated Congenital Dislocation of the Knee: A Case Report

Firooz Madadi, MD; Mohammad A. Tahririan, MD; Mohsen Karami, MD; Firoozeh Madadi, MD

*Research performed at Akhtar Hospital, Tehran, Iran**Received: 21 December 2015**Accepted: 23 January 2016***Abstract**

Congenital dislocation of the knee (CDK) is a rare disorder. We report the case of a 7-year-old girl with bilateral knee stiffness, marked anterior bowing of both legs, and inability to walk without aid.

Radiologic investigation revealed bilateral knee joint dislocation accompanied by severe anterior bowing of both tibia proximally and posterior bowing of both femur distally, demonstrating a complicated congenital knee dislocation.

Two-staged open reduction with proximal tibial osteotomy was performed to align the reduced knee joints. The patient was completely independent in her daily activities after surgical correction.

Keywords: Congenital knee dislocation, Complication

Introduction

First described by Chateline, congenital dislocation of the knee (CDK) is a rare disorder with an incidence of 80-100 times less than the developmental dysplasia of the hip (1). CDK is often associated with other musculoskeletal anomalies, among which DDH is the most common deformity (2-4). It is more common in females and can be uni- or bilateral. The exact etiology of CDK is unknown; however, the associated factors can be categorized as extrinsic, which is due to the abnormal intrauterine pressure leading to intrauterine malposition, or intrinsic, which is due to the genetic abnormalities and neuromuscular imbalances (5, 6). The most common theory is based on the changes in the quadriceps muscle which can be found in all patients.

Management starts with closed reduction and cast or splinting (7-12). Surgical reduction is indicated when conservative measures fail or when the child is referred after the age of one year.

In this case report, we present a child with bilateral CDK.

Case presentation

A 7-year-old girl with bilateral CDK was referred with the history of closed reduction and serial casting at the age of 4 years. The family history of musculoskeletal disorder was negative. The patient was able to walk only with the aid of elbow crutches. The range of both knees was -30° to -10° in recurvatum. Further

assessment revealed no abnormality in the hip or ankle joints. Marked quadriceps atrophy was also noted. X-ray revealed a bilateral dislocation of the knees with marked anterior bowing of proximal tibial metaphyses related to prior manipulation about the knees. Moreover, a reverse deformity (posterior bowing) was noted in both distal femur metaphyses [Figure 1].

Treatment was planned in two stages. In the first stage, the knee was reduced after releasing the anterior capsule, tensor fasciae latae, and lateral retinaculum [Figure 2]. Both cruciate ligaments and menisci were normal. Quadriceps lengthening (around 12 cm) was done by Z-plasty along with excision of fibrous tissues beneath the contracted quadriceps. Ninety and 100 degrees of flexion were achieved at the end of the surgery in the left and right knees, respectively.

In the second stage, extension osteotomy of both proximal tibia was done below the tibial tubercles using a minimal incision with no internal fixation [Figure 3]. At the last follow up after 2 years, flexion of the right and left knee was 90 and 85 degrees, respectively [Figure 4]. The patient was able to perform the individual daily activities with a painless stable knee.

Discussion

The patient was a 7-year-old girl with bilateral CDK who was treated with manipulation and closed reduction at the age of 4, instead of anterior capsular release and removal of obstacles and open reduction. The

Corresponding Author: Mohammad A. Tahririan, Isfahan University of Medical Sciences, Isfahan, Iran
Email: tahririan@med.mui.ac.ir



THE ONLINE VERSION OF THIS ARTICLE
ABJS.MUMS.AC.IR

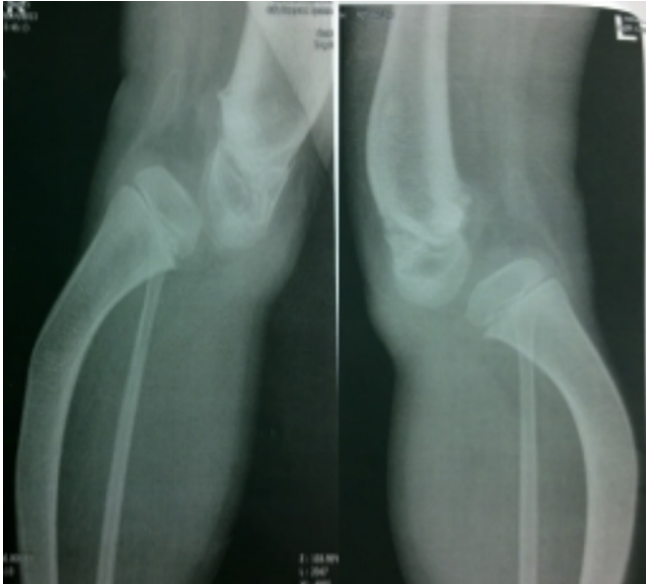

Figure 1. Bilateral congenital dislocation of the knee and anterior bowing of proximal tibia.

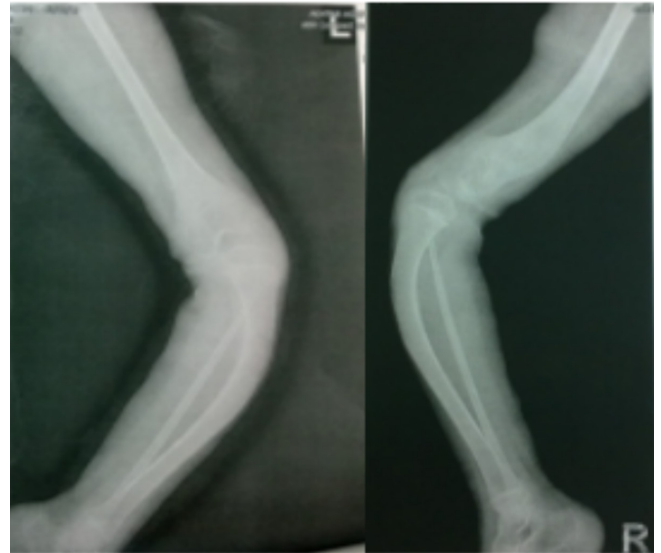


Figure 2. Open reduction of both knee joints.

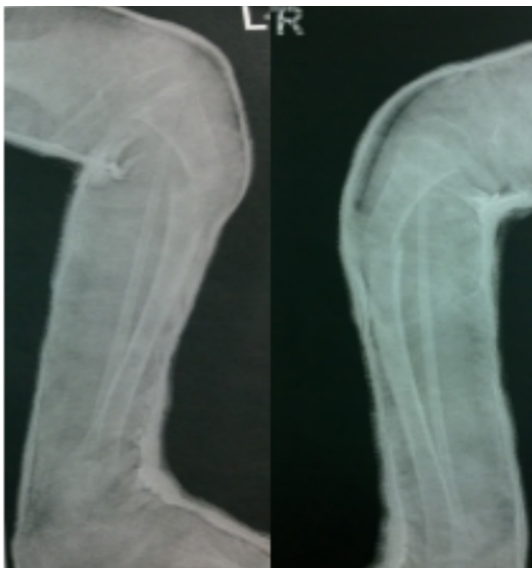

Figure 3. Bilateral osteotomy below the tibial tubercle.

result of primary conservative treatment was bilateral physeal injury in both distal femur and proximal tibia. Nonoperative treatment includes gradual stretching and serial casting, which is the most commonly recommended treatment in early infancy. Bensahel et al recommended surgery in children older than 3 months if nonoperative modalities failed (1).

The most common findings during surgery are tight anterior capsule, along with quadriceps fibrosis and contracture, especially in the inferior and lateral parts. A review of the literature revealed that the results of surgery seem to be most favorable when performed before the age of 2 years (1, 10, 13).

Oetgen et al stated that the most striking observation in patients with CDK is the high incidence (78%) of knee instability (14). Bell et al, believe that the cruciate ligament abnormalities are secondary to the delay in treatment (13). In contrast, Katz et al proposed that the cruciate ligament abnormalities can be primarily observed in older children (15). Although most authors have reported satisfactory results with surgery in childhood, Johnson et al believe that the results are poorer in older children with CDK managed by V-Y

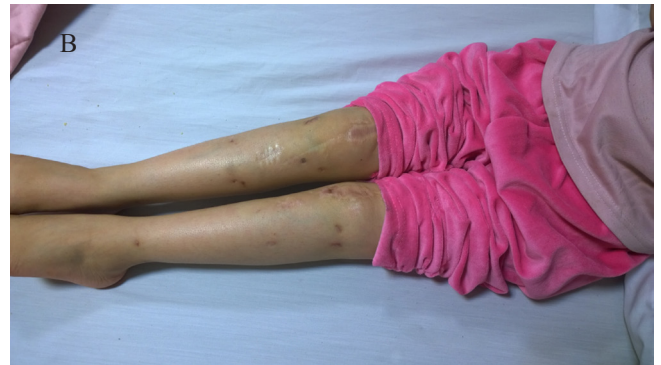
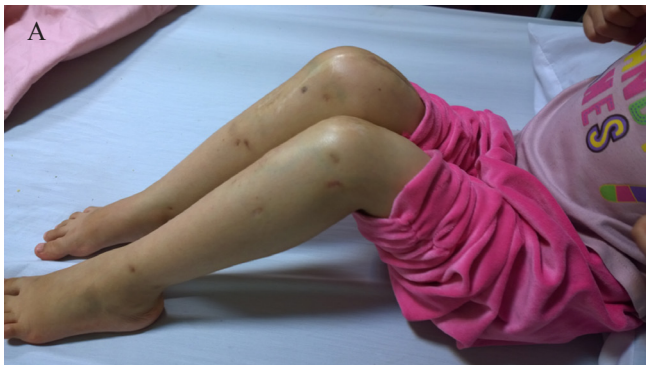
Figure 4. A: 90 deg flex B: full ext 2years after the final surgery.

advancement or Z-plasty of the quadriceps; they concluded that prognosis is most favorable in unilateral cases, and when surgery is performed before the age of 2 years (10). However, some reports of the late surgery in the neglected CDK showed promising results. Oetgen et al. noted that both quadricepsplasty and femoral shortening lead to comparable clinical and patient self-reported functional results (14). Kumar et al. reported a late surgery in a neglected case of CDK. A 12-year old patient was operated in three stages including knee joint distraction by ring fixator, followed by open reduction, and finally supracondylar extension osteotomy, in which they achieved good functional outcomes (16).

Manipulation and closed reduction for CDK should preferably be performed in early infancy after which

patella should be manipulated passively. Passive motion of the patella should be confirmed; otherwise, the knee is manipulated at the physal plate of either distal femur or proximal tibia. Moreover, the results of surgery in the late childhood are not as disappointing as in the earlier reports.

Firooz Madadi MD
Firoozeh Madadi MD
Mohsen Karami MD
Shahid Beheshti University of Medical Sciences, Tehran, Iran

Mohammad A. Tahririan MD
Isfahan University of Medical Sciences, Isfahan, Iran

References

- Bensahel H, Dal Monte A, Hjelmstedt A, Bjerkreim I, Wientroub S, Matasovic T, et al. Congenital dislocation of the knee. *J Pediatr Orthop.* 1989; 9(2):174-7.
- Müller M, Strecker W. Congenital knee dislocation in Larsen syndrome treated by arthroplasty. *Orthopade.* 2010; 39(4):444-8.
- Mahirogullari M, Pehlivan O, Kiral A, Cakmak S. Management of the bilateral congenital dislocation of the hip and knee: a case report. *Arch Orthop Trauma Surg.* 2006; 126(9):634-6.
- Naik PV. Management of congenital knee dislocation. *Curr Orthop Pract.* 2013; 24(1):43-8.
- de Castro Lopez MJ, Iglesias Deus A, Rodriguez Vidal A, Lopez Suarez O, Perez Munuzuri A, Couce Pico ML. Knee dislocation in the delivery room. *J Pediatr.* 2014; 165(4):871.
- Yalaburgi SB. Congenital dislocation of the knee. A report of 5 cases. *S Afr Med J.* 1981; 59(22):804-6.
- Ferris B, Aichroth P. The treatment of congenital knee dislocation. A review of nineteen knees. *Clin Orthop Relat Res.* 1987; 1(216):135-40.
- Carlson DH, O'Connor J. Congenital dislocation of the knee. *AJR Am J Roentgenol.* 1976; 127(3):465-8.
- Ko JY, Shih CH, Wenger DR. Congenital dislocation of the knee. *J Pediatr Orthop.* 1999; 19(2):252-9.
- Johnson E, Audell R, Oppenheim WL. Congenital dislocation of the knee. *J Pediatr Orthop.* 1987; 7(2):194-200.
- Schreiner S, Ganger R, Grill F. Congenital dislocation of the knee (CDK). *Orthopade.* 2012; 41(1):75-82.
- Makhmalbaf H, Kachoei AR, Mazloumi SM, Ebrahimzadeh M, Omid-Kashani F, Seyf P, et al. Bilateral one-half spica cast after open reduction and pelvic osteotomy in the developmental dislocation of the hip. *Iran Red Crescent Med J.* 2013; 15(12):e13366.
- Bell MJ, Atkins RM, Sharrard WJ. Irreducible congenital dislocation of the knee. Aetiology and management. *J Bone Joint Surg Br.* 1987; 69(3):403-6.
- Oetgen ME, Walick KS, Tulchin K, Karol LA, Johnston CE. Functional results after surgical treatment for congenital knee dislocation. *J Pediatr Orthop.* 2010; 30(3):216-23.
- Katz MP, Grogono BJ, Soper KC. The etiology and treatment of congenital dislocation of the knee. *J Bone Joint Surg Br.* 1967; 49(1):112-20.
- Kumar J, Dhammi IK, Jain AK. Neglected surgically intervened bilateral congenital dislocation of knee in an adolescent. *Indian J Orthop.* 2014; 48(1):96-9.