

CASE REPORT

Femoral Condyle Fracture during Revision of Anterior Cruciate Ligament Reconstruction: Case Report and a Review of Literature

Sohrab Keyhani, MD; Arash Sharafat Vaziri, MD; Hossein shafiei, MD; Mohsen Mardani-Kivi, MD

Research performed at Akhtar Hospital, Tehran, Iran

Received: 22 August 2014

Accepted: 25 December 2014

Abstract

A rare and devastating complication following anterior cruciate ligament (ACL) revision reconstruction is femoral fracture.

A 35-year old male soccer player with a history of ACL tear from one year ago, who underwent arthroscopic ACL reconstruction and functioned well until another similar injury caused ACL re-rupture. Revision of ACL reconstruction was performed and after failure of graft tension during the pumping, a fluoroscopic assessment showed a femoral condyle fracture. The patient referred to our knee clinic and was operated on in two stages: first fixation of the fracture and then ACL re-revision after fracture healing was complete.

Not inserting multiple guide pins, keeping a safe distance from the posterior cortex and giving more attention during graft tensioning, especially in revision surgeries, are all small points that can reduce the risk of fracture during the revision of ACL reconstruction.

Key words: Anterior cruciate ligament (ACL), Complication, Condylar fracture, Revision reconstruction

Introduction

Anterior cruciate ligament (ACL) reconstruction is the sixth most commonly performed orthopedic procedure with more than 100,000 surgeries performed annually in the United States (1-5). Revision rates have been reported at 5-25%, and this number continues to rise (2,6). Complications associated with this surgery occur in 1.8% to 24% of the procedures, which include joint stiffness, patellar fracture, infection, hardware failure, graft failure, wound complications, deep vein thrombosis and periarticular fractures (1,3-5,7). A rare and devastating complication following ACL reconstruction and revision reconstruction is femoral fracture. This complication has been attributed to stress concentration on the femoral tunnel or multiple pin insertions acting as stress risers. Literature on this rare complication is scarce with few case reports (3-5,7). In this care report we describe a patient with a femoral condyle fracture that occurred during revision of ACL reconstruction. To the best of our knowledge, there is no

other case report in the literature introducing a femoral condyle fracture during arthroscopic ACL reconstruction or revision reconstruction.

Case Report

A thirty-five-year-old male employee referred to our knee clinic with a history of femoral condyle fracture that had occurred during ACL revision reconstruction surgery at a private clinic. The previous year the patient had an arthroscopic ACL reconstruction with hamstring autograft due to ACL tear. He reported that he functioned well until another twisting injury occurred while playing soccer. After evaluation by an orthopedic surgeon in another clinic, the diagnosis of ACL graft tear was made and he underwent a revision of ACL reconstruction using the Endobutton technique. The surgeon had thought that previous tunnels on the tibial and femoral side were in a good position (while we believe that the femoral tunnel had been actually located anteriorly near 12 clock), so he decided to reuse these

Corresponding Author: Hossein shafiei, Orthopedic Department, Avicenna Hospital, Mazandaran University of Medical Sciences, Sari, Iran.
Email: shafiei_h@yahoo.com



THE ONLINE VERSION OF THIS ARTICLE
ABJS.MUMS.AC.IR

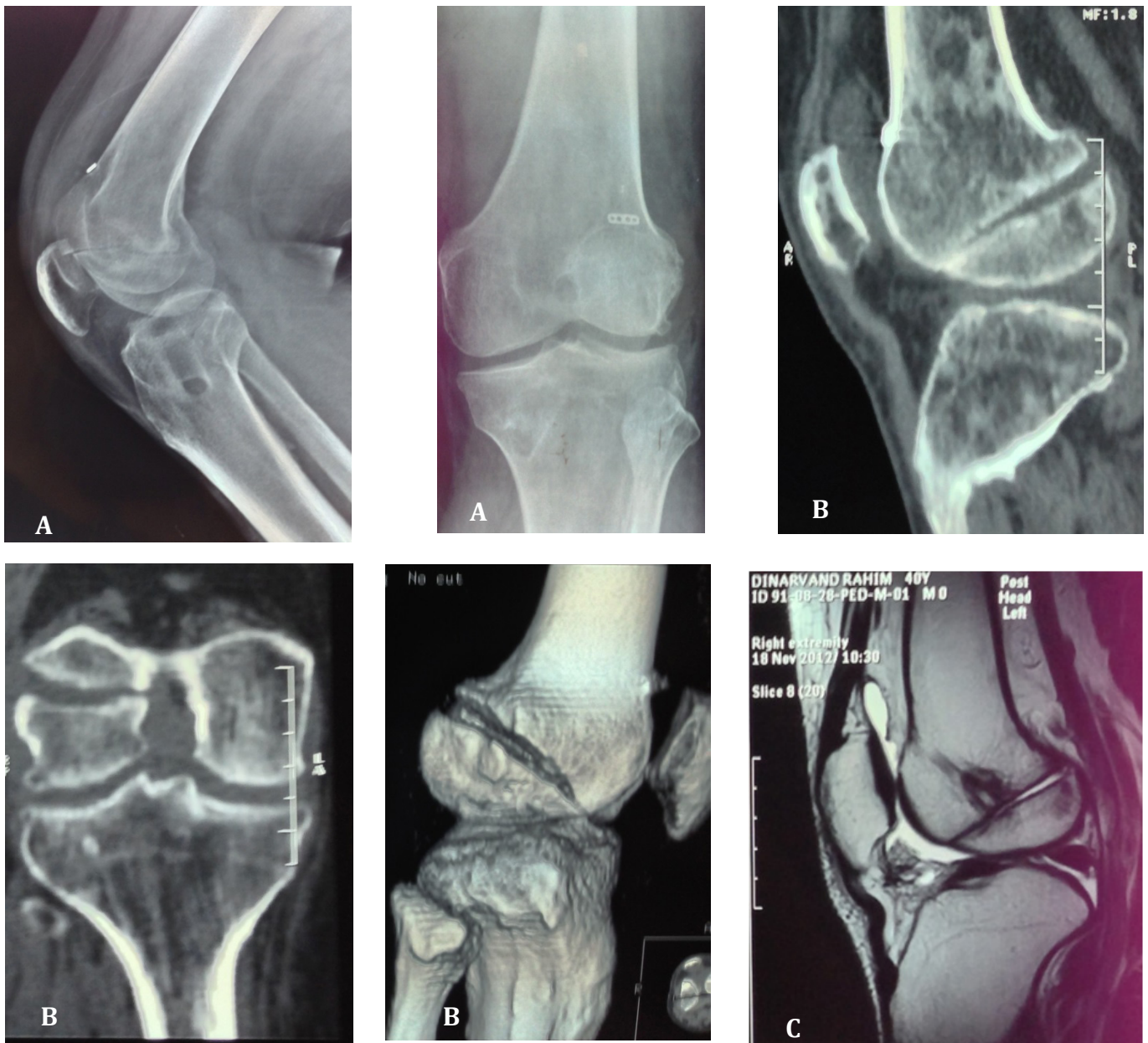


Figure 1. (a) Radigraph, (b) CT Scan and (c) MR image of the Patient.

tunnels. Therefore, after preparing an 11-mm-diameter allograft of the posterior tibial tendon, the pre-existing tunnels were reamed with an 11-mm reamer. Tunnel length on the femoral side was 50 mm and graft length in the tunnel was 30 mm. Unfortunately after passing the graft and while the surgeon was trying to pump the graft, the tension suddenly failed. Fluoroscopy revealed a coronal plane fracture of the lateral femoral condyle. Thus, the surgeon decided to stop the operation and after performing imaging studies (CT scan and MRI) the patient was referred to our clinic [Figure 1].

We evaluated the patient's imaging and decided to

operate on him in two stages. First, we treated the femoral condyle fracture using the lateral para-patellar approach and fixed the fracture with multiple screws and grafted the canal with cancellous bone. Then we decided to re-revision the ACL reconstruction after complete healing of the fracture and screw removal. Figure 2 shows the patient's post-operation radiograph after 2 months.

Discussion

As the number of ACL reconstructions performed each year continues to grow, so does the number of revision surgeries (6). Revision of ACL reconstruction is

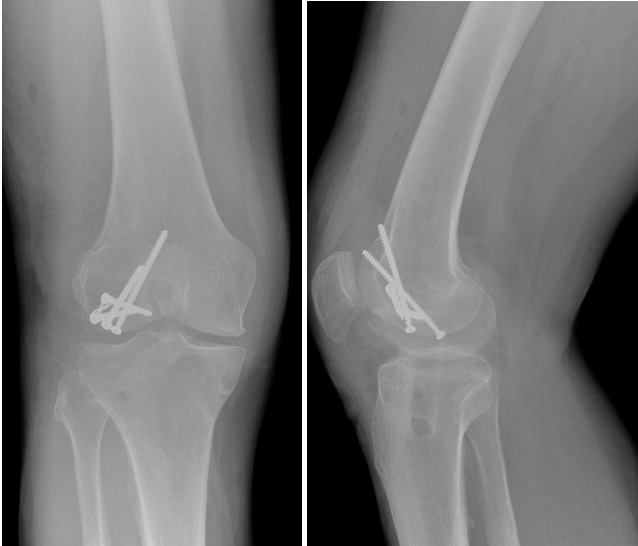

Figure 2 Post-operation Radiograph.

a complicated operation by nature, since the location of the primary graft tunnel and previous fixation hardware limits the choice of new tunnel placement and fixation options (7). It has been reported that improper femoral or tibial tunnel placement is responsible for up to 60% of graft failures in primary ACL reconstruction (2,7). Femoral condyle fracture is an extremely rare complication of ACL reconstruction surgery. All previous reports have presented femoral fractures occurring after ACL reconstruction and none have been during the revision procedure (1,3-5,7). Decreased bone mineral density up to 20% has been observed following knee ligament injury that might additionally contribute to the fracture of femoral condyle during or after ACL reconstruction because of decreased bending stress on the distal femur (1,4). This condition might be persistent even up to 2 years after ACL reconstruction despite aggressive rehabilitation, and there is predilection of bone loss especially at the lateral femoral condyle and medial tibial plateau (1). Given these facts, chemotherapy with bisphosphonates might be effective in patients with ACL injury by reducing bone resorption.

It is well documented that bone tunnel enlargement after ACL reconstruction occurs in up to 68% of cases, with several etiologies including multiple biological and mechanical factors having been described (3,4). This phenomenon as well as the need for further reaming of the tunnel during the revision surgery, enhances the probability of increasing the tunnel diameter to more than 20% of the bone diameter. This large femoral tunnel likely acts as a localized stress riser, and will reduce the energy-absorbing capacity of the distal femur and lower the stress threshold of the bone to much lower applied loads (3-5). Another potential factor suggested by some authors in weakening the bone is multiple guide pin insertions (1,3,4). Geometry of the distal femur is complex and geometric analysis of this part of the femur has shown that the thinnest cortical shell is located in the

posterior aspect of the condyle (1,3,4). Considering this point and the fact that proper positioning of the femoral tunnel is achieved when it is located as far posteriorly as possible (4 mm away from the posterior cortex), it means that the surgeon must pay especial attention to avoid disruption of the posterior cortex while placing the femoral tunnel (3,4, 6). Malposition of the femoral tunnel in index reconstruction surgery will oblige the surgeon to make a new tunnel that will eventually increase the risk of fracture (2).

As we observed during the open reduction and internal fixation of the femoral condyle in our case, it seems that anterior placement of the femoral tunnel was responsible for failure of the index procedure and reuse of this improper tunnel was the second mistake. However, this tunnel malposition cannot completely explain the failure of ACL reconstruction and femoral condyle fracture.

Considering the time interval between index surgery and revision surgery (1 year), reduced bone mineral density might also play some role in causing femoral condyle fracture, especially as the surgeon had reported that the fracture occurred during tensioning of the graft by pumping the knee.

In conclusion, considering the increasing number of revisions of ACL reconstructions nowadays, careful consideration of all the potential complications is important, particularly in devastating ones such as condylar fracture. Pre-operative planning using a three dimensional CT scan in order to obtain detailed information of the tunnel position as well as using the three-portal approach for clear visualization of the medial wall of the lateral femoral condyle as described by Hofbauer et al. will help the surgeon in placing the tunnel in the optimum position (2). Avoiding the insertion of multiple guide pins, keeping a safe distance from the posterior cortex, not reaming the canal for further enlargement in case of using the index tunnel and paying more attention during graft tensioning particularly in revision surgeries are all small but significantly important points that will reduce the risk of fracture during the revision of ACL reconstruction.

Sohrab Keyhani MD
Orthopedic Department, Akhtar Hospital, Shahid-
Beheshti University of Medical Sciences, Tehran, Iran

Arash Sharafat Vaziri MD
Orthopedic Department, Khatam-Anbia Hospital, Tehran,
Iran

Hossein shafiei MD
Avicenna Hospital, Mazandaran University of Medical
Sciences, Sari, Iran

Mohsen Mardani-Kivi MD
Trauma Road Research Center, Poursina Hospital, Guilan
University Of Medical Sciences, Rasht, Iran

References

1. Han Y, Sardar Z, McGrail S, Steffen T, Martineau PA. Peri-anterior cruciate ligament reconstruction femur fracture: a biomechanical analysis of the femoral tunnel as a stress riser. *Knee Surg Sports Traumatol Arthrosc.* 2011;19:77-85.
2. Hofbauer M, Muller B, Murawski CD, Baraga M, van Eck CF, Fu FH. Strategies for revision surgery after primary double-bundle anterior cruciate ligament (ACL) reconstruction. *Knee Surg Sports Traumatol Arthrosc.* 2013; 21(9):2072-80.
3. Julien TP, Ramappa AJ, Rodriguez EK. Femoral condylar fracture through a femoral tunnel eleven years after anterior cruciate ligament reconstruction: a case report. *J Bone Joint Surg Am.* 2010; 92:963-7.
4. Mithoefer K, Gill TJ, Vrahas MS. Supracondylar femoral fracture after arthroscopic reconstruction of the anterior cruciate ligament. A case report. *J Bone Joint Surg Am.* 2005; 87(7):1591-6.
5. Wilson TC, Rosenblum WJ, Johnson DL. Fracture of the femoral tunnel after an anterior cruciate ligament reconstruction. *Arthroscopy.* 2004; 20(5):45-7.
6. Pascual-Garrido C, Carbo L, Makino A. Revision of anterior cruciate ligament reconstruction with allografts in patients younger than 40 years old: a 2 to 4 year results. *Knee Surg Sports Traumatol Arthrosc.* 2014; 22(5):1106-11
7. Coobs BR, Spiridonov SI, LaPrade RF. Intra-articular lateral femoral condyle fracture following an ACL revision reconstruction. *Knee Surg Sports Traumatol Arthrosc.* 2010;18(9):1290-3.