

**CASE REPORT**

# Bilateral Simultaneous Femoral Neck and Shafts Fractures – A Case Report

Amirreza Sadeghifar, MD; Alireza Saied, MD

*Research performed at Kerman University of Medical Sciences, Kerman, Iran**Received: 2 May 2014**Accepted: 25 August 2014***Abstract**

Simultaneous fractures of the femoral neck and shaft are not common injuries, though they cannot be considered rare. Herein, we report our experience with a patient with bilateral occurrence of this injury. Up to the best of our knowledge this is the first case reported in literature in which correct diagnosis was made initially. Both femurs were fixed using broad 4.5 mm dynamic compression plate and both necks were fixed using 6.5 mm cannulated screws. Femur fixation on one side was converted to retrograde nailing because of plate failure. Both neck fractures healed uneventfully. In spite of rarity of concomitant fractures of femoral neck and shaft, this injury must be approached carefully demanding especial attention and careful device selection.

**Key words:** Bilateral, Femur, Fracture, Intramedullary, Neck, Shaft

**Introduction**

Simultaneous fractures of the femoral neck and shaft are not common injuries, though they cannot be considered rare having an incidence of 2-6% of all femoral fractures (1-3). These injuries are too rare to encounter during ones practice; nevertheless, they are common enough to deserve a classification system (4). The most important point about this entity is the diagnosis, which usually happens late in many cases besides the management, which is a matter of controversy (5). Herein we report our experience with a patient having bilateral simultaneous femoral neck and shaft fractures.

**Case presentation**

The patient was a 25 year old man, who sustained several fractures during a motor vehicle accident (MVA) including bilateral comminuted femoral shaft fractures and bilateral femoral neck fractures, right both bone forearm fracture, right distal radius intraarticular fracture, left lisfranc fracture-dislocation, and second metatarsal neck fractures [Figure 1]. Both femoral neck fractures were basicervical that was hard to diagnose on standard pelvis radiography, however, fractures were visible on plain radiography done for visualizing femoral fractures [Figure 1]. Because the femoral neck fractures were nondisplaced, they were

fixed using in situ screws before trying to fix femoral shaft fractures by plates. [Figure 2] Other fractures also were fixed by either open or closed techniques. Patient was instructed to bear no weight for 2-3 months postoperatively. He came back to the clinic 6 weeks after being discharged with failure of the right femur plate while he was walking with no crutches [Figure 3]. We removed the plate and replaced it with a retrograde nail [Figure 4]. The patient was asymptomatic after 8 months showing complete union of all fractures.

**Discussion**

Herein, we reported our experience with a patient having bilateral fractures of femoral neck and shaft. In a report of concurrent femoral neck and shaft fractures, one case had bilateral femoral neck and shaft fractures (6); however, it was diagnosed days after femoral shaft fracture fixation. A second probable case was described in a systematic review with no further details (7).

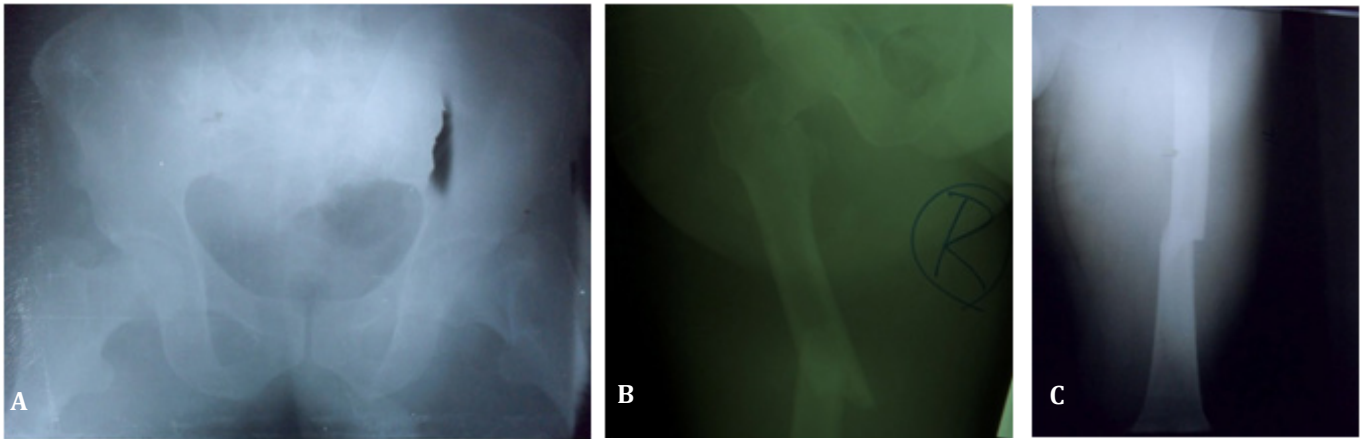
Although simultaneous fractures of femoral shaft and neck cannot be considered rare, these injuries are still a challenge for orthopedic surgeons. Neglected cases are frequent and this may lead to severe complications for patients (8). Even when it is diagnosed promptly, proper management may prove to be difficult.

**Corresponding Author:** Alireza Saied, Orthopedics Department, Dr. Bahonar Hospital, Kerman Neuroscience Research Center, Kerman, Iran.

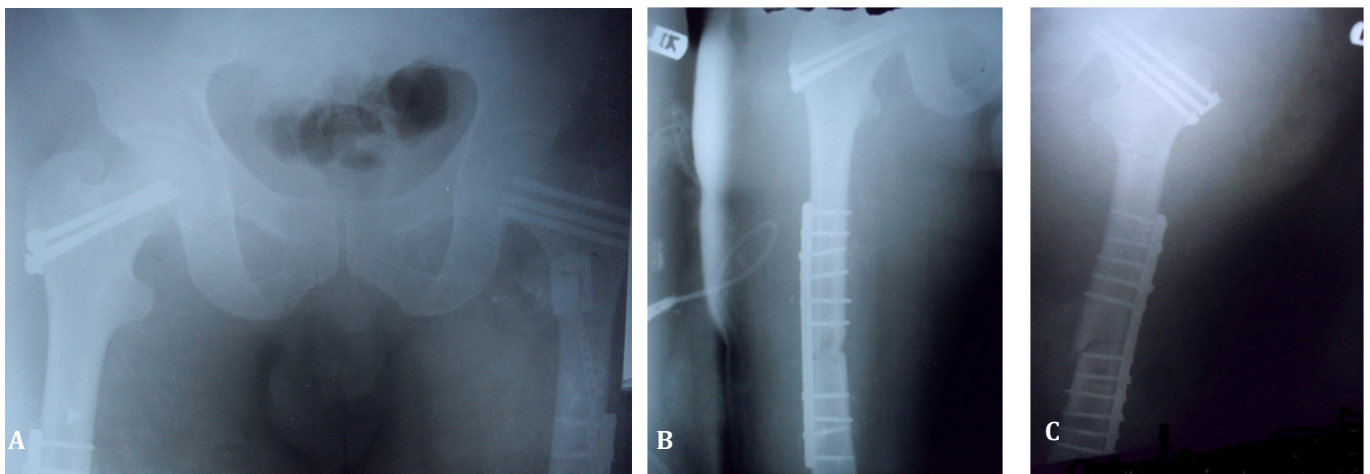
Email: arsaied@kmu.ac.ir



THE ONLINE VERSION OF THIS ARTICLE  
ABJS.MUMS.AC.IR



**Figure 1.** a Standard pelvis radiography and b, c right and left femur radiographies demonstrating bilateral femoral neck fractures that are almost hard to diagnose on standard pelvis radiography.



**Figure 2.** a (right) Postoperative radiography of patient demonstrates fixation of both femoral neck fractures using cannulated screws. b, c (left) postoperative radiographies show both femoral shaft fracture fixation using plate and screws.

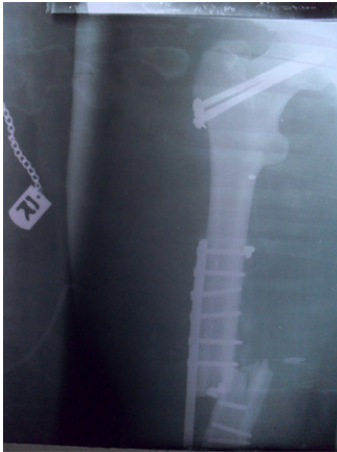These injuries are almost always resulted from high-energy trauma and usually are accompanied with several associated fractures. The suggested mechanism resulting to ipsilateral femoral shaft and neck fractures is compression of the femoral head against the acetabular roof while hip is in either abduction or adduction (9). Considering this, the mechanism of injury in our patient may have been a direct trauma because simultaneous indirect force on both hips and femurs seems unlikely although not impossible.

Several methods of treatment have been suggested for this complex pattern of injury including antegrade intramedullary nail along with separate screws for neck fracture (10, 11), plate fixation of shaft fracture together with cannulated screws for neck fracture (12), retrograde intramedullary nail for shaft fracture together with separate screws for neck fracture (3), and reconstruction intramedullary nail (13, 14). We managed this patient using broad 4.5 mm dynamic

compression plates for femur fractures and 6.5 mm cannulated screws for each femoral neck fracture.

The shortcoming in our technique was that we fixed the right femoral neck fracture with only two screws, nonetheless, it healed uneventfully, which could potentially be a point of failure. On the other hand, shaft fracture fixation was insufficient, which presented with early failure of fixation because of using too few screws (only four screws) in the distal segment of the femur. Considering bilateral high-energy injury demands a stronger weight shearing devices such as reconstruction nails, which is surely much more technically demanding. On the other hand, a fracture table may be mandatory, which may theoretically displace neck fractures (15). Possibly, the best option would have been a retrograde nail for femoral shaft fracture, which proved to be safe in the experience of other surgeons as well (16).

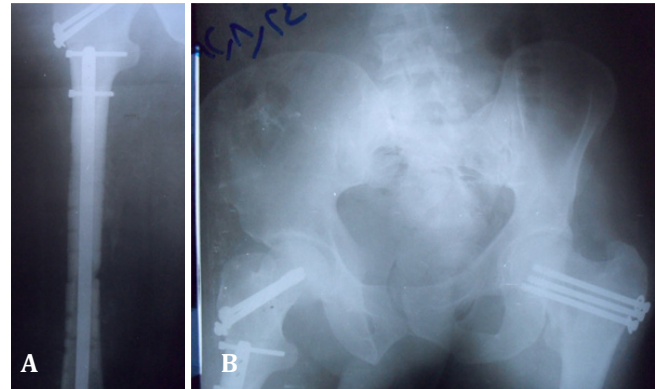
Having concurrent fractures of neck and shaft in



**Figure 3.** Anteroposterior radiography of the right femur shows plate failure because of insufficient fixation.

mind, standard pelvis radiography is necessary for any patient referring with femoral shaft fracture in order to prevent missed diagnosis and subsequent complications. In fact, almost 30% of these fractures may be missed initially (7).

We achieved good results in the presented patient in regards to femoral neck fractures, in which the short-term result was in accordance with the results achieved in similar studies (7). Most of femoral neck fractures associated with shaft fractures are nondisplaced or minimally displaced. The explanation has been dissipation of energy between the shaft and neck, so that the fractured neck tolerates fewer traumas than



**Figure 4.** a (right) Postoperative radiography of the right femur after plate removal and replacing it with retrograde nail. b (left) both neck fractures healed during follow-up period.

the usual neck fractures. Thus, nonunion is rare in this situation (17).

Amirreza Sadeghifar MD  
Medical Informatics Research Center, Dr Bahonar Hospital, Kerman University of Medical Sciences, Kerman, Iran

Alireza Saied MD  
Kerman Neuroscience Research Center, Dr Bahonar Hospital, Kerman University of Medical Sciences, Kerman, Iran

## References

1. Wolinsky PR, Johnson KD. Ipsilateral femoral neck and shaft fractures. *Clin Orthop Relat Res.* 1995; 318:81-90.
2. Watson JT, Moed BR. Ipsilateral femoral neck and shaft fractures: complications and their treatment. *Clin Orthop Relat Res.* 2002; 399:78-86.
3. Peljovich AE, Patterson BM. Ipsilateral femoral neck and shaft fractures. *J Am Acad Orthop Surg.* 1998; 6:106-113.
4. Winquist RA. Locked femoral nailing. *J Am Acad Orthop Surg.* 1993; 1(2):95-105.
5. Tornetta P 3rd, Kain MS, Creevy WR. Diagnosis of femoral neck fractures in patients with a femoral shaft fracture, Improvement with a standard protocol. *Bone Joint Surg Am.* 2007; 89:39-43
6. Schatzker J, Barrington TW. Fractures of the femoral neck associated with fractures of the same femoral shaft. *Can J Surg.* 1968; 11(3):297-305.
7. Alho A. Concurrent ipsilateral fractures of the hip and shaft of the femur. A systematic review of 722 cases. *Ann Chir Gynaecol.* 1997; 86(4):326-36.
8. McDonald LS, Tepolt F, Leonardelli D, Hammerberg EM, Stahel PF. A cascade of preventable complications following a missed femoral neck fracture after antegrade femoral nailing. *Patient Saf Surg.* 2013, 23; 7(1):16.
9. Abalo A, Dossim A, Ouro Bangna AF, Tomta K, Assiobo A, Walla A. Dynamic hip screw and compression plate fixation of ipsilateral femoral neck and shaft fractures. *J Orthop Surg (Hong Kong).* 2008 Apr; 16(1):35-8.
10. Wiss DA, Sima W, Brien WW. Ipsilateral fractures of the femoral neck and shaft. *J Orthop Trauma.* 1992; 6:159-66.
11. Wu CC, Shih CH. Ipsilateral femoral neck and shaft fractures. Retrospective study of 33 cases. *Acta Orthop Scand.* 1991; 62:346-51.
12. Chen CH, Chen TB, Cheng YM, Chang JK, Lin SY, Hung SH. Ipsilateral fractures of the femoral neck and shaft. *Injury.* 2000; 31:719-22.

13. Alho A, Ekeland A, Groggaard B, Dokke JR. A locked hip screw-intramedullary nail (cephalomedullary nail) for the treatment of fractures of the proximal part of the femur combined with fractures of the femoral shaft. *J Trauma*. 1996; 40:10-6.
14. Wu LD, Wu QH, Yan SG, Pan ZJ. Treatment of ipsilateral hip and femoral shaft fractures with reconstructive intramedullary interlocking nail. *Chin J Traumatol*. 2004; 7:7-12.
15. Lin SH, Lo CW, Cheng SC, Kuo MY, Chin LS. Use of reconstruction nails to manage ipsilateral displaced femoral neck-shaft fractures: assessment of a new approach. *J Orthop Surg (Hong Kong)*. 2002; 10(2):185-93.
16. Oh CW, Oh JK, Park BC, Jeon IH, Kyung HS, Kim SY, et al. Retrograde nailing with subsequent screw fixation for ipsilateral femoral shaft and neck fractures. *Arch Orthop Trauma Surg*. 2006; 126(7):448-53.
17. Alfonso D1, Vasquez O, Egol K. Concomitant ipsilateral femoral neck and femoral shaft fracture nonunions: a report of three cases and a review of the literature. *Iowa Orthop J*. 2006; 26:112-8.