

**SHORT COMMUNICATION****Posterior Vertebral Injury; Is This a Burst Fracture or a Flexion-Distraction Injury?**

Farzad Omid-Kashani, MD

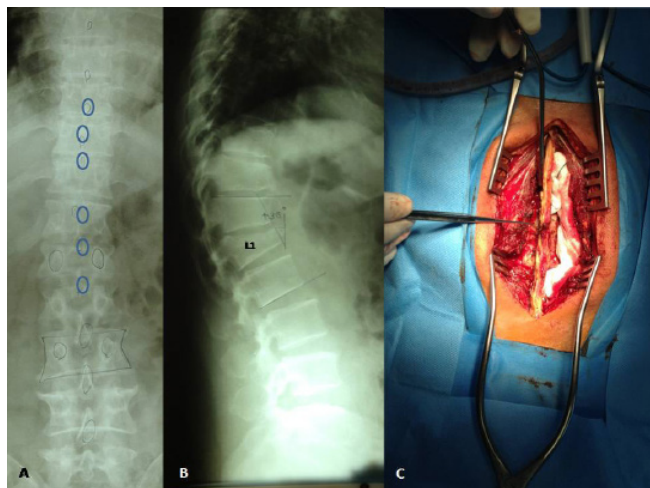
*Research performed at Orthopedic Research Center, Mashhad University of Medical Sciences, Mashhad, Iran**Received: 9 February 2014**Accepted: 20 June 2014***Abstract**

In thoracolumbar spinal fractures with posterior column injury for applying proper management, it is important to distinguish a flexion-distraction injury (FDI) from a three column burst fracture (BF) as in clinical examination, both may have a similar significant tenderness on direct spinal palpation. Careful attention to the comprehensive clinical examination and detailed imaging features are essential in making an accurate diagnosis and thus appropriate treatment.

**Key words:** Burst fracture, Flexion-distraction injury, Thoracolumbar spine, Trauma

**Introduction**

In trauma setting, physicians commonly encounter with the spinal injured patients suspicious of an unstable underlying injury. One of these questionable situations is posterior vertebral column injury in thoracolumbar spinal area. Is this an isolated stable



**Figure 1.** A 42 years old female with a history of motor vehicle accident. On anteroposterior view, inter-spinous distance was locally increased (A) and on lateral view, T12-L2 post-traumatic kyphosis was +30° (B). Intraoperative findings confirmed PLC injury (C).

posterior element injury? Is this a three column burst fracture (BF) or a flexion-distraction injury (FDI)? As some three column BFs may be amenable to brace treatment, and FDI's are usually strong indicators for surgical intervention, distinguishing these from each other is very important for appropriate treatment. In this short review, we summarize key characteristics observed with these two common traumatic conditions.

**Diagnosis and Management**

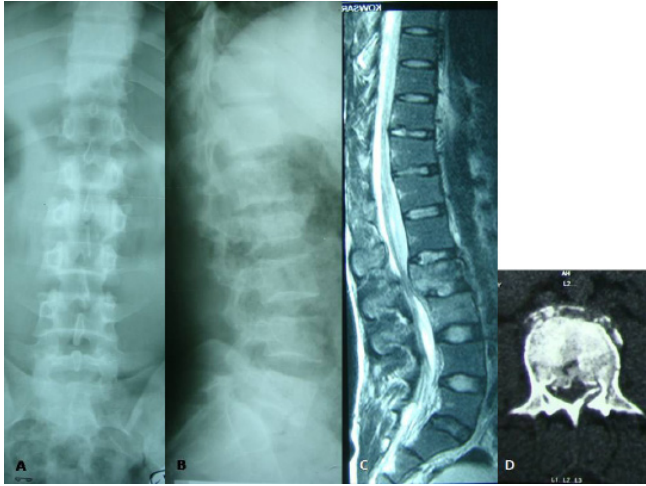
If the injury is limited to the posterior elements of the vertebra, proper management depends upon the patient's neurological status. This injury usually occurred as a result of a direct impaction or sudden muscular contracture. In the patients with normal neurology, mild conservative measures including a short time rest, analgesics, a soft thoracolumbar corset and then early mobilization are usually sufficient (1). In those rare cases with penetrating injuries and significant neurologic deficit, limited laminectomy to decompress neural element and probably repair of the torn dura matter is indicated (2).

In those patients with associated vertebral body injury, the physician should be able to properly differentiate FDI from three column BF. In clinical examination, both may have a significant tenderness on direct spinal palpation. The effect of safety belts on the shoulder or abdomen, presence of associated abdominal visceral injuries including spleen, liver rupture, intestinal perforation, or aortic dissection are in favor of a FDI,

**Corresponding Author:** Farzad Omid-Kashani, Orthopedic Research Center, Orthopedic Department, Imam Reza Hospital, Mashhad University of Medical Science, Mashhad, Iran.  
Email: [omidif@mums.ac.ir](mailto:omidif@mums.ac.ir)



THE ONLINE VERSION OF THIS ARTICLE  
[ABJS.MUMS.AC.IR](http://abjs.mums.ac.ir)



**Figure 2.** A 34 years old man presented with three column BF of L2 vertebra. A and B demonstrated plain radiographs, while C and D show his MRI and CT scanning views, respectively. Note increased inter-pedicular distance in L2 on anteroposterior view (A) and the absence of increased signal intensity in the PLC area on T2 weighted MRI (C). Canal compromise due to the retropulsed bony fragments and vertical fracture line without any significant post-traumatic kyphosis are in favor of BF.

while simultaneous occurrence of axially failed fractures like plateau or plafond of the tibia, and especially calcaneus are more commonly occurred with a BF (3, 4). In plain radiography, wide inter-pedicular distance on anteroposterior view is characteristic of a three column BF, while an inappropriately increased inter-spinous distance is highly indicative of FDIs (Figure 1) (5, 6). Significant post-traumatic kyphosis is also in favor of PLC disruption and FDIs, but this is not a definite rule.

Although, both middle and posterior columns fail in three column BF and FDI, they fail in compression in the former and in distraction in the latter. Therefore, retropulsion of a bony fragment from the middle column into the vertebral canal is another characteristic of BFs. Pattern of the bony fracture of the posterior elements of the injured vertebra has also some clues for proper diagnosis. Fracture lines extending vertically are usually indicative of axially applied loads in BFs but horizontal fracture lines in laminae are in favor of a FDI. However, these details are more clearly observed in computed tomography (CT) images (4, 7) (Figure 2).

In magnetic resonance imaging (MRI) scanning, tearing of posterior ligamentous complex (PLC) in the form of increased signal intensity is more clearly observed in T2 weighted images especially in short-tau inversion recovery (STIR) sequences (8). Some authors believe

**Table 1.** Differential characteristics of a thoracolumbar spinal injury with posterior column disruption

Index	Three column BF	FDI
	Physical Exams:	
-Posterior pain and tenderness	Mild to moderate	Mild to moderate
-Effect of safety strap	Absence	Present
-Abdominal visceral injury	Rare	Common
-Aortic dissection	Rare	Probable
	Plain Radiography:	
-Middle column height	Decreased	Normal or Increased
-Inter-pedicular distance	Normal or Increased	Normal
-Inter-spinous distance	Normal or decreased	Increased
-Laminar fracture line	Vertical	Horizontal
-Post-traumatic kyphosis	Not significant	Significant
	Computed Tomography:	
-Canal compromise (bony retropulsion)	Common	Rare
-Comminution in lamina	Common	Rare
-Laminar fracture line	Vertical	Horizontal
	Magnetic Resonance imaging:	
-PLC in T2 weighted images	Normal intensity	Increased signal intensity
-Canal compromise	Common	Rare

that MRI over-diagnoses PLC injury and its better not to absolutely rely on it for surgical decision (9). We summarize differential characteristics of thoracolumbar spinal fractures with posterior elements injury in Table 1.

### Conclusion

In conclusion, in thoracolumbar spinal trauma, the mere existence of posterior spinal tenderness is not equal with a FDI. Careful attention to the comprehensive

clinical examination and detailed radiologic features are essential in making a proper diagnosis and thus appropriate treatment.

Farzad Omidi-Kashani MD  
Orthopedic Research Center, Orthopedic Department  
Imam Reza Hospital, Mashhad University of Medical Science, Mashhad, Iran

### References

1. Homnick A, Lavery R, Nicastro O, Livingston DH, Hauser CJ. Isolated thoracolumbar transverse process fractures: call physical therapy, not spine. *J Trauma*. 2007; 63(6): 1292-5.
2. Inaba K, Barmparas G, Ibrahim D, Branco BC, Gruen P, Reddy S, et al. Clinical examination is highly sensitive for detecting clinically significant spinal injuries after gunshot wounds. *J Trauma*. 2011; 71(3): 523-7.
3. Wood KB, Li W, Lebl DS, Ploumis A. Management of thoracolumbar spine fractures. *Spine J*. 2014; 14(1): 145-64.
4. Singh K, Vaccaro AR, Eichenbaum MD, Fitzhenry LN. The surgical management of thoracolumbar injuries. *J Spinal Cord Med*. 2004; 27(2): 95-101.
5. Caffaro MF, Avanzi O. Can the interpedicular distance reliably assess the severity of thoracolumbar burst fractures? *Spine*. 2012; 37(4): E231-6.
6. Neumann P, Wang Y, Kärrholm J, Malchau H, Nordwall A. Determination of inter-spinous process distance in the lumbar spine. Evaluation of reference population to facilitate detection of severe trauma. *Eur Spine J*. 1999; 8(4): 272-8.
7. Müller CW, Hübner T, Gösling T, Krettek C. Traumatology of the spine. *Chirurg*. 2008; 79(10): 918, 920-6.
8. Radcliff K, Su BW, Kepler CK, Rubin T, Shimer AL, Rihn JA, et al. Correlation of posterior ligamentous complex injury and neurological injury to loss of vertebral body height, kyphosis, and canal compromise. *Spine (Phila Pa 1976)*. 2012; 37(13): 1142-50.
9. Rihn JA, Fisher C, Harrop J, Morrison W, Yang N, Vaccaro AR. Assessment of the posterior ligamentous complex following acute cervical spine trauma. *J Bone Joint Surg Am*. 2010; 92(3): 583-9.