

CASE REPORT

Dysplasia Epiphysealis Hemimelica (Trevor Syndrome) of Talus in a 21-Year Old Woman; Case Report

Amir R Sadeghifar, MD; Afshin Ahmadzadeh Heshmati, MD

Research performed at Bahonar Hospital, Kerman University of Medical Sciences, Kerman, Iran

Received: 31 December 2013

Accepted: 24 February 2014

Abstract

Dysplasia epiphysealis hemimelica is a rare nonhereditary epiphyseal disease that mimics synovial chondromatosis and osteochondroma of the joints. The disease mainly involves long bones of the lower extremities and tarsal bones. Herein we report 21-year old woman who presented with pain and limited range of ankle motion, who underwent surgical excision of talus exostosis after preoperative imaging and careful planning. After that she was discharged and her problem improved and she have no problem in three year follow up. Pathologic examination of specimen confirm the diagnosis.

Key words: Dysplasia epiphysealis hemimelica, Talus

Introduction

Dysplasia epiphysealis hemimelica is a rare developmental disorder of epiphyseal osteocartilaginous growth in children, usually in the lower limbs. Belot in 1926 first described this disorder (1). The etiology of dysplasia epiphysealis hemimelica is unknown (2,3). The pathological findings are similar to those described for solitary osteochondromas. The most common sites of involvement are the distal femur, proximal tibia, talus, and navicular. The presenting complaint usually is deformity and limited range of motion in the affected joint (4). Dysplasia epiphysealis hemimelica usually stops growing once maturity is reached, but incongruity if joints lead to osteoarthritis, malignant transformation has not been reported (5).

Case Report

The case was a 21-year old woman with complaint of ankle pain in stair climbing and long stand walking and running, which was started few months ago and was aggravated by time. In physical examination she had varus hind foot deformity, limited active and passive dorsiflexion but normal plantar flexion and supination and pronation. In x-ray, she had an exostosis in anterolateral portion of talar neck (Figure 1). CT scan

and MRI documented the diagnosis and help us for surgical plane (Figure 2,3). We approached patient with anterolateral incision and excise the lesion (Figure 4) and pathologist reported osteochondroma. We followed the patient for 3 years and fortunately she has no problem.

Discussion

Hemimelical involvement and connection with the epiphysis are important features of Dysplasia epiphysealis hemimelica (DEH). The lesion consists of osteocartilaginous tissue arising from the epiphysis and usually is hemimelic (either the lateral or the medial part of the ossification centers is involved). Although the incidence has been reported as one per million, it is likely higher than that. Mouchet and Belot in 1926 first described this as a tarsal bone disorder and used the term Tarsomegalie (1). In 1950 Trevor used the term tarso-epiphyseal aclasis, In 1956 Fairbank used the now common term dysplasia epiphysealis hemimelica. The etiology of dysplasia epiphysealis hemimelica is unknown (2,3,4). It has been hypothesized that this condition represents a fundamental defect in the regulation of one side of the affected epiphysis, may be single or multiple. The most common sites of involvement are the distal femur, proximal tibia, talus,

Corresponding Author: Amir R Sadeghifar, Dr Bahonar University Hospital, Kerman Medical University, Kerman, Iran.
Email: sadeghifar@kmu.ac.ir



THE ONLINE VERSION OF THIS ARTICLE
ABJS.MUMS.AC.IR

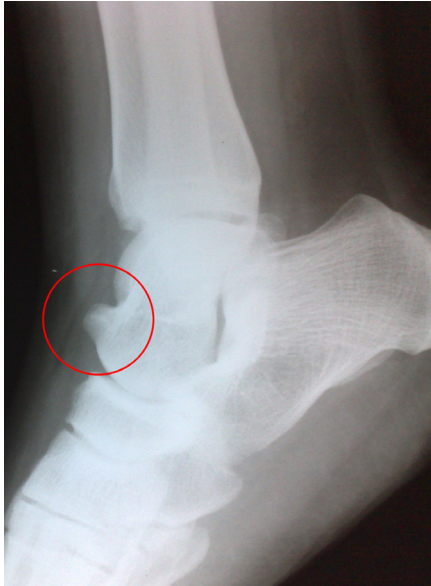

Figure 1. Dysplasia Epiphysealis Hemimelica on the anterolateral corner of talar neck presenting with pain and motion limitation in a 21-year-old woman.

and navicular (5). The usual symptom is the presence of deformity and limited range of motion in the affected joint. Other symptoms include a limp, muscle wasting, and, limb length discrepancy. Angular malalignment of the knee (valgum or varum), ankle, and hindfoot (valgus) may be evident. The affected portion of the epiphysis is enlarged and a mass may be palpable. Articular surface irregularity may lead to early secondary osteoarthritis. In x-rays of mature bones a multicentric radiodensity develops adjacent to the epiphysis or tarsal bone. Magnetic resonance imaging and computed tomography are more useful than radiography in identifying such epiphyseal involvement (6-9). DEH is usually mistaken for synovial chondromatosis, which is a geriatric disorder (8). Dysplasia epiphysealis hemimelica usually stops growing once maturity is reached, but incongruity if joints lead to osteoarthritis, malignant transformation has not been reported (10). Conservative treatment is recommended when there is no pain or deformity, surgical excision should be undertaken if the lesion is painful, deformity is occurring or joint function is limited. Surgery should be aggressive and early to avoid joint deformity and stiffening (11). Nonetheless, treatment should be customized, as patient expectations (cosmetic and wish to play sports) are important. Recurrence is common, and repeated local excision is often required. Any angular deformities can be treated with corrective osteotomy. Histopathologically, it was not possible to distinguish DEH from osteochondroma (12). With special molecular tests (EXT1, EXT2), genetic expressions can be analysed. Gene expressions are in normal ranges in DEH, whereas they are lower in osteochondroma (owing to a mutation) (12,13,14). These tests are costly, hence clinical and radiological findings are important diagnostic tools.

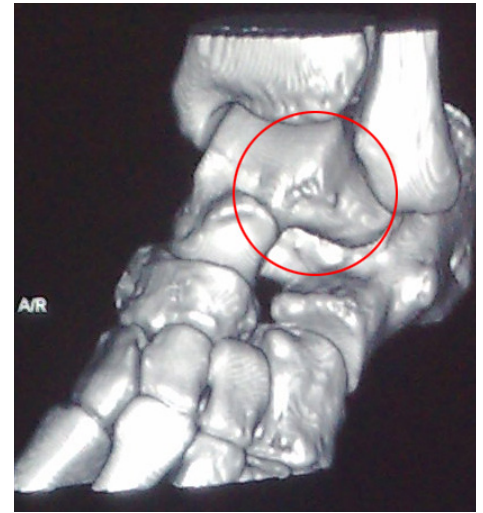
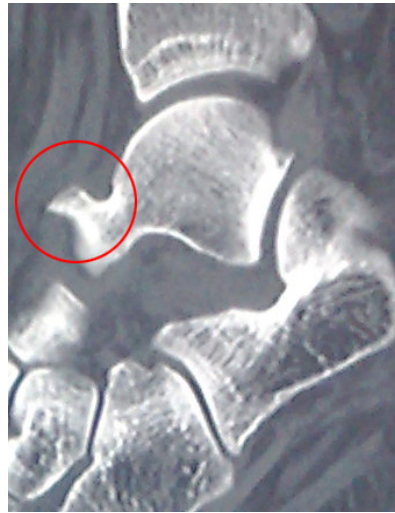

Figure 2 (left) and 3 (right). CT scan view of the talonavicular joint revealing the osseous lesion on top of the distal talar neck.

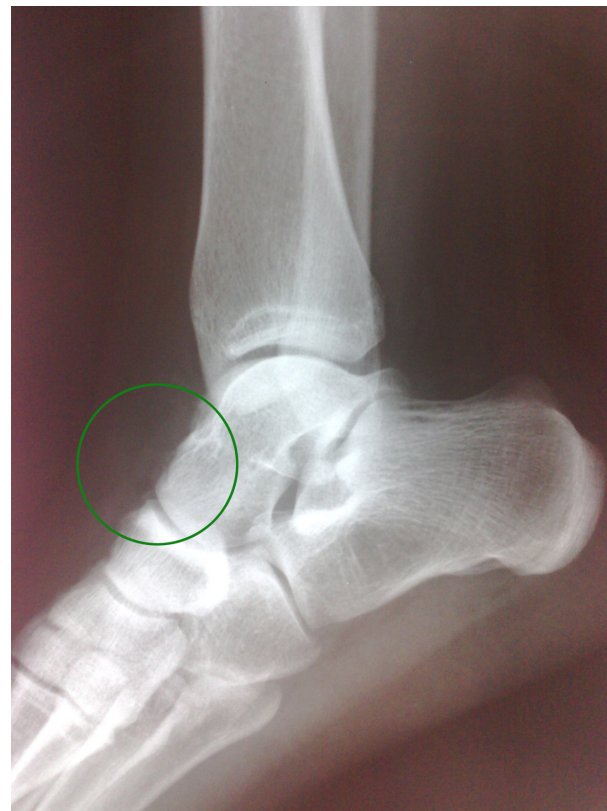

Figure 4. Post-operative radiography of the patients after excision of the lesion to the level of talonavicular joint

Amir R Sdeghifar MD
Afshin Ahmadzadeh Heshmati MD

Department of Orthopedic Surgery
Dr Bahonar University Hospital
Kerman Medical University, Kerman, Iran

References

1. Mouchet A, Belot J. La Tarsomegalie. *J Radiol Electrol.* 1926;10:289-93.
2. Keret D, Spatz DK, Caro PA, Mason DE. Dysplasia epiphysealis hemimelica: diagnosis and treatment. *J Pediatr Orthop.* 1992;12:365-72.
3. Kuo RS, Bellemore MC, Monsell FP, Frawley K, Kozlowski K. Dysplasia epiphysealis hemimelica: clinical features and management. *J Pediatr Orthop.* 1998;18:543-8.
4. Tachdjian M. *Pediatric Orthopedics.* 4th ed. Philadelphia: WB Saunders Co; 2008. pp:1096-100.
5. Bullough P. *Orthopaedic Pathology.* London: Mosby-Wolfe; 1997. pp: 1312-56.
6. Keret D, Spatz DK, Caro PA, Mason DE. Dysplasia epiphysealis hemimelica: diagnosis and treatment. *J Pediatr Orthop.* 1992; 12:365-72.
7. Kuo RS, Bellemore MC, Monsell FP, Frawley K, Kozlowski K. Dysplasia epiphysealis hemimelica: clinical features and management. *J Pediatr Orthop.* 1998;18:543-8.
8. Wiart E, Budzik JF, Fron D, Heraux B. Bilateral Dysplasia epiphysealis hemimelica of talus associated with lower leg intramuscular cartilaginous mass. *pediatr Radiol.* 2012;42(4):503-7.
9. Douira-Khomsy WI, Louati H, Mormech y, Saied W, Bouchoucha S, Seida A, et al. Dysplasia epiphysealis hemimelica: a report of four cases. *J Foot Ankle surg.* 2011;1(1):37-43
10. Bhosale SK, Dholakia DB, Sheth BA, Srivastava SK. Dysplasia epiphysealis hemimelica of the talus: two case reports. *J Orthop Surg.* 2005; 13:79-82.
11. Campanacci M. *Bone and soft tissue tumors.* 2nd ed. New York: Springer; 1998. pp: 207-11.
12. Fletcher C, Unni K, Mertens F (eds). *Pathology and genetics of tumours of soft tissue and bone.* Geneva: World Health Organization; 2006.
13. Ouvang Z, Xu M, Peng D. Dysplasia epiphysealis hemimelica with involvement of distal tibia physis and talus: recurrence of a case and literature review. *J Foot Ankle surg.* 2014;53(2):199-201.
14. Glick R, Khaldi L, Ptaszynski K, Steiner GC. Dysplasia epiphysealis hemimelica (Trevor disease): a rare developmental disorder of bone mimicking osteochondroma of long bones. *Hum Pathol.* 2007;38:1265-72.