

## RESEARCH ARTICLE

## Midterm Results of Arthroscopic Treatment for Recalcitrant Lateral Epicondylitis of the Elbow

Hossein Saremi, MD<sup>1</sup>; Mohammad A. Seydan, MD<sup>2</sup>; Mohammad A. Seifrabiei, PhD<sup>3</sup>*Research performed at Hamadan University of Medical Sciences, Hamadan, Iran**Received: 26 July 2019**Accepted: 23 December 2019***Abstract**

**Background:** An effective treatment for the elbow recalcitrant lateral epicondylitis is arthroscopic surgery. This study evaluated the midterm results of treating recalcitrant lateral epicondylitis with arthroscopic surgery.

**Methods:** A total of 40 subjects with recalcitrant lateral epicondylitis prepared for arthroscopic surgery on their elbows participated in this study. The elbow function was evaluated using the Quick disabilities of the arm, shoulder, and hand (Quick DASH) score. Pain intensity was assessed before and after the surgery by the visual analog scale (VAS). Grip and pinch strengths were assessed by a dynamometer.

**Results:** In this study, the mean age of the participants was 42.9±6.4 years. The average follow-up time was 42 months. The mean of VAS (pain intensities) were 7.05 and 3.20 before and after the surgery, respectively ( $P=0.001$ ). The Quick DASH score decreased from 63.18 to 25.68 from before to after the surgery ( $P=0.001$ ). The mean grip strength of the operated and nonoperated sides was not significantly different after the surgery.

**Conclusion:** Arthroscopic surgery seems to be an effective method with few complications in patients suffering from an elbow recalcitrant lateral epicondylitis in the midterm follow-up.

**Level of evidence:** II

**Keywords:** Arthroscopy, Function, Lateral epicondylitis, Pain, Tennis elbow, Strength

**Introduction**

Lateral epicondylitis is common in athletes and people who perform one-way and repeated movements in their jobs (1, 2). Approximately, 1-3% of the individuals referring to orthopedic clinics suffer from lateral epicondylitis. Epidemiological studies showed that 7 in every 1,000 people who referred to medical centers have had this problem (3, 4). Lateral epicondylitis is not limited to tennis players and is also observed in handicraftsmen (5). It can cause several days of absence from work, as well as long-term restrictions in performing routine tasks or sports (6, 7). A high incidence of lateral epicondylitis in women within the age range of 40-60 years is probably due to the low elasticity of the

tendons for the recurrent biomechanical stress in these ages (8).

Relapse is observed after the treatment unless the underlying factors are controlled (9). The disease is the most common cause of elbow pain. The encountered athletic disorder is treated without surgery (10). The prognosis of tennis elbow treatment is good, and spontaneous recovery occurs within 8 to 13 months. However, even with the ideal methods, it takes 3 to 6 months to complete treatment. Treatment is important since it reduces pain and returns people to their daily activities. Although more than 40 different treatments are available for this problem, there is still no consensus

**Corresponding Author:** Hossein Saremi, Orthopedic Surgery Department, Faculty of Medicine, Hamadan University of Medical Sciences, Hamadan, Iran  
Email: hosseinsaremi.shoulder@gmail.com



THE ONLINE VERSION OF THIS ARTICLE  
ABJS.MUMS.AC.IR

on the best possible treatment (11).

Most cases of lateral epicondylitis respond to nonsurgical treatments, including the use of analgesics, orthoses or straps, physiotherapy, corticosteroid injections, shock wave therapy, platelet-rich plasma, and low-dose thermal erosion devices (12, 13). Although most patients with lateral epicondylitis respond to conservative treatment, there is little evidence of its positive effects (12-14). On the other hand, 5-10% of these patients with chronic symptoms eventually require surgical intervention (15, 16). In some studies, the frequency of patients in need of surgical intervention in referral centers has been up to 25% (17).

Surgical procedures can be used when conservative treatments fail. Recent developments in the arthroscopic treatment of these lesions have allowed arthroscopic methods to provide better results (15). Open surgery has been reported with significant results in many studies; however, to the best of our knowledge, no study has shown satisfactory findings for open surgery of lateral epicondylitis up to now. Therefore, orthopedic surgeons are reluctant to perform open surgery for the treatment of recalcitrant lateral epicondylitis. In addition, there is no published study on the results of open surgery for tennis elbow in Iran. Consequently, the current study evaluated the midterm results of treating recalcitrant lateral epicondylitis with arthroscopic surgery.

### Materials and Methods

This cohort study was carried out within May 2012 to February 2017 in Hamedan, Iran. The study population consisted of all patients who had not responded to nonsurgical treatments after at least 6 months, and they were supposed to undergo arthroscopic surgery. A total of 42 subjects were enrolled in the present study. Two cases were excluded during the follow-up. All participants signed informed consent before entering the study.

The inclusion criteria were being older than 18 years and not responding to nonsurgical treatments for 6 months (including lifestyle modification, use of tennis elbow strap, administration of nonsteroidal anti-inflammatory drugs, and at least one corticosteroid injection). The exclusion criteria were a history of trauma or compression neuropathy (including cervical radiculopathy), previous surgery on the affected elbow, and no attendance at follow-up after the surgery. All demographic data of the patients were recorded before the surgery. The visual analog scale (VAS), quick disabilities of the arm, shoulder, and hand (Quick DASH) score, and grip and pinch strengths were recorded before and after the operation.

### Surgery technique

The researchers entered the scope via the anteromedial portal under general anesthesia in the lateral decubitus position. Then, the anterolateral portal was established as outside in technique. The lateral capsule and pathological discolored tissues of the extensor carpi radialis brevis (ECRB) origin were shaved. The annular ligament was not removed; however, it was trimmed if it seemed to impinge during elbow motion. The posterior interosseous nerve and ulnar lateral collateral ligament were preserved during the surgery [Figure 1].

Postsurgery care consisted of 24-hour immobilization in a sling followed by the elbow active-assisted range of motion. The participants started physiotherapy in the second week after the surgery if needed. The subjects were asked to stop using analgesic drugs and start to work as soon as they were comfortable.

The participants were visited at least five times, including 3 weeks, 3 months, 6 months, 1 year, and 2 years after the surgery. The patients' pain and satisfaction were evaluated using a standard questionnaire. The pain intensity was assessed by the VAS in this study. According to the evidence, it was shown that this method has high validity and reliability (0.94) in the evaluation of pain

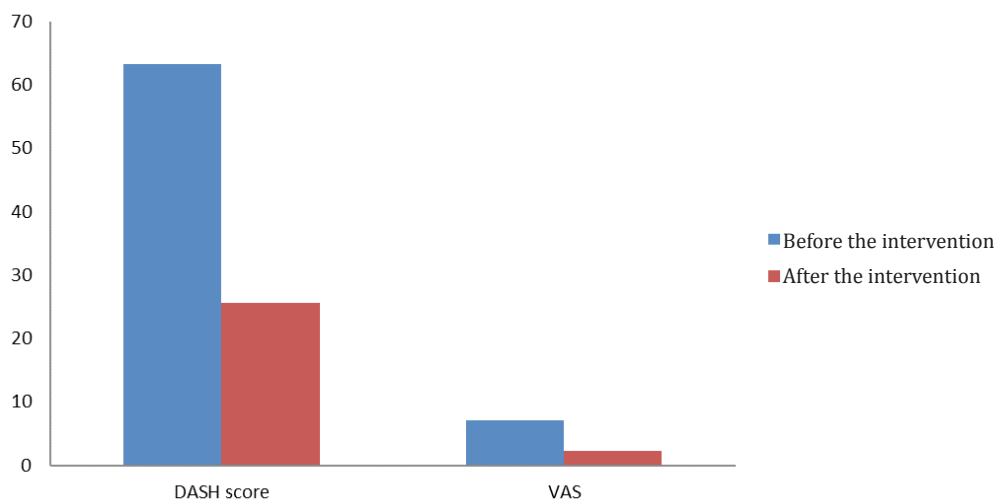


Figure 1. Visual analog scale and DASH score before and after the surgery.

(18). The function of the elbow was evaluated using the Quick DASH score, which has been used in multiple studies (19-21). The final score of Quick DASH is from 0 to 100. A higher score indicates the higher disability of the individual (19).

The measurements of hand grip and key pinch strength were performed on two sides, namely operated and nonoperated elbows. They were examined before and after the surgery using a manual dynamometer (Jamar, USA). The Jamar hydraulic hand dynamometer was used for the evaluation of hand grip strength. For this assessment, the person sat in a chair without armrest according to the recommendations of the American Society of Hand Therapists so that the elbows were bent 90°. The forearm was in a normal and neutral position, and the hand at 0 to 30° of dorsiflexion and 0 to 15° of ulnar deviation.

Then, the examiner put the dynamometer in the participant hands. The person levered the device by the whole hand with maximum force, and his score was recorded. To assess the key pinch strength, a special dynamometer was used, in which the person was in the previous position; however, this time she/he used the thumb and index finger instead (22, 23).

#### Statistical analysis

Descriptive statistics, Wilcoxon test, independent t-test, and paired t-test were used for data analysis. In this study,

the significance level was 95% ( $\alpha=0.05$ ). All the analyses were performed using SPSS software (version 16).

#### Results

The mean age of all participants was 42.9±6.4 years (age range: 29-52 years). There were 12 men and 28 women with the mean age of 42.33±6.40 and 43.21±6.32 years, respectively. In this study, 70% of the participants were women. A total of 32 (80%) subjects were right-handed, and 8 (20%) patients were left-handed. Moreover, 22 (55%) participants were operated on their dominant hand, and 18 (45%) subjects were operated on their nondominant hands. The average time for returning to work was 18 days (range: 14-42 days). The average follow-up time was 42 months. On average, the patients suffered from pain for 10 months before the surgery (range: 6 to 18 months).

The nonparametric Wilcoxon test was used to compare the pain (the VAS) and functional scores (Quick DASH score) before and after the operation because the data distribution was not normal based on the Kolmogorov-Smirnov test ( $P \geq 0.05$ ). The results of the Wilcoxon test showed that the average of postsurgery limb performance measured by the Quick DASH score reduced from 63.18 to 25.68, indicating a significant improvement in the elbow function [ $P=0.001$ ; Table 1]. The mean of the VAS was 7.05 before the surgery and decreased to 2.3 after the operation, which was significant [ $P=0.001$ ; Figures 2; 3].

Table 1. Comparison of pain and function in patients before and after intervention

Variable	Before the surgery (Mean ± SD)	After the surgery (Mean ± SD)	P (Wilcoxon)
Visual analog scale	7.05 ± 1.63	2.30 ± 2.86	0.001
Quick DASH score	63.18 ± 12.03	25.68 ± 19.42	0.001

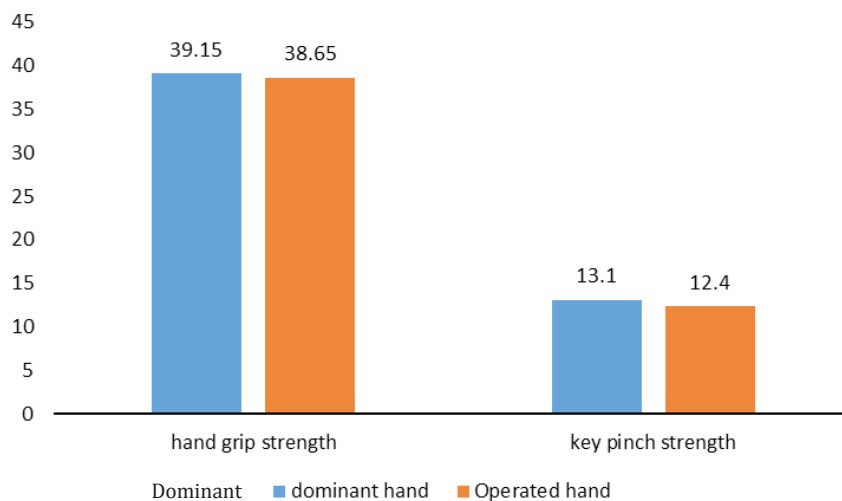


Figure 2. Comparison of the dominant and operated hands' grip and pinch strength.

**Table 2. Comparison of grip and pinch strength of dominant and operated hand (pound)**

Variable	Operated hand (Mean ± SD)	Non-operated hand (Mean ± SD)	P(t-test)
hand grip strength	38.65 ± 19.16	39.15 ± 18.99	0.850
key pinch strength	12.40 ± 3.29	13.10 ± 3.68	0.402

The Quick DASH scores were reported as 63.18±12.03 and 25.68±19.42 before and after the surgery, respectively. T-test was used to compare the means of pinch and grip strengths between the operated and nonoperated sides 3 months after the surgery. The obtained results showed that the means of grip and pinch strengths were not significantly different ( $P \geq 0.05$ ). The means of grip strength of the operated and nonoperated hands were 38.65±19.16 and 39.15±18.99 pounds, respectively. The means of pinch strength of operated and nonoperated hands were 12.4±3.29 and 13.10±3.68 pounds, respectively [Table 2].

### Discussion

Lateral epicondylitis is a common cause of elbow pain, and its recalcitrant cases are in need of surgery. Surgical procedures can be open, percutaneous or arthroscopic. More than 15 surgical techniques have been suggested for the treatment of lateral epicondylitis. Arthroscopic surgery is a new method for the treatment of this disease (12, 24, 25).

In the current study, the patients were relieved from pain after the surgery based on the results of the VAS. Previous studies have shown that patients undergoing elbow arthroscopic surgery have experienced a significant reduction in pain after the surgery (24, 26). Szabo et al. studied three surgical techniques (i.e., arthroscopy, open surgery, and percutaneous) to investigate their side effects, such as pain, complications, and recurrence (27). The results revealed that they were not significantly different. All three techniques significantly decreased the pain. They concluded that the reduction of pain with arthroscopic surgery can have positive effects on the quality of life (27).

The Quick DASH score significantly decreased in the present study, indicating an improvement in the postsurgery function of the elbow. The results of a study by conducted Wada et al. showed that arthroscopic surgery in tennis elbow syndrome is associated with a reduction in the postoperative Quick DASH score, which is in agreement with the results of the present study (28). A study carried out by Solheim et al. showed that arthroscopy can significantly reduce the Quick DASH score, indicative of the improvement in the performance of patients, which is also in line with the findings of the present study (25). Furthermore, Solheim et al. demonstrated that arthroscopic treatment can be more beneficial than open surgery (24). The improvement could be due to pain reduction after arthroscopy surgery, resulting in a better score in the Quick DASH score questionnaire (24).

Based on the results of the present study, the grip and pinch strengths of the operated and nonoperated sides were not significantly different 3 months after the surgery. Although some studies have shown controversial findings about the effectiveness of arthroscopic and open surgery outcomes for grip and pinch strengths in lateral epicondylitis, other studies have demonstrated that the open method has better results. There were significant differences between arthroscopic and open surgery results in some studies. However, arthroscopic treatment has been reported with fewer complications, leading to a faster return to work and daily activities (29).

Based on the findings of the present study, the mean time of returning to work and normal activities was 18 days. This is an advantage of arthroscopic elbow surgery. Previous studies have also shown that after arthroscopic surgery, the patients can return to work faster, compared to other methods. For example, in studies carried out by Baker et al. and Verhaar et al., it took about two and a half weeks for the patients to get back to work, which is similar to the results of the present study (10, 30).

The results of the current study showed the effectiveness of arthroscopic treatment in the reduction of pain and improvement of elbow function in recalcitrant lateral epicondylitis according to the validated Quick DASH score (31). Normal grip and pinch strength results of the operated side indicated that the release of ECRB muscle origin without doing any repair had no effect on hand strength. Although arthroscopic surgery is a sophisticated technique, compared to open surgery for the surgeons, its benefits and no associated complications can make it a suitable alternative to other surgical procedures for the treatment of lateral elbow epicondylitis. The limitation of the current study was not considering a control group.

Arthroscopic surgery seems to be an effective method with few complications in patients suffering from an elbow recalcitrant lateral epicondylitis in the midterm follow-up. In this study, 70% of the participants were women because only the patients who referred to Besat Hospital of Hamadan University of Medical Sciences, Hamadan, Iran, were chosen without any sampling. Therefore, it can be considered in future studies to investigate whether this problem is more common among women or men, at least in the west of Iran (the patients in this study referred to Besat Hospital from the provinces in the west of Iran). There might be differences in this regard in different regions that should be assessed in future studies. It is also recommended to

carry out a similar study with a control group.

**Conflicts of Interest:** The authors declare that there is no conflict of interest.

**Funding:** The present study was not financially supported by any institutions.

### Acknowledgements

The authors would like to thank Muhammed Hussein Mousavinasab for editing this text.

Hossein Saremi MD<sup>1</sup>

Mohammad A. Seydan MD<sup>2</sup>

Mohammad A. Seifrabiei PhD<sup>3</sup>

1 Orthopedic Surgery Department, Faculty of Medicine, Hamadan University of Medical Sciences, Hamadan, Iran  
2 Student Research Committee, Hamadan University of Medical Sciences, Hamadan, Iran

3 Social Medicine Department, Faculty of Medicine, Hamadan University of Medical Sciences, Hamadan, Iran

### References

1. Runge F. Zur genese und behandlung des schreibekrampfes. Berl Klin Wochenschr. 1873; 10(1):245-8.
2. Tisano BK, Estes AR. Overuse injuries of the pediatric and adolescent throwing athlete. Med Sci Sports Exerc. 2016; 48(10):1898-905.
3. Fox GM, Jebson PJ, Orwin JF. Overuse injuries of the elbow. Phys Sportsmed. 1995; 23(8):58-66.
4. Pluim BM, Staal Jb, Windler Ge, Jayanthi N. Tennis injuries: occurrence, aetiology, and prevention. Br J Sports Med. 2006; 40(5):415-23.
5. Vicenzino B, Wright A. Lateral epicondylalgia I: epidemiology, pathophysiology, aetiology and natural history. Phys Ther Rev. 1996; 1(1):23-34.
6. Silverstein B, Welp E, Nelson N, Kalat J. Claims incidence of work-related disorders of the upper extremities: Washington state, 1987 through 1995. Am J Public Health. 1998; 88(12):1827-33.
7. Feuerstein M, Miller VL, Burrell LM, Berger R. Occupational upper extremity disorders in the federal workforce: prevalence, health care expenditures, and patterns of work disability. J Occup Environ Med. 1998; 40(6):546-55.
8. Winston J, Wolf JM. Tennis elbow: definition, causes, epidemiology. Tennis elbow. New York: Springer; 2015. P. 1-6.
9. Jansen CW, Olson SL, Hasson SM. The effect of use of a wrist orthosis during functional activities on surface electromyography of the wrist extensors in normal subjects. J Hand Ther. 1997; 10(4):283-9.
10. Maffulli N, Wong J, Almekinders LC. Types and epidemiology of tendinopathy. Clin Sports Med. 2003; 22(4):675-92.
11. Bisset L, Paungmali A, Vicenzino B, Beller E. A systematic review and meta-analysis of clinical trials on physical interventions for lateral epicondylalgia. Br J Sports Med. 2005; 39(7):411-22.
12. Smidt N, Assendelft W, Arola H, Malmivaara A, Green S, Buchbinder R, et al. Effectiveness of physiotherapy for lateral epicondylitis: a systematic review. Ann Med. 2003; 35(1):51-62.
13. Saremi H, Chamani V, Vahab-Kashani R. A newly designed tennis elbow orthosis with a traditional tennis elbow strap in patients with lateral epicondylitis. Trauma Mon. 2016; 21(3):e35993.
14. Labelle H, Guibert R, Joncas J, Newman N, Fallaha M, Rivard C. Lack of scientific evidence for the treatment of lateral epicondylitis of the elbow. An attempted meta-analysis. J Bone Joint Surg Br. 1992; 74(5):646-51.
15. Yan H, Cui GQ, Liu YL, Xiao J, Yang YP, Ao YF. A randomized comparison of open and arthroscopic Nirschl debridement for refractory lateral epicondylitis. Zhonghua Wai Ke Za Zhi. 2009; 47(12):888-91.
16. Matache BA, Berdusco R, Momoli F, Lapner PL, Pollock JW. A randomized, double-blind sham-controlled trial on the efficacy of arthroscopic tennis elbow release for the management of chronic lateral epicondylitis. BMC Musculoskelet Disord. 2016; 17(1):239.
17. Kraushaar BS, Nirschl RP. Current concepts review-tendinosis of the elbow (Tennis Elbow). Clinical features and findings of histological, immunohistochemical, and electron microscopy studies. J Bone Joint Surg. 1999; 81(2):259-78.
18. Hawker GA, Mian S, Kendzerska T, French M. Measures of adult pain: visual analog scale for pain (VAS pain), numeric rating scale for pain (NRS pain), mcgill pain questionnaire (MPQ), short-form mcgill pain questionnaire (SF-MPQ), chronic pain grade scale (CPGS), short form-36 bodily pain scale (SF-36 BPS), and measure of intermittent and constant osteoarthritis pain (ICOAP). Arthritis Care Res. 2011; 63(Suppl 11):S240-52.
19. Beaton DE, Wright JG, Katz JN; Upper Extremity Collaborative Group. Development of the QuickDASH: comparison of three item-reduction approaches. J Bone Joint Surg Am. 2005; 87(5):1038-46.
20. Longo UG, Franceschi F, Loppini M, Maffulli N, Denaro V. Rating systems for evaluation of the elbow. Br Med Bull. 2008; 87(1):131-61.
21. Iordens GI, Den Hartog D, Tuinebreijer WE, Eygendaal D, Schep NW, Verhofstad MH, et al. Minimal important change and other measurement properties of the Oxford Elbow Score and the Quick Disabilities of the Arm, Shoulder, and Hand in patients with a simple elbow dislocation; validation study alongside the multicenter FuncSiE trial. PloS One. 2017; 12(9):e0182557.
22. Szekeres M, MacDermid JC, King GJ, Grewal R. The relationship between the Patient-rated Ulnar Nerve

- Evaluation and the common impairment measures of grip strength, pinch strength, and sensation. *J Hand Ther.* 2015; 28(1):39-44.
23. Lam NW, Goh HT, Kamaruzzaman SB, Chin AV, Poi PJ, Tan MP. Normative data for hand grip strength and key pinch strength, stratified by age and gender for a multiethnic Asian population. *Singapore Med J.* 2016; 57(10):578-84.
24. Solheim E, Hegna J, Øyen J. Arthroscopic versus open tennis elbow release: 3-to 6-year results of a case-control series of 305 elbows. *Arthroscopy.* 2013; 29(5):854-9.
25. Solheim E, Hegna J, Øyen J, Inderhaug E. Arthroscopic treatment of lateral epicondylitis: tenotomy versus debridement. *Arthroscopy.* 2016; 32(4):578-85.
26. Phorkhar T, Chanlalit C. Functional results in arthroscopic treatment in patients with chronic lateral elbow pain. *J Med Assoc Thai.* 2015; 98(Suppl 10):S130-4.
27. Szabo SJ, Savoie FH 3rd, Field LD, Ramsey JR, Hosemann CD. Tendinosis of the extensor carpi radialis brevis: an evaluation of three methods of operative treatment. *J Shoulder Elbow Surg.* 2006; 15(6):721-7.
28. Wada T, Moriya T, Iba K, Ozasa Y, Sonoda T, Aoki M, et al. Functional outcomes after arthroscopic treatment of lateral epicondylitis. *J Orthop Sci.* 2009; 14(2):167-74.
29. Savoie FH 3rd, O'Brien MJ. Arthroscopic tennis elbow release. *Instr Course Lect.* 2015; 64(1):225-30.
30. Verhaar J, Walenkamp G, Kester A, van Mameren H, van der Linden T. Lateral extensor release for tennis elbow. A prospective long-term follow-up study. *J Bone Joint Surg Am.* 1993; 75(7):1034-43.
31. Ebrahimzadeh MH, Moradi A, Vahedi E, Kachooei AR, Birjandinejad A. Validity and reliability of the Persian version of shortened disabilities of the arm, shoulder and hand questionnaire (Quick-DASH). *Int J Prev Med.* 2015; 6(1):59.