

CASE REPORT

Fetal Rhabdomyoma of the upper Extremity in a 31-Year Old Patient: a Case Report

Georg Hauer, MD; Jörg Friesenbichler, MD, PhD; Franz Gollowitsch, MD; Andreas Leithner, MD; Lukas A. Holzer, MD, PhD

Research performed at the Medical University of Graz, Graz, Austria

Received: 12 April 2018

Accepted: 02 June 2018

Abstract

Fetal rhabdomyomas (RM) are extremely rare benign mesenchymal tumours that occur primarily in the head and neck. This tumour exhibits immature skeletal muscle differentiation. The patients' median age is four years and surgical resection is the recommended treatment.

Fetal RM of limbs are rare and not well described in the literature and if, predominantly in form of case reports. We report the second case of a fetal RM in the upper extremity in a 31-year old male patient.

One should be aware of this skeletal muscle tumour and fetal RM should be considered as a differential diagnosis to its malignant counterpart rhabdomyosarcoma.

Level of evidence: V

Keywords: Fetal, Rhabdomyoma, Rhabdomyosarcoma, Tumour

Introduction

Rhabdomyomas (RM) are rare benign skeletal muscle tumours which show different degrees of maturation and are classified into cardiac and extracardiac type depending on location. The extracardiac RM is subdivided into adult and fetal subtype. The fetal RM is again subdivided into "classic" and "intermediate" subtype (1). The fetal subtype has a great predilection for the head and neck region and the patient's median age is four years (1). Herein we present the clinical, radiological and pathological features and findings of a 31-year old male patient diagnosed with fetal RM located in the left distal upper arm near the elbow joint. There are only a few cases that can be found on databases describing fetal RM outside the head and neck region. This is the second case report of a fetal RM in the upper extremity which has been reported yet (2).

Case presentation

In July 2013 a 31-year old male Caucasian was referred

to our department due to a painless soft tissue tumour on his left upper arm, which he had for two months. The findings of an X-ray and a sonography taken in a first peripheral hospital were available. The X-ray was without any findings, but in the sonography, a 2.0 x 1.3 x 2.5 cm hypoechoic lesion was described. This lesion seemed to have little perfusion and to come from muscle tissue. The clinical examination revealed a palpable expansion near the proximal left elbow joint with normal skin coverage. There were neither signs of pain nor of any infection such as heat, redness or secretion. The tumour was moveable. MRI scan was performed and presented a circumscribed lesion located on the left distal upper arm, medial-sided, intramuscular in the brachialis muscle. The size of the lesion was 3.0 cm (proximodistal) x 1.5 cm (transversal) x 1.4 cm (sagittal). The expansion was hyperintense in T1- and T2-weighted imaging with a strong contrast medium enhancement (after Gadolinium injection) [Figure 1a; 1b]. Radiologist's suspected diagnosis included a connective

Corresponding Author: Lukas A. Holzer, AUVA Trauma Center Klagenfurt, Waidmannsdorferstraße 35, Klagenfurt am Wörthersee, Austria; Department of Orthopaedics and Traumatology, Medical University of Graz, Auenbruggerplatz 5, Graz, Austria

Email: lukas.holzer@medunigraz.at



THE ONLINE VERSION OF THIS ARTICLE
ABJS.MUMS.AC.IR

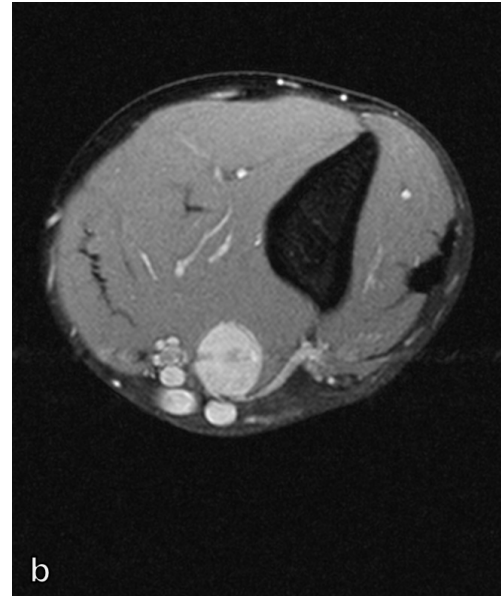
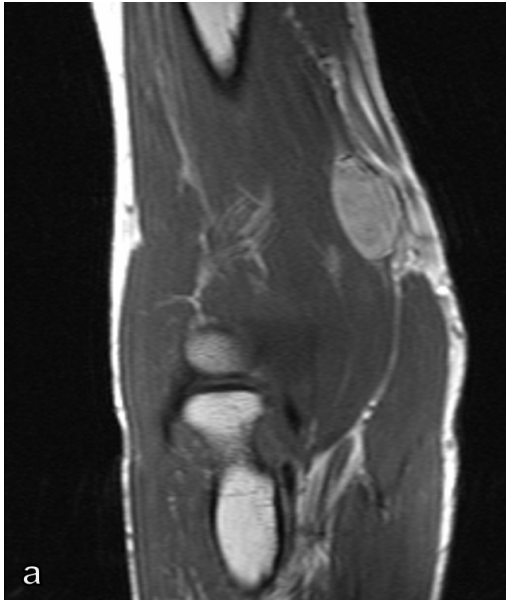


Figure 1A-B. The MRI scan of the left distal upper arm presents a 3.0 cm (proximodistal) x 1.5 cm (transversal) x 1.4 cm (sagittal) big tumour intramuscular in brachialis muscle with a strong contrast medium enhancement and close proximity to surrounding vessels in sagittal (A) and axial (B) sequence.

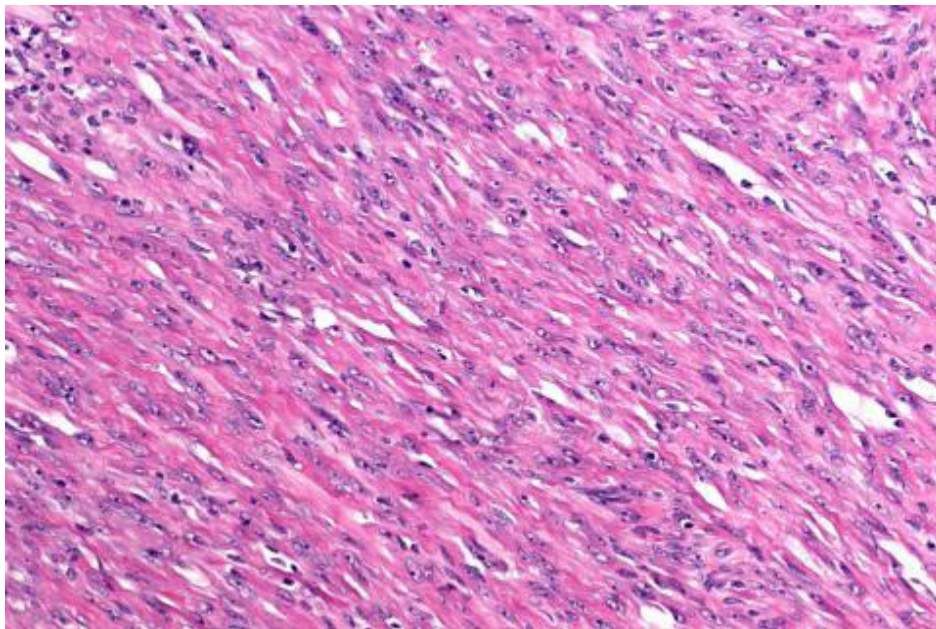


Figure 2. Fetal rhabdomyoma, intermediate type, with immature skeletal muscle cells in HE stain 20x10. The tumour consists of intersecting bundles of differentiated eosinophilic myofibrils.

tissue tumour (Schwannoma), but nothing could be said about dignity.

Marginal resection was performed without any complications. The histological evaluation revealed a spindle cell proliferation arranged in twisted fascicles and

totally surrounded by an intact fibrous pseudocapsule. The tumor cells were spindle-shaped, partially rounded with deep eosinophilic cytoplasm demonstrating a skeletal muscle differentiation [Figure 2]. Marked cytologic atypia and increased mitotic activity were not

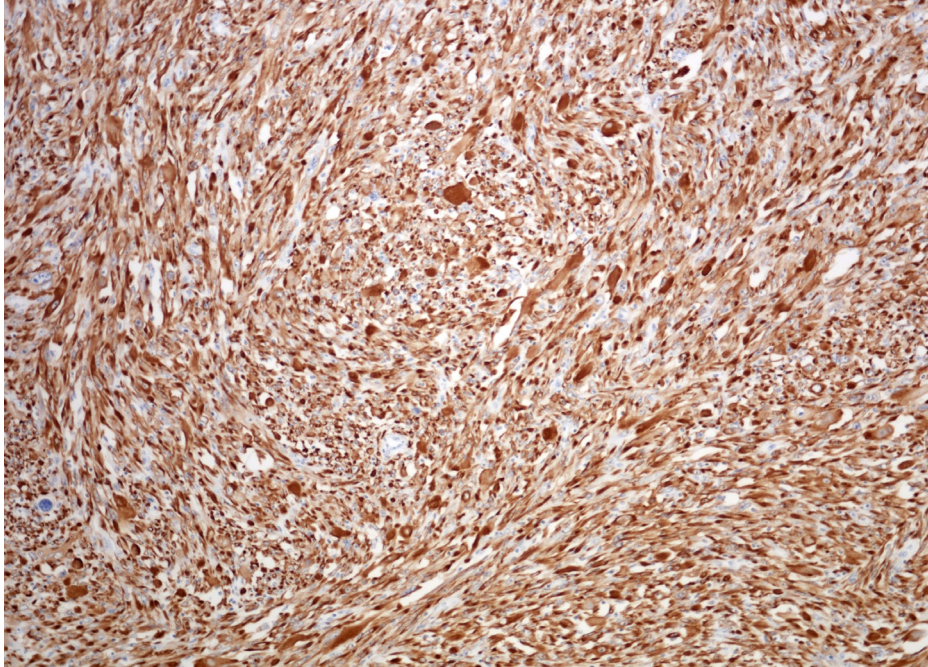


Figure 3. Fetal rhabdomyoma, intermediate type, consisting of tumour cells with specific reaction on desmin in immunohistochemistry.

seen. All cells showed a strongly positive reaction with desmin [Figure 3]. Immunohistochemistry was negative with all keratins, S100, CD31 and CD34. A small subset of cells demonstrated nuclear positivity with Myo FD5. Ki-67 staining was seen in less than one percent of tumor cells. Diagnosis of a fetal rhabdomyoma, intermediate (juvenile) subtype was made. There was no evidence for malignancy. Resection margins were free of tumour. No further adjuvant treatment (neither chemotherapy nor radiotherapy) was indicated. A one-year follow-up examination was without any clinical-radiological evidence for recurrence of the tumour.

Discussion

Our case presents two abnormalities which make this case of a fetal RM a rare one. On the one hand the tumour appeared in an atypical location and on the other hand the patient's age is quite uncommon.

More than 90% of fetal RM normally occur in the head and neck region with a predilection for the postauricular soft tissue concerning "classic" fetal RM and the soft tissue of face or mucosal regions for the "intermediate" RM (1, 3, 4). They present as nondescript masses or polypoidal lesions (5).

As a constellation like in our case, it is very hard to obtain correct diagnosis before getting immunohistological results. The age of the patient, the location of the tumour and MRI images were misleading and only immunohistological findings led to the correct diagnosis of the tumour. MRI images suggested a Schwannoma due

to close proximity to surrounding vessels.

Macroscopically, the tumour presented as a white to brown tissue. Hematoxylin and eosin (HE) stains findings with interlacing broad fascicles of spindled muscle cells and partially big rounded cells perfectly fitted with literature's description of "intermediate" fetal RM (1).

Due to similarities of fetal intermediate RM to rhabdomyosarcoma, it is essential to obtain correct diagnosis in order to avoid severe mistakes in therapy and outcome. Especially, well-differentiated spindle cell rhabdomyosarcoma has a close resemblance to fetal intermediate RM (5). In contrast to rhabdomyosarcoma, fetal RM tends to be fairly well circumscribed and more superficially located (6). Histopathologically, the most important criterion is the absence of clear nuclear atypia separating fetal RM from rhabdomyosarcoma (1). Another distinguishing factor is the patients' age. Rhabdomyosarcomas typically affect children, whereas our patient had an age of 31 years. Characteristics like infiltrative growth, mitotic activity or areas of necrosis are typical signs for malignancy, but cannot totally be excluded for fetal RM (1). Malignant transformation of fetal RM is rare, but has also been reported (2, 7). Pathologists disproved increased mitotic activity and therefore no procedure followed the marginal resection. Fetal RM does not metastasize and usually does not recur if totally excised, therefore unnecessary therapy has to be avoided (1). Infantile fibromatosis is another differential diagnosis to fetal RM due to its resemblance. However, fetal RM is better circumscribed and more likely to be

situated in the subcutis than in muscle tissue (6).

Just a small number of cases can be found describing fetal RM outside the head and neck region, occurring at sites like the abdominal wall, the stomach, the chest wall, the retroperitoneum and the limbs (2, 4, 5, 8-10).

Concerning the occurrence of fetal RM in the upper limb, only one case has been published yet (2). Osgood et al. describe the case of a 55-year old woman with a fetal RM in triceps brachii muscle (2). Concerning the occurrence in lower limbs, two cases were found, both located in the thigh: An isolated case of a fetal RM of the lower extremity is reported by Premalata et. al, whereas Dahl et. al found a fetal RM in the lower limb of a patient with another fetal RM in the chest wall and a nevoid basal cell carcinoma syndrome (5, 10). Last-mentioned syndrome can be associated with fetal RM (11).

With an age of 31 years, our patient is far over the median age of four years and only a few fetal RM occurred in patients with an age over 15 years (1). There is a slightly male predominance (2.4:1) for fetal RM and the median size of the tumour mass is 3.0 cm (1).

Although fetal RM is a very rare tumour entity, one should

be aware of the existence of this skeletal muscle tumour. There is a resemblance to malignant rhabdomyosarcoma and a possibility of malignant transformation.

Georg Hauer MD
Jörg Friesenbichler MD PhD
Andreas Leithner MD
Department of Orthopaedics and Traumatology, Medical University of Graz, Auenbruggerplatz 5, Graz, Austria

Franz Gollowitsch MD
Institute of Pathology, Medical University of Graz, Auenbruggerplatz 5, Graz, Austria

Lukas A. Holzer MD PhD
AUVA Trauma Center Klagenfurt, Waidmannsdorferstraße 35, Klagenfurt am Wörthersee, Austria
Department of Orthopaedics and Traumatology, Medical University of Graz, Auenbruggerplatz 5, Graz, Austria

References

- Kapadia SB, Meis JM, Frisman DM, Ellis GL, Heffner DK. Fetal rhabdomyoma of the head and neck: a clinicopathologic and immunophenotypic study of 24 cases. *Hum Pathol.* 1993; 24(7):754-65.
- Osgood PJ, Damron TA, Rooney MT, Goldschmidt AM, Sullivan TJ. Benign fetal rhabdomyoma of the upper extremity. A case report. *Clin Orthop Relat Res.* 1998; 349(1):200-4.
- Willis J, Abdul-Karim FW, di Sant'Agnese PA. Extracardiac rhabdomyomas. *Semin Diagn Pathol.* 1994; 11(1):15-25.
- Dehner LP, Enzinger FM, Font RL. Fetal rhabdomyoma. An analysis of nine cases. *Cancer.* 1972; 30(1):160-6.
- Premalata CS, Kumar RV, Saleem KM, Fathima LJ, Das K. Fetal rhabdomyoma of the lower extremity. *Pediatr Blood Cancer.* 2009; 52(7):881-3.
- Weiss SW, Goldblum JR. *Enzinger and Weiss's soft tissue tumors.* 5th ed. New York: Mosby Elsevier; 2008.
- Kodet R, Fajstavr J, Kabelka Z, Koutecky J, Eckschlager T, Newton WA Jr. Is fetal cellular rhabdomyoma an entity or a differentiated rhabdomyosarcoma? A study of patients with rhabdomyoma of the tongue and sarcoma of the tongue enrolled in the intergroup rhabdomyosarcoma studies I, II, and III. *Cancer.* 1991; 67(11):2907-13.
- Tuazon R. Rhabdomyoma of the stomach. Report of a case. *Am J Clin Pathol.* 1969; 52(1):37-41.
- Whitten RO, Benjamin DR. Rhabdomyoma of the retroperitoneum. A report of a tumor with both adult and fetal characteristics: a study by light and electron microscopy, histochemistry, and immunochemistry. *Cancer.* 1987; 59(4):818-24.
- Dahl I, Angervall L, Save-Soderbergh J. Foetal rhabdomyoma. Case report of a patient with two tumours. *Acta Pathol Microbiol Scand A.* 1976; 84(1):107-12.
- DiSanto S, Abt AB, Boal DK, Krummel TM. Fetal rhabdomyoma and nevoid basal cell carcinoma syndrome. *Pediatr Pathol.* 1992; 12(3):441-7.