

RESEARCH ARTICLE

A Novel Suture Button Construct for Acute Ankle Syndesmotic Injuries; A Prospective Clinical and Radiological Analysis.

Mohamed A. Imam MD, PhD; James Holton BSc, BM, MRCS; Abdel NA Hassan, FRCS Orth; Ahmed Matthana, MD, PhD

Research performed at Department of Trauma and Orthopaedics, Faculty of Medicine, Suez Canal University, Egypt

Received: 14 November 2016

Accepted: 29 November 2017

Abstract

Background: The importance of the syndesmosis in ankle stability is well recognized. Numerous means of fixation have been described for syndesmotic injuries including the suture button technique. Significant cost limits the use of the commercially available options. We, therefore, designed a cheap and readily available alternative construct. We aim to assess the results of using a novel suture-button construct in treatment of syndesmotic ankle injuries.

Methods: Fifty-two patients (34 males and 18 females) fulfilled our inclusion/exclusion criteria. Five patients were lost to follow-up. The remaining 47 patients were successfully followed up for a minimum of 24 months. The pre and post-surgery American Orthopedic Foot and Ankle Society scores (AOFAS) together with reported complications and post-operative radiological analysis were assessed. In this innovative construct, we utilized polyester braided surgical sutures jointly with double mini two-holed plates, a No.2 polygalactin 910 suture, a 4 mm drill bit, together with a 15 cm long suture needle with slotted end. This technique was supported with the use of the image intensifier.

Results: The AOFAS score improved significantly from a mean of 32.4 to 94.2 ($P < 0.004$). Radiologically, the medial clear space (MCS), tibio-fibular clear space (TFCS) ($P = 0.05$) and tibio-fibular overlap (TFO) measurements showed a significant improvement postoperatively ($P = 0.02$). Patients reported good satisfaction rates with a 96% success rate (95% CI: 94.0% to 99.3%).

Conclusion: We have observed that this low cost suture button construct is a simple, safe and cost effective treatment option for acute syndesmotic injuries.



Keywords: Ankle, Injury, Suture button, Syndesmosis

Introduction

The distal tibiofibular syndesmosis is considered crucial for ankle stability that is compulsory for adequate weight transmission and, subsequently, walking (1). The syndesmosis encompasses the anterior-inferior tibiofibular ligament, posterior-inferior tibiofibular ligament, inferior transverse tibiofibular ligament, and the interosseous ligament. This complex steadies the mortise by securing the fibula in the fibular notch (1–3). Syndesmotic injuries are frequently associated with malleolar fractures (1). Nevertheless, they may occur alone without associated fractures.

Isolated syndesmotic injuries are commoner in sports related injuries and these can potentially be managed non-operatively. Yet, Symptomatic distal tibiofibular syndesmotic injuries and injuries associated with ankle fractures are usually treated by surgical rigid fixation by syndesmotic screws (4, 5). Syndesmotic injuries ought to be repaired if found unstable after fixation of malleolar fractures to prevent instability and subsequently reduce the risk of ankle osteoarthritis (OA). As yet, anatomic reduction and rigid fixation is the standard treatment of syndesmotic injuries as abnormal shift of the talus has

Corresponding Author: James Holton, Royal Orthopaedic Hospital, Birmingham, UK
Email: Holton1404@gmail



THE ONLINE VERSION OF THIS ARTICLE
ABJS.MUMS.AC.IR

been associated with early and progressive OA (3).

Syndesmotic injuries are thought to occur in 10% of fractures around the ankle and up to 20% of fractures that require operative intervention (6). The current AO foundation online resources list 3.5 or 4.5mm screws can be used with either a single or two screw construct (7). However, a negative with screw fixation is that a subsequent procedure may be required to remove the screws if there is loosening or soft tissue irritation.

Numerous means of fixation have been described over the years including the suture button technique, bolt fixation, staples and syndesmotic hooks. Recently, fixation by the suture button technique, such as the TightRope by Arthrex (Arthrex Inc., Naples, FL, USA) has been popularized. Recent in-vitro biomechanical studies have advocated this technique as a sturdy means of fixation and it was reported to be as potent as syndesmotic screws mechanically. This method allowed more flexibility resulting in a physiologic movement of the distal tibiofibular joint (8, 9). In addition, even though the suture-button system was initially presented as a construct that did not need removal, the rate of implant removal has been reported as up to 25% (4). Klitzman et al conducted a cadaveric study to analyze suture button biomechanics in comparison to screw fixation (10). The study found that suture-button fixation held reduction after cycling with submaximal loads comparable to an intact syndesmosis. Also, more physiologic movement of the fibula in the sagittal plane was noted when compared to tri-cortical screw fixation. However, Teramoto et al reported potential limitations of suture button devices with finding insufficient fixation in multidirectional testing (11).

Due to increased costs, these commercially available devices may not be easily accessible in all institutions. Consequently, we decided to develop a similar construct in a more cost effective manner. Our aim is to describe and evaluate the effectiveness of a bespoke suture-button assembly for the management of distal tibiofibular syndesmotic diastasis injuries.

Materials and Methods

This study was carried out prospectively between January 2011 and April 2014. Fifty-two consecutive patients were recruited for this study (34 males and 18 females) with a mean age of 38.2 (18-55) years. Five patients were lost to follow-up (three withdrew, and 2 lost to follow-up) while the remaining 47 patients continued their regular follow-up up to a minimum of two years post surgery. The study was carried out in a level 1 trauma center serving a population of 5 million people. After being approved by our institutional research board (IRB). This study was carried out as a multi-surgeon (two), single centre study, using the same technique in all recruited patients.

The study received approval by the Research Ethics Board at our institution before its initiation. A minimum 24-month post-operative follow-up period for each patient was planned. Our inclusion criteria included male and female patients in all age groups who presented to our institution with distal tibiofibular syndesmotic diastasis injuries. Patients were medically fit for surgery and able

to provide informed consent. Radiological confirmation of syndesmotic injury was determined by a tibiofibular clear space (TFCS) more than 5.0 mm on the anteroposterior or mortise radiographs, medial clear space (MCS) more than superior clear space or 6.0 mm on the anteroposterior radiographs, or tibiofibular overlap (TFOL) less than 6.0 mm on the anteroposterior radiograph or less than 1.0 mm on the mortise radiographs (7, 1, 12, 13).

Our exclusion criteria were patients with pathological fractures, open or potentially infected ankle fractures, multiple injuries in the same limb, uncontrolled diabetes mellitus, neuropathic arthropathy or Charcot joint patients, neuropsychiatric and other disorders that may render patients unable to comply with instructions. All patients were given an information sheet and asked to provide consent prior to inclusion to the study. All patients were invited to complete an American Orthopaedic Foot and Ankle Society (AOFAS) ankle score prior to and at one and two-year intervals post-surgery. Both (M.I.) and (A.M.) assessed the eligibility of all patients pre-operatively before recruitment in the study.

Construct Structure (Illustration of steps summarized in Figure 1)

The components were assembled intra-operatively under sterile conditions. These components included a polyester braided Ethibond (size 5) sterile surgical sutures and two mini plates (size 2 mm) with two holes, Polygalactin 910 sutures Vicryl (size No.2), 4 mm drill bit, and a 15cm long slotted suture needle was also required. Two polyester ropes were delivered through the two holes of the first plate; by using the folding technique four threads were recruited to transfix the syndesmosis. Afterwards, we utilized the Vicryl sutures as temporary guiding ropes to deliver the main passing plate. This was achieved by knotting a single thread at both tips of this plate (Steps summarized in Figure 1A and 1B).

Surgical technique and postoperative care

Pre-operative antibiotics and antibiotic regimens were the same as per local trauma protocol. Post-operative rehabilitation regimens were carried out in the same manner for all patients. Using spinal anesthesia, patients were positioned supine on the operating table. Initially, a tourniquet was applied at a pressure of 300 mmHg. The associated fractures, if present, were fixed using the standard AO philosophies of osteosynthesis. Spontaneous reduction of ankle syndesmotic diastasis usually ensues after open reduction and internal fixation (ORIF) of malleolar fractures. Syndesmotic injuries were assessed with stress radiographs intra-operatively after fracture fixation. The syndesmosis was stabilised with a spiked bone forceps after fracture fixation if diastasis remained disrupted. If no fracture existed, an incision of approximately 2-3 cm was made on the lateral aspect of the fibula, about 2-5 cm proximal to the plafond level. This is followed by drilling of a tibiofibular tunnel parallel to and proximal to the joint line by 2-5 cm in a direction that is 30° postero-anterior in the horizontal plane from fibula to tibia [Figure 1C]. These steps were performed guided by fluoroscopic image intensifier. Afterwards, the

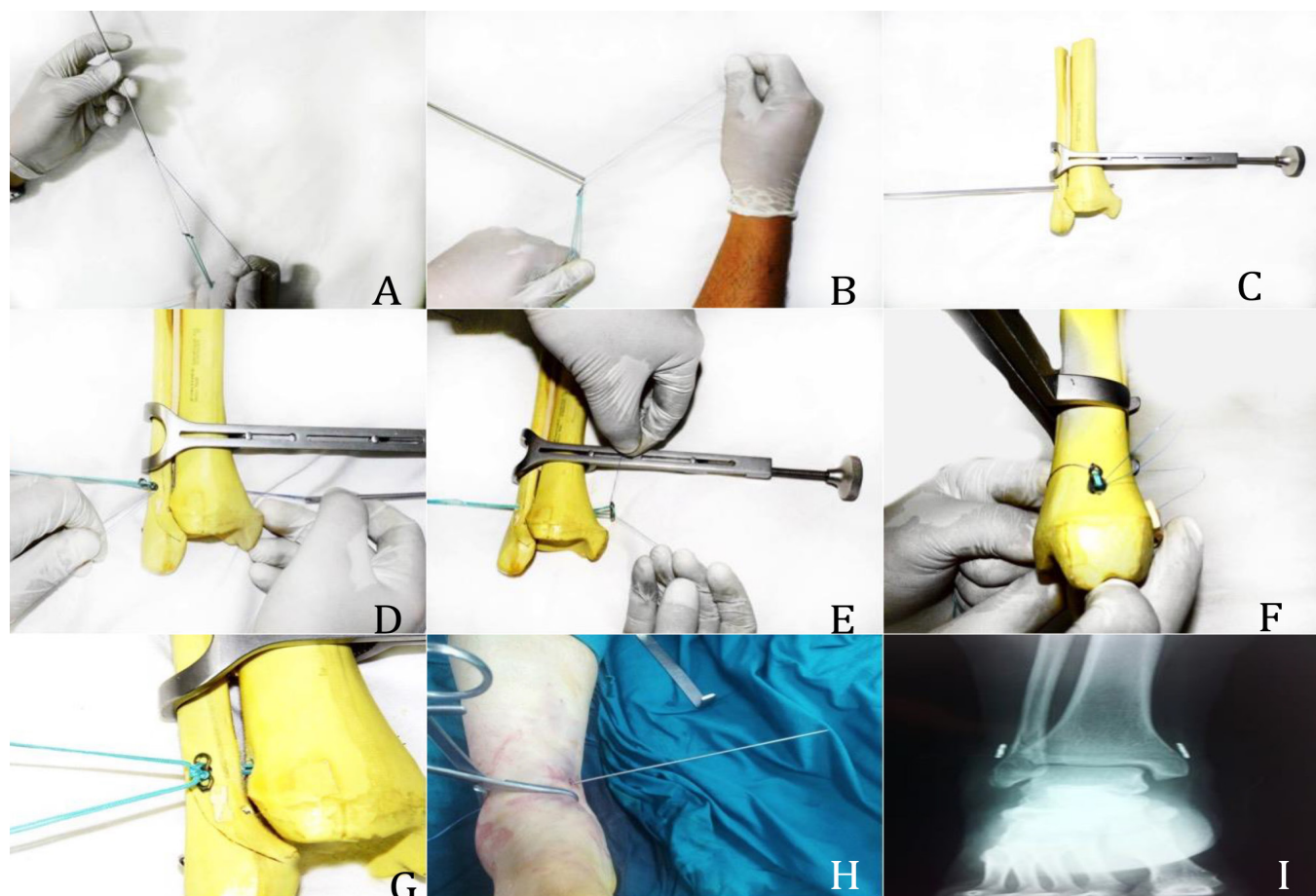


Figure 1. Surgical technique. 1A+B Sutures assembled onto the two hole plates. 1C- Drilling (4 mm) of the tibiofibular tunnel 2-5cm proximal to the joint line. 1D to 1F- passing of the tibia plate and 'flipping' it into position to anchor against the tibia. 1G- Fibula plate secured down to reduce the syndesmosis. 1H- Intra-operative images of the passing of the plate. 1I- Post-operative radiographs of the suture buttons in place and the syndesmosis reduced.

slotted 15 cm straight needle was loaded with the double Vicryl guiding threads and passed through this tunnel until retrieved percutaneously from the medial aspect of the tibia. By pulling one of the two threads the plate could be directed through the tunnel until passing out on the medial aspect. Thereafter, pulling the other thread would secure the plate transversely anchoring on the medial tibial cortex. Finally, the polyester threads were passed through the second mini plate on the fibular side (two threads on each hole) and were knotted tightly together on the plate when satisfactory syndesmotom reduction was achieved [Figure 1D-I]. After wound closure patients were immobilized in a below knee plaster cast for the first two weeks. For isolated injuries of the syndesmosis patients were instructed to partial weight bear in a walking cast.

If malleolar fractures were present, the patient was kept non-weight bearing for six weeks then full weight bearing following this. Two authors (AM and MI) were the operating surgeons in all cases. Five procedures were

carried out by each surgeon prior to commencement of the study to improve the learning curve and decreased potential technical errors that could affect the outcome of procedure.

The key differences with the suture button we describe are that the TightRope system by Arthrex (Arthrex Inc., Naples, FL, USA) uses a knotless ultra-high molecular weight polyethylene (UHMWPE) as its suture construct whilst ours uses Ethibond sutures. Our device is also formed using two, two holes plates compared with the specially designed construct by arthrex that can be used alone or through a plate. The construct we describe would have to be used separately to a plate and could not be used through a plate like the Arthrex system.

Clinical and radiological assessment

Patients were followed up at 6 weeks, 6, 12 and 24 months postoperatively. Final clinical and radiographic evaluation was undertaken at 24 months. Radiographic analysis as previously described was performed on the

radiographs of the affected ankles by two independent observers.

Statistical Analysis

The data was analyzed using SPSS software (Version 14; SPSS Inc, Chicago, Illinois). Data was checked for normality using the Kolmogorov-Smirnov test. For normally distributed data Student's t-test was used and Mann-Whitney U test was applied for non-parametric data. The survival rate was calculated using Kaplan-Meier survival curves with 95% confidence intervals (CI). Student t-tests was used to compare the improvement of the ankle scores pre and post-operatively. A *P-value* of less than or equal to 0.05 was considered statistically significant.

Results

During the two years following surgery, five patients were lost to follow-up. The remaining 47 ankles (28 right and 19 left) were evaluated at two years following surgery. The mean age of patients was 38.2 (18-55) years at the time of surgery. The mechanism of injury was falls in 13 patients, road traffic accidents in 22 patients and sports injuries in the remaining patients. Four patients presented with pure syndesmotic disruption, while the remaining 43 patients had associated malleolar fractures. The AOFAS score improved significantly from 32.4 (range 21.3-37.2) preoperatively to 94.5 (range 84-98) at 2 years post surgery ($P=0.004$).

There were two documented superficial wound infections post surgery treated successfully with antibiotics without requiring secondary surgery. One patient required treatment for deep vein thrombosis. Revision was undertaken as a result of implant failure in two ankles. The first revision was carried out after

14 days. The patient sustained a fall on the 10th day postoperatively. There was subsidence and pull through of the plate into the bone. Revision was performed with a repeat of the suture-button construct to restore of anatomical reduction. No further surgery was required as complete healing was achieved.

The second case was a 36-year-old woman, who was revised at 5 weeks. She was one of our early cases recruited in the study, presenting with an isolated syndesmotic injury. Marked widening of the MCS during the initial post-operative follow up X-rays was observed. This failure of syndesmotic reduction was attributed partly to a missed deltoid ligament disruption and additionally due to imperfect tightening of the threads. Repair of the deltoid ligament, hardware removal and fixation with a syndesmotic screw was undertaken to revise the fixation. No further surgery was required as complete healing was achieved.

A complete radiographic series was available for 47 ankles (47 patients). The distance of sutures from tibial plafond had a mean of 25.5 (23.2 - 34.3) mm. The MCS significantly decreased from 8.8 (6.7-12.8) mm pre-operatively to 3.2 (range 2.6 - 4.1) mm at two years post-operatively ($P=0.04$). Similarly, The TFCS significantly decreased from a mean of 9.2 mm (6.9- 11.8) pre-operatively to mean of 4.2 mm (range 3.3-5) at two years post-operatively ($P=0.05$). The TFO in the AP view significantly improved from a mean of 2 (0-5) mm preoperatively to a mean of 8 (7-9) mm ($P=0.02$). Finally, excluding the two revisions, none of the ankles demonstrated evidence of nonunion radiologically. Using radiographic loosening of the construct as the endpoint for failure, the survival rate of the component was with 96% survival (95% CI: 94.0% to 99.3%) [Figure 2].

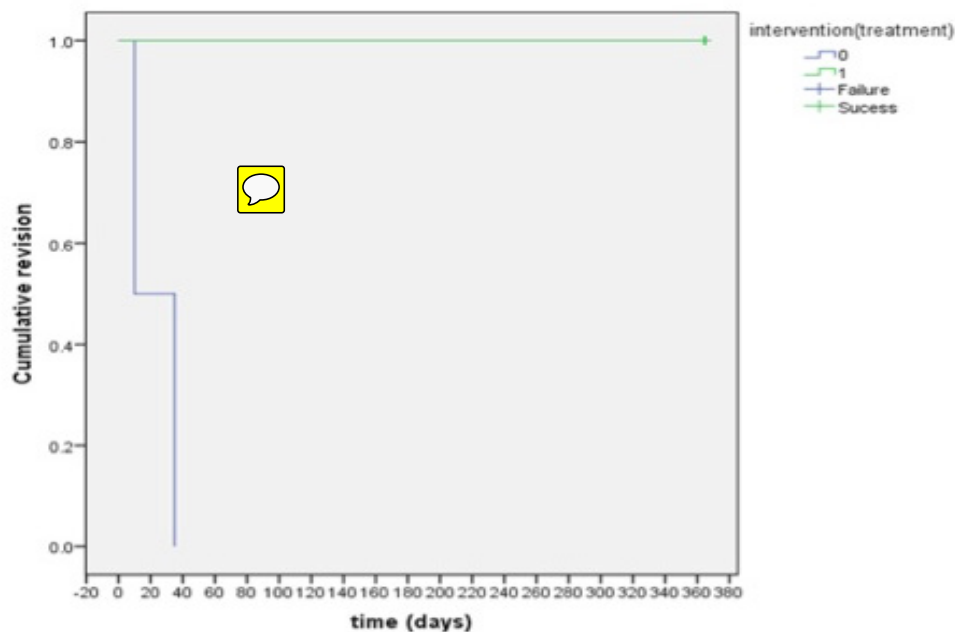


Figure 2. Kaplan-Meier plot of survivorship of the implant.

The crude cost of this construct is approximately 45 dollars compared to 625 dollars, which is the cost of the commercial available alternative provided by Arthrex (Arthrex Inc., Naples, FL, USA) in our institution. This reduced the expense for the 52 constructs recruited in this study from \$32500 to \$2340. Accordingly, using our construct was significantly cheaper ($P < 0.001$).

Discussion

We have observed excellent survivorship at 96% in a consecutive series of 47 low cost suture-button constructs for acute ankle syndesmotic injuries with a two-year follow-up. The use of suture buttons for management of syndesmotic ruptures has increased as an alternative solution to syndesmotic screws as it provides superior physiological properties when compared to standard syndesmotic screw fixation methods (3, 8, 9, 14).

Syndesmotic injuries occur when there is a disruption of the distal attachment of the tibia and fibula. The disruption of the syndesmosis is common, as it constitutes up to 18% of ankle sprains (3). Identification of these injuries is crucial to avoiding long-term morbidity. Diagnosis and management of these disruptions requires a comprehensive understanding of the normal anatomy and the role it plays in the stability of the ankle (1). Cadaveric studies have demonstrated that the use of a suture button technique provides similar biomechanical strength yielded by screw fixation (14, 15). Bava et al has reported that suture buttons are used in approximately 10% of all surgical procedures performed for syndesmotic disruptions in the United States (16). It provides the required flexibility for the normal gliding movement of the distal tibiofibular joint (3, 8). Subsequently, It may lead to faster return to work with comparable outcome compared to both the syndesmotic screw and the bolt fixation (17).

There is a recent move to suture-button fixation by many orthopaedic surgeons. This has fundamentally been because of the purported advantage of providing quicker weight bearing, rapider recovery, and proposed superior functional outcomes compared with screw fixation (18). Naqvi et al compared the commercially available suture-button to syndesmotic screws in the management of syndesmotic injuries (18). They demonstrated that screw fixation allow significant diastasis of the operated syndesmosis in comparison to the other side. Moreover, the screw fixation group demonstrated 21.7% greater incidence of hardware removal. No significant difference was demonstrated between both groups in regards to return to pre-injury weight-bearing status, although the suture-button group showed an average return to full weight-bearing a week ahead on average. Thornes et al published significantly superior AOFAS scores for suture-button group compared to screw fixation (91 versus 80; 93 versus 83) at 3-month and 1-year follow-ups respectively (17). They also demonstrated quicker return to work with an average of 2.8 months for the suture-button group compared to 4.6 months

in the screw fixation group. Additionally, Thornes et al reported that 75% of the patients in the screw fixation group required hardware removal, while none of the suture-button group required a second surgery (17). Recently, a systematic review by Schepers displayed similar AOFAS outcome scores for the management of syndesmotic injuries with a mean of 89 points when the TightRope system was used compared to 86 points when screw fixation was used. The follow-up was 2.2 times longer in the screw group with an increased requirement for implant removal (3). We achieved a mean AOFAS score of 94.5, using our technique at 24 months follow-up.

Implant removal is a concern with both suture button and screw fixation. Schepers reported that implant removal was required in 22/220 (10%) patients treated with a TightRope compared to 449/866 (51.9%) patients treated with a syndesmotic screw or bolt with an average follow-up of 16 and 24 months respectively (3). Furthermore, the relative early rehabilitation together with the absence of the need to remove hardware makes this procedure more attractive (14, 17). There is still an ongoing debate on whether it is necessary to remove syndesmotic screws but also the diameter of screw to be used, and number of cortices required for fixation. A common complication with screw fixation is the failure of the screws, which may require further surgery to retrieve the failed metalwork. Nonetheless, a review by Schepers concluded that there is no functional difference in patients with retained or removed screws (19). The presence of reported complications following screw removal, such as recurrent diastasis and infection is also a source of concern (5, 20).

Our assembly comprised two two-holed mini plates (Trinon GmbH, Karlsruhe, Germany) deployed as buttons and polyester braided (No.5) surgical sutures as ropes. In this study, we aim to assess the results of using a simply fashioned suture-button construct in the treatment of syndesmotic ankle injuries. Moreover, by using this technique early weight bearing can be safely allowed, and the need of another operation for removal of the hardware is reduced (3, 21).

We report two ankles with superficial infection and implant failures in two patients. Complications of stitch abscess, osteomyelitis, painful aseptic osteolysis, polyethylene debris osteolysis reaction and implant failures have been reported previously (21, 22). Degroot et al recommended guidelines to optimize the surgical technique to avoid these complications (21). The authors proposed cutting the FiberWire at least 1 cm beyond the knot, so as its sharp end rests flat bordering to the fibula to avoid soft tissue irritation alongside utilizing a small medial incision so as to place the endobutton directly on the tibial cortex to avoid soft tissue interposition, thus precluding re-diastasis. In addition, they advocated introducing the TightRope through a fibula plate, to avoid lateral button pull-through and subsequently re-diastasis. At a mean follow-up of 20 months both the clinical and radiological measurements were improved and returned to normal values for the entire study group

post-operatively. Nonetheless, One in four patients required removal of the suture button device due to local irritation or lack of motion. Three patients showed heterotopic ossification, and implant failure due to osteolysis, which was evident in four patients (21).

A limitation of our study is that MR images were not available for all patients after surgery, to assess the degree of healing of the syndesmosis. We have also used radiographic parameters to assess reduction of the syndesmosis, although we recognize that CT is the gold standard to assess reduction, there was not enough available scans to use it as an assessment tool (12, 13). Confounding factors including duration of symptoms, concurrent compensation claims or pending litigation, which might affect the final outcome after surgery. Likewise, we did not have a control group in which the gold standard (Syndesmotom screw) is used for management of similar injuries. Although we report good clinical outcomes, there is no biomechanical evidence to support that this construct is as strong as screws or TightRope or has the physiological benefit reported from the TightRope system. The results of the current study do not prove "cost-effectiveness," because crude costs on its own do not establish cost-effectiveness. Calculation of cost-effectiveness needs a multifaceted analysis that involves more than one variable.

In the current financial pressure on healthcare providers worldwide, enhanced efficiency and appropriate application of existing resources is crucial. We report excellent survivorship of 47 low cost suture button constructs for management of acute ankle syndesmotom injuries with a two-year follow-up. This suture button technique delivered satisfactory anatomical reduction and durable physiologic fixation of the syndesmosis. Further biomechanical studies are required to validate this novel construct and compare it to established

suture button systems.

Acknowledgements

This work was self-funded by Suez Canal University Hospitals. All authors read and approved the final manuscript. We would like to thank Dr Ahmed Maaty for undertaking statistical analysis for this study.

This study was self-funded.

All Authors declare that they have no conflict of interest.

All procedures performed in studies involving human participants were in accordance with the ethical standards of the institutional research committee and with the 1964 Helsinki declaration and its later amendments or comparable ethical standards.

Informed consent was obtained from all individual participants included in the study.

Mohamed A. Imam MD PhD
Department of Trauma and Orthopaedics, Faculty of
Medicine, Suez Canal University, Egypt

James Holton BSc BM MRCS
Royal Orthopaedic Hospital, Birmingham, UK

Abdel NA Hassan FRCS Orth
Ashford and St Peters Hospital, Chertsey, UK

Ahmed Matthana MD PhD
Department of Trauma and Orthopaedics, Faculty of
Medicine, Suez Canal University, Egypt

References

1. Lin CF, Gross ML, Weinhold P. Ankle syndesmosis injuries: anatomy, biomechanics, mechanism of injury, and clinical guidelines for diagnosis and intervention. *J Orthop Sports Phys Ther.* 2006; 36(6):372-84.
2. Salamon A, Salamon T, Nikolic V, Radic R, Nikolic T, Jo-Osvatic A. Holistic approach to functional anatomy of the injured ankle joint. *Coll Antropol.* 2003; 27(2):645-51.
3. Schepers T. Acute distal tibiofibular syndesmosis injury: a systematic review of suture-button versus syndesmotom screw repair. *Int Orthop.* 2012; 36(6):1199-206.
4. Miller TL, Skalak T. Evaluation and treatment recommendations for acute injuries to the ankle syndesmosis without associated fracture. *Sports Med.* 2014; 44(2):179-88.
5. Hsu YT, Wu CC, Lee WC, Fan KF, Tseng IC, Lee PC. Surgical treatment of syndesmotom diastasis: emphasis on effect of syndesmotom screw on ankle function. *Int Orthop.* 2011; 35(3):359-64.
6. Egol KA, Pakh B, Walsh M, Tejwani NC, Davidovitch RI, Koval KJ. Outcome after unstable ankle fracture: effect of syndesmotom stabilization. *J Orthop Trauma.* 2010; 24(1):7-11.
7. Amendola A, Williams G, Foster D. Evidence-based approach to treatment of acute traumatic syndesmosis (high ankle) sprains. *Sports Med Arthrosc.* 2006; 14(4):232-6.
8. Forsythe K, Freedman KB, Stover MD, Patwardhan AG. Comparison of a novel FiberWire-button construct versus metallic screw fixation in a syndesmotom injury

- model. *Foot Ankle Int.* 2008; 29(1):49–54.
9. Soin SP, Knight TA, Dinah AF, Mears SC, Swierstra BA, Belkoff SM. Suture-button versus screw fixation in a syndesmosis rupture model: a biomechanical comparison. *Foot Ankle Int.* 2009; 30(4):346–52.
 10. Klitzman R. Views and experiences of IRBs concerning research integrity. *J Law Med Ethics.* 2011; 39(3):513–28.
 11. Teramoto A, Suzuki D, Kamiya T, Chikenji T, Watanabe K, Yamashita T. Comparison of different fixation methods of the suture-button implant for tibiofibular syndesmosis injuries. *Am J Sports Med.* 2011; 39(10):2226–32.
 12. Harper MC, Keller TS. A radiographic evaluation of the tibiofibular syndesmosis. *Foot Ankle.* 1989; 10(3):156–60.
 13. Gardner MJ, Demetrakopoulos D, Briggs SM, Helfet DL, Lorch DG. Malreduction of the tibiofibular syndesmosis in ankle fractures. *Foot Ankle Int.* 2006; 27(10):788–92.
 14. Miller RS, Weinhold PS, Dahners LE. Comparison of tricortical screw fixation versus a modified suture construct for fixation of ankle syndesmosis injury: a biomechanical study. *J Orthop Trauma.* 1999; 13(1):39–42.
 15. Seitz WH Jr, Bachner EJ, Abram LJ, Postak P, Polando G, Brooks DB, et al. Repair of the tibiofibular syndesmosis with a flexible implant. *J Orthop Trauma.* 1991; 5(1):78–82.
 16. Bava E, Charlton T, Thordarson D. Ankle fracture syndesmosis fixation and management: the current practice of orthopedic surgeons. *Am J Orthop (Belle Mead NJ).* 2010; 39(5):242–6.
 17. Thornes B, Shannon F, Guiney AM, Hession P, Masterson E. Suture-button syndesmosis fixation: accelerated rehabilitation and improved outcomes. *Clin Orthop Relat Res.* 2005; 431(1):207–12.
 18. Naqvi GA, Shafqat A, Awan N. Tightrope fixation of ankle syndesmosis injuries: clinical outcome, complications and technique modification. *Injury.* 2012; 43(6):838–42.
 19. Schepers T. To retain or remove the syndesmotoc screw: a review of literature. *Arch Orthop Trauma Surg.* 2011; 131(7):879–83.
 20. Schepers T, Van Lieshout EM, de Vries MR, Van der Elst M. Complications of syndesmotoc screw removal. *Foot Ankle Int.* 2011; 32(11):1040–4.
 21. Degroot H, Al-Omari AA, El Ghazaly SA. Outcomes of suture button repair of the distal tibiofibular syndesmosis. *Foot Ankle Int.* 2011; 32(3):250–6.
 22. Storey P, Gadd RJ, Blundell C, Davies MB. Complications of suture button ankle syndesmosis stabilization with modifications of surgical technique. *Foot Ankle Int.* 2012; 33(9):717–21.