

**CURRENT CONCEPTS REVIEW**

# A challenge on Orthopedic Sciences: The Influence of Spinal Disease and Deformities on Total Hip Arthroplasty: A Review on Literature

Ali Yeganeh, MD; Mehdi Moghtadaei, MD; Mohsen Motalebi, MD

*Research performed at Rasool-e-akram Hospital, Tehran, Iran*

*Received: 22 June 2017*

*Accepted: 09 January 2018*

**Abstract**

**Background:** Adult degenerative disorders of hip and spine are common. The recent studies inconsistently have discussed about the influence of spinal disorders on total hip arthroplasty (THA). In this review, we discussed clearly about these relationships and their effects on the most appropriate position of the acetabular component.

**Methods:** We searched on databases and evaluated the articles about spinopelvic parameters in patients with spinal disorders who needed THA.

**Results:** The literature search showed a prevalence of 21.2 % to 60.4% of low back pain (LBP) in patients, who are candidates for primary THA. The coexistence of degenerative disease of hip and spine or other diseases can significantly alter spinopelvic alignment. Accordingly, pain management or any other treatment in these patients requires proper understanding about the biomechanics of the hip and the spinal and their corresponding interactions. In this review article, we discussed about these interactions and their effects on the most appropriate position of the acetabular component.

**Conclusion:** We concluded that counseling sessions among patients, orthopedic surgeons and spine surgeons can result in obtaining the best outcome for these individuals.

**Level of evidence:** I

**Keywords:** Hip arthroplasty, Spinal disorders, Spinal parameters, Spinopelvic alignment

**Introduction**

It is impossible to evaluate a specific region of body without considering its interactions with the other body elements. Thus, having a tunnel vision to the site of pathology without evaluating other related origins is not accepted and may result in mismanagement.

Adult degenerative disorders of the hip and the spine are common (1). Studies reported up to 12% of degenerative hip joint disease for patients with age 80 and above (2). Also, the prevalence of spondylosis has ranged from 9.7% to 90.1% according to age and sex in general populations (78.2% in women and 90.1% in

**Corresponding Author:** Mohsen Motalebi, Department of Orthopedics, Baqiyatallah University of Medical Sciences, Tehran, Iran  
Email: dr.motalebi@gmail.com



THE ONLINE VERSION OF THIS ARTICLE  
ABJS.MUMS.AC.IR

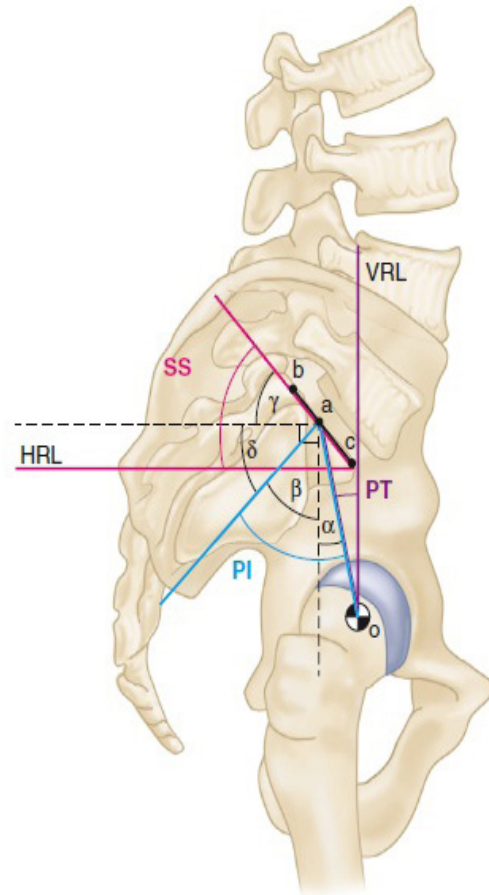
men older than 80) (3, 4). A literature review showed a prevalence of 21.2 % to 60.4% of LBP in patients, who are candidates for primary total hip arthroplasty (THA) (5, 6).

Due to this high association of osteoarthritis in hip and spinal joints, hip-spinal syndrome has been introduced by Offierski and MacNab in 1983 (7). They categorized this syndrome into four groups as follows. (1) Simple hip spine syndrome with pathologic changes in the hip and the spine with a clear source of pain and disability (2). Secondary hip-spine syndrome; it is defined as aggravated spine syndrome by the hip deformity (3). Complex hip-spine syndrome, a condition that in both spine and hip were symptomatic and there was no clear source for the pain and disability (4). Misdiagnosis syndrome; in this category, the source of pain was not identified properly.

The coexistence of degenerative disease of hip and spine or other diseases can significantly alter spinopelvic alignment (8-11). Accordingly, pain management or any treatment in these patients requires proper understanding about biomechanics of hip and spinal parameters and consideration of the relative contribution of each region. In this review, we discussed about these relationships and finally their effects on the most appropriate position of the acetabular component.

### Biomechanics and Parameters

Human bipedalism is an exclusive and ergonomic position which requires excellent coordination between the hip and the spine (12). The normal spine is vertical, having a midline axis that passes through the central of the sacrum (central sacral vertical line). On the other hand, the normal pelvis is horizontal, with symmetrical points at equal height (13). However, the spatial perception of the sagittal pelvic position is more complex. Understanding of sagittal balance of the pelvis requires the definition of certain parameters. Pelvic incidence (PI), introduced by Beaupere and colleagues, was defined as the angle between the line perpendicular to the sacral plate at its midpoint and the line connecting this point to the axis of the femoral heads on a lateral radiograph (14, 15) [Figure 1]. On a lateral view, the width of the pelvis is quantified by the PI. It is a constant angle that becomes set at the end of the growth period, regardless of its position. It is specific for each person and differs in various individuals. Pelvic tilt (PT) and sacral slope (SS) are two angles that are directly correlated with the PI. Actually, PI is the algebraic sum of PT and SS. The pelvis can rotate around the femoral heads up to a certain limit. This rotation is regarded as the PT. PT is defined by the angle between the vertical reference line and the line connecting the midpoint of the sacral plate and the axis of the femoral heads. Another parameter is SS, the angle between a line parallel to the S1 end plate and a horizontal line. This angle is variable during spinopel. In addition, there is a proved relationship between SS and lumbar lordosis (LL). As LL decreases, SS concurrently



**Figure 1. Spinopelvic parameters.**  
VRL; vertical reference line, HRL; horizontal reference line, SS; sacral slope, PT; pelvic tilt, PI; pelvic incidence

decreases and PT increases, thus, the pelvis is getting retroverted (16-18).

Spinal diseases and deformity can lead to sagittal and coronal imbalance. To maintain complete activity of daily living (CADL), such patients have to increase motion in hip joints due to lumbar pain or fear from lumbar motion pain (19). Many investigations showed that SS and PT changes in various positions (20-22). When someone is lying, SS and LL are at their peak (usually above 45°) and pelvis is tilted forward and also acetabular version and abduction are in the lowest to give high maneuverability to hip for full extension. In standing position, the PT is slightly backward, SS decreases slightly (35° to 45°), and acetabular version and abduction increase. Finally, as the patient goes to a seated position, the pelvis is completely backward, SS decreases to less than 25° and for full hip flexion, acetabular version and abduction further increase (23). Patients who have undergone THA and have a balanced spine show a similar adjustment in spine pelvis

alignment in different positions (24). Patients suffered from lumbar disease with limited lumbar range of motion (ROM) show slight change in pelvis orientation in different positions. There is little changes in SS, PT, or acetabular version or abduction with body positioning, inherently limiting the ability to accommodate additional hip flexion or extension in sitting and standing positions, respectively (20, 22). Degenerative spine disease or other spine pathologies which are shown in LBP results in LL and SS reduction and a significant increase in PT (25, 26). The compensatory mechanisms in these patients with lumbar hypolordosis are thoracic hyperextension, forwarded trunk tilt, knee flexion, hip extension, posterior PT and acetabular anteversion (AA) (11, 21, 27, 28).

### Spinal Disease and Acetabular Component

Many studies evaluated the changes in pelvic parameters during various positions in patients undergoing THA (29-32). Lazennec et al. found that changing position from standing to sitting in patients with previous THA results in a mild increase of 15.6° in AA (29). They concluded that lumbosacral mobility was crucial for this physiological change to limit post-operative impingement. Kanawade et al. showed a mean verticality increase of 25° in acetabular component in patients with THA and normal spinal mobility in the position of standing to sitting (31). They recommended adjusting placement of the components to avoid instability, especially in patients with a hyper-mobile pelvis (33). There are also some researches to anticipate amount of change (32, 34). Lembeck et al. determined that for every 1° increase in pelvic retroversion, AA increases 0.7° (34).

Recently, the role of spinal disease and deformity in acetabular component orientation during THA has been mentioned by some investigators. This is because of studies which showed a significant high rate of complication in patients who were undergone THA with concurrent spinal disease and deformity, specially dislocation and impingement. Prather et al. showed a greater improvement in CADL and pain relief in patients who were undergone THA without spinal disease and deformity when compared to those who have spinal disease and deformity (35). Tang et al. evaluated 95 primary THA in 58 patients with ankylosing spondylitis and detected the higher incidence of complications such as dislocation on top of them (36). In 2014, Zheng et al. conducted a study on 28 patients with ankylosing spondylitis and detected a high rate of dislocation, given that they first underwent THA and then had a corrective spinal osteotomy (37). Also, Nilsdotter et al. reported that patients with post-operative LBP have less long term functional improvement after THA (38). Conversely, some investigators showed THA in patients with severe osteoarthritis of hip can significantly relieve LBP (39, 40).

This subject remains as a challenge in orthopedic sciences and some procedure should be done firstly such as THA or spinal procedure. Also finding proper answer for some questions is still challenging. The questions

can be if we can nominate patients with coexistence hip and spinal osteoarthritis just for THA without any procedure on spine?; or does spinal misalignment have no influence on acetabular cup in THA? Some authors recommended THA can relieve both hip and LBP (39, 40). There are some notes on this recommendation as follows. 1) Remaining hip pain or LBP after THA results in less improvement in patient's outcome (38). 2) THA alone without considering spinal disease and deformity lead to increase rate of complication. 3) The most important diagnostic method for coexistence of osteoarthritis in hip and spinal joints are the remaining pain after THA. Thus, we think LBP relief after THA have been due to a referral pain from hip, as we know there is low compliance between osteoarthritis clinical symptoms and radiographic signs. Thus, a LBP with spine origin will not relief after THA. Some surgeons recommend to treat the most symptomatic diseases firstly, but there is an important criticism on this recommendation. Pelvic parameters have a significant influence on position of acetabular cup which changed significantly after spinal procedures (41). In overall, most surgeons recommended correcting spinal misalignment before THA. Once it is impossible to correct spinal misalignment, acetabular cup orientation should be adjusted (42).

The definition of safe zone for acetabular cup was mentioned by Lewinnek and colleagues in 1978 (43). They showed that dislocation rate after THA was the lowest in 15±10° anteversion and 40±10° inclination of acetabular cup. A big problem on their definition was that they did not consider lumbar spine parameters and it's dynamic. In case of spine disease and deformity, hypolordosis lead to increase posterior PT (retroversion) (44). In the standing position and for compensating this position, acetabulum should be anteverted and abducted. Thus, pelvis is forced to hyperextended position and finally results in posterior hip impingement and anterior instability. On the other hand, in the seated position, hip joints are hyperflexed because of a rigid lumbar spine which cannot flex spinopelvic complex as much as needed. This leads to potential posterior instability (19). In fact, the compensatory mechanisms to restore postural balance in patients with lumbar hypolordosis include thoracic hyperextension (or loss of kyphosis), forward tilt of the trunk, knee flexion, hip extension, and increased or posterior PT (10, 26, 27). The net compensatory outcome is positive sagittal balance and relative pelvis retroversion with subsequent excessive AA (21). Zhu and coworkers in 2010 determined that only 6.1% of patients have zero PT (45). Most patients (83.9%) fell in a narrow range close to neutral PT (PT<10°). However, the outlier patients would have been a cup implanted correctly according to anterior pelvic plane, but functionally, it would be a malposition that leads to a high risk in extreme position for dislocation and impingement.

Studies have quantified the impact of PT on acetabular inclination as approximately each degree of posterior tilt (retroversion) leads to a 0.7° increase

in acetabular inclination (32, 46). Anatomic version progressively increases with a mean of  $7.1^\circ$  with changing position from standing to sitting in relation to a  $14.5^\circ$  increase in posterior tilt (29). Attention to pelvis and acetabulum position for lumbar rigidity and deformity compensation lead to set off the most (58%) dislocated THAs and have cups placed in the safe zone. This trigger point encouraged investigators to find the relationship between different spinopelvic parameters and cup orientation to recommend various models (47, 48). In 2009, Legaye described a detailed chart based on exact calculation formulas for adjusting AA and inclination [Figure 2] (49). They also noted that the difference between the observed and theoretical values of the SS allows for a precise assessment of the pelvic sagittal mal-rotation (49). If a backward mal-rotation is detected, the corrective angle has to be detracted from the target angle. The recommended corrections were in agreement with those described by Tang et al. who suggested reduction of the inclination and ante version by  $5^\circ$  for each  $10^\circ$  of sagittal mal-rotation beyond  $20^\circ$  (50). Other investigators recommended a correction of  $0.5$  to  $0.7^\circ$  for  $1^\circ$  of pelvic sagittal rotation (19, 51)

Many surgeons have recommended to place acetabular cup in a 'safe zone' of  $5^\circ$  to  $25^\circ$  of anteversion to minimize the complications such as impingement and dislocation and make the maximum ROM available (43, 52). Authors using synthetic special models of hip joint revealed that cup positioning placement in

the safe zone can provide the greatest ROM in flexion and extension (53, 54). Practical movement is greatly sensitive to placing the acetabular cup, with limits to CADL happening through changes of anteversion as little as  $10^\circ$  to  $15^\circ$  (53). Recently, a functional study by Phan and coworkers was performed according to a history of spinal surgery, clinical postural imbalance and also based on pre-operative standing and sitting lateral radiography views (33). Patients considered for THA were categorized into four groups. They attempted to propose an algorithm based on flexible or rigid spinopelvic junctions and also with appropriate sagittal spinal balance ( $PT < 25^\circ$ ;  $PI-LL < 10^\circ$ ) or persistent imbalance ( $PT > 25^\circ$ ;  $PI-LL > 10^\circ$ ) to explain the role of spinal deformity and disease on THA.

In Group I, flexible and balanced patients who had no previous spinal diseases with a full movement of spinopelvic junction were considered. Most of them had a balanced spinal sagittal and full recompense of the spine to accommodate positional changes of the pelvis. Exact AA in this group would be dictated by surgeon precedence, but should be in the acetabular safe zone of  $5^\circ$  to  $25^\circ$  of anteversion to allow for a functional ROM and minimize the risk of impingement.

They also defined patients with rigid spinopelvic junction and sagittal spinal balance (balance Rigid and balance) in Group II. In these patients, AA would not indigenously increase during sitting, potentially causing a loss of functional range of flexion of the hip. They recommended that the orientation of the acetabular

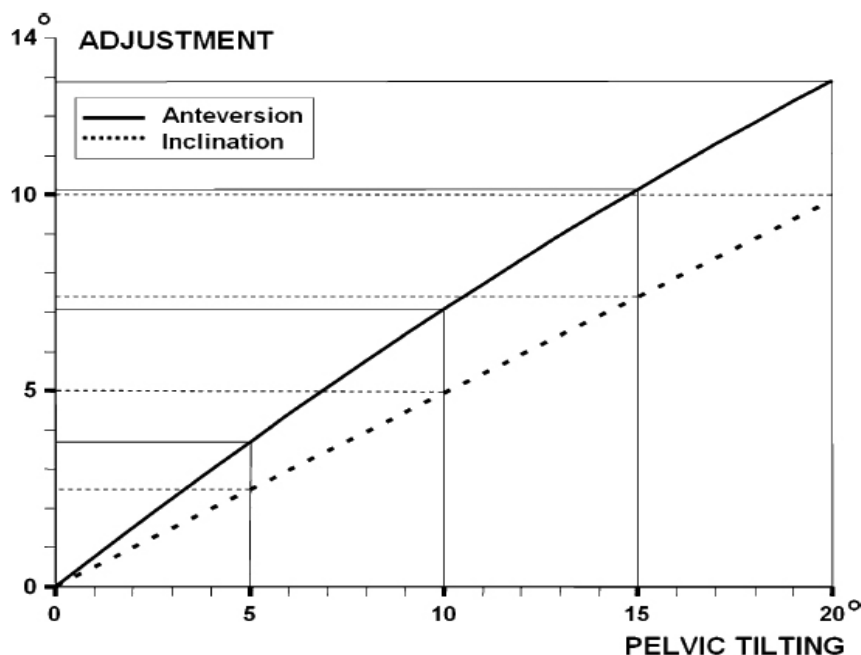


Figure 2. Relation between the pelvic tilt and the angle of inclination and anteversion of the acetabular cup for an aimed  $45^\circ$  inclination according to Legaye's study.

cup for this group should be more anteverted helping to correct the relative acetabular retroversion in the sitting position. Nevertheless, because of a normal ROM in standing position, an extreme anteverted acetabular cup can limit ROM in this position. Therefore, Phan and colleagues recommended placement of the acetabular component in the higher end of the traditional safe zone, with AA of 15° to 25°, to provide an ideal balance in providing the best ROM in both the standing and sitting positions (33).

The authors mentioned that there are two possible treatment pathways for Group III (flexible and unbalance) with flexible spinopelvic junction and sagittal spinal imbalance (PT > 25°; PI-LL > 10°). The first option was to correct the spinal deformity surgically before THA and then patients were treated according Group I procedure. For patients unwilling or unable to undergo major spinal surgery, or with overriding pain in the hip, the second possible option was to proceed with THA with placement of the acetabular component in a position more fully replicating that of the balanced patient (33).

As Phan and colleagues described there are two possible treatments, based on the probability of future spinal surgery for patients Group IV (rigid and unbalance). The first treatment is the correction of spinal malalignment and then placement of the patient into the Group II. The second treatment is to proceed with THA, placing the acetabular component in a position where more fully replicates than in the balanced patient. However, it is important to note that spinal surgery after THA may require revision of the acetabular cup to accommodate the pelvic re-orientation following spinal realignment if there is impingement of the hip and instability (33).

Finally, it seems that except of AA and inclination, other factors such as age, developmental dysplasia, prior hip fracture, and female gender are associated with increase in hip dislocation after THA (55, 56). Esposito et al. mentioned in their study on 7040 patients undergone primary THA that cup position alone did not predict risk of dislocation (48). Abdel et al. also detected that the vast majority of dislocated THAs are within the Lewinnek safe zone for acetabular component position (47). It is required to conduct studies to evaluate these factors in patients with spinal disease and deformity undergone THA.

In this study, we tried to discuss all possible methods for THA in patients with coexisting spinal disease and deformity. These patients are in a high risk for post-operation complications such as dislocation, remaining pain and reducing daily activity. It is obvious that counseling sessions between patient, orthopedic surgeon and spine surgeon can result in achieving the best outcome for these patients.

The authors declare no conflict of interest.

Ali Yeganeh MD

Mehdi Moghtadaei MD

Department of Orthopedics, Rasool-e-akram Hospital, Iran University of Medical Science, Tehran, Iran

Mohsen Motalebi MD

Department of Orthopedics, Baqiyatallah University of Medical Sciences, Tehran, IR Iran

## References

1. Sing DC, Barry JJ, Aguilar TU, Theologis AA, Patterson JT, Tay B, et al. Prior lumbar spinal arthrodesis increases risk of prosthetic-related complication in total hip arthroplasty. *J Arthroplasty*. 2016; 31(9 Suppl):227-32.
2. Lawrence RC, Helmick CG, Arnett FC, Deyo RA, Felson DT, Giannini EH, et al. Estimates of the prevalence of arthritis and selected musculoskeletal disorders in the United States. *Arthritis Rheum*. 1998; 41(5):778-99.
3. Yoshimura N, Muraki S, Oka H, Mabuchi A, En-Yo Y, Yoshida M, et al. Prevalence of knee osteoarthritis, lumbar spondylosis, and osteoporosis in Japanese men and women: the research on osteoarthritis/osteoporosis against disability study. *J Bone Miner Metab*. 2009; 27(5):620-8.
4. Muraki S, Oka H, Akune T, Mabuchi A, En-Yo Y, Yoshida M, et al. Prevalence of radiographic lumbar spondylosis and its association with low back pain in elderly subjects of population-based cohorts: the ROAD study. *Ann Rheum Dis*. 2009; 68(9):1401-6.
5. Hsieh PH, Chang Y, Chen DW, Lee MS, Shih HN, Ueng SW. Pain distribution and response to total hip arthroplasty: a prospective observational study in 113 patients with end-stage hip disease. *J Orthop Sci*. 2012; 17(3):213-8.
6. Staibano P, Winemaker M, Petruccioli D, de Beer J. Total joint arthroplasty and preoperative low back pain. *J Arthroplasty*. 2014; 29(5):867-71.
7. Offierski CM, MacNab I. Hip-spine syndrome. *Spine*. 1976; 8(3):316-21.
8. Thomas JS, France CR. The relationship between

- pain-related fear and lumbar flexion during natural recovery from low back pain. *Eur Spine J.* 2007; 17(1):97-103.
9. Wong TK, Lee RY. Effects of low back pain on the relationship between the movements of the lumbar spine and hip. *Hum Mov Sci.* 2004; 23(1):21-34.
  10. Barrey C, Darnis A. Current strategies for the restoration of adequate lordosis during lumbar fusion. *World J Orthop.* 2015; 6(1):117-26.
  11. Raphael IJ, Rasouli MR, Kepler CK, Restrepo S, Albert TJ, Radcliff KE. Pelvic incidence in patients with hip osteoarthritis. *Arch Bone Jt Surg.* 2016; 4(2):132-6.
  12. Berge C. Heterochronic processes in human evolution: an ontogenetic analysis of the hominid pelvis. *Am J Phys Anthropol.* 1998; 105(4):441-59.
  13. Le Huec J, Aunoble S, Philippe L, Nicolas P. Pelvic parameters: origin and significance. *Eur Spine J.* 2011; 20(Suppl 5):564-71.
  14. Duval-Beaupère G, Schmidt C, Cosson P. A barycentremetric study of the sagittal shape of spine and pelvis: The conditions required for an economic standing position. *Ann Biomed Eng.* 20(4):451-62.
  15. Duval-Beaupère G, Robain G. Visualization on full spine radiographs of the anatomical connections of the centres of the segmental body mass supported by each vertebra and measured in vivo. *Int Orthop.* 1987; 11(3):261-9.
  16. Legaye J, Duval-Beaupère G, Hecquet J, Marty C. Pelvic incidence: a fundamental pelvic parameter for three-dimensional regulation of spinal sagittal curves. *Eur Spine J.* 1998; 7(2):99-103.
  17. Stagnara P, De Mauroy JC, Dran G, Gonon GP, Costanzo G, Dimnet J, et al. Reciprocal angulation of vertebral bodies in a sagittal plane: approach to references for the evaluation of kyphosis and lordosis. *Spine.* 1982; 7(4):335-42.
  18. Vaz G, Roussouly P, Berthonnaud E, Dimnet J. Sagittal morphology and equilibrium of pelvis and spine. *Eur Spine J.* 2002; 11(1):80-7.
  19. Blizzard DJ, Nickel BT, Seyler TM, Bolognesi MP. The impact of lumbar spine disease and deformity on total hip arthroplasty outcomes. *Orthop Clin North Am.* 2016; 47(1):19-28.
  20. Lazennec JY, Brusson A, Rousseau MA. Hip-spine relations and sagittal balance clinical consequences. *Eur Spine J.* 2011; 20(Suppl 5):686-98.
  21. Sariali E, Lazennec JY, Khiami F, Gorin M, Catonne Y. Modification of pelvic orientation after total hip replacement in primary osteoarthritis. *Hip Int.* 2009; 19(3):257-63.
  22. Lazennec JY, Brusson A, Rousseau MA. Lumbar-pelvic-femoral balance on sitting and standing lateral radiographs. *Orthop Traumatol Surg Res.* 2013; 99(1 Suppl):S87-103.
  23. Lazennec JY, Rousseau MA, Rangel A, Gorin M, Belicourt C, Brusson A, et al. Pelvis and total hip arthroplasty acetabular component orientations in sitting and standing positions: measurements reproductibility with EOS imaging system versus conventional radiographies. *Orthop Traumatol Surg Res.* 2011; 97(4):373-80.
  24. Weng W, Wu H, Wu M, Zhu Y, Qiu Y, Wang W. The effect of total hip arthroplasty on sagittal spinal-pelvic-leg alignment and low back pain in patients with severe hip osteoarthritis. *Eur Spine J.* 2016; 25(11):3608-14.
  25. Charosky S, Guigui P, Blamoutier A, Roussouly P, Chopin D; Study Group on Scoliosis. Complications and risk factors of primary adult scoliosis surgery: a multicenter study of 306 patients. *Spine.* 2012; 37(8):693-700.
  26. Lafage V, Schwab F, Patel A, Hawkinson N, Farcy JP. Pelvic tilt and truncal inclination: two key radiographic parameters in the setting of adults with spinal deformity. *Spine.* 2009; 34(17):E599-606.
  27. Barrey C, Roussouly P, Le Huec JC, D'Acunzi G, Perrin G. Compensatory mechanisms contributing to keep the sagittal balance of the spine. *Eur Spine J.* 2013; 22(Suppl 6):S834-41.
  28. Lafage V, Schwab F, Skalli W, Hawkinson N, Gagey PM, Ondra S, et al. Standing balance and sagittal plane spinal deformity: analysis of spinopelvic and gravity line parameters. *Spine.* 2008; 33(14):1572-8.
  29. Lazennec JY, Boyer P, Gorin M, Catonné Y, Rousseau MA. Acetabular anteversion with CT in supine, simulated standing, and sitting positions in a THA patient population. *Clin Orthop Relat Res.* 2011; 469(4):1103-9.
  30. Radcliff KE, Orozco F, Molby N, Delasotta L, Chen E, Post Z, et al. Change in spinal alignment after total hip arthroplasty. *Orthop Surg.* 2013; 5(4):261-5.
  31. Kanawade V, Dorr LD, Wan Z. Predictability of acetabular component angular change with postural shift from standing to sitting position. *J Bone Joint Surg Am.* 2014; 96(12):978-86.
  32. Wan Z, Malik A, Jaramaz B, Chao L, Dorr LD. Imaging and navigation measurement of acetabular component position in THA. *Clin Orthop Relat Res.* 2009; 467(1):32-42.
  33. Phan D, Bederman SS, Schwarzkopf R. The influence of sagittal spinal deformity on anteversion of the acetabular component in total hip arthroplasty. *Bone Joint J.* 2015; 97-B(8):1017-23.
  34. Lembeck B, Mueller O, Reize P, Wuelker N. Pelvic tilt makes acetabular cup navigation inaccurate. *Acta Orthop.* 2005; 76(4):517-23.
  35. Prather H, Van Dillen LR, Kymes SM, Armbrecht MA, Stwalley D, Clohisey JC, et al. Impact of coexistent lumbar spine disorders on clinical outcomes and physician charges associated with total hip arthroplasty. *Spine J.* 2012; 12(5):363-9.
  36. Tang WM, Chiu KY. Primary total hip arthroplasty in patients with ankylosing spondylitis. *J Arthroplasty.* 2000; 15(1):52-8.
  37. Zheng GQ, Zhang YG, Chen JY, Wang Y. Decision making regarding spinal osteotomy and total hip replacement for ankylosing spondylitis experience with 28 patients. *Bone Joint J.* 2014; 96-B(3):360-5.
  38. Nilsdotter AK, Petersson IF, Roos EM, Lohmander LS. Predictors of patient relevant outcome after total hip replacement for osteoarthritis: a prospective study. *Ann Rheum Dis.* 2003; 62(10):923-30.
  39. Ben-Galim P, Ben-Galim T, Rand N, Haim A, Hipp J,

- Dekel S, et al. Hip-spine syndrome: the effect of total hip replacement surgery on low back pain in severe osteoarthritis of the hip. *Spine*. 2007; 32(19):2099-102.
40. Chimenti PC, Drinkwater CJ, Li W, Lemay CA, Franklin PD, O'Keefe RJ. Factors associated with early improvement in low back pain after total hip arthroplasty: a multi-center prospective cohort analyses. *J Arthroplasty*. 2016; 31(1):176-9.
  41. Eksi MS, Yucekul A, Barry JJ, Theologis AA, Mizutani J, Pekmezci M, et al. The effects of adult spinal deformity surgery on total hip arthroplasty acetabular component position. *Spine J*. 2015; 15(10):S260.
  42. Meftah M, Yadav A, Wong AC, Ranawat AS, Ranawat CS. A novel method for accurate and reproducible functional cup positioning in total hip arthroplasty. *J Arthroplasty*. 2013; 28(7):1200-5.
  43. Lewinnek GE, Lewis JL, Tarr R, Compere CL, Zimmerman JR. Dislocations after total hip-replacement arthroplasties. *J Bone Joint Surg Am*. 1978; 60(2):217-20.
  44. Tannast M, Langlotz U, Siebenrock KA, Wiese M, Bernsmann K, Langlotz F. Anatomic referencing of cup orientation in total hip arthroplasty. *Clin Orthop Relat Res*. 2005; 436(1):144-50.
  45. Zhu J, Wan Z, Dorr LD. Quantification of pelvic tilt in total hip arthroplasty. *Clin Orthop Relat Res*. 2010; 468(2):571-5.
  46. Maratt JD, Esposito CI, McLawhorn AS, Jerabek SA, Padgett DE, Mayman DJ. Pelvic tilt in patients undergoing total hip arthroplasty: when does it matter? *J Arthroplasty*. 2015; 30(3):387-91.
  47. Abdel MP, von Roth P, Jennings MT, Hanssen AD, Pagnano MW. What safe zone? The vast majority of dislocated THAs are within the Lewinnek safe zone for acetabular component position. *Clin Orthop Relat Res*. 2016; 474(2):386-91.
  48. Esposito CI, Gladnick BP, Lee YY, Lyman S, Wright TM, Mayman DJ, et al. Cup position alone does not predict risk of dislocation after hip arthroplasty. *J Arthroplasty*. 2015; 30(1):109-13.
  49. Legaye J. Influence of the sagittal balance of the spine on the anterior pelvic plane and on the acetabular orientation. *Int Orthop*. 2009; 33(6):1695-700.
  50. Tang WM, Chiu KY, Kwan MF, Ng TP. Sagittal pelvic mal-rotation and positioning of the acetabular component in total hip arthroplasty: three-dimensional computer model analysis. *J Orthop Res*. 2007; 25(6):766-71.
  51. Babisch JW, Layher F, Amiot LP. The rationale for tilt-adjusted acetabular cup navigation. *J Bone Joint Surg Am*. 2008; 90(2):357-65.
  52. Biedermann R, Tonin A, Krismer M, Rachbauer F, Eibl G, Stöckl B. Reducing the risk of dislocation after total hip arthroplasty: the effect of orientation of the acetabular component. *J Bone Joint Surg Br*. 2005; 87(6):762-9.
  53. Kosashvili Y, Omoto D, Backstein D, Safir O, Lakstein D, Gross AE. Acetabular alignment and primary arc of motion for minus, skirtless, and skirted 28-, 32-, 36-, and 40-mm femoral heads. *J Arthroplasty*. 2013; 28(2):279-85.
  54. D'lima DD, Urquhart AG, Buehler KO, Walker RH, Colwell CW Jr. The effect of the orientation of the acetabular and femoral components on the range of motion of the hip at different head-neck ratios. *J Bone Joint Surg Am*. 2000; 82(3):315-21.
  55. Morrey B. Difficult complications after hip joint replacement: dislocation. *Clin Orthop Relat Res*. 1997; 344(1):172-87.
  56. Woo RY, Morrey BF. Dislocations after total hip arthroplasty. *J Bone Joint Surg Am*. 1982; 64(9):1295-306.