

## CASE REPORT

# Ilizarov Stump Lengthening Can Aggravate Phantom Limb Pain – a Case Report

Konstantin Igorevich Novikov, PhD; Koushik Narayan Subramanyam, MS, MRCSEd; Sergey V Kolesnikov, MD; Oleg K Chegurov, PhD; Elina S Kolesnikova, MD; Abhishek V Mundargi, DNB

Research performed at Russian Ilizarov Scientific Centre for Restorative Traumatology and Orthopaedics, M.Ulianova, Kurgan, RU

Received: 17 July 2017

Accepted: 11 November 2017

### Abstract

Ilizarov is an accepted technique for lengthening short amputation stumps to improve prosthetic function and rehabilitation. The relation of stump lengthening and phantom limb pain (PLP) has not been reported in literature. We present here a case report of a transfemoral amputee who had a flare up of PLP following stump lengthening. He responded well to a combination of pharmacological therapy and soft tissue manipulative techniques and desired length was achieved. This report alerts the possibility of aggravation of PLP following stump lengthening and discusses management.



**Keywords:** Above knee amputation, Amputee rehabilitation, Ilizarov, Phantom limb pain, Stump lengthening

### Introduction

Phantom limb pain (PLP) is pain in the limb segment that does not exist. Its etiology remains poorly understood. Many pharmacological, physical, reflexological and surgical techniques are reported for its management (1). Reports of stump lengthening with Ilizarov are rare and none of them mention the relation of stump lengthening to PLP (2-4). We report a case of aggravation of PLP following Ilizarov stump lengthening. Written informed consent for the surgery and publication was obtained from this patient.

### Case report

A 36 year old male patient had crush injury of right lower limb with femoral arterial injury following run over in a high velocity road traffic accident. Emergency above knee amputation was done as a life and limb saving measure. It was through proximal third of thigh and the stump length was 7cm [Figure 1]. The next day patient developed phantom limb pain (PLP) which was most intense at the toes. He was treated with conventional narcotic and non-narcotic analgesics and was started on oral carbamazepine at a dose of 400

mg per day. The patient responded significantly and was maintained on oral NSAIDs and 200 mg per day of Carbamazepine.

Ten days from surgery, he underwent Ilizarov frame application at our specialized centre with an attempt to lengthen the stump for optimum rehabilitation. Distraction started on seventh day at a rate of 0.25mm four times a day. Five days from commencement of distraction, the patient developed aggravation of PLP. We reduced the dose of distraction to 0.5mm per day and the patient was maintained on oral carbamazepine 200 mg/day, Inj Ketorolac 60 mg/day and Inj Tramadol 100 mg/day. With this treatment Visual Analog Scale (VAS) was 5 and patient refused further lengthening and distraction was stopped after nine days.

On the tenth day, he was referred to a psychiatrist. He reported a VAS of 7 and evaluation revealed painful post-operative scar, painful spasm of quadriceps, tensor fascia lata, gluteus medius and adductor brevis, soreness of urogenital diaphragm, tenderness over right sacroiliac joint and limited motion of L4/5 and L5/S1 spinal segments. On the same day he underwent

**Corresponding Author:** Koushik Narayan Subramanyam, Department of Orthopaedics, Sri Sathya Sai Institute of Higher Medical Sciences, Prashanthigram, Puttaparthi, Andhra Pradesh, India  
 Email: drkoushik@hotmail.com



THE ONLINE VERSION OF THIS ARTICLE  
 ABJS.MUMS.AC.IR

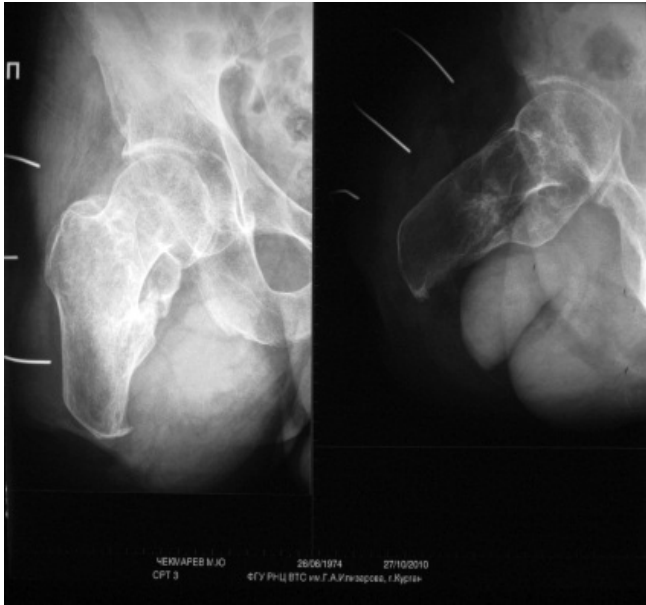

Figure 1. Radiograph of proximal femur stump before lengthening.

manipulative therapy consisting of myofascial release of the painful scar, quadriceps, tensor fascia lata, gluteus medius, adductor brevis and urogenital diaphragm and mobilization of L4/5 and L5/S1 spinal segments. Immediately after the session, VAS dropped to 1 and all medications were stopped.

Distraction restarted on the next day at a rate of 0.25 mm thrice daily. PLP reappeared to the extent of VAS 3,

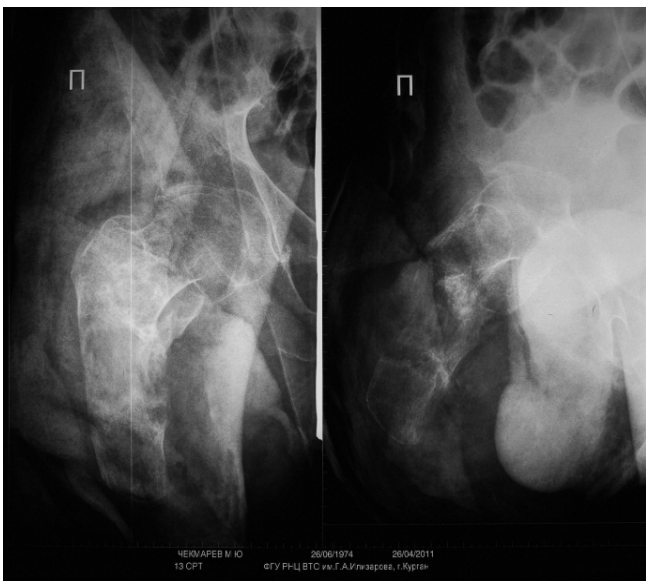


Figure 3. Radiograph of proximal femur stump well consolidated after 5cm lengthening.

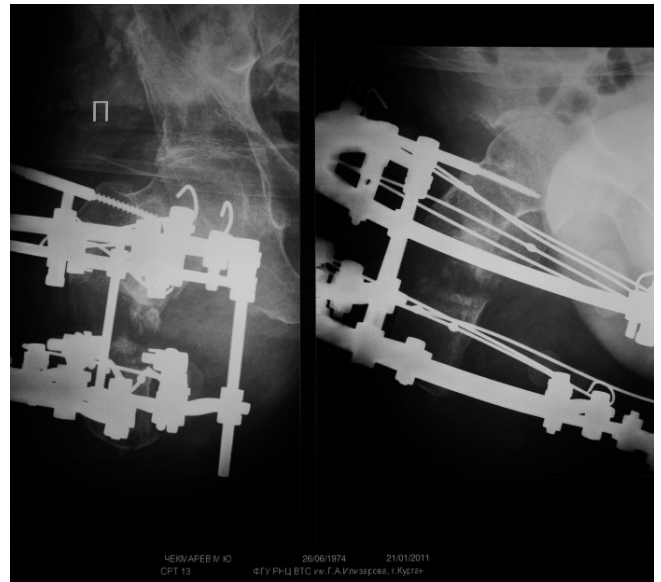


Figure 2. Radiograph of proximal femur stump after gradual distraction with fixator in situ.

but was only till the knee and could be well controlled by injection of 60 mg of Ketorolac as per need basis. Five more sessions of the same manipulative therapy was given at a frequency of one per week. At the end of distraction VAS was at 1 and was maintained at the same level till removal of fixator [Figure 2]. At 15 weeks follow up from removal of fixator patient was completely free of pain without any analgesics. Throughout the period, the patient was on regular stump mobilisation and strengthening exercises as usual. The period of distraction was 62 days after which the Ilizarov fixator was left in place for 104 days for maturation of regenerate. The stump achieved the planned lengthening of 5cm, i.e., by more than 70% of its original length and was rehabilitated well with prosthesis [Figure 3].

### Discussion

Up to 75% of amputees present with PLP (5). It usually begins in the first few days after amputation, and in most cases becomes chronic, with a high variability in terms of frequency, intensity and quality of pain sensation (6). The presence of preoperative limb pain and associated depressive symptoms directly correlates with its incidence, persistence and intensity of PLP (7).

To our knowledge this is the first report of aggravation of PLP in stump lengthening. This also alerts the possibility of appearance of PLP in stump lengthening in a patient without PLP and hence vigilance is needed. Extreme caution must be exercised in stump lengthening of patients with history of PLP. The delay of lengthening after amputation is likely to reduce the incidence or intensity of PLP in such cases. Associated

factors like pre-operative pain and depressive symptoms must be taken into consideration. Even if PLP occurs during stump lengthening, it responds to conventional treatment modalities. However treatment of PLP in such cases must be aggressive to prevent chronic pain.

Informed consent was obtained from the patient included in the study.

The authors report no conflict of interest concerning the materials or methods used in this study or the findings specified in this paper.

All procedures followed were in accordance with the ethical standards of the responsible committee on human experimentation (institutional and national) and with the Helsinki Declaration of 1975, as revised in 2008.

All authors have contributed to review of the case, collection of relevant literature and preparation of the

manuscript.

Konstantin Igorevich Novikov PhD  
Sergey V Kolesnikov MD  
Oleg K Chegurov PhD  
Elina S Kolesnikova MD  
T&O Department, Russian Ilizarov Scientific Centre for Restorative Traumatology and Orthopaedics, M.Ulianova, Kurgan, Russia

Koushik Narayan Subramanyam MS MRCSEd  
Abhishek V Mundargi DNB  
Department of Orthopaedics, Sri Sathya Sai Institute of Higher Medical Sciences, Prashanthigram, Puttaparthi, Andhra Pradesh, India

## References

1. Brown CA, Lido C. Reflexology treatment for patients with lower limb amputations and phantom limb pain-an exploratory pilot study. *Complement Ther Clin Pract.* 2008; 14(2):124-31.
2. Eldrige JC, Armstrong PF, Krajbich JI. Amputation stump lengthening with the Ilizarov technique. A case report. *Clin Orthop Relat Res.* 1990; 256:76-9.
3. Horesh Z, Levy M, Stein H. Lengthening of an above knee amputation stump with the Ilizarov technique-a case report. *Acta Orthop Scand.* 1998; 69(3):326-8.
4. Mertens P, Lammens J. Short amputation stump lengthening with Ilizarov method: risks versus benefits. *Acta Orthop Belg.* 2001; 67(3):274-8.
5. Ehde DM, Czerniecki JM, Smith DG, Campbell KM, Edwards WT, Jensen MP, et al. Chronic phantom sensations, phantom pain, residual limb pain, and other regional pain after lower limb amputation. *Arch Phys Med Rehabil.* 2000; 81(8):1039-44.
6. Lenggenhager B, Arnold CA, Giummarra MJ. Phantom limbs: pain, embodiment, and scientific advances in integrative therapies. *Wiley Interdiscip Rev Cogn Sci.* 2014; 5(2):221-31.
7. Dijkstra PU, Geertzen JH, Stewart R, van der Schans CP. Phantom pain and risk factors: a multivariate analysis. *J Pain Symptom Manage.* 2002; 24(6):578-85.