

TECHNICAL NOTE

Modified Internal Fixation Technique for Acromioclavicular (AC) joint dislocation: The “Hidden Knot Technique”

Hamidreza Aslani, MD; Fateme Mirzaee, MSc; Zohreh Zafarani, MD; Shahin Salehi, MD

*Research performed at Knee and Sport Medicine Research Center, Milad Hospital, Tehran, Iran**Received: 14 February 2017**Accepted: 29 November 2017***Abstract**

Acromioclavicular (AC) joint injuries are common and often seen in contact athletes, resulting from a fall on the shoulder tip with adducted arm. This joint is stabilized by both static and dynamic structures including the coracoclavicular (CC) ligament. Most reconstruction techniques focus on CC ligament augmentation as the primary stabilizer of the AC joint. The best surgical technique for some AC joint dislocations is still controversial. In this study, we explained a modification of the CC ligament reconstruction technique described by Wellmann. The method is based on minimally invasive CC ligament augmentation with a flip button/polydioxanone (PDS) repair, typically used for extracortical ACL graft fixation. Patients commonly complain that heavy sutures under the skin in subcutaneous tissue irritate the skin and sometimes require reoperation for suture removal. We present an augmentation technique that resolves this issue by changing the suture knot location to the sub-clavicular position.

Level of evidence: II**Keywords:** Acromioclavicular joint dislocation, Coracoclavicular ligament reconstruction, Internal fixation, Shoulder injury, Shoulder surgery**Introduction**

Separation of the acromioclavicular (AC) joint is usually a result of direct trauma to the shoulder area. It mostly happens when a force is applied to the acromion such as fall on the lateral aspect of the shoulder, with an adducted arm (1). This lesion accounts for 12% of all traumatic shoulder girdle injuries and occurs five times more frequently in men (2). Separation of the AC joint is a common injury among athletes involved in contact sports and victims of motor vehicle accidents, particularly motorcycle crashes. The acromioclavicular joint (ACJ) is a true synovial joint stabilized by coracoclavicular (CC) and acromioclavicular ligaments. Both AC and CC ligaments are necessary anatomic structures to stabilize the ACJ. Rockwood classified this injury into grades (I–VI) depending on the severity of the damage and the degree of displacement (3). Grade I–II injuries are treated nonoperatively. The treatment

of grade III injuries is controversial with some authors recommending an operative approach in cases of manual workers and active patients as well as high-level athletes (4). Surgical treatment is recommended for grade IV–VI injuries. There are several surgical methods for treating AC dislocations that focus on CC ligament reconstruction. The techniques that have been described in the literature include AC joint pinning, CC loop cerclage, hook plates, use of a CC screw, CC ligament repair, coracoid transfer, distal clavicle excision, and ligament or muscle transfer (5). While the clinical superiority of these procedures remains unclear, various complications have been reported such as pain, diminished function of the upper extremity, implant migration or breakage, recurrent injury and need for implant removal (6, 7).

It should be emphasized that all aforementioned surgical options are invasive and lead to some postoperative

Corresponding Author: Hamidreza Aslani, Shahid Beheshti University of Medical Sciences, Knee and Sport Medicine Research Center, Tehran, Iran
Email: hraslani1342@gmail.com



THE ONLINE VERSION OF THIS ARTICLE
ABJS.MUMS.AC.IR

morbidities such as glenohumeral lesions, pain, graft failure, and decreased extremity function (8, 9). The minimally invasive augmentation technique is another method of AC joint fixation which has been evaluated by Wellman et al. (10). In this method, the two flip buttons which are routinely used for anterior cruciate ligament (ACL) graft fixation are applied for connecting a double polydioxanone (PDS) loop to the clavicle and coracoids (11). The technique is minimally invasive and can be comparable with other methods and may have biomechanical advantages (12). After observing the patients who had undergone AC joint fixation with this technique and complained of a painful suture knot located directly under the skin, we modified the original augmentation technique with changing the suture knot location to the sub clavicular position.

Technical note

Twenty-four patients with type III-V Rockwood AC joint separation were operated using the modified CC ligament reconstruction technique (Part of this technique has been re-written from the original surgical technique (10)).

The patient was placed in the beach-chair position, and the entire upper extremity was draped in a manner to permit full and unrestricted arm positioning during the procedure. An oblique 3cm skin incision, starting at the posterior edge of the lateral clavicle was made toward the coracoid tip. The torn fascia of the deltoid muscle was further opened along its fiber course, and the superior aspect of the distal clavicle and the AC joint line were exposed by blunt subfascial dissection. The clavicular insertions of the trapezoid and deltoid ligaments were palpated at the anteroinferior surface of the clavicle, and the center point between them on the upper clavicular surface was marked with a curette (10).

If palpation of the ligament stumps was impossible,

the conoid tubercle served as the alternative orientation mark. According to the individual shoulder proportions, the center of the CC ligament attachment is located approximately 30 mm medial to the AC joint line. Blunt preparation is further performed toward the coracoid process until the base can be touched. The base of the coracoid must be identified for placement of a C-shaped drill guide. The drill guide is introduced into the medial coracoid aspect, whereas the lateral aspect should not be approached, leaving the coracoacromial ligament intact. The drill guide is slightly moved under the coracoid to control the strictly proximal position at the coracoid base. By use of the C-shaped drill guide, a K-wire is placed centrally in the coracoid base and overdrilled with a 4.5-mm drill bit. A suture is intertwined between 2 flip buttons (Fliptack; Karl Storz), normally used for extracortical ACL graft fixation. For this connection, the Ethibond excel No 1 (Ethicon) is used via the flip buttons through their internal, but, in our technique, the two ends of the suture will be between the two endobuttons [Figure 1].

The distal flip button is then inserted into a custom-made button pusher, guided through the 4.5-mm coracoid drill hole in an upstanding position, and placed under the coracoid base [Figure 2]. Afterwards, the button is flipped into a horizontal position; then, an anatomically placed clavicular bone tunnel is drilled into the preassigned central zone of the trapezoid and conoid ligament insertion. From the superior view, this bone tunnel is placed slightly anterior to the long axis of the clavicle. The sharp cortical edges of the drill hole are smoothed with a curette. Subsequently, a 45 degree SutureLasso™ (Arthrex) is guided through the clavicular bone.

Then the clavicular flip button is retrieved through the clavicular drill hole after it is fed into the SutureLasso™. The supraclavicular flip button is advanced onto the upper clavicle surface by pulling the free ends of the lateral hole suture. By use of an anatomic offset

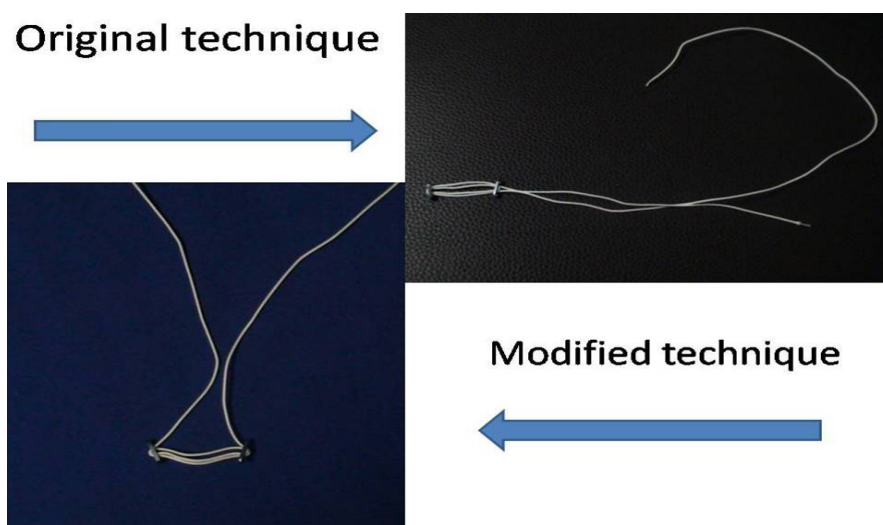


Figure 1. Comparison between the original and modified techniques.

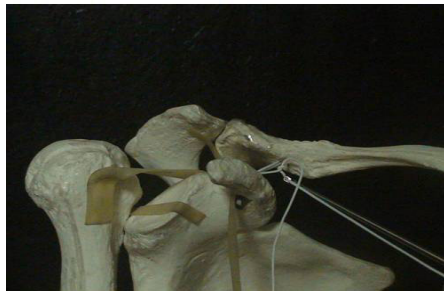Original technique**Modified technique**

Figure 2. Comparison between tying of original and modified techniques.

repositioning instrument, the clavicle is reduced in the AC joint afterward. Finally, the Ethibond loop is tied by arthroscopic knot pusher and not sliding square knots by the surgeon. If feasible, the torn AC ligaments are approximated by use of a No. 2 PDS suture. The deltoid fascia and subcutaneous tissue are carefully repaired. Skin closure is performed with a No. 4 Monocryl stitch (Ethicon, Somerville, NJ) via an intracutaneous suture technique. With regard to the postoperative rehabilitation method, the upper extremity is immobilized for 4 weeks in a sling. Afterwards, free motion of the right shoulder will be started.

Discussion

Stability and mobility of the AC joint depends on the integrity of the AC ligaments and the capsule as well as the CC ligaments and the trapezius and deltoid muscles. The CC ligament is the prime ligament of the AC joint (13). Therefore, anatomic reconstruction of this ligament may improve AC joint stability and joint kinematics.

The best surgical technique for some AC joint dislocations is still controversial (1). In this study, we described a modification of the CC ligament reconstruction technique described by Wellmann (10). The method is based on minimally invasive CC ligament augmentation with a flip button/polydioxanone (PDS) repair, typically used for extracortical ACL graft fixation. The important points of this procedure include the anatomic (thus no tendency towards anterior subluxation); secure (there are special aiming guide for drilling through the coracoid process to protect neurovascular structures and the thorax); and stable placement of a double PDS cerclage under the coracoid base transferring a flip button through coracoid bone tunnel. Also, unlike some methods, no implant removal (hook plate) is necessary (14, 15).

Nevertheless, one of the most common postoperative complaints of the patients who have been operated

by this method is the irritating heavy sutures in subcutaneous tissue under the skin that sometimes necessitates stitch removal. Therefore, we modified the original augmentation technique as we hypothesized that changing the suture knot location to the sub clavicular position may have no adverse effects on the surgery outcome, but, can prevent the annoying sensation of the painful subdermal suture knot.

Clinical experience has shown that CC augmentation techniques using suture cord (PDS) is easy to perform and has a comparable invasiveness to recently presented arthroscopic techniques (10, 16).

In conclusion, the modified CC ligament reconstruction technique; the "Hidden Knot Technique", in AC joint separation can provide satisfactory therapeutic results and avoid postoperative complaints of the patients about the irritating heavy sutures in subcutaneous tissue under the skin.

Hamidreza Aslani MD

Zohreh Zafarani MD

Knee and Sport Medicine Research Center, Milad hospital, Tehran, Iran

Fateme Mirzaee MSc

University of Social Welfare and Rehabilitation Sciences

Knee and Sport Medicine Research Center, Milad hospital, Tehran, Iran

Shahin Salehi MD

Department of Sports Medicine, Shahid Beheshti

University of Medical Sciences, Tehran, Iran

References

1. Abat F, Sarasquete J, Natera LG, Calvo A, Perez-Espana M, Zurita N, et al. Biomechanical analysis of acromioclavicular joint dislocation repair using coracoclavicular suspension devices in two different configurations. *J Orthop Traumatol*. 2015; 16(3):215-9.
2. Balog TP, Min KS, Rumley JC, Wilson DJ, Arrington ED. Arthroscopic anatomic coracoclavicular ligament repair using a 6-strand polyester suture tape and cortical button construct. *Arthrosc Tech*. 2015; 4(6):e757-61.
3. Rockwood CA, Williams GR, Young D. Disorders of the acromioclavicular joint. Philadelphia: The Saunders; 1998.
4. Beris A, Lykissas M, Kostas-Agnantis I, Vekris M, Mitsionis G, Korompilias A. Management of acute acromioclavicular joint dislocation with a double-button fixation system. *Injury*. 2013; 44(3):288-92.
5. Wang Y, Zhang J. Acromioclavicular joint reconstruction by coracoid process transfer augmented with hook plate. *Injury*. 2014; 45(6):949-54.
6. Rosslenbroich SB, Schliemann B, Schneider KN, Metzlauff SL, Koesters CA, Weimann A, et al. Minimally invasive coracoclavicular ligament reconstruction with a flip-button technique (MINAR): clinical and radiological midterm results. *Am J Sports Med*. 2015; 43(7):1751-7.
7. Sandmann GH, Martetschlager F, Mey L, Kraus TM, Buchholz A, Ahrens P, et al. Reconstruction of displaced acromioclavicular joint dislocations using a triple suture-cerclage: description of a safe and efficient surgical technique. *Patient Saf Surg*. 2012; 6(1):25.
8. Beitzel K, Obopilwe E, Chowaniec DM, Niver GE, Nowak MD, Hanypsiak BT, et al. Biomechanical comparison of arthroscopic repairs for acromioclavicular joint instability: suture button systems without biological augmentation. *Am J Sports Med*. 2011; 39(10):2218-25.
9. Shao RY, Zhang YC, Lou CJ, Shi GC, Yu JF, Luo C, et al. Coracoclavicular ligament reconstruction using autologous double-strand palmaris longus tendon and artificial ligament for the treatment of acromioclavicular joint dislocation. *Zhongguo Gu Shang*. 2011; 24(3):202-4.
10. Wellmann M, Zantop T, Petersen W. Minimally invasive coracoclavicular ligament augmentation with a flip button/polydioxanone repair for treatment of total acromioclavicular joint dislocation. *Arthroscopy*. 2007; 23(10):1132.e1-5.
11. Karas V, Barker J, Strauss E, McGill K, Provencher MT, Bach BR, et al. Can you achieve anatomic femoral tunnel placement with transtibial anterior cruciate ligament reconstruction using smaller tunnel sizes? *Arthroscopy*. 2011; 27(10):e195-6.
12. Wellmann M, Zantop T, Weimann A, Raschke MJ, Petersen W. Biomechanical evaluation of minimally invasive repairs for complete acromioclavicular joint dislocation. *Am J Sports Med*. 2007; 35(6):955-61.
13. Yoo YS, Seo YJ, Noh KC, Patro BP, Kim DY. Arthroscopically assisted anatomical coracoclavicular ligament reconstruction using tendon graft. *Int Orthop*. 2011; 35(7):1025-30.
14. Kumar N, Sharma V. Hook plate fixation for acute acromioclavicular dislocations without coracoclavicular ligament reconstruction: a functional outcome study in military personnel. *Strategies Trauma Limb Reconstr*. 2015; 10(2):79-85.
15. Li Q, Hsueh PL, Chen YF. Coracoclavicular ligament reconstruction: a systematic review and a biomechanical study of a triple endobutton technique. *Medicine*. 2014; 93(28):e193.
16. Wellmann M, Kempka JP, Schanz S, Zantop T, Waizy H, Raschke MJ, et al. Coracoclavicular ligament reconstruction: biomechanical comparison of tendon graft repairs to a synthetic double bundle augmentation. *Knee Surg Sports Traumatol Arthrosc*. 2009; 17(5):521-8.