

CASE REPORT

Massive Emphysema and Pneumothorax Following Shoulder Arthroscopy under General Anaesthesia: A Case Report

Mohammad j. shariyate, MD; Amir R. Kachooei, MD; Mohammad H. Ebrahimzadeh, MD

Research performed at Orthopedic Research Center, Mashhad University of Medical Sciences, Mashhad, Iran

Received: 22 March 2017

Accepted: 26 October 2017

Abstract

The patient was a 61-year-old female with massive rotator cuff tear who had no history of smoking, COPD, asthma, or other pulmonary diseases. Four hours following shoulder arthroscopy, the patient developed progressive dyspnea, which was diagnosed as pneumothorax with subcutaneous emphysema extending to the neck and face. Chest tube was inserted promptly. The patient was discharged with a good condition after 7 days. Follow up of the patient for the next 3 months was uneventful.

Keywords: Emphysema, General anesthesia, Pneumothorax, Shoulder arthroscopy

Introduction

Arthroscopy has become a preferred diagnostic and treatment option for shoulder conditions (1, 3). Although pneumothorax during shoulder arthroscopy is a rare complication, its presence might be life threatening, which requires prompt diagnosis and treatment.

We report a patient in whom ipsilateral pneumothorax was developed following arthroscopic rotator cuff repair.

Case presentation

A 61-years-old woman presented with a one-year history of inability to move her right arm due to a massive rotator cuff tear. Patient's body mass index was 24 kg/m², and she did not report any history of smoking, chronic obstructive pulmonary disease, asthma, or other pulmonary diseases. Arthroscopic rotator cuff repair was planned. In the past medical history, the patient had three prior surgeries for herniated lumbar disc, colorectal mass, and hysterectomy, the last of which was 9 years ago under general anesthesia (GA).

The patient underwent right shoulder arthroscopy using posterior, lateral, and anterior portals in a

beach chair position under GA. Regional anesthesia was not attempted at all. Retracted muscles including subscapularis were released aggressively by using an arthroscopic shaver, and repaired to their respective insertions using suture anchors.

No hypotension or drop in oxygen saturation was observed during surgery, and the patient was delivered to the recovery room with stable vital signs. Four hours later following the surgery, the patient developed progressive dyspnea. On physical examination, palpable emphysema was observed extending to the neck and face with diminished breath sounds over the right side of the chest [Figure 1; 2]. Chest X-ray and a high-resolution computed tomography revealed a right lung collapse [Figure 3]. Upon diagnosis of a massive right-sided pneumothorax within 8 hours of the index surgery, the patient was transferred to the operating room for placement of a chest tube. In the routine pre-op consultation with a cardiologist and an anesthesiologist, lung auscultation was clear, and echocardiogram and chest X-ray were reported unremarkable [Figure 4]. The patient was discharged from the hospital with a good condition seven days after surgery with no further

Corresponding Author: Mohammad H. Ebrahimzadeh, Orthopedic Research Center, Mashhad University of Medical Sciences, Mashhad, Iran
Email: EbrahimzadehMH@mums.ac.ir



THE ONLINE VERSION OF THIS ARTICLE
ABJS.MUMS.AC.IR

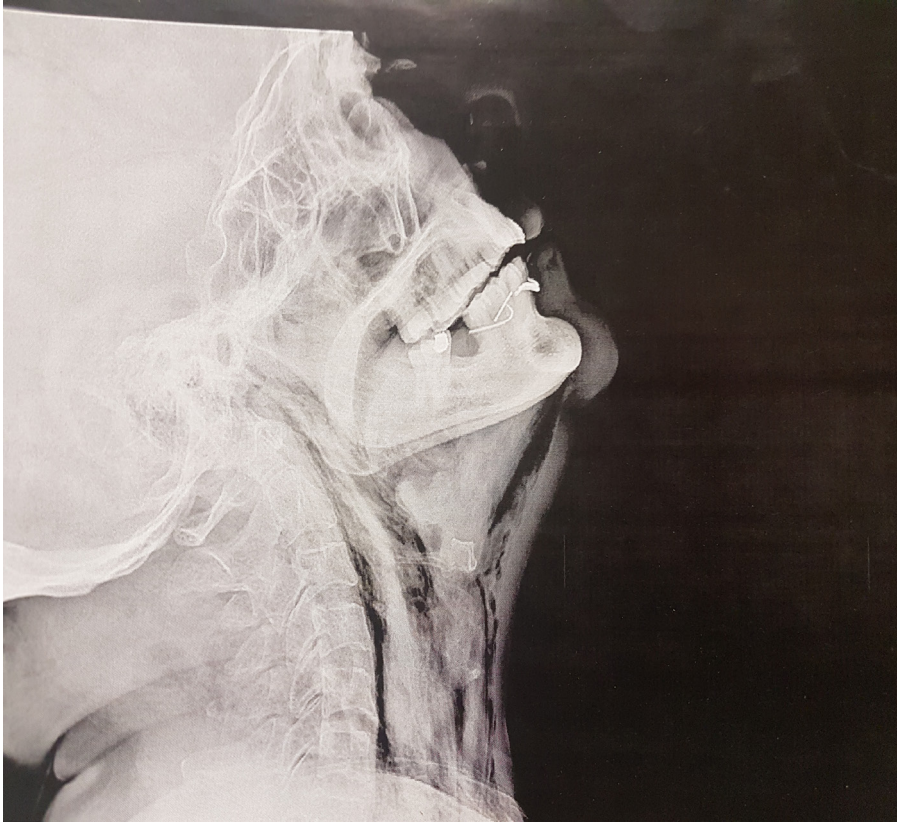

Figure 1. Significant subcutaneous facial and cervical emphysema.

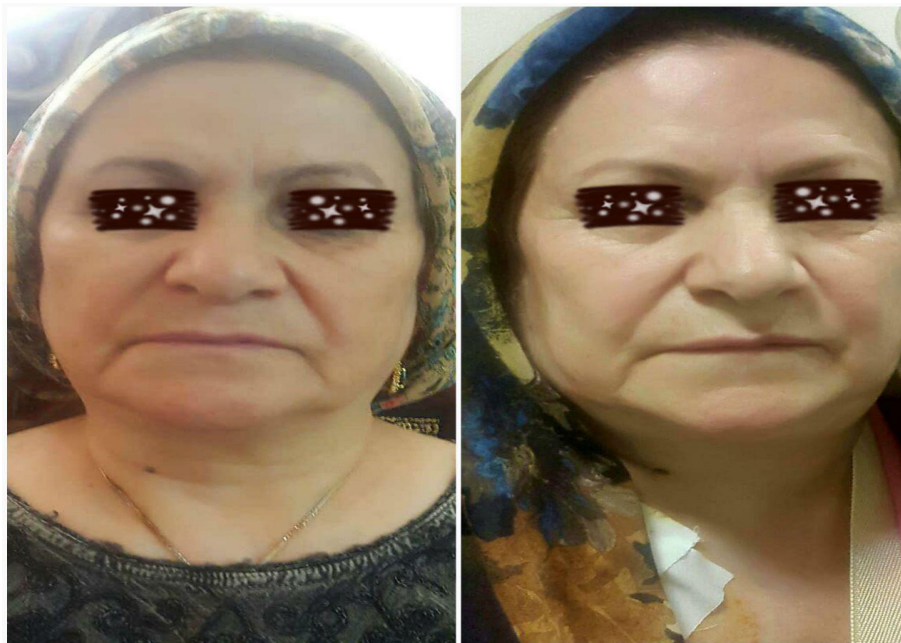

Figure 2. Significant clinical subcutaneous emphysema.

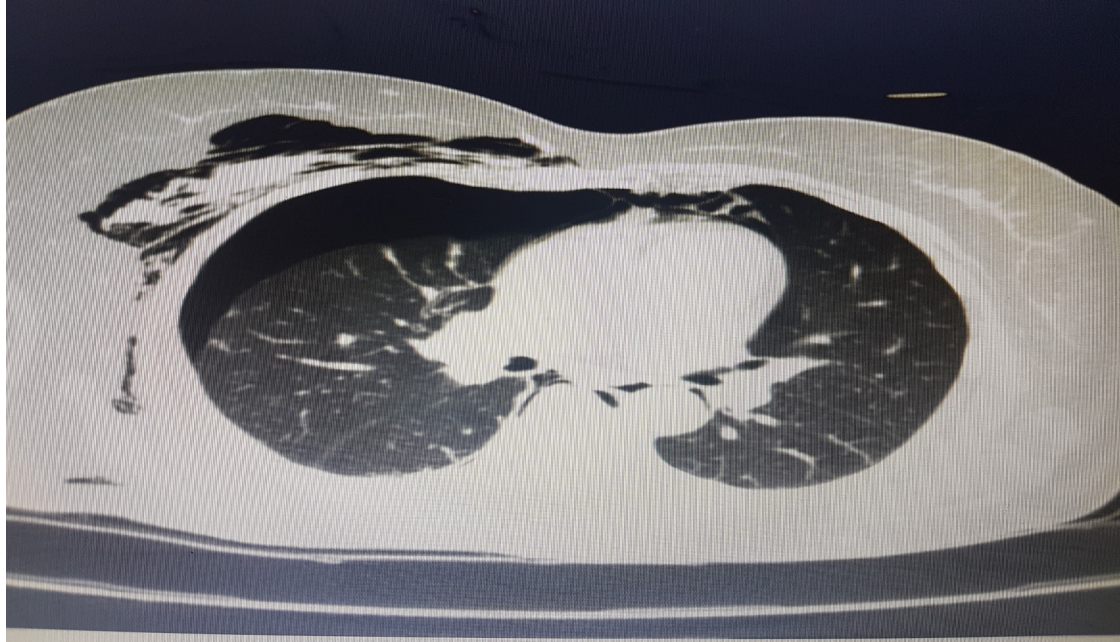


Figure 3. Right pneumothorax with evidence of massive subcutaneous emphysema and without any bullae and blebs.

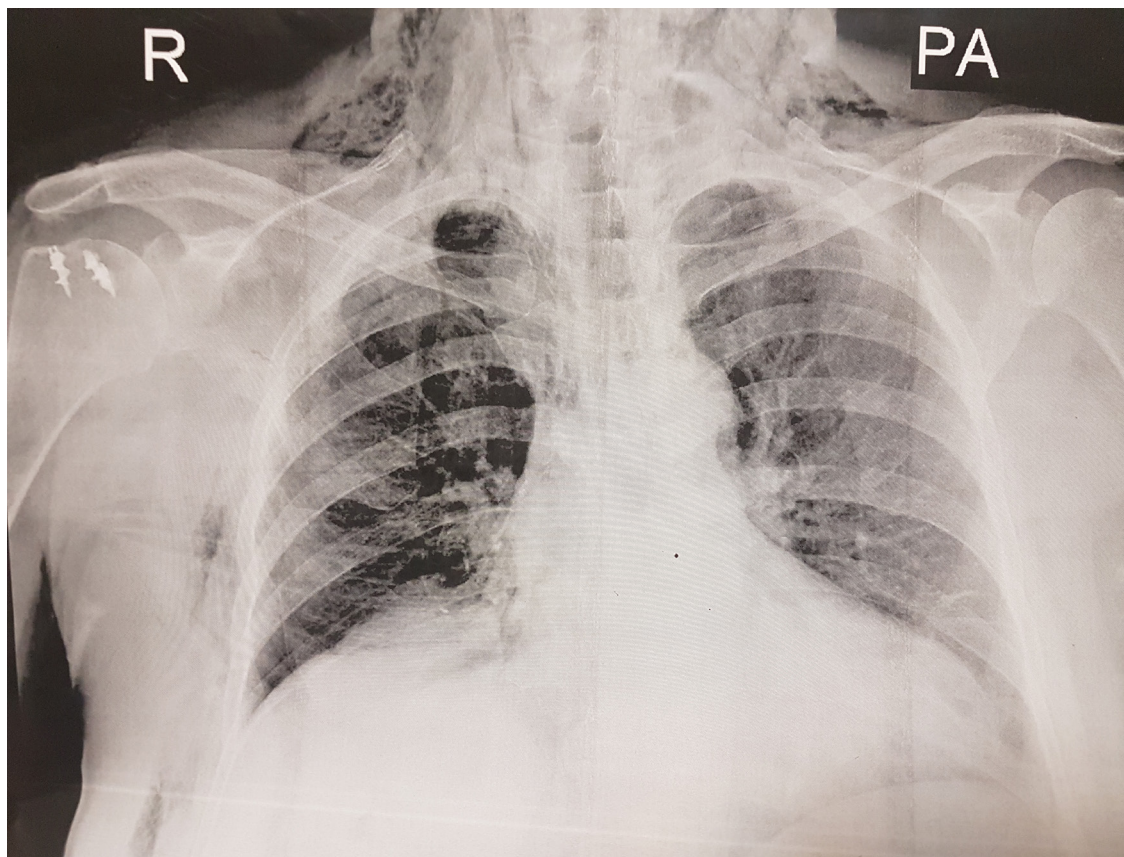


Figure 4. After chest tube placement.

intervention after removing the chest tube. The patient was followed up for 3 months, which was uneventful.

Discussion

In our patient, we hypothesized 3 reasons as the causative factor of pneumothorax.

A- Pneumothorax following shoulder arthroscopy

There are few reports regarding secondary pneumothorax following shoulder arthroscopy (4). Pneumothorax after shoulder arthroscopy is too rare that is not generally recognized as a potential complication. Lau et al. reported pneumothorax and subcutaneous emphysema in a patient following shoulder arthroscopy (5). They attributed the use of intra-articular shaving as the cause of pneumothorax. Cull and Dietzel, J.V. Ciullo reported four cases of pneumothorax following shoulder arthroscopy under GA (6). Calvisi et al. also reported pneumothorax in a patient undergoing shoulder arthroscopy under regional block (7). Furthermore, Lee et al. reported two cases with bilateral subcutaneous emphysema and tension pneumothorax during shoulder arthroscopy. Alssan et al. also reported a case of pneumothorax in a patient undergoing shoulder arthroscopy under combined general and regional anesthesia (8).

Bamps et al reported a case of pneumothorax 10 hours after shoulder arthroscopy, which was speculated to be due to iatrogenic rupture of parietal pleura (9).

B- Pneumothorax following general anesthesia

In general, there are few reports of pneumothorax caused by GA. Christine et al. reported a case of pneumothorax following GA, intubation, and maintenance with inhalation and oxygen in nitrous oxide. There are three probable causes in this regard including air way force, bronchus intubation, and patient risk factor such as smoking and lung disease (10).

Rastogi and wright reported a patient with pneumothorax during GA and ascribed it to the air way and trans-pulmonary force (11). They suggested that the trans-pulmonary pressure of 60 mm Hg can lead to

barotrauma. Recently, there have been reports regarding the incidence of pneumothorax following GA even with laryngeal mask airway (12). In general, the factors leading to barotrauma include difficult intubation, airway exchange catheter, and assisted oxygenation tools.

C- Patient factors

History of smoking, lung disease, and recent chest trauma can be the risk factors for pneumothorax (13). Additionally, the incidence of spontaneous pneumothorax has been reported following perioperative stress/trauma anesthesia.

We could not find a decisive contributing factor for our patient's pneumothorax. The patient was not a classic case of spontaneous pneumothorax. Two possible causes of pneumothorax in this patient could be barotrauma (caused by GA) and trauma during shoulder arthroscopy caused by shaver and diathermy and arthroscopic electrosurgery (cold ablation).

Out of these two, iatrogenic pneumothorax is more plausible because patient's hemodynamic was stable during surgery, whereas aggressive and deep use of shaver and coblator to release the retracted rotator cuff muscles could increase the risk of arthroscopic trauma. Prompt management of this condition is of importance.

Mohammad j. shariyate MD
Department of Orthopedics, Imam Khomeini Hospital,
Urmia University of Medical Sciences, Urmia, Iran

Amir R. Kachooei MD
Mohammad H. Ebrahimzadeh MD
Orthopedic Research Center, Department of Orthopedic
Surgery, Mashhad University of Medical Sciences, Ghaem
Hospital Medical School, Mashhad, Iran

References

1. Ebrahimzadeh MH, Moradi A, Pour MK, Moghadam MH, Kachooei AR. Clinical outcomes after arthroscopic release for recalcitrant frozen shoulder. Arch Bone Joint Surg. 2014; 2(3):220.
2. Kilinc AS, Ebrahimzadeh MH, Lafosse L. Subacromial internal spacer for rotator cuff tendon repair: "the balloon technique". Arthroscopy. 2009; 25(8):921-4.
3. Ebrahimzadeh MH, Biriandineiad A, Golhasani F, Moradi A, Vahedi E, Kachooei AR. Cross-cultural adaptation, validation, and reliability testing of the Shoulder Pain and Disability Index in the Persian population with shoulder problems. Int J Rehabil Res. 2015 ;38(1):84-7.
4. Lee HC, Dewan N, Crosby L. Subcutaneous emphysema, pneumomediastinum, and potentially life-threatening tension pneumothorax: pulmonary complications from arthroscopic shoulder decompression. Chest. 1992; 101(5):1265-7.
5. Lau KY. Pneumomediastinum caused by subcutaneous emphysema in the shoulder. a rare complication of

- arthroscopy. *Chest*. 1993; 103(2):1606-7.
6. Dietzel DP, Ciullo JV. Spontaneous pneumothorax after shoulder arthroscopy: a report of four cases. *Arthroscopy*. 1996; 12(1):99-102.
 7. Calvisi V, Lupparelli S, Rossetti S. Subcutaneous emphysema and pneumomediastinum following shoulder arthroscopy with brachial plexus block: a case report and review of the literature. *Arch Orthop Trauma Surg*. 2009; 129(3):349-52.
 8. Leander-Olsson O, Borglund-Hemph A, Jakobsson JG. Pneumothorax following shoulder arthroscopy under combined regional and general anaesthesia-A case report. *Int J Surg Case Rep*. 2016; 24:73-6.
 9. Bamps S, Renson D, Stefaan Nijs S. Pneumothorax after shoulder arthroscopy: a rare but life-threatening complication. *J Orthop Case Rep*. 2016; 6(4):3-5.
 10. Christian MS, Munson ES, Hamilton WK. Pneumothorax following induction of anesthesia. *JAMA*. 1969; 209(11):1710-1.
 11. Rastogi PN, Wright JE. Bilateral tension pneumothorax under anaesthesia. *Anaesthesia*. 1969; 24(2):249-52.
 12. Choy MC, Pescod D. Pneumothorax in association with spontaneous ventilation general anaesthesia--an unusual cause of hypoxaemia. *Anaesth Intensive Care*. 2007; 35(2):270-3.
 13. Vezzani A, Manca T, Benassi F, Santori G, Valentino M, Nicolini F, et al. Diagnostic value of chest ultrasound after cardiac surgery: a comparison with chest X-ray and auscultation. *J Cardiothorac Vasc Anesth*. 2014; 28(6):1527-32.