

CURRENT CONCEPTS REVIEW**Osteoporosis and the Management of Spinal Degenerative Disease (II)**

Félix Tomé-Bermejo, MD, PhD; Angel R. Piñera, MD; Luis Alvarez, MD, PhD

*Research performed at the Spine Department, Fundación Jiménez Díaz University Hospital, Madrid, Spain**Received: 20 November 2016**Accepted: 11 May 2017***Abstract**

Osteoporosis has become a major medical problem as the aged population of the world rapidly grows. Osteoporosis predisposes patients to fracture, progressive spinal deformities, and stenosis, and is subject to be a major concern before performing spine surgery, especially with bone fusions and instrumentation. Osteoporosis has often been considered a contraindication for spinal surgery, while in some instances patients have undergone limited and inadequate procedures in order to avoid concomitant instrumentation. As the population ages and the expectations of older patients increase, the demand for surgical treatment in older patients with osteoporosis and spinal degenerative diseases becomes progressively more important. Nowadays, advances in surgical and anesthetic technology make it possible to operate successfully on elderly patients who no longer accept disabling physical conditions. This article discusses the biomechanics of the osteoporotic spine, the diagnosis and management of osteoporotic patients with spinal conditions, as well as the novel treatments, recommendations, surgical indications, strategies and instrumentation in patients with osteoporosis who need spine operations.

Keywords: Degenerative scoliosis, Degenerative spondylolisthesis, Fracture, Instrumentation, Osteoporosis, Stenosis

Clinical relevance of the osteoporotic aging spine

Occurrence and development of osteoporosis is a painless process. The set of degenerative changes appearing in aging spines in symptomatic patients, are identical to those with degenerated spines in asymptomatic subjects (1). However, profound inactivity from a progressive and painful degeneration and destabilization of the spine coupled with the pain and inactivity from a symptomatic osteoporotic compression fracture can lead to a downward spiral of further bone loss and degeneration, more vertebral fractures, more pain and inactivity.

The presence of osteoporosis in a degenerated spine favors the occurrence of vertebral fractures and the development of deformity and stenosis. Pain and disability may be the clinical manifestation of the presence of an osteoporotic aging spine. Clinicians are responsible for the recognition, correlation and interconnection the presence of degenerative changes on the imaging studies with the clinical symptoms. It is admitted that a degenerated spine can be completely

asymptomatic and continue so. Imaging studies (X-ray, CT scan, magnetic resonance imaging [MRI]) and bone-scan can identify the presence of degenerated zygapophyseal joints and disc degeneration. However, imaging tests have a limited clinical correspondence, since many of these degenerative changes also appear in asymptomatic patients, especially with aging (2).

Zygapophysial joint osteoarthritis, degenerative changes in the discs, intervertebral space narrowing, and bony remodeling due to osteoporosis they are all degenerative changes associated with the aging of the spine (1). These degenerative changes induce to deformities in the vertebrae, modifications and alterations in the stress distribution and the normal alienation of the spine accountable for the occurrence of degenerative segmental instabilities and subluxations like spinal stenosis, degenerative spondylolisthesis, and scoliosis. Degenerative spondylolisthesis and scoliosis are generally asymptomatic, but they can associate or aggravate a preexisting symptomatic spinal stenosis (3).

Corresponding Author: Félix Tomé-Bermejo, Spine Department, Fundación Jiménez Díaz University Hospital, Madrid, Spain
Email: felix tome@hotmail.com



THE ONLINE VERSION OF THIS ARTICLE
ABJS.MUMS.AC.IR

As the population ages, fractures, stenosis, and deformities become more common. The pathogenesis of the occurrence and development of degenerative changes of the spine is uncertain. The hereditary factor along with the physical environment appears to be decisive. Physical exercise, a balanced diet and proper postural hygiene and ergonomic advices are the only means of prevention at our disposal today.

Degenerative lumbar spinal stenosis

Neural canal stenosis is the narrowing of the spinal canal with the intrusion of surrounding bone and soft tissue onto the neural structures. Stenosis in the elderly is the result of a combination of osteophyte formation from degenerated zygapophysial joints, ligamentum flavum hypertrophy, disc space narrowing, and circumferential bulging of disc osteophyte complex instigated by remodeling of the adjacent vertebral bodies due to osteoporosis. Stenosis of the spinal canal occurs when the diameter of the canal becomes too narrow for the thedural sac (4). Central and lateral stenosis commonly develop simultaneously and are the most frequent indication for surgical treatment in adults above the age of 65.

Neurogenic claudication is the classic presenting symptom of lumbar spinal stenosis. It refers to the presence of pain and numbness in the legs that gets worse when walking and is typically relieved by lumbar forward flexion or sitting down. Other accompanying symptoms are the presence of low back pain, and in severe cases motor impairment of the lower limbs and bladder and bowel dysfunction may appear.

The origin and pathogenesis of these symptoms is not entirely understood. Compression of nerve roots together with an ischemic environment due to the reduction or even interruption of the local blood flow by compression of blood vessels due to the narrowing of the neural canal may be the cause of the neurological symptoms. Pain and symptoms in the legs are typically relieved by sitting and forward flexion of the lumbar spine. This could occur due to the increase in the diameter of the neural canal by the stretching and flattening of the ligamentum flavum which occurs with lumbar flexion, thus relieving the compression on the neurological structures and the spinal blood supply (5-7).

Compression at more than one spinal level produces venous congestion, insufficient arterial blood supply and an ischemic environment of the neural elements. Compromised autonomic innervations of the legs may inhibit the appropriate vasodilation response to increased muscle use, responsible for lower limbs pain and numbness (7).

Imaging studies of the spine in patients with lumbar degenerative spinal stenosis provide details regarding the location and extent of stenosis; however, it is important to remember that the severity of stenosis noted on imaging studies often does not correlate with the severity of symptoms. Schizas et al. (8) have recently proposed a classification of spinal stenosis based on the morphology of the dural sac as observed on MR T2-weighted axial images of the lumbar spine. The classification is based on the cerebrospinal fluid (CSF)/rootlet ratio as observed in axial

T2 images and was formulated following observation of the diverse configurations according to which the rootlets were disposed within the dural sac on the MR. Description of the rating goes from Grade A (From A1 to A4): minor stenosis with CSF clearly visible inside the dural sac but with an inhomogeneous distribution; Grade B: (moderate stenosis) the rootlets occupy the entire dural sac, but they can still be individualized and some CSF is still evident; Grade C: (severe stenosis) no rootlets can be identifiable, the dural sac demonstrates a homogeneous gray signal with no CSF signal visible and epidural fat is present posteriorly; Grade D: (extreme stenosis) no identifiable rootlets, and there is no epidural fat posteriorly.

Natural history in patients with untreated lumbar spine stenosis is not completely understood because there is a lack of prospective randomized studies documenting the clinical course. However, previous studies demonstrate the superiority of the surgical treatment compared with the conservative in the treatment of symptomatic lumbar spine stenosis (9). Conservative management of lumbar spinal stenosis includes activity modification, physiotherapy, non-steroidal anti-inflammatory drugs, bracing, and epidural injections. Conservative treatment is usually useful in improving symptoms from neurogenic claudication; however, it is commonly recognized that surgery is indicated if conservative treatment fails (10).

Decompression is fundamental to the successful surgical treatment of a stenotic segment, and is accomplished by a thorough removal of all structures contributing to the neurologic compression (11). The type of decompression carried out will depend on the anatomic site of stenosis and the patient's symptoms. Extensive decompressive laminectomy together with medial facetectomy and foraminotomy is the standard procedure.

Limiting the decompression to the causative structures would prevent further impairment and postoperative instability. There is an emergent tendency toward less aggressive decompression, preserving anatomical structures and theoretically reducing the likelihood for postoperative iatrogenic instability (4). The interspinous process spacer offers patients with spinal stenosis a less invasive alternative to laminectomy (12). The success rate obtained in the elderly with these devices is similar to that generally reported for decompressive surgery. Kondrashov et al. compared the clinical outcome of interspinous spacer versus laminectomy in a group of 30 patients undergoing surgical treatment for lumbar spine stenosis (13). At the end of the 4 years of follow-up, only 33% of the Laminectomy group reported satisfactory results, compared with 78% of the Interspinous group. However, the preoperative average Oswestry Disability Index (ODI) scores in the interspinous group were 25% greater (45 Vs. 36).

Interspinous process devices are a quite new technology, and the indications and design are expected to improve. Deyo et al. published a retrospective analysis comparing the complications, costs, and revision surgery rates of interspinous spacers and laminectomy or fusion surgery in 99,084 patients (14). They found a reoperation rate for spacer (16.8% at 2 years) that was significantly higher than reoperation rates reported for patients having decompression surgery (7.8% at 2 years). They suggested

Table 1. Summary of reports of surgical treatment for degenerative lumbar disease using pedicle screws augmented with PMMA

Author	Year of publication	Number of patients/ Mean age	Mean follow-up months	Diagnosis	Augmentation technique	Cement leakage rate	Complications	Reinterventions
Singh et al.	2005	9/76.1 years	11.2 months	Osteoporotic fracture and spondylolisthesis 9	Through biopsy needle	22.2%	1 Screw migration 1 Nonunion fracture 4 AVCFx	1 cement extravasation removed-laminectomy
Frankel et al.	2007	23/	21 months	Osteoporotic fracture 8 Spondylolisthesis 5 Spinal malignancy 6 Revision surgery 4	Through biopsy needle	39.1%	1 asymptomatic PMMA pulmonary embolus 2 Superficial wound infection	None
Chang et al.	2008	41/75.1 years	22.3 months	Osteoporotic fracture 32 Spinal stenosis 5 Spinal malignancy 4	Through biopsy needle	26.2%	1 Stroke 6th day postop. 2 Deep wound infection 1 AVCFx	None
Kim et al.	2008	20/60.5 years	15 months	Osteoporotic fracture 20	Through biopsy needle	None	None	1 Seroma. Debridement and secondary suture
Aydogan et al.	2009	36/66 years	37 months	Osteoporotic fracture 6 Spinal stenosis 26 Spondylolisthesis 3 Spinal malignancy 1	Through biopsy needle	None	4 Superficial wound infection	None
Moon et al.	2009	37/68.7 years	33.3 months	Degenerat. spondylolisthesis 6 Spondylolitt. spondylolisthesis 5 Spondylotic stenosis 26	Fenestrated pedicle screws	5.4%	1 Pedicle screw loosening	2 Dural tear repair
Hu et al.	2011	Group A: 25/73 years Group B: 23/74.6 years	Group A: 16.5 m Group B: 15.9 m	Osteoporotic fracture 31 Spondylolisthesis + stenosis 11 Spinal malignancy 6	Group A: TBN Group B: FPS	Group A: 18.3% Group B: 13.6%	Group B: 1 post-operative sciatica	None
Amendola et al.	2011	21/67.2 years	36.4 months	Osteoporotic fracture 4 Degenerative disease 2 Spinal malignancy 10 Revision surgery 5	Fenestrated pedicle screws	23.8%	1 nerve root palsy 2 Superficial wound infection 1 DVT 7th day postop. 1 Cauda equina syndrome	1 PVCF
Xie et al.	2011	14/63.14 years	45.6 months	Degenerative scoliosis	Through biopsy needle	14.3%	1 Pneumonia	None
Piñera et al.	2011	23/77 years	32 months	Spinal stenosis 11 Degenerat. spondylolisthesis 12	Fenestrated pedicle screws	29.3%	2 Bronchospasm 4 Adjacent disc degeneration 2 Urinary infection	3 Debridement for delayed deep wound infection
Sawakami et al.	2012	17/73.8 years	33.6 months	Vertebral pseudarthrosis 17	Pedicle screws covered with 1.0 mL PMMA	None	2 Superficial wound infection 5 AVCFx	2 Fusion extension
Zapatowicz et al.	2012	17/69 years	14.9 months	Osteoporotic fracture 11 Spondylodiscitis 1 Degenerat. spondylolisthesis 4 Spinal malignancy 1	Through biopsy needle	45%	1 Pneumothorax 1 Intraoperative pedicle fracture	1 Delayed spondylodiscitis reinfection. Removal of loose screws
Lubansu et al.	2012	15/71.2 years	13.3 months	Osteoporotic fracture 4 Degenerat. spondylolisthesis 5 Spinal/foraminal stenosis 6	Percutaneous fenestrated pedicle screws	30%	1 Transient radiculitis due to screw misplacement 1 Superficial wound infection	None

TBN: Through biopsy needle; FPS: Fenestrated pedicle screws; AVCFx: Adjacent vertebral compression fracture; DVT: Deep venous thrombosis;

that interspinous implants might be a valid alternative for those patients with high preoperative morbidity. On the other hand, for patients of average surgical risk and longer life expectancy, the increased reoperation rates with interspinous devices might make the case for conventional decompression surgery.

The extent of surgical decompression to carry out on elderly osteoporotic patients complaining from

lumbar stenosis with instability must be determined by a combination of a variety of clinical factors (age, physiological status, or medical comorbidities) and anatomical findings. In the presence of preoperative instability (4 mm of translation or >10° of angular motion between adjacent endplates on lateral flexion and extension X-rays, spondylolisthesis, or scoliosis), or when laminectomy is accompanied by greater than

50% resection of both facets or complete facetectomy of one side, fusion is generally recommended (14-18). A literature review shows conflicting results regarding the outcome of lumbar spine decompression and fusion surgery for spinal stenosis in the elderly. Ragab et al. reported the results of 118 patients older than 70 years of age who underwent lumbar decompressive surgery (16). Among the 45 patients who had posterolateral fusion, only 3 had pedicle screw instrumentation. Of the 118 patients, 109 reported satisfaction with the treatment received, and found that in terms of morbidity, the results were comparable with those of a younger population.

Instrumented spinal fusion in the elderly has been problematic concerning the safety and efficacy of pedicle screws. Carreon et al. published a retrospective study with 98 patients above 65 years of age that underwent decompression and instrumented fusion (17). They reported at least one major complication in 21% of patients, and at least one minor complication in 70%. An older age and an increased number of levels instrumented were found to be risk factors for the occurrence of major complications. Cassinelly et al. studied 166 patients older than 65 years, including 18 patients older than 80, who were treated for stenosis with decompression and fusion with (n=75) or without instrumentation (n=91) (18). They reported a similar rate of minor complications in both groups (30%), no deaths, and only one complication attributable to the use of instrumentation. Advanced age, the presence of medical comorbidities, or the use of instrumentation did not increase the rate of major or minor complications.

However, in elderly patients, because of their poor bone quality, mechanical failures due to screw loosening represent a major concern. Chang et al. reported the results of a retrospective study including 41 patients with

osteoporosis that underwent spinal decompression and fusion with PMMA augmented pedicle screws (19). There was neither symptomatic cement leakage nor significant screw migration after 2 years of follow-up.

Degenerative lumbar spondylolisthesis

Degenerative spondylolisthesis is the forward displacement of one lumbar vertebra in relation to the caudal vertebra with an intact posterior arch. Slippage is more frequent in women, and most usually occurs at the L4-L5 level. Degenerative spondylolisthesis is considered to be the result of chronic segmental instability with disk degeneration. This process results in loss of ligamentous support due to ligamentous laxity with compensatory hypertrophy of the facet joints and in thickening of the ligamentum flavum. It seldom surpasses 30% of vertebral width and it is normally asymptomatic, but may end up compromising the neural canal aggravating a preexisting spinal stenosis at the level of the slip, but also can cause back pain and radiculopathy (5, 10, 20).

Diagnosis can be established by obtaining lateral radiographs of the lumbar spine and lumbosacral junction with the patient standing, in order to assess the grade of displacement. CT scanning offers the best visualization of bony morphology. The MR will also determine the condition of the intervertebral disc at the level of the spondylolisthesis, and exclude canal or foraminal stenosis resulting in neural compression (21). Grading can be performed according to the Meyerding classification, with Grade I to IV referring to 25%, 50%, 75%, and 100% displacement, respectively (22) [Figure 1].

The majority of patients with degenerative spondylolisthesis will respond well to non-operative treatment, including NSAIDs, epidural injections, and lumbar flexibility and strengthening exercises. Patients

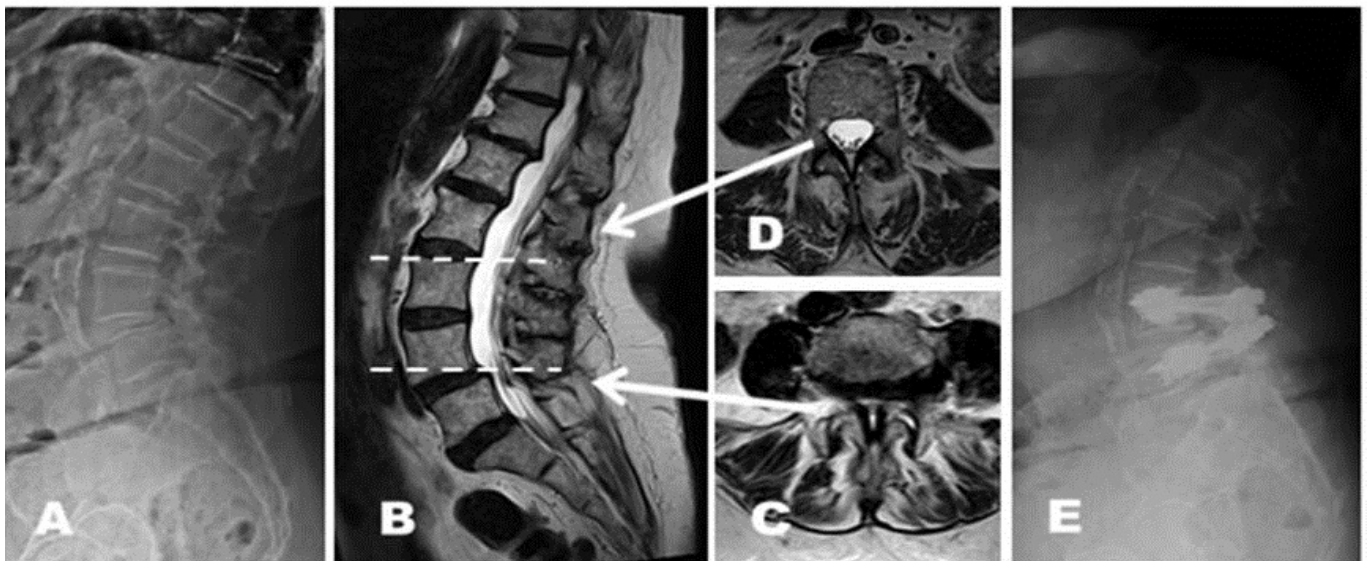


Figure 1. (A) lateral radiograph of a 78-year-old woman with neurogenic claudication. A Grade I L4 degenerative spondylolisthesis is present. Sagittal (B) and transverse MRI cuts demonstrate central neural and foraminal stenosis at L4-L5 (C) with normal canal width cranial to the stenosis (D). Lateral radiograph (E) obtained after laminectomy and L4-L5 instrumented arthrodesis with PMMA-augmented fenestrated pedicle screws.

with severe or persistent symptoms that interfere significantly with quality of life, or those with neurological deficit, may benefit from surgical decompression removing all bony and soft-tissue pressure on their neural elements.

There is no universal agreement regarding the optimal surgical approach for the treatment of degenerative spondylolisthesis: current controversies include the need for an additional fusion (either posterolateral or interbody fusion) with or without instrumentation, compared with decompression only. Lombardi et al. reported on three groups of patients undergoing surgical treatment for degenerative spondylolisthesis: Group I underwent extensive spinal decompression without additional spinal fusion; Group II underwent extensive spinal decompression and fusion; Group III underwent a more limited decompression with special attention to maintain the zygapophyseal joint facets and the pars interarticularis (23). Group I demonstrated the worst results, with only 33% of good/excellent results. Group II demonstrated the best results with 90% of good/excellent results. Group III did not show such positive results as Group II probably due to a suboptimal decompression of neurological structures in an attempt to preserve the zygapophyseal joint facets and the pars interarticularis.

Patients with a relatively stable listhesis could be safely treated by means of laminectomy without fusion. Presently, the consensus in the literature is that neural decompression with fusion demonstrates superior results to decompression alone in terms of better functional outcome due to the lessening of symptomatic instability.

When fusion is performed, many authors recommend including instrumentation to improve fusion rates, reduce postoperative activity limitations, and improve patient outcomes. Fischgrund et al. published a randomized prospective study comparing the results of decompressive lumbar laminectomy and posterolateral fusion with or without instrumentation, and were evaluated for a mean of 2 years after surgery (24). Transpedicular instrumentation significantly improved the fusion rates (82% of the instrumented cases versus 45% of the non-instrumented cases). However, clinical outcome assessed in terms of pain relief and increase in activity showed no improvement with the addition of instrumentation. These findings are similar to the findings in previous studies in which the radiographic fusion rate did not correlate with the clinical result. The question of which group of patients may substantially benefit from the addition of instrumentation remains unanswered.

Degenerative scoliosis

Scoliosis in adults can be primary degenerative scoliosis due to an asymmetric degenerative disc and facet joint osteoarthritis leading to a rotatory disorganization and destabilization of the spine; idiopathic adolescent scoliosis which progresses in adult life; a secondary adult curve to an oblique pelvis, leg length discrepancy, hip pathology, lumbosacral transitional abnormalities; or be caused by osteoporosis combined with vertebral fractures and asymmetric arthritic disease. Nevertheless, once the curve has significantly progressed, at times it is laborious

to know the exact the etiology of deformity (25, 26).

Degenerative adult scoliosis induces more unbalanced degeneration and loading, generating a downward spiral that enhances curve progression. The destruction of discs, facet joints, and joint capsules ends in a 3-dimensional rotational or translational dislodgment. The biological response to an unstable spine is the development of zygapophyseal joints and vertebral endplate osteophytes, and hypertrophy and calcification of the ligamentum flavum, all leading to an increasing narrowing of the lumbar canal, thus creating central and lateral lumbar spine stenosis (25, 27).

Patients suffering from adult degenerative scoliosis may present constant and non-specific back pain that usually appears only with the standing position, alleviating with the patient lying down flat or on their side, when the axial load is taken off the spine. Other important symptoms can be radicular pain, neurogenic claudication, and neurological deficit, including cauda equina syndrome with bladder and rectal sphincter involvement.

Severe rotation of the apical vertebra, a Cobb angle of 30° or more, lateral vertebra translation of more than 6 mm, or a position of L5 above the intercrestal line have all been discussed as features that are predictive of curve progression in patients with lumbar degenerative scoliosis (5, 28, 29). Osteoporosis is another major consideration in the management of adult degenerative scoliosis. Degenerative curves become progressive as a result of the asymmetric load on weakened vertebrae, which becomes progressively more wedged and deformed. With the progression of the deformity, the patient may become more symptomatic (26).

Non-surgical treatment options essentially reside in muscle relaxants, anti-inflammatory drugs, physiotherapy and light physical exercise, eluding manipulations and vigorous activities that may increase the symptoms. Epidural injections and selective zygapophysial joint blocks could help to alleviate the symptoms temporarily. Frequently a well-fitted brace to support the symptomatic lumbar spine area can be also helpful.

There are conflicting reports regarding the need for spinal surgery in this patient population. The indication for surgery and the type of surgery to carry out involve complex decision-making. Unquestionably, surgical treatment would only be indicated if conservative treatments fail. The indication for surgical treatment must be also conditioned by the patient's general health, the age of the patient, the coexistence of osteoporosis or other disorders affecting the patient's bone quality (metabolic and nutritional disorders), and also must be taken into account the expectations of the patient.

Available surgical options for adult degenerative scoliosis include anterior, posterior, and combined approaches. In cases with central or lateral stenosis and symptomatology referred mainly to the lower limbs and without one greater lumbar component, a simple and limited decompression can be performed. However, if significant sagittal plane imbalance or lateral listhesis of 5 mm or more is present, wide and multilevel decompression is needed. Decompression should be accompanied by instrumented stabilization to avoid the risk of postoperative curve progression (5, 28, 29) [Figure 2].

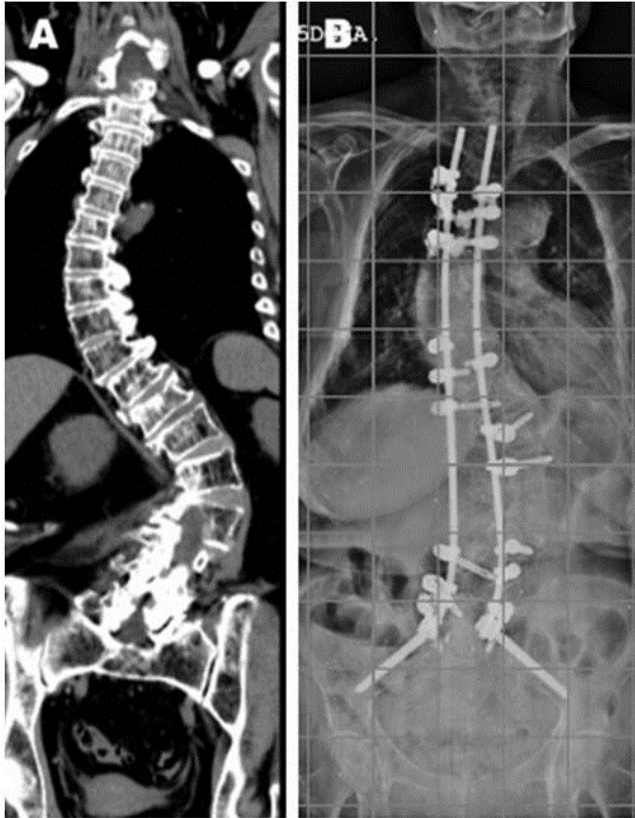

Figure 2. (A) coronal preoperative CT reconstruction of a 73-year-old woman who had severe degenerative adult scoliosis of the thoracolumbar spine. Postoperative posteroanterior (B) radiograph demonstrating correction obtained following a posterior-only approach with the use of a dual rod construct and PMMA-augmented fenestrated pedicle screws. Pelvic fixation was used because of the long thoracolumbar fusion and the need to fuse across the L5-S1 disc space.

In some complex but favorable cases, vertebral osteotomies or sequential segmental correction and instrumentation may be considered. In patients requiring extended constructs for correction and stabilization, special attention must be given to spinal balance and local shearing among implants, especially in the presence of osteoporosis. In such patients, significant loads can be placed on mechanically compromised points of fixation and can lead to implant or adjacent segment failure (5).

The outcomes of surgical treatment for adult spinal deformity have evolved considerably over the past years. Correction of the deformity may vary between 30 to 60% mostly depending on the nature of the deformity, the rigidity of the curve and the surgical procedure. In spite these limited clinical results, patient satisfaction is significantly favorable and can reach up to 90%. If coronal and sagittal balance is achieved and preserved with a firm fusion, the results are generally satisfactory. However, adult patients have an increased risk of

suffering surgical complications compared to young patients. Pain is rarely completely relieved, with residual pain in 5 to 15% of operated cases. Major complications include pseudarthrosis (5 to 27%), thromboembolism (1 to 20%), neurologic injury (1 to 5%) and infection (0.5 to 5%). Mortality remains low but not unimportant at less than 1% (5, 26, 30, 31).

Osteoporotic vertebral compression fractures. Degenerative sagittal imbalance

Both osteoporosis and the occurrence of fractures associated to the presence of bone fragility are the most frequent cause of morbidity and mortality in elderly patients. The lifetime risk of fracture due to bone fragility is 15-30% in men and 30-50% in women (32). In most western countries, low bone mass and the associated risk of fragility fracture is one of the major health concerns affecting already almost half of the elderly population (33).

Spinal fractures are the most frequent condition resulting from osteoporotic disease, and an indicator of excess morbidity and mortality. Patients with spinal fractures have a significant increase in morbidity and mortality in juxtaposition with a population with the same risk factors by sex and age. Direct consequences of vertebral fracture include chronic pain, decreased range of motion, slower gait, and compromised pulmonary function (34).

In subsequent years after the occurrence of one or more vertebral fractures, it has been reported a detriment in the functional health status from 17 to 44%, and an increase in the mortality incidence from 62 to 95 per 1000 person-years (35). Early detection and appropriate therapy for patients suffering vertebral fracture may decrease the deterioration in their physical function (36).

Vertebral compression fractures put patients with osteoporosis at much greater risk for developing local and global changes in spinal sagittal balance due to kyphotic deformities and spinal stenosis secondary to imbalance and degenerative changes (37). Furthermore, symptomatic neurocompression caused by osteoporotic fractures can occur, and range from the slow development of a subacute paralysis that gradually and slowly degenerates to complete paraplegia, to the less frequent occurrence of an acute paraplegia generally after an acute crush fracture (38). The first is usually associated with delayed vertebral collapse and progressive kyphotic deformity.

Percutaneous spinal cement augmentation procedures are minimally invasive techniques for the treatment of osteoporotic vertebral fractures that do not respond to conservative treatments. Bone cement used for vertebroplasty and balloon kyphoplasty immediately stabilizes the fractured vertebral body, enhancing loading capacity and relieving pain [Figure 3]. Many studies have reported satisfactory reductions in clinical symptoms caused by vertebral compression fracture on a short- and long-term basis after vertebroplasty and balloon kyphoplasty (39-42).

Hulme et al. conducted a systematic literature review

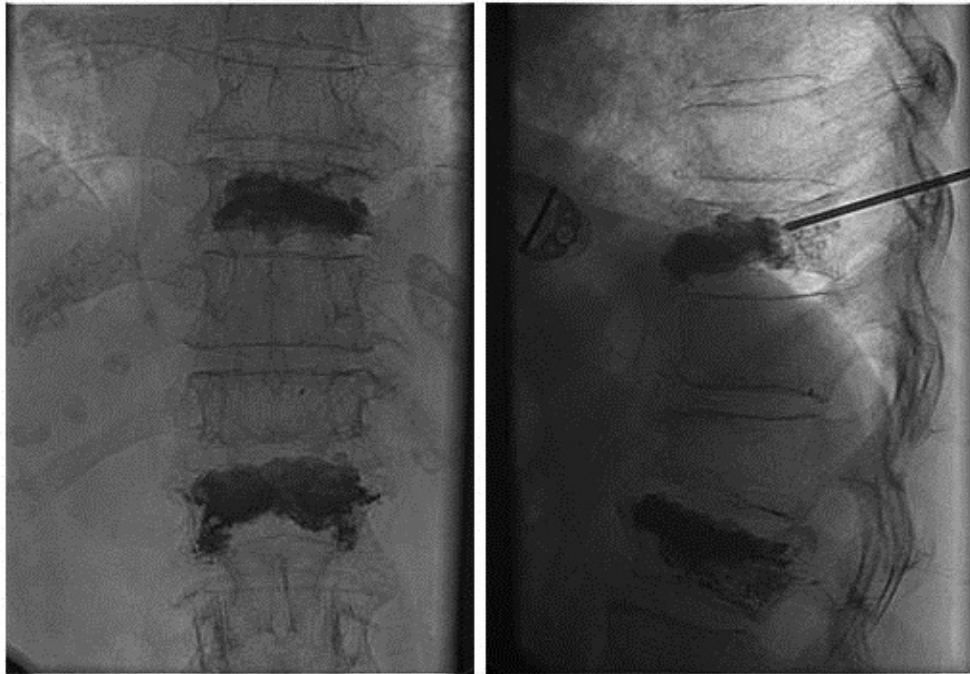

Figure 3. Intraoperative fluoroscopy AP and lateral views of an 83-year-old woman with osteoporotic compression fractures on L1 and T10. Bone cement used for vertebroplasty and balloon kyphoplasty immediately stabilizes the fractured vertebral body, enhancing loading capacity and relieving pain.

of 69 peer-reviewed published studies analyzing vertebroplasty and balloon kyphoplasty for the treatment of vertebral fractures (43). They reported eloquent pain relief (87% vertebroplasty; 92% balloon kyphoplasty) and amelioration in physical function (ODI fell from 60% preop to 32% postop).

Extravertebral cement leakage is the most frequently reported complication and is the major risk after vertebroplasty and balloon kyphoplasty. It is generally clinically asymptomatic; however, cases of major complications and death have been reported. Complications due to cement extravasations outside the vertebral body include pulmonary embolism, cement into the vena cava, heart and kidneys, spinal cord compression, and foraminal leaks producing nerve root compression requiring surgery for decompression (39-42). Another important question is the risk of fractures in adjacent-level vertebrae. A significant increase in the incidence of new painful fractures of adjacent vertebral bodies in patients with bone cement leakage has been recently reported (44).

Multiple compression fractures lead to a progressive kyphosis, loss of stature and paraspinal muscle shortening. To maintain a more erect and correct posture, a prolonged and active muscle contraction is required, and this may aggravate a preexisting generalized back pain. This generalized back pain can cause patients to limit their activity and an outstanding detriment in their quality of life (45). Vertebroplasty and balloon kyphoplasty offers a very limited or any kyphosis

correction, and does not appreciably contribute to the restoration of sagittal balance. This fact could restrain the medium and long term effectiveness of less invasive and percutaneous techniques, thus supporting the indication and convenience of more aggressive and complex surgical techniques for the restoration of the sagittal balance. The importance of the restoration of the sagittal balance lies in that it represents the most reliable and determinant predictor of clinical symptomatology [Figure 4]. Kim et al evaluated the improvement of 32 patients that underwent surgery for osteoporotic spinal deformity (46). At two years' follow-up, 94% of the patients admitted subjective improvement of symptoms; 70% of patients reported a decrease in pain scores (Visual Analogue Scale); and 54% of patients an improvement in associated disability (Oswestry Disability Index). However, in spite of these mid and long term promising results, a large number of patients reported the occurrence of short-term complications (37.5%), and even three patients required additional surgery to treat these setbacks.

Osteoporotic spinal deformities aggravated by the presence of global sagittal imbalance may have catastrophic consequences on patients. However, their surgical correction implies high complexity and high risk of complications, which requires a previous rigorous and sensitive assessment of the possible risks and benefits of their treatment (47).

Osteoporosis and spinal surgery complications

Previous clinical studies have reported peri/

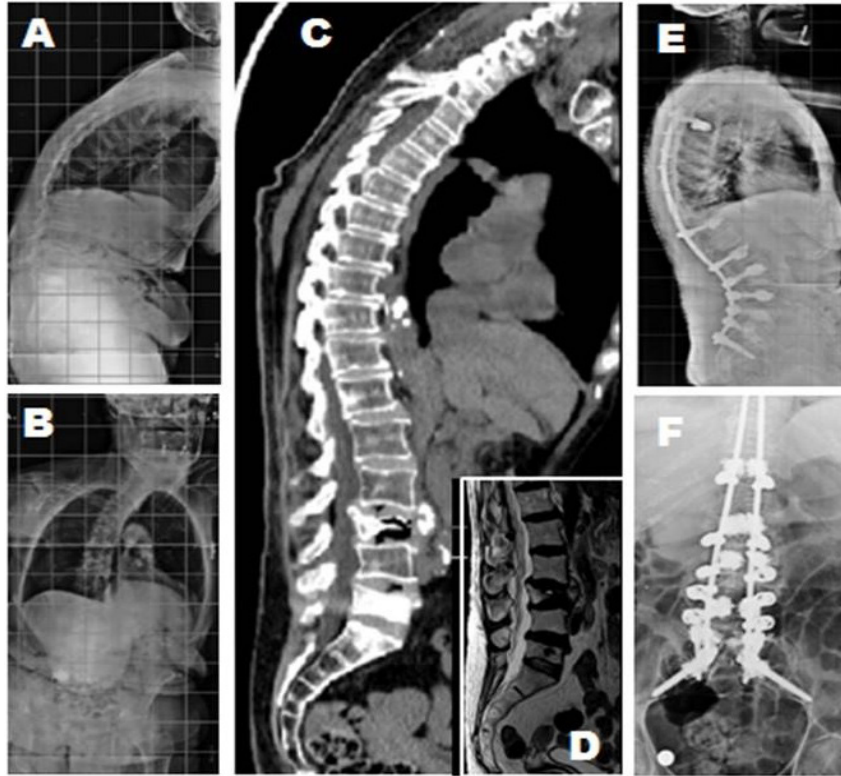


Figure 4. (A-B) posteroanterior and lateral radiographs of a 77-year-old woman with Parkinson disease, progressive sagittal and coronal imbalance and neurogenic claudication. Note L5 vertebroplasty. (C-D) sagittal CT and MRI demonstrating a L3 osteoporotic compression fracture severely affecting the patient's global sagittal alignment. (E-F) postoperative posteroanterior and lateral radiographs demonstrating correction obtained following posterior-only approach with an L3 pedicle subtraction osteotomy, a dual rod construct with thoracic spine sublaminar wires and proximal and distal PMMA-augmented fenestrated pedicle screws, L5-S1 interbody fusion and pelvic fixation.

postoperative complication incidences when operating on patients with adult spinal deformity and poor bone quality of up to or more than 40%. However, to the present day there are still very few studies evaluating the incidence and specific types of complications associated with its surgical treatment.

Carreon et al. reported the results of a study examining the rate of perioperative medical complications in 98 elderly patients who underwent posterior decompression and lumbar arthrodesis with instrumentation to treat degenerative disorders of the spine (17). The mean age was 72 years (65 to 84 years). Perioperative complications occurred in 78 patients (79%). Twenty-one patients (22%) had at least one major complication including 2 deaths both from postoperative wound sepsis, and 69 had at least one minor complication (70%). The most frequent complications were wound infection (10%) among the major complications and urinary tract infection (34%) among the minor complications. A greater blood loss, a prolonged operative time, a greater number of levels fused, and an older age, all were associated with an increased occurrence of perioperative complications. The presence, type, or number of preoperative medical conditions was not related to the

occurrence of complications. This finding is similar to that of Benz et al. , who reported that the presence of associated medical diseases did not affect the incidence of postoperative complications (48). However, other studies showed that the prevalence of postoperative morbidity increased as the number of pre-morbid diseases increased (49-51).

De Wald and Stanley revised 47 procedures in 38 patients to investigate the occurrence of instrumentation-related complications in multilevel fusion surgery for adult spinal deformity patients above 65 years of age (52). The mean follow-up interval was 30 months. They found that spinal deformity correction in patients with bone fragility had early (<3 months) complications including pedicle fractures and adjacent vertebral body compression fractures above and below constructs with a net incidence of 13%. They found late complications (>3 months) to include pseudoarthrosis with rod breakage (11%), screw loosening (7%), acute disc herniation above the last instrumented level (4%) [Figure 5], pelvic fixation prominence (11%), and progressive junctional kyphosis at the cephalad portion of the construct (26%). One major adverse event, which usually leads to

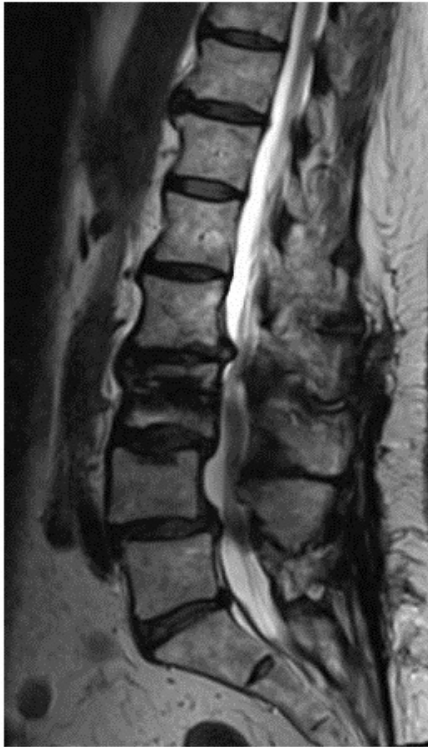

Figure 5. Sagittal T2-weighted MRI image demonstrating L2-L3 acute disc herniation above the instrumentation.

reoperation, is junctional kyphosis. Kim et al. reported the risk factors for the occurrence of postoperative

sagittal imbalance in long lumbar spinal fusions in adults (51). Sagittal imbalance greater than 5 cm, a 10° smaller lumbar lordosis than thoracic kyphosis at 8 weeks postop, and an age above 55 years and with associated comorbidities, were considered to be at extraordinary risk. The reestablishment of a balanced sagittal spine is deemed to be the most relevant factor of preventing junctional imbalance (53).

Not all patients with proximal junctional kyphosis are symptomatic. Glattes et al. reviewed the X-rays and clinical outcomes of 81 consecutive adult deformity patients to determine the occurrence of proximal junctional kyphosis and its effect on patient outcomes (54). Mean follow-up was 5.3 years. Incidence of proximal junctional kyphosis was 26%, but SRS-24 scores were not significantly affected. No patient, radiographic, or instrumentation variables were identified as risk factors for developing proximal junctional kyphosis. However, if the resulting loss of correction and progressive imbalance is caused by an adjacent vertebral body compression fracture, or fracture-subluxation, this may in time lead to muscle pain or further fracture, requiring an extension of the spinal fusion [Figure 6].

In cases of long fusions, the use of a rod that has a short taper to a smaller diameter so called transition rod, at the top end, and the addition of prophylactic vertebroplasty at segments immediately cranial and caudal to instrumentation have been advocated with the justification of eluding junctional segment fractures (55). Aydogan et al. used prophylactic vertebroplasty augmentation in segments proximal and distal to multilevel instrumented fusion to avert junctional segment fractures (56). The average age of the patients was 66 (59 to 78) years. All patients had the T-score value of less than -2.5. There were no proximal or

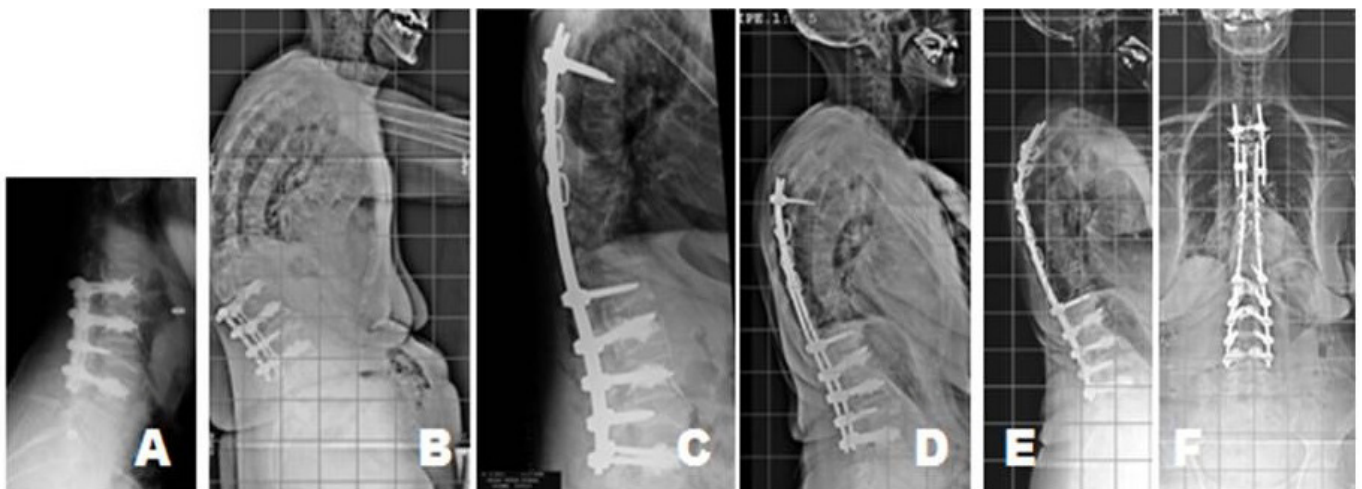


Figure 6. (A) postoperative lateral radiograph of a 71-year-old woman who had laminectomy and L4-L1 fusion with PMMA-augmented fenestrated pedicle screws. (B) early follow-up lateral radiograph demonstrating loss of correction and progressive imbalance caused by failure of the instrumentation at the upper-instrumented vertebra with vertebral body compression fracture. (C) the fusion was extended to T6 using bilateral pedicular screws and sublaminar wires. (D) failure of instrumentation occurred again at the upper-instrumented vertebra. (E) fusion was re-extended to T4 with thoracic spine sublaminar wires. Satisfactory profile in both frontal and sagittal planes were obtained.

distal junctional segment fractures observed during the follow-up course. They argue that these additional vertebroplasties could serve as a possible means of avoiding junctional fractures. This opinion requires investigation before it can be confirmed, since additional vertebroplasty augmentation has been recently associated with further and more severe spinal fractures (57).

The authors did not receive grants or outside funding in support of their research or preparation of this manuscript. They did not receive payments or other benefits or a commitment or agreement to provide such benefits from a commercial entity. No commercial entity paid or directed, or agreed to pay or direct, any

benefits to any research fund, foundation, educational institution, or other charitable or non-profit organization with which the authors are affiliated or associated.

Félix Tomé-Bermejo MD PhD
Angel R. Piñera MD
Luis Alvarez MD PhD
Spine Department, Fundación Jiménez Díaz University
Hospital, Madrid, Spain

References

1. Benoist M. Natural history of the aging spine. *Eur Spine J.* 2003; 12(Suppl 2):S86-9.
2. Tomé-Bermejo F, Barriga Martín A, Martín JL. Identifying patients with chronic low back pain likely to benefit from lumbar facet radiofrequency denervation: a prospective study. *J Spinal Disord Tech.* 2011; 24(2):69-75.
3. Weinstein JN, Lurie JD, Tosteson TD, Hanscom B, Tosteson AN, Blood EA, et al. Surgical versus nonsurgical treatment for lumbar degenerative spondylolisthesis. *N Engl J Med.* 2007; 356(22):2257-70.
4. Gunzburg R, Szpalski M. The conservative surgical treatment of lumbar spinal stenosis in the elderly. *Eur Spine J.* 2003; 12(Suppl 2):S176-80.
5. Hart RA, Prendergast MA. Spine surgery for lumbar degenerative disease in elderly and osteoporotic patients. *Instr Course Lect.* 2007; 56(1):257-72.
6. Arbit E, Pannullo S. Lumbar stenosis: a clinical review. *Clin Orthop Relat Res.* 2001; 384(5):137-43.
7. Porter RW. Spinal stenosis and neurogenic claudication. *Spine (Phila Pa 1976).* 1996; 21(17):2046-52.
8. Schizas C, Theumann N, Burn A, Tansey R, Wardlaw D, Smith FW, et al. Qualitative grading of severity of lumbar spinal stenosis based on the morphology of the dural sac on magnetic resonance images. *Spine.* 2010; 35(21):1919-24.
9. Panjabi MM, White AA 3rd. Basic biomechanics of the spine. *Neurosurgery.* 1980; 7(1):76-93.
10. Vaccaro AR, Scott TB. Indications for instrumentation in degenerative lumbar spinal disorders. *Orthopedics.* 2000; 23(3):260-71.
11. Sengupta DK, Herkowitz HN. Lumbar spinal stenosis: treatment strategies and indications for surgery. *Orthop Clin North Am.* 2003; 34(2):281-95.
12. Deyo RA, Cherkin DC, Loeser JD, Bigos SJ, Ciol MA. Morbidity and mortality in association with operations on the lumbar spine. The influence of age, diagnosis, and procedure. *J Bone Joint Surg Am.* 1992; 74(4):536-43.
13. Kondrashov DG, Hannibal M, Hsu KY, Zucherman JF. X-STOP versus decompression for neurogenic claudication: Economic and clinical analysis. *Int J Minim Invasive Spine Surg Tech.* 2007; 1(2):3.
14. Deyo RA, Martin BI, Ching A, Tosteson AN, Jarvik JG, Kreuter W, et al. Interspinous spacers compared to decompression or fusion for lumbar stenosis: complications and repeat operations in the medicare population. *Spine (Phila Pa 1976).* 2013; 38(10):865-72.
15. Postacchini F. Surgical management of lumbar spinal stenosis. *Spine.* 1999; 24(10):1043-7.
16. Ragab AA, Fye MA, Bohlman HH. Surgery of the lumbar spine for spinal stenosis in 118 patients 70 years of age or older. *Spine.* 2003; 28(4):348-53.
17. Carreon LY, Puno RM, Dimar JR 2nd, Glassman SD, Johnson JR. Perioperative complications of posterior lumbar decompression and arthrodesis in older adults. *J Bone Joint Surg Am.* 2003; 85-A(11):2089-92.
18. Cassinelli EH, Eubanks J, Vogt M, Furey C, Yoo J, Bohlman HH. Risk factors for the development of perioperative complications in elderly patients undergoing lumbar decompression and arthrodesis for spinal stenosis: an analysis of 166 patients. *Spine.* 2007; 32(2):230-5.
19. Chang MC, Liu CL, Chen TH. Polymethylmethacrylate augmentation of pedicle screw for osteoporotic spinal surgery: a novel technique. *Spine.* 2008; 33(10):E317-24.
20. Cloyd JM, Acosta FL Jr, Ames CP. Complications and

- outcomes of lumbar spine surgery in elderly people: a review of the literature. *J Am Geriatr Soc.* 2008; 56(7):1318-27.
21. Tsirikos AI, Garrido EG. Spondylolysis and spondylolisthesis in children and adolescents. *J Bone Joint Surg Br.* 2010; 92(6):751-9.
 22. Meyerding HW. Low backache and sciatic pain associated with spondylolisthesis and protruded intervertebral disc: incidence, significance, and treatment. *J Bone Joint Surg.* 1941; 23(2):461-70.
 23. Lombardi JS, Wiltse LL, Reynolds J, Widell EH, Spencer C 3rd. Treatment of degenerative spondylolisthesis. *Spine.* 1985; 10(9):821-7.
 24. Fischgrund JS, Mackay M, Herkowitz HN, Brower R, Montgomery DM, Kurz LT. Degenerative lumbar spondylolisthesis with spinal stenosis: a prospective, randomized study comparing decompressive laminectomy and arthrodesis with and without spinal instrumentation. *Spine.* 1997; 22(24):2807-12.
 25. Aebi M. The adult scoliosis. *Eur Spine J.* 2005; 14(10):925-48.
 26. Bradford DS, Tay BK, Hu SS. Adult scoliosis: surgical indications, operative management, complications, and outcomes. *Spine.* 1999; 24(24):2617-29.
 27. Tribus CB. Degenerative lumbar scoliosis: evaluation and management. *J Am Acad Orthop Surg.* 2003; 11(3):174-83.
 28. Gupta MC. Degenerative scoliosis. Options for surgical management. *Orthop Clin North Am.* 2003; 34(2):269-79.
 29. Pritchett JW, Bortel DT. Degenerative symptomatic lumbar scoliosis. *Spine (Phila Pa 1976).* 1993; 18(6):700-3.
 30. Hu SS, Holly EA, Lele C, Averbach S, Kristiansen J, Schiff M, et al. Patient outcomes after spinal reconstructive surgery in patients > or = 40 years of age. *J Spinal Disord.* 1996; 9(6):460-9.
 31. Gertzbein SD, Halloway MR, Hall S. Pseudarthrosis of the lumbar spine. Outcome after circumferential fusion. *Spine (Phila Pa 1976).* 1998; 23(21):2352-6.
 32. Randell A, Sambrook PN, Nguyen TV, Lapsley H, Jones G, Kelly PJ, et al. Direct clinical and welfare costs of osteoporotic fractures in elderly men and women. *Osteoporos Int.* 1995; 5(6):427-32.
 33. Kanis JA. Assessment of fracture risk and its application to screening for postmenopausal osteoporosis: synopsis of a WHO report. WHO Study Group. *Osteoporos Int.* 1994; 4(6):368-81.
 34. Gehlbach SH, Bigelow C, Heimisdottir M, May S, Walker M, Kirkwood JR. Recognition of vertebral fractures in a clinical setting. *Osteoporos Int.* 2000; 11(7):577-82.
 35. Schlaic C, Minne HW, Bruckner T, Wagner G, Gebest HJ, Grunze M, et al. Reduced pulmonary function in patients with spinal osteoporotic fractures. *Osteoporos Int.* 1998; 8(3):261-7.
 36. Kanter AS, Asthagiri AR, Shaffrey CI. Aging spine: challenges and emerging techniques. *Clin Neurosurg.* 2007; 54:10-8
 37. Ponnusamy KE, Iyer S, Gupta G, Khanna AJ. Instrumentation of the osteoporotic spine: biomechanical and clinical considerations. *Spine J.* 2011; 11(1):54-63.
 38. Hadjipavlou AG, Katonis PG, Tzermiadianos MN, Tsoukas GM, Sapkas G. Principles of management of osteometabolic disorders affecting the aging spine. *Eur Spine J.* 2003; 12(Suppl 2):S113-31.
 39. Li X, Yang H, Tang T, Qian Z, Chen L, Zhang Z. Comparison of kyphoplasty and vertebroplasty for treatment of painful osteoporotic vertebral compression fracture: twelve-month follow-up in a prospective nonrandomized comparative study. *Clin Spinal Surg.* 2012; 25(3):142-9.
 40. Alvarez L, Alcaraz M, Perez-Higueras A, Granizo JJ, de Miguel I, Rossi RE, et al. Percutaneous vertebroplasty: functional improvement in patients with osteoporotic compression fractures. *Spine.* 2006; 31(19):1113-8.
 41. Alvarez L, Perez-Higueras A, Quiñones D, Rossi RE, Granizo J. Seven year experience of percutaneous vertebroplasty for osteoporotic vertebral fractures: analysis of factors determining outcome in 212 patients. *Spine J.* 2003; 3(5):96.
 42. Alvarez L, Perez-Higueras A, Granizo JJ, de Miguel I, Quinones D, Rossi RE. Predictors of outcomes of percutaneous vertebroplasty for osteoporotic vertebral fractures. *Spine.* 2005; 30(1):87-92.
 43. Hulme PA, Jrebs J, Ferguson SJ, Berlemann U. Vertebroplasty and kyphoplasty: a systematic review of 69 clinical studies. *Spine.* 2006; 31(17):1983-2001.
 44. Chen WJ, Kao YH, Yang SC, Yu SW, Tu YK, Chung KC. Impact of cement leakage into disks on the development of adjacent vertebral compression fractures. *J Spinal Disord Tech.* 2010; 23(1):35-9.
 45. Bassewitz HL, Herkowitz HN. Osteoporosis of the spine: medical and surgical strategies. *Univ Pennsylvania Orthop J.* 2000; 13:35-42.
 46. Kim WJ, Lee ES, Jeon SH, Yalug I. Correction of osteoporotic fracture deformities with global sagittal imbalance. *Clin Orthop Relat Res.* 2006; 443(1):75-93.
 47. Bono CM, Einhorn TA. Overview of osteoporosis: pathophysiology and determinants of bone strength. *Eur Spine J.* 2003; 12(Suppl 2):S90-6.
 48. Benz RJ, Ibrahim ZG, Afshar P, Garfin SR. Predicting

- complications in elderly patients undergoing lumbar decompression. *Clin Orthop*. 2001; 384(11):116-21.
49. Smith EB, Hanigan WC. Surgical results and complications in elderly patients with benign lesions of the spinal canal. *J Am Geriatr Soc*. 1992; 40(9):867-70.
50. Oldridge NB, Yuan Z, Stoll JE, Rimm AR. Lumbar spine surgery and mortality among Medicare beneficiaries, 1986. *Am J Public Health*. 1994; 84(8):1292-8.
51. Kim YJ, Bridwell KH, Lenke LG, Rhim S, Cheh G. Sagittal thoracic decompensation following long adult spinal instrumentation and fusion to L5 or S1: causes, prevalence, and risk factor analysis. *Spine*. 2006; 31(20):2359-66.
52. De Wald CJ, Stanley T. Instrumentation-related complications of multilevel fusions for adult spinal deformity patients over age 65: surgical considerations and treatment options in patients with poor bone quality. *Spine*. 2006; 31(19 Suppl):S144-51.
53. Lattig F. Bone cement augmentation in the prevention of adjacent segment failure after multilevel adult deformity fusion. *J Spinal Disord Tech*. 2009; 22(6):439-43.
54. Glattes RC, Bridwell KH, Lenke LG, Kim YJ, Rinella A, Edwards C 2nd. Proximal junctional kyphosis in adult spinal deformity following long instrumented posterior spinal fusion: incidence, outcomes, and risk factor analysis. *Spine (Phila Pa 1976)*. 2005; 30(14):1643-9.
55. Cahill PJ, Wang W, Asghar J, Booker R, Betz RR, Ramsey C, et al. The use of a transition rod may prevent proximal junctional kyphosis in the thoracic spine after scoliosis surgery: a finite element analysis. *Spine (Phila Pa 1976)*. 2012; 37(12):E687-95.
56. Aydogan M, Ozturk C, Karatoprak O, Tezer M, Aksu N, Hamzaoglu A. The pedicle screw fixation with vertebroplasty augmentation in the surgical treatment of the severe osteoporotic spines. *J Spinal Disord Tech*. 2009; 22(6):444-7.
57. Fernández-Baíllo N, Sánchez Márquez JM, Sánchez Pérez-Grueso FJ, GarcíaFernández A. Proximal junctional vertebral fracture-subluxation after adult spine deformity surgery. Does vertebral augmentation avoid this complication? A case report. *Scoliosis*. 2012; 7(1):16.