

**CASE REPORT**

# Ossified Dorsal Wrist Ganglion Cyst: A Case Report

Juana Medina, MD; Michael Rivlin, MD; Joanna Chan, MD; Pedro K. Beredjiklian, MD

Research performed at Rothman Institute of Orthopedics, Thomas Jefferson University, Philadelphia, PA, USA

Received: 20 October 2015

Accepted: 7 January 2016

**Abstract**

Ganglion cysts are the most common wrist tumors, and 60 -70% originate dorsally from the scapholunate interval. Ossification of these lesions is exceedingly rare, with only one such lesion located in the finger reported in the literature. We present a case of an ossified dorsal wrist ganglion in a 68-year-old woman.

**Keywords:** Bone cyst, Hand bone ganglion, Ossified ganglion cyst

**Introduction**

**G**anglions are cystic spaces without epithelial lining, containing a mucinous material of variable viscosity with a high concentration of hyaluronic acid (1). Approximately 50-70% of soft tissue tumors of the hand are ganglions, and those which present dorsally typically originate from the scapholunate ligament region (2). The differential diagnoses for these masses include giant cell tumor, lipoma, or anomalous muscles such as extensor digitorum brevis manus.

These lesions are common clinical entities, presenting as either progressively growing or fluctuating masses (1, 2). While many are asymptomatic, some present with dorsal wrist pain exacerbated with extension, likely from compression of branches of the posterior interosseous nerve. Initial evaluation of those masses begins with radiographs, with advanced imaging studies such as ultrasound (US) or magnetic resonance (MR) when clinically indicated. Calcification or ossification within the lesion is exceedingly rare, with only one case of an ossified ganglion in a finger reported in the literature. We present a case of an ossified dorsal wrist ganglion in a 68-year-old woman.

**Case report**

A 68-year-old woman presented with a painful, progressively growing mass over the dorsal aspect of her dominant right wrist. The progressively

growing lesion was present for over two years, with increasing pain. She did not recall a specific traumatic injury preceding the onset of symptoms. On physical examination, the patient had a solid, tender mass on the dorsal aspect of the wrist, overlying the second dorsal compartment. There was no fluctuation. There was mild limitation in the range of motion of the wrist, but with significant tenderness at the end range of wrist extension. Neurovascular exam was intact.

Radiographic evaluation with plain x-rays didn't show fracture or acute abnormalities [Figure 1]. MRI with gadolinium contrast revealed a complex cystic mass on the dorsal aspect of the wrist at the proximal carpal row, dorsal to the scaphoid and lunate [Figure 2]. Given the patient's advanced age, which is atypical for ganglion cyst presentation, an MRI with gadolinium contrast was obtained in the event this mass had neoplastic features. The lesion was well circumscribed, measuring 1.7 \* 1.4 \* 1.1 cm with coalescent areas of low signal intensity on the fluid sensitive sequences.

During surgical excision, a cystic mass was found to originate from the scapholunate interosseous ligament and dorsal wrist capsule. The cyst and communicating stalk were removed entirely and cauterization of the area of the stalk was also performed. Histologic evaluation of the mass revealed a 2.2 \* 1.7 \* 1.1 cm, irregularly shaped soft tissue mass consistent with an ossified ganglion cyst [Figure 3]. The patient had

**Corresponding Author:** Pedro K. Beredjiklian, Rothman Institute of Orthopedics, 925 Chestnut Street, 5<sup>th</sup> Floor, Philadelphia, USA  
Email: [Pedro.beredjiklian@rothmaninstitute.com](mailto:Pedro.beredjiklian@rothmaninstitute.com)



THE ONLINE VERSION OF THIS ARTICLE  
[ABJS.MUMS.AC.IR](http://abjs.mums.ac.ir)

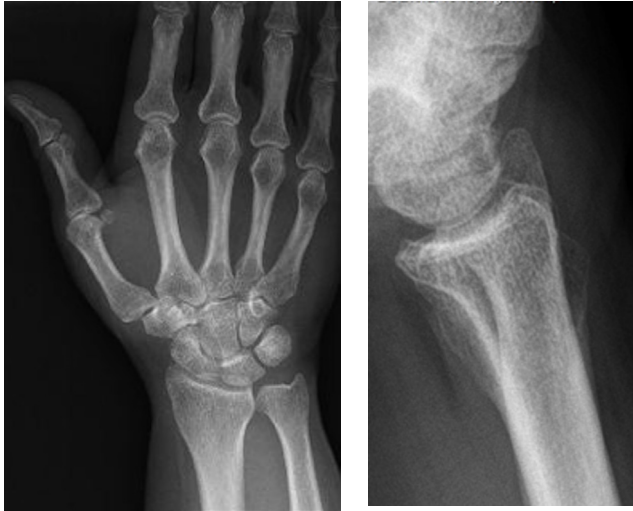

Figure 1. Anteroposterior and lateral views of wrist x-rays.

an uneventful postoperative outcome and had no symptoms of recurrence thirteen months after the surgical procedure.

### Discussion

Ganglion cysts are the most frequent benign tumors in wrist and hand (2). Dorsal wrist ganglions account for 60-70% of all wrist ganglions. A typical clinical presentation and the pathologic concordant findings is present in 97 % of cases (3). As such, it has been

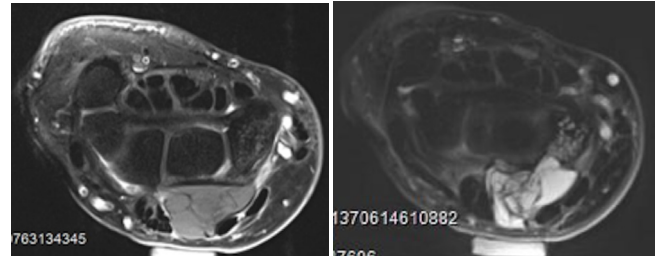


Figure 2. Transverse wrist views of MRI on T1 and T2 sequences.

suggested that the resected ganglion cyst specimen should not have routine pathological examination. In this particular case, the atypical clinical characteristics both on examination and MRI led to a histologic evaluation of this lesion, which revealed calcification in the walls and lumen of the cyst.

While there are different pathomechanical theories to explain the development of ganglion cysts, the etiology of these lesions remains unclear. Some authors believe that ganglions are the result of myxoid degeneration of the connective tissue of the joint capsule or tendon sheath (4, 5). Others have postulated that mucin secretion resulting from cellular hyperplasia is etiologic in the development of these cysts (5). Johnson and colleagues have theorized that proliferation of fibroblasts in the wall of the cyst leads to an increase in the production of hyaluronic acid production, an important component of the fluid within the walls of the cyst (6).

Ossified ganglions are exceedingly rare, and we

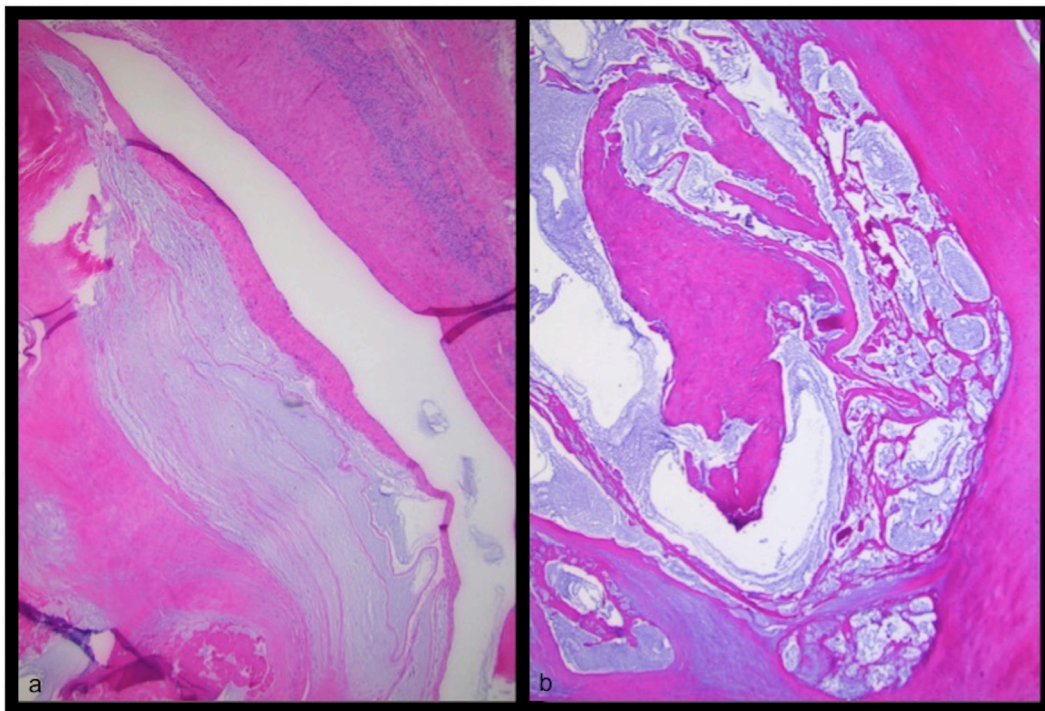


Figure 3. (a) Histologic image of lesion with normal myxoid content (asterisk); (b) ossified component (asterisk) H&E stain 40x.

found only one case report in the literature (7). Tehranzadeh and colleagues reported the presence of an ossified ganglion in a small finger in a 50-year-old female swimmer (8). The authors describe a firm, mobile, subcutaneous mass on the ulnar aspect of the proximal interphalangeal joint. The fibrous wall of the cyst showed focal extravasation of red blood cells and myxoid change with calcification at the most peripheral portion of the cyst wall.

In conclusion, we present a case of an ossified dorsal ganglion cyst in a patient with atypical findings clinically and on radiographic evaluation. In spite of the rare pathologic findings, treatment with routine surgical excision led to successful treatment and satisfactory clinical outcome.

Juana Medina MD  
Ortopedia y traumatología, Fundación Santa Fe de Bogotá, Bogotá, D.C., Cundinamarca, Colombia, USA

Michael Rivlin MD  
Pedro K. Beredjiklian MD  
Rothman Institute of Orthopedics, Thomas Jefferson University, Philadelphia, PA, USA

Joanna Chan MD  
Department of Pathology and Laboratory Medicine, Jefferson University Hospital, Philadelphia, PA, USA

### References

1. Nahra ME, Bucchieri JS. Ganglion cysts and other tumor related conditions of the hand and wrist. *Hand Clin.* 2004; 20(3):249-60.
2. Nguyen V, Choi J, Davis KW. Imaging of Wrist Masses. *Curr Probl Diagn Radiol.* 2004; 33(4):147-60.
3. Guitton TG, van Leerdam RH, Ring D. Necessity of Routine Pathological Examination after Surgical Excision of Wrist Ganglions. *J Hand Surg Am.* 2010; 35(6):905-8.
4. Kachooei AR, Nota SP, Menendez ME, Dyer GS, Ring D. Factors associated with operative treatment of de Quervain tendinopathy. *Arch Bone Jt Surg.* 2015; 3(3):198-203.
5. Tophoj K, Henriques U. Ganglion of the wrist--a structure developed from the joint. *Acta Orthop Scand.* 1971; 42(3):244-50.
6. Johnson WC, Graham JH, Helwig EB. Cutaneous myxoid cyst: a clinico-pathological and histochemical study. *JAMA.* 1965; 191(1):15-20.
7. Moradi A, Kachooei AR, Mudgal CS. Acute calcium deposits in the hand and wrist. *J Hand Surg Am.* 2014; 39(9):1854-7.
8. Tehranzadeh J, Anavim A, Lin F. Radiographically ossified ganglion cyst of finger in a swimmer. *Skeletal Radiol.* 1998; 27(12):705-7.