

CASE REPORT

Adult Degenerative Scoliosis with Spinal Stenosis Treated with Stand-Alone Cage via an Extreme Lateral Transpsoas Approach; a Case Report and Literature Review

Arvind von Keudell, MD; Marjan Alimi, MD; Harry Gebhard, MD; Roger Härtl, MD

*Research performed at Cornell University, New York, USA**Received: 21 June 2014**Accepted: 16 February 2015***Abstract**

We report the case of a 73-year-old female with severe degenerative scoliosis and back and leg pain that was successfully treated with stand-alone cages via an extreme lateral transpsoas approach. This patient had declined open surgery and instrumentation due to her advanced age concerns about potential side effects.

Key words: Degenerative scoliosis, Minimally invasive spinal surgery, XLIF

Introduction

Adult degenerative scoliosis is prevalent in 68% of the asymptomatic population, who are over 60 (1). In symptomatic patients who failed non-operative treatment, surgery is usually performed via open decompression and fusion procedures using posterior instrumentation with or without interbody fusion. Since the introduction of minimally invasive access to the spine, surgical treatment options for this pathology are becoming more versatile (2-4).

Surgical decompression alone, which would be the least invasive traditional surgical option, is frequently prohibitive due to a high risk of worsening of the spinal deformity (5, 6). Non-instrumented decompression with posterolateral fusion is associated with a risk of non-union and deterioration of the scoliosis. Finally, surgeons can consider decompression with instrumentation and posterolateral fusion (7-13). However in the elderly patient with multiple comorbidities there are significant preoperative risks related to high blood loss, long hospital stays, and instrumentation failure (7, 14, 15). On the other hand, potential advantages of minimally invasive spine surgery include less blood loss and tissue injuries, shorter hospital stay, less narcotic use, smaller scars and earlier return to normal activities (3, 16).

Ozgun et al. have described the lateral transpsoas approach for lumbar discectomy and interbody fusion. Recently this technique has been successfully implemented for patients with adult degenerative scoliosis (17-21). The anterior discectomy and fusion using an interbody spacer leads to indirect decompression of the neuroforamina and the spinal canal. This procedure is usually performed in conjunction with posterior instrumentation and fusion, sometimes also with additional direct decompression (22). We did not plan to address the spinal deformity by this procedure.

Surgeons have used this technique without posterior instrumentation. However, to our knowledge this has not been reported in the peer-reviewed literature. We report the case of a 73-year-old female with degenerative scoliosis and back and leg pain that was successfully treated with stand-alone cages via an extreme lateral transpsoas approach. This patient had declined open surgery and instrumentation due to her advanced age and concerns about potential side effects.

Case Report

A 73-year-old woman consented to have her medical records published. She presented with low back pain,

Corresponding Author: Roger Härtl, Department of Neurological Surgery, Cornell University, 525 East 68th Street, New York, NY, United States.
Email: roger@hartlmd.com



THE ONLINE VERSION OF THIS ARTICLE
ABJS.MUMS.AC.IR

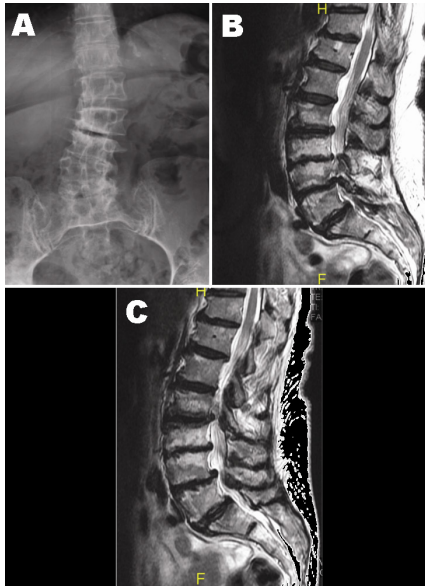


Figure 1. Pre operative anteroposterior X-Ray (A) and sagittal T2-weighted MRI scan (B, C).

bilateral radiculopathy, and neurogenic claudication as well as with osteopenia of her lumbar spine, which was treated with bisphosphonates. On a self-reported scale her back pain was scored 7 out of 10, accompanied by bilateral leg pain scored 8 and 9 out of 10. Nonsurgical treatment including physical therapy and three epidural steroid injections could not relieve her clinical symptoms

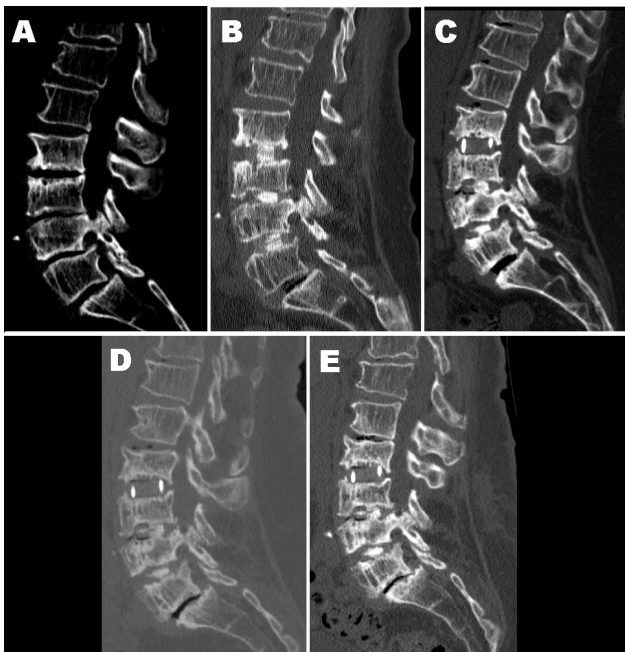


Figure 3. Sagittal CT scans pre-op (A), immediate post-op (B), 10 months after surgery (C), 26 months after surgery (D), and 36 months after surgery (E).

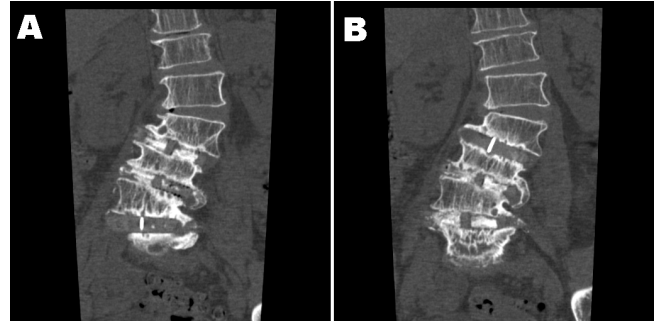


Figure 2. Coronal CT Scan 36 months postoperatively demonstrating bony fusion at L2/L3 (A) and at L3/L5 (B).

over a period of 14 months. Magnetic resonance imaging (MRI) showed scoliosis with left-sided convexity at L1-2 and right-sided convexity at L4. Lumbar spinal canal stenosis with severe neural foraminal narrowing was present at levels L2-L3, L3-L4, L4-L5 [Figure 1].

Operative Technique and Results

The patient was placed in a true lateral decubitus position guided by intraoperative fluoroscopy. A small incision was made on the right side and access to the L2 to L5 disc spaces was obtained using tubular dilators (Nuvasive, CA) as described by Ozgur et al. (17). The abdominal muscle was divided bluntly, followed by a gentle finger dissection into the retroperitoneal space. A series of tubular dilators was inserted to gain access to the L4 and L5 area. Safe docking of the spreaders onto the intervertebral disc space was performed under continuous intraoperative EMG control (electromyography) (Neurovision®, NuVasive, California). We performed an extensive discectomy and with extensive release of the contralateral annulus and ligaments. A 22 x 50 x 10 mm cage was inserted, filled with Actifuse® bone graft substitute (Actifuse Synthetic Bone Graft, Apatech, Ltd.). The same procedure was performed for L3-L4 and L2-L3, through the same skin incision but through different fascial incisions. At the end of the procedure abdominal fascia, subcutaneous and skin tissues were closed separately. There were no complications during the procedure; the blood loss was minimal.

The patient was discharged home on post-operative day one and was treated with a brace for six weeks after surgery. The patient had mild right thigh numbness and pain, which improved gradually. Within 4 weeks after the operation, her VAS (Visual Analogue Scale) back pain and VAS leg pain completely resolved from a pre-operative value of 8-9, to a scale of 0 out of 10. The patient was last seen 36 months postoperatively, with continued complete resolution of her symptoms. Imaging studies at 36 months revealed stable implants, minimal subsidence and most likely evidence of fusion [Figures 2; 3].

It is important to note that although in Figure 3, optimal fusion is not evident simultaneously at different levels on the final imaging, comprehensive review of the CT-Scan revealed fusion at all 3 different levels. This is because

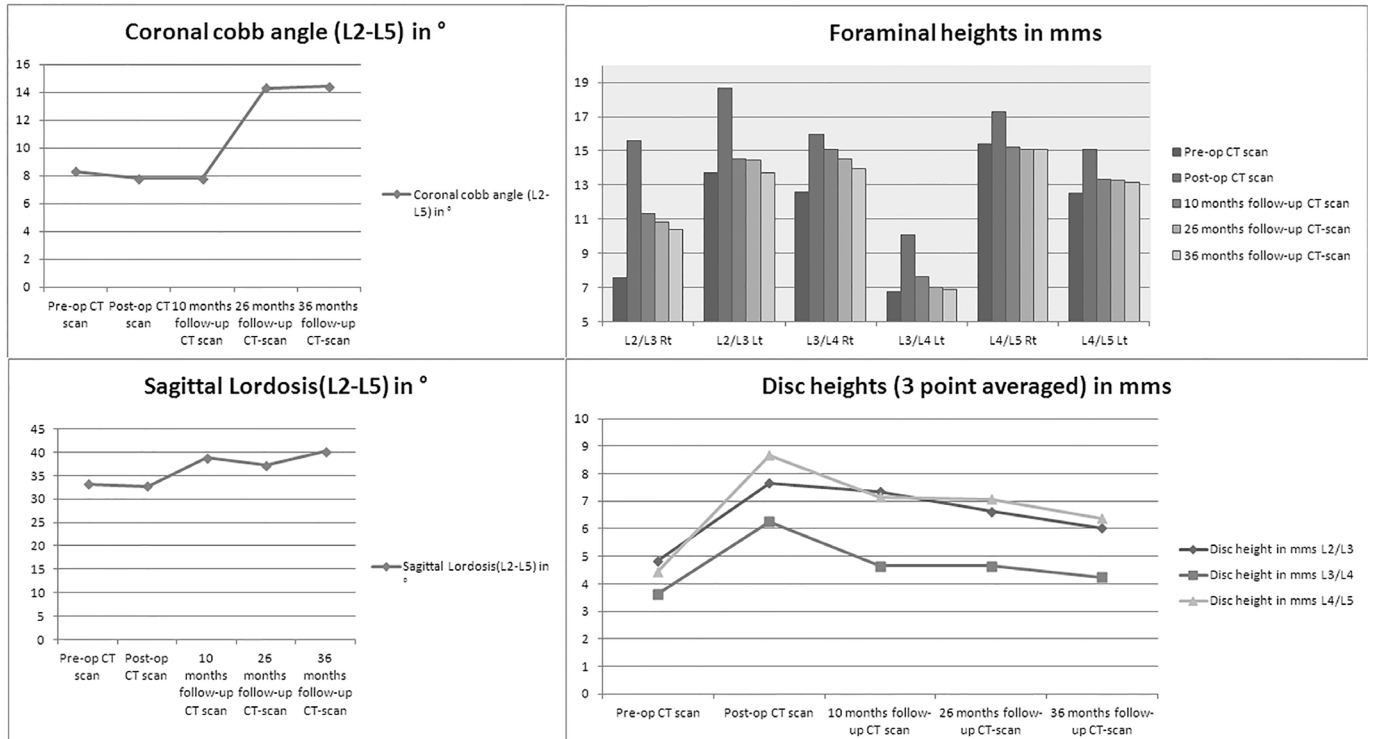


Figure 4. Radiographic parameters change over time.

the presented case was a deformity case undergoing a multi-level interbody fusion; thus, fusion could not be discernible on a single cut at all levels.

A summary of radiographic measurements from pre- and postoperative CT and MRI scans is given in Table 1. Postoperative imaging studies showed improvement of disc height and central spinal and foraminal stenosis [Figure 3]. Pre- and postoperative MRI scans were used to compare the spinal stenosis at the surgical levels. The area of the spinal canal was determined using "SurgimapSpine" (Menaris, Mexico City Area, Mexico) software and increased 34% after surgery. Coronal and sagittal Cobb angles did not change significantly after surgery and remained stable over the course of 10 months [Figure 4]. The coronal Cobb angle increased to 16 degrees at last follow-up, although the patient remained asymptomatic. As for functional outcome, the Oswestry Disability Index (ODI) was 48 pre-operatively, which decreased to 2, four weeks after surgery. The patient was able to return to her original level of activity and remained fully functional and pain-free 36 months after the index surgery.

Discussion

Currently there is scarce data on extreme lateral interbody fusion for the treatment of degenerative scoliosis and no data exists on stand-alone procedures for this pathology. Pimenta et al. has introduced the technique, which was popularized by Ozgur et al., for the treatment of degenerative disc disease (17, 23).

Subsequently, its feasibility was also investigated for the treatment of degenerative scoliosis in the lumbar spine. To our knowledge, there are five studies that have described their experience of XLIF for degenerative scoliosis of the lumbar spine as seen in Table 2 (22, 24-27). In the first series of 12 patients, Anand et al. have reported on their initial results of combined minimally invasive surgery including lateral interbody fusion and instrumentation (24). After a short follow-up time of 75 days, they reported early pain reduction, although 25% had transient thigh dysesthesia or quadriceps weakness. In a subsequent study, Anand et al. described the results of 28 patients with a mean follow up of 22 months (22). Significant improvement in the VAS pain (57%) was found and all patients maintained correction of their deformity with solid fusion in all patients on plain radiographs. Wang et al. reported on 23 patients who underwent a similar technique as described by Pimenta et al. (23, 27). Although the operated time was considerably longer than all other studies, no increase in intraoperative complications was noted. Transient thigh symptoms were similar to the average of all other studies (30.4% vs. 43%). Significant pain improvement (54.1%) was shown after a mean follow up of 12 months and CT imaging confirmed fusion of all interbody levels. Dakwar et al. reported on 25 patients with symptomatic degenerative scoliosis in the lumbar spine with an average of 11 months follow up (25). Patients had significant VAS pain improvement (70.4%). At a minimum of 6 months, 20 out of the 25 patients

Table 1. Summary of the pre-op, post-op, 10 months follow-up, 26 months follow-up, and 36 months follow-up of changes in coronal cobb angle, sagittal lordosis, foraminal heights and disc heights

| | Pre-op CT scan | Post-op CT scan | 10 months follow- up CT scan | 26 months follow- up CT-scan | 36 months follow- up CT-scan |
|---|-------------------|--------------------|---------------------------------|---------------------------------|---------------------------------|
| Coronal cobb angle (L2-L5) in ° | 8.3° | 7.8° | 7.8° | 14.3° | 14.4° |
| Sagittal Lordosis(L2-L5) in ° | 33.2° | 32.7° | 38.8° | 37.2° | 40.2° |
| Foraminal heights in mms | | | | | |
| L2/L3 Rt | 7.55 | 15.58 | 11.32 | 10.82 | 10.37 |
| L2/L3 Lt | 13.69 | 18.68 | 14.53 | 14.46 | 13.70 |
| L3/L4 Rt | 12.58 | 15.94 | 15.06 | 14.50 | 13.98 |
| L3/L4 Lt | 6.73 | 10.05 | 7.64 | 7.03 | 6.91 |
| L4/L5 Rt | 15.39 | 17.26 | 15.22 | 15.12 | 15.06 |
| L4/L5 Lt | 12.51 | 15.12 | 13.32 | 13.26 | 13.16 |
| Disc heights (3 point averages) in mms | | | | | |
| L2/L3 | 4.84 | 7.67 | 7.35 | 6.63 | 6.03 |
| L3/L4 | 3.63 | 6.26 | 4.64 | 4.64 | 4.25 |
| L4/L5 | 4.45 | 8.68 | 7.16 | 7.08 | 6.37 |

showed solid fusion on the CT scan or flexion/extension radiographs. In another study, Tormenti et al. reported on eight patients, who underwent XLIF with posterior fusion (26). A high rate of transient thigh para- or dyesthesia was found in 6 out of the 8 patients (75%). Two patients experienced motor radiculopathy, in one patient it was resolved, but persisted in the other one for three months postoperatively. Significant improvements were seen on the VAS score and Cobb angle.

In this report, we described a patient in whom we performed an extreme lateral transpsoas approach for stand-alone cage placement to treat leg and back pain due to adult degenerative lumbar scoliosis. Presently, direct posterior decompression and instrumented fusion, with or without interbody fusion is the mainstay in operative treatment for degenerative lumbar scoliosis. However, because of significant co-morbidities in these patients and the risks associated with surgery, operative treatment is frequently avoided. Surgery is associated with long operative times, high blood loss and prolonged hospitalization. Complication rates with this type of surgery can be > 50% (7, 11, 13, 28). In a recent study Cho, et al. reported a complication rate of

68% including blood loss, ileus, urinary tract infection, transient delirium, superficial infection, and neurologic deficits (8).

The extreme lateral transpsoas approach was first described by Pimenta et al. in 2001 as a novel approach to the lumbar spine with some studies suggesting promising outcomes in adult scoliosis (18-20, 23). However, there are also risks associated with it such as graft subsidence, especially in osteoporosis and lateral thigh dyesthesia due to damage or irritation of the interpsoas nerve fibers or psoas edema and infection (29).

The concept of indirect decompression has been well described in the past, mainly in ALIF surgery (30, 31). In our case it also resulted in an increase of the spinal canal at the operated levels. The indirect decompression of the lumbar central and foraminal stenosis was the most likely reason for the patient's relieve of symptoms.

Concerns with stand-alone procedures are compromised fusion rates and possible subsidence of the vertebrae. Therefore, an interbody cage is frequently backed up with anterior or posterior instrumentation to avoid cage displacement and micromotion at the cage-bone interface that may impair bone growth and

Table 2. Summary of studies reported on XLIF for scoliosis

| Author | Procedure | Indication | Anterior levels | Levels | Internal fixation | No. of posterior levels | Total n | Mean follow-up | VAS decrease | Total complications | Transient thigh problems |
|-------------------------------|---------------------|------------|-----------------|--------|-------------------|-------------------------|---------|----------------|--------------|---------------------|--------------------------|
| Anand et al. ² | XLIF, DLIF, AxiaLIF | Scoliosis | 2-6 | T12-S1 | BP | 2-8 | 12 | 75d | 32.4% | 0% | 25% |
| Anand et al. ³ | XLIF, DLIF, AxiaLIF | Scoliosis | 1-6 | T12-S1 | BP | 3-8 | 28 | 22.4mo | 57% | 21.4% | 60.1% |
| Dakwar et al. ¹¹ | XLIF | Scoliosis | 1-6 | T10-L5 | LP | 2-7 | 25 | 11mo | 70.4% | 24% | 12% |
| Tormenti et al. ³⁴ | XLIF, TLIF, PLF | Scoliosis | 2-5 | L1-L5 | BP | 6-12 | 8 | 10.5mo | 60.2% | 150% | 75% |
| Wang et al. ³⁵ | X, DLIF | Scoliosis | 1-5 | T12-L5 | BP | | 23 | 12mo | 54.1% | 30.4% | 30.4% |

eventually provoke endplate failure with subsidence and nonunion. Lateral fixation was not an option in the present case due to the number of levels involved and potential injury to the psoas muscle. Due to our promising previous experience, we decided to proceed with a stand-alone procedure without further instrumentation but with post-operative bracing.

Stand-alone interbody cages allow significantly less range of motion than normal anatomy during all loading modes except axial rotation (32). The standard cage for lateral transpsoas procedures is 18 mm. Steffen et al. have shown that a wider footprint, supported in the periphery of the endplate, is more effective in providing segmental stability, and has a higher axial strength to resist implant subsidence compared to a narrower implant (33). Therefore, we and others (Dr. Luiz Pimenta, personal communication) recommend that a rim-to-rim alignment of 22 mm cages be used in stand-alone procedures to ensure initial stability and avoidance of subsidence (34). Oxland et al. have shown that posterior instrumentation does not enhance stability and interface strength under axial compression (35). Blumenthal et al. reviewed a series of 190 patients in whom cages were used anteriorly as stand-alone devices with a minimum

2-year follow up to determine the revision rate (36). The incidence of reoperation to include supplemental posterior fixation was only 1.1%.

Although it has been shown that supplementation of posterior fixation diminishes residual segmental mobility and preserves lumbar lordosis, the optimal construct and the cage-bone interface mechanics have yet to be determined.

Arvind von Keudell MD

Department of Orthopaedic Surgery, Brigham and Women's Hospital, Harvard University, 75 Francis Street, Boston, MA, United States

Marjan Alimi MD

Roger Härtl MD

Department of Neurological Surgery, Cornell University, 525 East 68th Street, New York, NY, United States

Harry Gebhard MD

Department of Orthopedics and Trauma Surgery, Kantonsspital Baselland, Rheinstrasse 26, CH-4410 Liestal

References

- Schwab F, Dubey A, Gamez L, El Fegoun AB, Hwang K, Pagala M, et al. Adult scoliosis: prevalence, SF-36, and nutritional parameters in an elderly volunteer population. *Spine*. 2005;30(9):1082-5.
- Birknes JK, White AP, Albert TJ, Shaffrey CI, Harrop JS. Adult degenerative scoliosis: a review. *Neurosurgery*. 2008;63(3):94-103.
- Fessler RG, O'Toole JE, Eichholz KM, Perez-Cruet MJ. The development of minimally invasive spine surgery. *Neurosurg Clin N Am*. 2006;17(4):401-9.
- Everett CR, Patel RK. A systematic literature review of nonsurgical treatment in adult scoliosis. *Spine*. 2007;32(19):S130-4.
- Epstein JA, Epstein BS, Jones MD. Symptomatic lumbar scoliosis with degenerative changes in the elderly. *Spine (Phila Pa 1976)*. 1979;4(6):542-7.
- Nachemson A. Adult scoliosis and back pain. *Spine*. 1979;4(6):513-7.
- Carreon LY, Puno RM, Dimar JR, 2nd, Glassman SD, Johnson JR. Perioperative complications of posterior lumbar decompression and arthrodesis in older adults. *J Bone Joint Surg Am*. 2003; 85(11):2089-92.
- Cho KJ, Suk SI, Park SR, Kim JH, Kim SS, Choi WK, et al. Complications in posterior fusion and instrumentation for degenerative lumbar scoliosis. *Spine*. 2007;32(20):2232-7.
- Crandall DG, Revella J. Transforaminal lumbar interbody fusion versus anterior lumbar interbody fusion as an adjunct to posterior instrumented correction of degenerative lumbar scoliosis: three year clinical and radiographic outcomes. *Spine*. 2009;34(20):2126-33.
- Kang BU, Choi WC, Lee SH, Jeon SH, Park JD, Maeng DH, et al. An analysis of general surgery-related complications in a series of 412 minilaparotomic anterior lumbosacral procedures. *J Neurosurg Spine*. 2009;10(1):60-5.
- Marchesi DG, Aebi M. Pedicle fixation devices in the treatment of adult lumbar scoliosis. *Spine*. 1992; 17:304-9.
- Sasso RC, Best NM, Mummaneni PV, Reilly TM, Hussain SM. Analysis of operative complications in a series of 471 anterior lumbar interbody fusion procedures. *Spine*. 2005;30(6):670-4.
- Zurbruggen C, Markwalder TM, Wyss S. Long-term results in patients treated with posterior instrumentation and fusion for degenerative scoliosis of the lumbar spine. *Acta Neurochir (Wien)*. 1999; 141(1):21-6.
- Deyo RA, Cherkin DC, Loeser JD, Bigos SJ, Ciol MA. Morbidity and mortality in association with operations on the lumbar spine. The influence of

- age, diagnosis, and procedure. *J Bone Joint Surg Am.* 1992;74(4):536-43.
15. Glassman SD, Alegre G, Carreon L, Dimar JR, Johnson JR. Perioperative complications of lumbar instrumentation and fusion in patients with diabetes mellitus. *Spine J.* 2003;3(6):496-501.
 16. German JW, Adamo MA, Hoppenot RG, Blossom JH, Nagle HA. Perioperative results following lumbar discectomy: comparison of minimally invasive discectomy and standard microdiscectomy. *Neurosurg Focus.* 2008;25(2):20.
 17. Ozgur BM, Aryan HE, Pimenta L, Taylor WR. Extreme Lateral Interbody Fusion (XLIF): a novel surgical technique for anterior lumbar interbody fusion. *Spine J.* 2006;6(4):435-43.
 18. Benglis DM, Elhammady MS, Levi AD, Vanni S. Minimally invasive anterolateral approaches for the treatment of back pain and adult degenerative deformity. *Neurosurgery.* 2008;63(3):191-6.
 19. Pimenta L, Gharzedine I, Coutinho E, editors. XLIF Approach for the Treatment of Adult Scoliosis: 2-year Follow-up. NASS 22nd Annual Meeting. Austin, Texas: The Spine Journal; 2007.
 20. Pimenta L, Bellera F, Schaffa T, Malcolm J, McAfee P, editors. A new minimally invasive surgical technique for adult lumbar degenerative scoliosis. 11th International Meeting on Advanced Spine Techniques (IMAST). Southampton, Bermuda; 2004.
 21. Rodgers WB, Hyde J, Cohen D, Deviren V, Khajavi K, Peterson M, et al., editors. A Prospective, Multi-Center, Non-Randomized Evaluation of XLIF in the Treatment of Adult Scoliosis: Mid-Term Radiographic Outcomes. NASS 24th Annual Meeting. San Francisco, California: The Spine Journal; 2009.
 22. Anand N, Rosemann R, Khalsa B, Baron EM. Mid-term to long-term clinical and functional outcomes of minimally invasive correction and fusion for adults with scoliosis. *Neurosurg Focus.* 2010;28(3):E6.
 23. Pimenta L. Lateral endoscopic transpsoas retroperitoneal approach for lumbar spine surgery. VIII Brazilian Spine Society Meeting. Brazil: Belo Horizonte, Minas Gerais; 2001.
 24. Anand N, Baron EM, Thaiyananthan G, Khalsa K, Goldstein TB. Minimally invasive multilevel percutaneous correction and fusion for adult lumbar degenerative scoliosis: a technique and feasibility study. *J Spinal Disord Tech.* 2008;21(7):459-67.
 25. Dakwar E, Cardona RF, Smith DA, Uribe JS. Early outcomes and safety of the minimally invasive, lateral retroperitoneal transpsoas approach for adult degenerative scoliosis. *Neurosurg Focus.* 2010;28(3):8.
 26. Tormenti MJ, Maserati MB, Bonfield CM, Okonkwo DO, Kanter AS. Complications and radiographic correction in adult scoliosis following combined transpsoas extreme lateral interbody fusion and posterior pedicle screw instrumentation. *Neurosurg Focus.* 2010;28(3):7.
 27. Wang MY, Mummaneni PV. Minimally invasive surgery for thoracolumbar spinal severe: initial clinical experience with clinical and radiographic outcomes. *Neurosurg Focus.* 2010;28(3):9.
 28. Aebi M. The adult scoliosis. *Eur Spine J.* 2005; 14(10): 925-48.
 29. Rodgers WB, Gerber E, editors. Safety of the Extreme Lateral Interbody Fusion (XLIF) Procedure: Complication Rates in a Series of 300 Surgeries. NASS 23rd Annual Meeting; Toronto, Canada: The Spine Journal; 2008.
 30. Hsieh PC, Koski TR, O'Shaughnessy BA, Sugrue P, Salehi S, Ondra S, et al. Anterior lumbar interbody fusion in comparison with transforaminal lumbar interbody fusion: implications for the restoration of foraminal height, local disc angle, lumbar lordosis, and sagittal balance. *J Neurosurg Spine.* 2007;7(4):379-86.
 31. Inoue S, Watanabe T, Hirose A, Tanaka T, Matsui N, Saegusa O, et al. Anterior discectomy and interbody fusion for lumbar disc herniation. A review of 350 cases. *Clin Orthop Relat Res.* 1984; 183:22-31.
 32. Bozkus H, Chamberlain RH, Perez Garza LE, Crawford NR, Dickman CA. Biomechanical comparison of anterolateral plate, lateral plate, and pedicle screws-rods for enhancing anterolateral lumbar interbody cage stabilization. *Spine (Phila Pa 1976).* 2004;29(6):635-41.
 33. Steffen T, Tsantrizos A, Fruth I, Aebi M. Cages: designs and concepts. *Eur Spine J.* 2000;9:S89-94.
 34. Steffen T, Tsantrizos A, Aebi M. Effect of implant design and endplate preparation on the compressive strength of interbody fusion constructs. *Spine.* 2000; 25(9):1077-84.
 35. Oxland TR, Lund T. Biomechanics of stand-alone cages and cages in combination with posterior fixation: a literature review. *Eur Spine J.* 2000;9: S95-101.
 36. Blumenthal SL, Hisey MS, Ohnmeiss DD. Can threaded fusion cages be used effectively as stand-alone devices? International Society for the Study of the Lumbar Spine; Adelaide, Australia; 2000.