

TECHNICAL NOTE

Plantaris Tendon Autograft Can Restore Patellar Stability in Adolescent Medial Patellofemoral Ligament Reconstruction: A Technical Note

Josip Vlačić, MD, PhD; Mario Josipović, MD, PhD; Dinko Nizić, MD; Marko Simunović, MD, PhD; Zdravko Schauerl, PhD; Mislav Jelić, MD, PhD

Research performed at the Division of Pediatric Orthopedic Surgery, Children's Hospital Zagreb, and Department of Orthopedic Surgery, University Hospital Centre Zagreb

Received: 26 September 2023

Accepted: 2 March 2024

Abstract

Medial patellofemoral ligament reconstruction is a standard treatment option for patients with patellar instability. The main purpose of this study was to determine whether isolated anatomic medial patellofemoral ligament reconstruction using double folded, four-strand plantaris tendon autograft restores patellar stability in adolescent patients. Plantaris tendon autografts were harvested through proximal approach and used in four adolescent patients. A four-strand autograft was prepared in a double-limbed configuration and fixed on the patella and the femur with suture anchors and interference screws, respectively. The mean Kujala score improved significantly from 44 ± 24 SD (range, 19 to 69) points preoperatively to 94 ± 10 SD (range, 78 to 100) points postoperatively ($P < 0.001$). All patients reported excellent subjective outcomes and returned to their pre-injury level of sporting activities. The use of a four-strand plantaris tendon autograft in isolated anatomic medial patellofemoral ligament reconstruction can restore patellar stability in adolescents.

Level of evidence: IV

Keywords: Adolescents, Autograft, Medial patellofemoral ligament reconstruction, Patellar instability, Plantaris tendon

Introduction

The medial patellofemoral ligament (MPFL) has a crucial role in patellofemoral stability. Therefore, a clinical and scientific interest in MPFL reconstruction procedures has been noted.¹⁻⁴ Different anatomic and nonanatomic MPFL reconstruction techniques have been employed in adolescent patients with patellar instability, along with distinct graft options and fixation methods.^{5,6} However, there is no agreement on the ideal graft type for this surgery.⁶ Hamstring and quadriceps tendons are the most frequently used autografts, both with excellent clinical results.^{3,5-8}

Increasing number of primary MPFL reconstructions will invariably lead to more frequent revision procedures in the future.⁹ Index surgeries utilizing autograft harvest leads to more limited choice of autograft harvest sites for the revision surgery.⁹ Therefore, novel autografts should be considered. The plantaris muscle has minimal influence on

knee biomechanics.^{10,11} Since it has the longest tendon in human body and minimal donor site morbidity, its tendon has been broadly used for various ligament reconstructive procedures.^{12,13} However, MPFL reconstruction with plantaris tendon autograft (PLT) has never been reported.

The purpose of this study was to evaluate short-term clinical and subjective outcomes after isolated anatomic MPFL reconstruction using a four-strand PLT autograft in adolescent patients with patellar instability.

Surgical Technique**Patient inclusion**

This study was approved by the independent Ethics Committee of the Children's Hospital Zagreb as a continuous research of doctoral thesis on PLT biomechanical properties already accepted by the Ethics Committee at the University of Zagreb, School of Medicine. More specifically, this study

Corresponding Author: Mislav Jelić, School of Medicine, University of Zagreb, Zagreb, Croatia/ Department of Orthopaedic Surgery, University Hospital Centre Zagreb, Kispaticeva ulica 12, Zagreb, Croatia

Email: mislavorto@gmail.com



THE ONLINE VERSION OF THIS ARTICLE
ABJS.MUMS.AC.IR

investigates PLT autograft clinical application for MPFL reconstruction. All patients underwent isolated anatomic MPFL reconstruction using PLT autograft at a tertiary care orthopaedic facility from March 2019 to January 2021. The procedure was discussed in detail with patients' parents and informed consent was obtained. Clinical and radiographic data of four adolescent patients (three males and one female) were retrospectively analysed.

Despite exhaustive non-surgical management, all patients had persistent symptoms of patellar instability for at least one year prior to surgery and could not perform usual recreational activities. On physical examination, patellar apprehension test was positive during the first 30° of knee flexion, suggesting for MPFL insufficiency. Two radiologists independently evaluated other contributing factors of patellar instability on preoperative magnetic resonance imaging (MRI) scans. In all patients, patellar height and trochlear dysplasia were assessed.^{14,15} Radiologists also confirmed the presence of a plantaris muscle. Therefore, patient history, clinical examination, and described radiographic findings were used as indications for isolated MPFL reconstruction.

Patient outcome scores (Kujala Score and Single Assessment Numeric Evaluation - SANE question) were collected preoperatively and at the most recent follow-up.^{16,17} A successful outcome was rated as a negative patellar apprehension test, improvement in the Kujala score, and the patient's return to pre-injury level of sporting activities. The analysed data were collected from the medical records. The medical history obtained from the both the patients and their parents. The parents of all four patients provided written informed consent for inclusion in the study.

Surgical technique

First, a diagnostic arthroscopy was performed to exclude any intra-articular pathology. Additional pathology encountered in two patients was addressed prior to MPFL reconstruction. One patient had an unstable posterior horn of the lateral meniscus which was stabilized with all-inside suture (Meniscal Cinch™ II, Arthrex, Naples, FL, USA). The second patient had a symptomatic medial parapatellar plica which was excised with a shaver. After completion of the arthroscopic portion of the procedure, attention was turned to the PLT harvest. The PLT was harvested using a standard proximal approach through a small vertical skin incision located 1 cm posterior to the medial border of the tibia, at the junction of the proximal and the middle one-third of the lower leg. After incising the fascia, the PLT was identified using blunt dissection as the only longitudinal tight structure between the soleus and the medial head of the gastrocnemius muscle. The distal myotendinous junction was identified and transected, allowing tendon dissection and harvest with a full-radius tendon stripper distally.¹³ Harvested PLT length was measured. A PLT length of 32 cm or longer was required to create a proper double-looped PLT autograft, [Figure 1]. Previous biomechanical studies showed that a single strand PLT has a limited mean maximal force between 161.5 N and 197.0 N, while mean maximal force of 220.3 N ± 108.1 SD of a two-strand PLT construct was recently reported.¹⁸⁻²⁰ Therefore, a four-strand PLT graft should always exceed previously reported maximal force of the native MPFL of 208 N ± 90 SD.¹ If the harvested PLT was less than 32 cm in length, it was considered to too

short to obtain a sufficiently long double-looped PLT graft. In such cases a gracilis tendon (GT) autograft, to provide adequate graft size, was harvested in a standard fashion via separate skin incision. On a separate table, folded in half PLT graft free ends were whip-stitched with absorbable suture each, [Figure 1]. Following autograft preparation, a 3 cm incision along the medial margin of patella was made. For the patellar-sided fixation of the MPFL graft, two 20 mm sockets were created with a 4.5 mm drill over a 1.4 mm guidewire inserted in the groove (sulcus) in the proximal half of the medial patellar margin.²¹ Two 4.75 mm resorbable knotless anchors (SwiveLock®, Arthrex, Naples, FL, USA) were used to fix both ends of the double-looped PLT graft inside the sockets, [Figure 2].

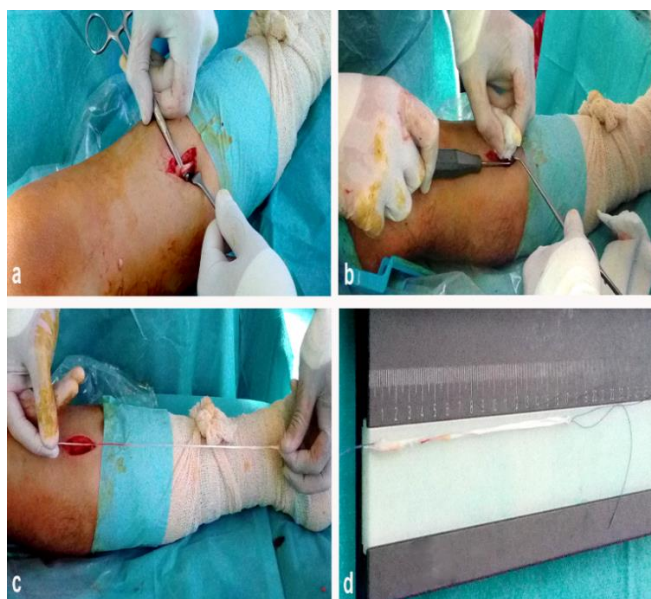


Figure 1. Intraoperative images. a) proximal approach for plantaris tendon harvest; b) plantaris tendon harvesting using a tendon stripper; c) harvested plantaris tendon length compared with a lower leg length; d) 17 cm long double-folded plantaris tendon graft

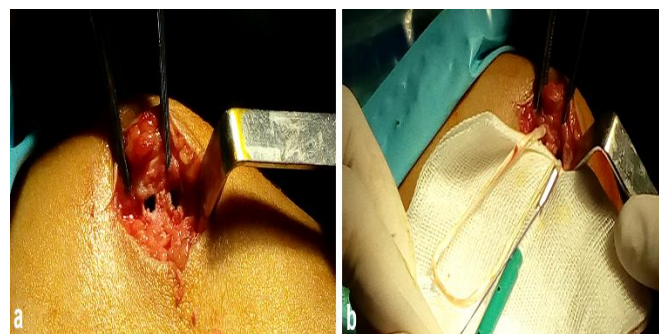

Figure 2. Intraoperative images. a) two 4.5 mm diameter holes are drilled at the proximal one-third of the medial margin of the patella; b) double-strand, plantaris tendon autograft ends are fixed inside the holes with 4.75 mm resorbable knotless anchors (SwiveLock®, Arthrex, Naples, FL, USA)

The anatomic femoral insertion point of the MPFL was identified through a skin incision between the medial femoral epicondyle and the adductor tubercle, according to

the technique described by Schöttle *et al.*, with lateral images obtained under fluoroscopy.²² The femoral tunnel was drilled with a 6.5 mm cannulated drill. The PLT graft was then shuttled between the second and the third layer of the medial knee. The graft was fixed in the femur at 30° of knee flexion using a 6 mm resorbable Interference Screw (BioComposite Interference Screw, Arthrex, Naples FL, USA) allowing lateral patellar translation of one quadrant. This produced a four-strand PLT autograft reconstruction of the native MPFL, [Figure 3].

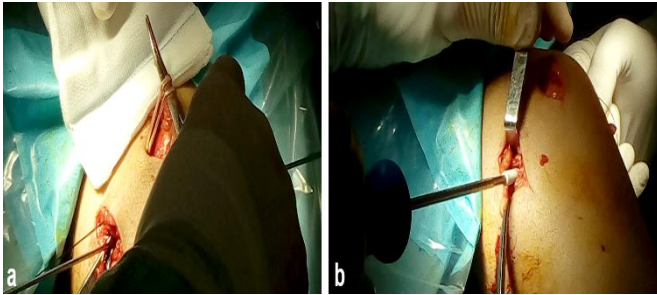


Figure 3. Intraoperative images. a) plantaris tendon autograft shuttled between the second and the third layers of the medial side of the knee and pulled into the femoral tunnel; b) a 6 mm resorbable Interference Screw (BioComposite Interference Screw, Arthrex, Naples, FL, USA) was used to fix the plantaris tendon autograft inside the femur.

Rehabilitation

An extension splint was applied postoperatively for two weeks allowing full weight-bearing. Subsequently, the patient was transitioned to a hinged brace with a weekly increase of 30° of progressive flexion (30° to 60° to 90° to 120°) until complete range of motion (ROM) restoration. Patients were referred for extensive physical therapy and encouraged to ride a stationary bicycle while being restricted from pivoting sports activities. Complete sporting activity, depending on the type of activity and rehabilitation results, was allowed after four to six months.

Clinical Outcome Measures

At final follow-up (18 to 40 months after surgery), the patellar apprehension test was performed as well as functional evaluation of the knee using the Kujala score. Preoperative and postoperative Kujala scores were then compared. Patient satisfaction with the operated knee was also assessed using the SANE question.^{16,17}

Statistical Analysis

Statistical analysis was performed by the statistical package Statistica (TIBCO Software, Inc., Palo Alto, CA, USA). Statistics of descriptive data were calculated by standard formulae (median, range, minimum, and maximum). A paired-samples t-test was performed to compare preoperative and postoperative Kujala scores. A P-value < 0.05 was regarded as statistically significant.

Discussion

However, if a four-strand PLT graft is fixed in a way to allow patella translation of at least one quadrant laterally, the risk of excessive stiffness is reasonably reduced. Still, these

A total of four patients, (three males and one female) with a mean age of 17 years (range: 16 to 18 years) at the time of surgery were included in the study. Clinical data is listed in [Table 1]. Utilizing the modified Insall-Salvati ratio obtained from the MRI scans,¹⁴ patellar height ratios were measured less than 1.5 for all patients. Classification of all trochlea on MRI noted all patients to be Dejour type A or type B¹⁵. No intraoperative complications were reported. All patients had negative patellar apprehension test and returned to pre-injury level of sporting activities with six months postoperatively. One patient had slight discomfort at the PLT donor site that resolved spontaneously five months after surgery. The mean Kujala score improved significantly from 44 ± 24 SD (range, 19 to 69) points preoperatively to 94 ± 10 SD (range, 78 to 100) points postoperatively ($P < 0.001$). Results of subjective patient questionnaires are presented in [Table 2].

This study concludes that utilization of four-strand PLT autograft in anatomic MPFL reconstruction can adequately restore patellar stability in adolescents. Therefore, PLT autograft may be a valuable choice for MPFL reconstruction.

Although PLT autografts have proven to be a reliable tool for various reconstructive procedures in orthopaedics, PLT autograft for MPFL reconstruction has never been reported.^{12,23} However, a recent biomechanical study supports PLT usefulness as a graft for the MPFL reconstruction.²⁰ In MPFL reconstruction, several advantages can be considered for PLT autograft. First, the plantaris muscle has no significant influence on knee biomechanics.^{10,11} Second, its tendon is long, relatively feasible to harvest, and has minimal donor site morbidity.^{12,13} However, potential drawbacks exist regarding plantaris muscle variability and inconstancy and as well as unpredictable PLT harvest length. Therefore, preoperative knee MRI assessment by a trained radiologist is recommended to identify the presence of the plantaris. Also, preoperative lower leg length measurements should be obtained as it positively correlates with PLT length.¹² If harvesting PLT results with a tendon length less than 32 cm, other graft sources should be utilized. The minimum of 32 cm PLT length was set as a cut off value due to the mean MPFL length of 5.7 cm, as reported in a systematic review on MPFL anatomy.²⁴ Previous biomechanical studies showed maximal force of the native MPFL of $208 \text{ N} \pm 90$ SD and maximal force of a two-strand PLT construct $220.3 \text{ N} \pm 108.1$ SD, to guarantee sufficient graft strength we used four-strand PLT autograft.^{1,20} Therefore, PLT at least 32 cm long, used as four-strand autograft, would have enough purchase after being fixed with screws inside all three bone tunnels during MPFL reconstruction in adolescents. It is debatable whether all two-folded PLT grafts for MPFL reconstruction should have enough resistance to ensure patellar stability, without the risk of medial overconstraint of the patellofemoral joint with subsequent risk of early patellofemoral osteoarthritis.

questions should be answered based on further comparative clinical studies.

Table 1. Details of four patients included in this study

Case	Age (years)	Gender	Side	Patellar instability symptoms before surgery (months)	Additional procedures	Current follow-up (months)
1	17	Male	Left	27	None	40
2	17	Female	Right	15	Lateral meniscus posterior horn stabilization	33
3	18	Male	Right	20	None	30
4	16	Male	Right	12	Medial plica excision	18

Table 2. Patients' outcome scores up to latest follow-up. SANE indicates Single Assessment Numeric Evaluation

Case	Kujala score		SANE Question
	Pre-op	Current	Current
1	19	78	100
2	60	99	93
3	69	100	85
4	27	98	95
Median (range, x to y) points	43 (19 to 69)	98 (78 to 100)	94 (85 to 100)

The ideal surgical technique and graft source for adolescent MPFL reconstruction are yet to be established^{5,6,25}. Due to a variety of surgical techniques and fixation methods, focus on optimal graft choice has been investigated³. Due to advantages of autograft use, including ease of graft access, absence of rejection, and faster healing, autograft tendon is considered a preferred graft source for MPFL reconstruction²⁵. Anatomic reconstruction utilizing a double-limbed graft configuration has also been deemed preferable²⁵. Therefore, double-limbed autograft configuration is our institutional preferred choice when performing MPFL reconstruction in adolescents.

In our study, all patients were treated with the same surgical technique for double-limbed anatomic MPFL reconstruction as described by Schöttle *et al.*, with the substitution of a PLT autograft instead of a GT autograft²¹. After a mean follow-up of 30 months, significant improvement in the postoperative Kujala score compared with the preoperative Kujala score was recorded, with a mean increase of 50 points ($P < 0.001$)¹⁶. When assessing patient satisfaction, the SANE outcome question rated excellent for all patients¹⁷. It is encouraging that no poor results were recorded using the four-strand PLT autograft.

Still, hamstring and quadriceps tendons are the most used autografts in adolescent MPFL reconstruction^{3,5,6,9}. Using those grafts in various surgical techniques have presented favourable results in terms of restoring patellar stability^{5,8,9}. However, hamstring autografts are much stronger and stiffer than the native MPFL^{26,27}. In addition, knee flexion weakness can still be noted one year after GT harvesting²⁸. It also has been noted that harvesting a superficial 10 mm wide portion of quadriceps tendon led to significant reduction of tendon's residual tensile strength²⁹. Therefore, careful consideration of autograft sources in adolescent

MPFL reconstruction is needed. Importantly, the hamstrings and quadriceps play significant roles in knee kinematics, therefore utilization of the associated tendons should be employed with caution. Secondly, with the inevitable increase of MPFL reconstruction revisions, alternative autograft sites need to be considered.

There are several limitations of this study. Due to this being a pilot study, there was a small patient cohort. While the average follow up of 30 months only provides medium-term results, all were back to full pre-injury activities. Longer follow up can further elucidate long-term graft viability, failure rates, and development of postoperative patellofemoral arthrosis. Also, the outcomes presented were through subjective tests and without radiological postoperative assessment of patellofemoral joint. Therefore, we cannot give definitive remarks regarding the safety and efficacy of this procedure. Other limitations include the absence of Lysholm and Tegner questionnaires as well as lack of ROM measurements to determine objective functional outcomes. Other limitations are plantaris muscle inconstancy and uncertainty to obtain sufficient PLT length for a proper four-strand PLT autograft. Finally, a biomechanical evaluation of this technique is not given. Instead, data from other PLT biomechanical studies are used and inferred. However, this study sets proof of concept for a new autograft in adolescent anatomic MPFL reconstruction.

An anatomic isolated MPFL reconstruction in adolescents using a four-strand PLT autograft restored patellar stability. Therefore, PLT autograft can be acknowledged as a viable option for anatomic MPFL reconstruction. However, further long-term comparative studies are needed to validate the broad application of such an approach and to document its outcome superiority over currently used strategies.

Acknowledgement

The authors would like to thank to Ivan Budelic, MD for taking pictures during surgery, Carlo Camathias, MD for reviewing the manuscript, and Martin J. Morrison, III, MD for language editing.

Conflict of interest: None

Funding: None

Josip Vlaic MD, PhD ^{1,2}

Mario Josipovic MD, PhD ^{2,3}

Dinko Nizic MD ⁴

Marko Simunovic MD, PhD ⁵

Zdravko Schauerl PhD ⁶

Mislav Jelic MD, PhD ^{2,3}

1 Division of Paediatric Orthopaedic Surgery, Children's Hospital Zagreb, Zagreb, Croatia

2 School of Medicine, University of Zagreb, Zagreb, Croatia

3 Department of Orthopaedic Surgery, University Hospital Centre Zagreb, Zagreb, Croatia

4 Department of Radiology and Ultrasound Diagnostics, Special Hospital for Pulmonary Diseases, Zagreb, Croatia

5 Department of Radiology, University Hospital Centre Zagreb, Zagreb, Croatia

6 Department of Materials, Faculty of Mechanical Engineering and Naval Architecture, University of Zagreb, Zagreb, Croatia

References

1. Mounthey J, Senavongse W, Amis AA, Thomas NP. Tensile strength of the medial patellofemoral ligament before and after repair or reconstruction. *J Bone Joint Surg Br.* 2005; 87:36-40.
2. Yeung M, Leblanc MC, Ayeni OR, et al. Indications for Medial Patellofemoral Ligament Reconstruction: A Systematic Review. *J Knee Surg.* 2016; 29:543-554. doi: 10.1055/s-0035-1564730.
3. McNeilan RJ, Everhart JS, Mescher PK, Abouljoud M, Magnussen RA, Flanigan DC. Graft choice in isolated medial patellofemoral ligament reconstruction: a systematic review with meta-analysis of rates of recurrent instability and patient-reported outcomes for autograft, allograft, and synthetic options. *Arthroscopy.* 2018; 34:1340-1354. doi: 10.1016/j.arthro.2017.11.027.
4. Sidharthan S, Wang G, Schlichte LM, Fulkerson JP, Green DW. Medial Patellofemoral Ligament Reconstruction in Skeletally Immature Patients. *JBJS Essent Surg Tech.* 2020; 10:1-3. doi: 10.2106/JBJS.ST.18.00110.
5. VandenBerg CD, Sarkisova N, Pace JL, et al. Current practice trends in the surgical management of patellofemoral instability: a survey of the Paediatric Research in Sports Medicine (PRISM) Society. *J Child Orthop.* 2021; 15:571-576. doi: 10.1302/1863-2548.15.210084.
6. Migliorini F, Maffulli N, Bell A, Betsch M Outcomes, return to sport, and failures of MPFL reconstruction using autografts in children and adolescents with recurrent patellofemoral instability: A systematic review. *Children (Basel).* 2022; 9:1892. doi: 10.3390/children9121892.
7. Schepsis AA, Rogers AJ. Medial patellofemoral ligament reconstruction: indications and technique. *Sports Med Arthrosc Rev.* 2012; 20:162-170. doi: 10.1097/JSA.0b013e318264188b.
8. Gfoller P, Hoser C, Runer A, Abermann E, Wierer G, Fink C. Medial patellofemoral ligament (MPFL) reconstruction using quadriceps tendon autograft provides good clinical, functional and patient-reported outcome measurements (PROM): a 2-year prospective study. *Knee Surg Sports Traumatol Arthrosc.* 2019; 27:2426-2432. doi: 10.1007/s00167-018-5226-6.
9. Sanchis-Alfonso V, Montesinos-Berry E, Ramirez-Fuentes C, Leal-Blanquet J, Gelber PE, Monllau JC. Failed medial patellofemoral ligament reconstruction: Causes and surgical strategies. *World J Orthop* 2017; 8:115-129. doi:10.5312/wjo.v8.i2.115
10. Schöttle P, Schmeling A, Romero J, Weiler A. Anatomical reconstruction of the medial patellofemoral ligament using a free gracilis autograft. *Arch Orthop Trauma Surg.* 2009; 129:305-309. doi: 10.1007/s00402-008-0712-9.
11. Silver RL, de la Garza J, Rang M. The myth of muscle balance. A study of relative strengths and excursions of normal muscles about the foot and ankle. *J Bone Joint Surg Br.* 1985; 67:432-437. doi: 10.1302/0301-620X.67B3.3997956.
12. Spina AA. The plantaris muscle: anatomy, injury, imaging, and treatment. *J Can Chiropr Assoc.* 2007; 51:158-165.
13. Vlaic J, Josipovic M, Bohacek I, Jelic M. The plantaris muscle: too important to be forgotten. A review of evolution, anatomy, clinical implications and biomechanical properties. 2019; 59:839-845. doi: 10.23736/S0022-4707.18.08816-3.
14. Pagenstert GI, Hintermann B. Proximal mini-invasive grafting of plantaris tendon. In: Easley ME, Wiesel SW, editors. *Operative Techniques in Foot and Ankle Surgery*, Philadelphia: Lippincott Williams & Wilkins, a Wolters Kluwer business; 2011.
15. Miller TT, Staron RB, Feldman F. Patellar height on sagittal MR imaging of the knee. *AJR Am J Roentgenol.* 1996; 167:339-341. doi: 10.2214/ajr.167.2.8686598.
16. Dejour DH. The patellofemoral joint and its historical roots: the Lyon School of Knee Surgery. *Knee Surg Sports Traumatol Arthrosc.* 2013; 21:1482-1494. doi: 10.1007/s00167-012-2331-9.
17. Kujala UM, Jaakkola LH, Koskinen SK, Taimela S, Hurme M, Nelimarkka O. Scoring of patellofemoral disorders. *Arthroscopy.* 1993; 9:159-163. doi: 10.1016/s0749-8063(05)80366-4.
18. O'Connor CM, Ring D. Correlation of single assessment numeric evaluation (SANE) with other patient reported outcome measures (PROMs). *Arch Bone Jt Surg.* 2019; 7:303-306.
19. Zarzycki W, Mazurkiewicz S, Wisniewski P. Research on strength of the grafts that are used in anterior cruciate ligament reconstruction. *Pol Orthop Traumatol.* 1999; 64:293-302.
20. Bohnsack M, Surie B, Kirsch IL, Wulker N. Biomechanical properties of commonly used autogenous transplants in the surgical treatment of chronic lateral ankle instability. *Foot Ankle Int.* 2002; 23:661-664. doi: 10.1177/107110070202300714.
21. Vlaic J, Josipovic M, Bohacek I, et al. Plantaris tendon is valuable graft for the medial patellofemoral ligament reconstruction: A biomechanical study. *Knee.* 2022; 38:212-219. doi: 10.1016/j.knee.2022.08.016.
22. Schöttle PB, Schmeling A, Rosenstiel N, Weiler A. Radiographic landmarks for femoral tunnel placement in medial patellofemoral

- ligament reconstruction. *Am J Sports Med.* 2007; 35:801-804. doi: 10.1177/0363546506296415.
23. Josipović M, Vlaić J, Serdar J, et al. Plantaris tendon: a novel graft for anterolateral ligament reconstruction and additional reinforcement for anterior cruciate ligament autografts in combined reconstructive procedures *Knee Surg Sports Traumatol Arthrosc.* 2020; 28:2604-2608. doi: 10.1007/s00167-020-05885-x.
24. Placella G, Tei M, Sebastiani E, et al. Anatomy of the medial patello-femoral ligament: a systematic review of the last 20 years literature. *Musculoskelet Surg.* 2015; 99:93-103. doi: 10.1007/s12306-014-0335-y.
25. Weinberger JM, Fabricant PD, Taylor SA, Mei JY, Jones KJ. Influence of graft source and configuration on revision rate and patient-reported outcomes after MPFL reconstruction: a systematic review and meta-analysis. *Knee Surg Sports Traumatol Arthrosc.* 2017; 25:2511-2519. doi: 10.1007/s00167-016-4006-4.
26. Arendt EA. Anatomy and biomechanics of the patellar ligaments. *Tecniche Chirurgiche in Ortopedia E Traumatologia.* 2007; 5:13-18.
27. Zaffagnini S, Marcheggiani Muccioli GM, Grassi A, Bonanzinga T, Marcacci M. Minimally invasive medial patellofemoral ligament reconstruction with fascia lata allograft: surgical technique. *Knee Surg Sports Traumatol Arthrosc.* 2014; 22:2426-2430. doi: 10.1007/s00167-014-2940-6.
28. Nordin JS, Olsson O, Lunsjo K. The gracilis tendon autograft is a safe choice for orthopedic reconstructive procedures: a consecutive case series studying the effects of tendon harvesting. *BMC Musculoskelet Disord.* 2019; 20:138. doi: 10.1186/s12891-019-2520-5.
29. Adams DJ, Mazzocca AD, Fulkerson JP. Residual strength of the quadriceps versus patellar tendon after harvesting a central free tendon graft. *Arthroscopy.* 2006; 22:76-79. doi: 10.1016/j.arthro.2005.10.015.