

**CASE REPORT**

# Simultaneous Middle Third Clavicle Fracture and Type 3 Acromioclavicular Joint Dislocation; A Case Report

Saeed Solooki, MD; Ali Azad, MD

*Research performed at Bone and Joint Disease Research Center of Shiraz University of Medical Sciences, Shiraz, Iran**Received: 1 January 2014**Accepted: 16 February 2014***Abstract**

Simultaneous middle third clavicle fracture and acromioclavicular joint dislocation is a rare combination injury, as a result of high-energy trauma. We report a patient with a middle third clavicle fracture and ipsilateral grade three-acromioclavicular joint dislocation, which is a rare combination. The patient wanted to get back to work as soon as possible, so the fracture was fixed with reconstruction plate after open reduction and plate contouring; and acromioclavicular joint dislocation was reduced and fixed with two full threaded cancellous screws. One screw was inserted through the plate to the coracoid process. Clinical and radiographic finding revealed complete union of clavicle fracture and anatomical reduction of acromioclavicular joint with pain free full joint range of motion one year after operation.

**Key words:** Acromioclavicular joint dislocation, Middle third clavicle fracture  
Level of evidence: IV

**Introduction**

Middle third clavicle fracture is a common injury as a result of falling down. Another injury occurred during falling down is acromioclavicular joint dislocation. Both injuries simultaneously, occur as a result of higher energy trauma such as car accidents rarely (1, 2, 3).

Acromioclavicular joint dislocation is classified as six types according to Rockwood classification, which has been used widely (4).

We report a middle third clavicle fracture and ipsilateral type three acromioclavicular joint dislocation that is a rare combination.

**Case report**

A 40-year-old farmer man brought to our orthopedic department after car turn over. He presented with marked ecchymosis, swelling, and tenderness at the mid-clavicle and a prominent distal end of the clavicle and was not able to use his shoulder. Clinical and radiographic finding revealed a fracture of middle third clavicle and acromioclavicular joint dislocation (Figure 1). Other physical examination such as neurologic and vascular examination was normal. There was not any other injury or fracture. We decided to operate and fixed both clavicle fracture and acromioclavicular joint dislocation because of the patient's job and he wanted to get back to hard

work as soon as possible. The clavicle fracture caused pressure on the skin above. After preparing and draping under general anesthesia in beach chair position through transverse incision at the superior border of the clavicle toward acromioclavicular joint, proximal and distal part of fracture were exposed. After reduction, fixation was performed with a 3.5 reconstruction plate with contouring the plate. We stabilized the acromioclavicular joint without exploring the joint and coracoclavicular ligament with two full threaded cancellous screws. One screw was inserted through the plate to coracoid process in order to have a more stable fixation (Figure 2). We placed patient's shoulder in an arm sling for four weeks after operation. Patient was encouraged to do gentle range of motion of elbow joint and pendulum exercise of shoulder the day after operation. He was allowed to do light works after four to 12 weeks. We did not let patient come back to his work before 12 weeks. The patient was followed at two and six weeks, three and one year. Union occurred 3 months postoperatively. Clinical and radiographic finding revealed complete union of clavicle fracture and anatomical reduction of acromioclavicular joint with pain free full joint range of motion after one year. Figure 3 shows complete union of clavicle fracture.

**Discussion**

Although fracture of clavicle and acromioclavicular

**Corresponding Author:** Ali Azad, Shiraz Medical School, Bone and Joint Disease Research Center, Shiraz University of Medical Sciences, Shiraz, Iran.  
Email: Aliazadmd@gmail.com



THE ONLINE VERSION OF THIS ARTICLE  
ABJS.MUMS.AC.IR

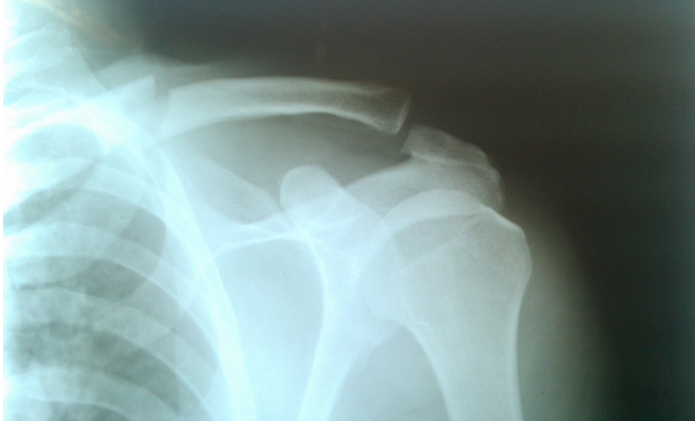

Figure 1. Pre operation x ray showing middle third clavicle fracture along with acromioclavicular joint dislocation.

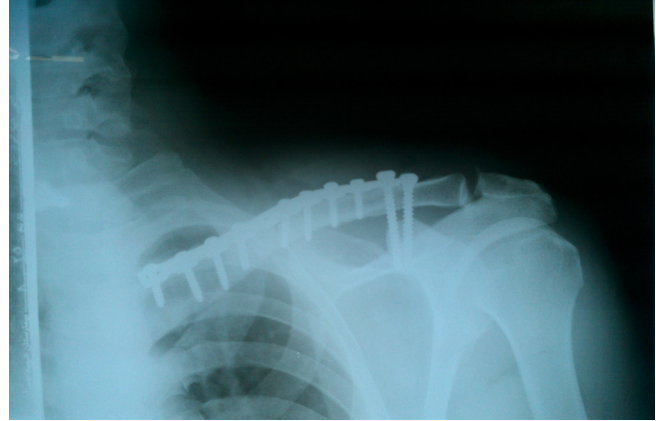


Figure 2. Intra-operative radiography showing the fixation of clavicle using 3.5 reconstruction plate and reduction of acromioclavicular joint using two cancellous screws introduced into coracoid.

joint dislocation is common separately but both injuries at the same time is rare and it needs higher energy trauma (1, 2).

After literature review we found only seven articles that presented ten patients with this combined injury (3, 5-10).

In 1990 Lancourt *et al* reported a case of 19 year old horseback rider with this combination injury. They treated the acromioclavicular joint dislocation only with two Steinman pin with good result (5).

In 1992 Wurtz *et al* reported four cases of simultaneous clavicle fracture and AC joint dislocation. They treated two of the patients with coracoclavicular screw and one patient with Steinman pin with good result. Another patient was treated conservatively (7).

In 1995 Heinz *et al* reported a case with the same problem that was treated conservatively with good outcome (3).

In 2004 Wisniewski reported a 32 year old patient with both posterior dislocation of AC joint and clavicle fracture. He did not open the clavicle, but the AC joint was reduced and fixed with k wires (6).

Yeh and his colleagues reported another case in 2009.

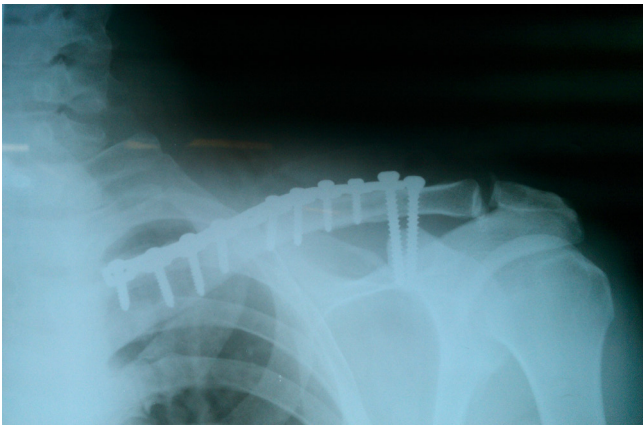


Figure 3. One year post operation x ray showing complete union.

The case was a 46 years old lady who was thrown from a horse. They fixed the clavicle with locking plate. Acromioclavicular and coracoclavicular ligament were reconstructed with semitendinosus allograft. This kind of fixation is a new method of fixation and their results were very good (8).

In 2011 Psarakis *et al* presented a 38 years old man who was involved in car accident with the same combination injury. They fixed the clavicle with locking plate and AC joint with Tightrope fixation system, which is a new method of fixation with perfect result (9).

Woolf and his colleagues published an article in 2013 presenting another combination injury. They chose internal fixation for both clavicle and AC joint dislocation with final good result (10).

The treatment of choice for acromioclavicular joint dislocation still is unclear. We decided to fix the clavicle fracture because the fracture caused pressure on the skin above. Acromioclavicular joint was reduced and fixed with two full threaded cancellous screws. One screw was inserted through the plate to get a more stable fixation. The result was very pleasant. Moreover the patient denied removing the coracoclavicular screws. He had pain free full range of motion after one year and could come back to his work soon.

The combination of mid third clavicle fracture and acromioclavicular joint dislocation is rare with several treatment methods. Our study revealed that fixation of the clavicle with a reconstruction plate and acromioclavicular joint with two full threaded cancellous screws lead to good clinical result; also this method is cheaper and more available.

Saeed Solooki MD  
Ali Azad MD

Shiraz Medical School, Bone and Joint Disease Research Center, Shiraz University of Medical Sciences, Shiraz, Iran

---

**References**

---

1. Zlowodzki M, Zelle BA, Cole PA, Jeray K, McKee MD. Treatment of acute midshaft clavicle fractures: systematic review of 2144 fractures: on behalf of the Evidence-Based Orthopaedic Trauma Working Group. *J Orthop Trauma*. 2005;19(7):504-7.
2. Wellmann M, Smith T. Epidemiology, anatomy, biomechanics and imaging of acromioclavicular joint injuries. *Unfallchirurg*. 2012;115(10):867-71.
3. Heinz WM, Misamore GW. Mid-shaft fracture of the clavicle with grade III acromioclavicular separation. *J Shoulder Elbow Surg*. 1995;4:141-2.
4. Williams GR, Nguyen VD, Rockwood CR. Classification and radiographic analysis of acromioclavicular dislocations. *ApplRadiol*. 1989; 12:29-34.
5. Lancourt JE. Acromioclavicular dislocation with adjacent clavicular fracture in a horseback rider. *Am J Sports Med*. 1990; 18(3):321-2.
6. Wisniewski TF. Posterior acromioclavicular dislocation with clavicular fracture and trapezius entrapment. *Eur J Trauma*. 2004; 30(2):120-3.
7. Wurtz LD, Lyons FA, Rockwood CA. Fracture of the middle third of the clavicle and dislocation of the acromioclavicular joint. A report of four cases. *J Bone Joint Surg Am*. 1992; 74:133-7.
8. Yeh PC, Miller SR, Cunningham JG, Sethi PM. Midshaft clavicle fracture and acromioclavicular dislocation: a case report of a rare injury. *J Shoulder Elbow Surg*. 2009;18(5):1-4.
9. Psarakis SA, Savvidou OD, Voyaki SM, Beltsios M, Kouvaras JN. A rare injury of ipsilateral mid-third clavicle fracture with acromioclavicular joint dislocation. *Hand (N Y)*. 2011; 6(2): 228-32.
10. Woolf SK, Valentine BJ, Barfield WR, Hartsock LA. Middle-third clavicle fracture with associated type IV acromioclavicular separation: case report and literature review. *J Surg Orthop Adv*. 2013;22:183-6.