

**SHORT COMMUNICATION****Elbow Arthroplasty: A Concise Literature Update**

E. Carlos Rodriguez-Merchan, MD, PhD; Amir R. Kachooei, MD, PhD; Eloy Tabeayo, MD

*Research performed at the Departments of Orthopedic Surgery, La Paz University Hospital, Madrid Spain; and Montefiore Medical Center Bronx, NY, USA*

Received: 5 March 2023

Accepted: 14 May 2023

**Abstract**

Total elbow arthroplasty (TEA) is increasingly used, especially in patients with rheumatoid arthritis (RA) and distal humerus fractures (DHF). This narrative review of the recent literature published in 2022 reached the following conclusions: 1) Age greater than 80 is not a contraindication for TEA. 2) The estimated 10-year survival reported for linked TEAs is 92%, and unlinked TEAs 84%. 3) For DHFs in the elderly, regarding the flexion/extension arc, TEA gives substantially better results than open reduction and internal fixation (ORIF). The reoperation and elbow stiffness rates are substantially lower in TEA than in ORIF. 4) Comparing distal humeral hemiarthroplasty (DHH) vs. TEA in individuals over 65 years with a non-reconstructable DHF favors DHH regarding the range of motion but with a similarly high rate of adverse events in the two surgical techniques. 5) The rate of eradication of periprosthetic joint infection (PJI) is 69-76% with two-stage, 71% with resection arthroplasty, 67% with one-stage, 58% with DAIR, and 40% with elbow arthrodesis.

**Level of evidence:** III**Keywords:** Complications, Distal humeral fractures, Elbow, Results, Rheumatoid arthritis, Survival,

Total elbow arthroplasty

**Introduction**

**T**otal elbow arthroplasty (TEA) is a surgical technique that is increasingly used, especially in patients with rheumatoid arthritis (RA) and distal humerus fractures (DHF).<sup>1</sup>

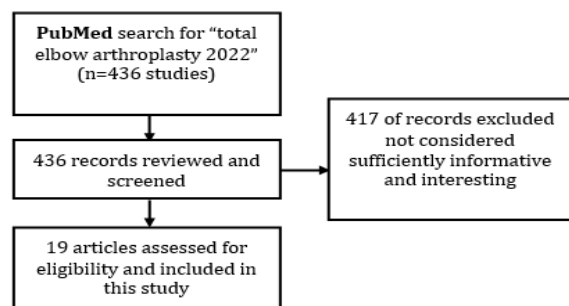
In a systematic review published in 2021 by Davey et al, the rates of aseptic loosening, periprosthetic joint infection (PJI), implant dislocation, and nerve injury were 12.9%, 3.3%, 4.2%, and 2.1%, respectively. The overall complication and revision rates were 16.3% and 14.6%, respectively. It was concluded that TEA offered individuals satisfactory clinical results at long-run follow-up, with relatively stable revision and complication rates compared to short and medium term.<sup>2</sup>

This narrative literature review aims to synthesize and analyze the most interesting and informative articles on TEA published in 2022.

**Main body**

On February 7, 2023, a literature search was performed in

PubMed for articles published in 2022 on TEA using the keywords "total elbow arthroplasty 2022". [Figure 1] shows the flow chart of our search strategy.



**Figure 1.** Flow chart of our search strategy regarding total elbow arthroplasty (TEA) in the year 2022. The authors (ECR-M) reviewed the 436 articles and then chose 19 articles because they thought that they were the most informative and interesting

**Corresponding Author:** E. Carlos Rodriguez-Merchan, Department of Orthopedic Surgery, La Paz University Hospital, Madrid, Spain

Email: ecrmerchan@hotmail.com



THE ONLINE VERSION OF THIS ARTICLE  
ABJS.MUMS.AC.IR

The main results on elbow arthroplasty published in 2022 are shown in [Table 1].<sup>1, 3-20</sup> [Figures 2, 3, 4 and 7]

show some clinical cases of TEA. [Figures 5 and 6] show two types of prosthetic designs.

**Table 1. Most important information on elbow arthroplasty published in 2022**

AUTHORS [REFERENCE]	YEAR	TYPE OF STUDY	MATERIALS AND METHODS	RESULTS
Gambhir et al. <sup>1</sup>	2022	TEA: Elective vs. traumatic cases	In a retrospective study, Gambhir et al. compared the 90-day complication percentages of primary TEA for osteoarthritis (primary-OA; RA) versus those for DHFs.	Compared to the TEA-DHF (n = 19) and TEA-OA (n = 14) cohorts, the RA (n = 16) cohort had higher rates of all-cause adverse events and ulnar nerve palsy. There were no substantial differences between cohorts in readmissions or secondary interventions. The 90-day complication/readmission percentages of TEA carried out for DHFs were lower than those performed for OA and RA. <sup>1</sup>
Seok et al. <sup>3</sup>	2022	TEA vs. ORIF in the elderly	Retrospective assessment of 44 individuals (50 TEAs) aged 60 years or older with distal humeral fractures treated with either ORIF or TEA after a mean follow-up of 51 months.	In terms of the flexion/extension arc, TEA gave substantially better results than ORIF in distal humeral fractures in the elderly. The reoperation and elbow stiffness rates were substantially lower in the TEA cohort than in the ORIF cohort.
Meijering et al. <sup>4</sup>	2022	Latitude TEA (Tornier Surgical Implants, Stafford, TX, USA) is a third-generation implant created to reestablish the natural anatomy of the elbow.	This is a retrospective assessment of 44 individuals (50 TEAs) after a mean follow-up of 51 months.	Kaplan-Meier survival analysis demonstrated a 10-year survival rate of 82% after the procedure. The mean age at the time of surgery was 65 years (range, 28-87 years). The main indication for surgery was inflammatory arthritis. The leading cause of revision was aseptic loosening. Radial head dissociation was encountered in 8 patients (24%), but none complained.
Bhat et al. <sup>5</sup>	2022	Latitude TEAs	These authors reported the mid-term functional results, radiological findings, adverse events, and survivorship of 13 Latitude TEAs. There were 10 females, mean age of 72 years and varying indications. The mean follow-up was 5.9 years.	The functional scores and the range of motion improved. There was one reoperation for a deep infection. No radiologic signs of loosening were seen.
Morrey et al. <sup>6</sup>	2022	Nexel TEA	These authors reported the results of 35 primary Nexel TEAs (Zimmer Biomet, Warsaw, IN, USA) implanted over three years with varying indications.	Twelve elbows (1/3) required revision surgery to remove a part or all components at an average of 2.2 years. All revision surgeries revealed gross loosening of the component(s). Metallic debris and periprosthetic fractures were present in 45% and 50% of cases, respectively. Humeral component loosening and periprosthetic fractures were found in 2 and 4 elbows, respectively. Overall, 17 of 35 (50%) elbows experienced reoperation, and 20 of 35 (60%) elbows had at least one postoperative adverse event.
Evans et al. <sup>7</sup>	2022	Survivorship of TEA	These authors analyzed the longevity and long-term function of TEA in a systematic review and meta-analysis of case-series and national registry reports with more than 10 years of follow-up. They surveyed 628 linked TEAs and 610 unlinked TEAs.	The studied population was treated for RA in over 90% of cases. The estimated 10-year survival for linked TEAs was 92% and unlinked TEAs 84%. <sup>7</sup>
Patrick et al. <sup>8</sup>	2022	TEA for acute DHFs	These authors reported that fellowship training did impact the surgical decision-making process for managing distal humerus fractures. Hand and Upper Extremity surgeons carried out the greatest number of TEA for acute DHFs, followed by Shoulder and Elbow surgeons.	Trauma surgeons carried out the lowest proportion of TEA to ORIF.

Table 1. Continued

Stone et al. <sup>9</sup>	2022	TEA for acute DHFs	These authors reported short to medium-term results	They demonstrated both DHH and TEA were valuable alternatives.
Burden et al. <sup>10</sup>	2022	TEA for acute DHFs	These authors compared DHH vs. TEA in individuals aged over 65 years with a non-reconstructable DHF.	Their results indicated PROMs and ROM mostly favored DHH.
Leschinger et al. <sup>11</sup>	2022	TEA for acute DHFs	These authors stated that good to very good clinical results could be achieved in older individuals with DHFs using TEA	A secondary TEA is also feasible after primary conservative treatment.
Calderazzi et al. <sup>12</sup>	2022	TEA for acute DHFs	These authors reported that the concurrent fracture of one or both epicondyles is commonly associated with severe joint comminutions and makes ORIF more demanding.	In these individuals, primary TEA could be a reasonable management alternative.
Aliyev et al. <sup>13</sup>	2022	Morrey TEA in young patients with posttraumatic sequelae	These authors assessed the clinical and radiological results of TEA for trauma sequelae in 63 individuals below 45 years of age. The mean follow-up was 5.2 years.	Adverse events were found in 16 (33%) individuals. Among them, 10 individuals (20%) needed revision TEA. Of the 10 individuals needing revision TEA, in 3 it was due to aseptic loosening, in 6 it was due to PJI and in 1 it was due to component disconnection. The overall 5-year implant survival rate was 79%, and the 10-year survival rate was 78%. TEA permitted the re-establishment of the full ROM in the elbow joint and substantially ameliorated upper extremity function in most individuals. Nevertheless, the low survival rate of TEA and the high prevalence of adverse events do not allow TEA to become a routine procedure for managing posttraumatic sequelae in young individuals.
Gupta et al. <sup>14</sup>	2022	TEA in octogenarians (age greater than 80)	These authors analyzed whether octogenarians undergoing TEA are at augmented risk of postoperative adverse events relative to the younger geriatric population. A national database was analyzed to identify TEA individuals. Patients were categorized into an aged 65 to 79 group and an aged 80 to 89 group.	The two groups had no differences in mortality, readmission, and reoperation. Age greater than 80 should not be utilized as an independent factor when assessing whether a geriatric individual is an adequate candidate for TEA.
Tai et al. <sup>15</sup>	2022	DAIR for PJI	These authors analyzed the results of DAIR and studied risk factors for failure. A retrospective cohort study of 26 individuals 18 years or older diagnosed with elbow PJI and treated with DAIR followed by long-term systemic antimicrobial therapy.	DAIR failed in 17 individuals with elbow PJI with a failure rate of 65% at two years. The mean time to failure from DAIR was 43 days. Tai et al. found that DAIR failed in all individuals with sinus tracts or negative cultures. The cohort with good results had a shorter mean duration of symptoms (5 vs. 18 days) and a higher proportion of monomicrobial infections (59% vs. 89%) than those with unfavorable results.
Mercurio et al. <sup>16</sup>	2022	Revision TEA for PJI	In a systematic review with level IV of evidence, these authors analyzed the results of revision surgery after PJI of the elbow. Staphylococcus aureus was the most frequent microorganism (40%).	The Coonrad-Morrey TEA (Zimmer Biomet, Warsaw, IN, USA) represented 41% of the infected implant and the most frequent design utilized for the PJI revision TEA. Two-stage revision and DAIR were the most frequent procedures carried out for PJI of the elbow, and, on the whole, they represented 36 and 33%, respectively. The eradication rate was 76% with two-stage, 71% with resection arthroplasty, 67% with one-stage, 58% with DAIR, and 40% with elbow arthrodesis. DAIR exhibited a substantially lower eradication rate than the two-stage. Reoperations happened in 40% of individuals after elbow arthrodesis, 33% after one stage, 27% after DAIR and resection arthroplasty, and 24% after two-stage. Conversion to amputation happened in 2.2% of individuals after resection arthroplasty and 1% after DAIR. In conclusion, two-stage revision and DAIR were the most frequent procedures to treat PJI; however, the former exhibited a substantially higher eradication rate. Resection arthroplasty showed a high eradication rate, but postoperative lower clinical and functional results limit the indications for this procedure. One-stage procedure exhibited a limited role in the current practice of PJI management.

Table 1. Continued				
Martinez-Catalan et al. <sup>17</sup>	2022	Revision TEA for PJI	Two-stage reimplantation for PJI after TEA.	These authors found two-stage reimplantation for PJI after TEA successfully eradicated deep infection in 69% of cases.
Kwak et al. <sup>18</sup>	2022	Revision TEA for PJI	These authors found that in individuals with chronic and deep infection of TEA, two-stage revision can be a reasonable alternative for eradicating the infection, alleviating pain, and reestablishing joint function.	The high percentage of second revisions due to bone and soft-tissue deficits remains a challenge.
Laumonerie et al. <sup>19</sup>	2022	Revision TEA for massive bone loss	According these authors, revision of a loose TEA is difficult, mainly in the setting of massive bone loss. They stated that elbow reconstruction utilizing an APC was a viable alternative for individuals with a massive bone loss after TEA.	Despite a relatively high rate of adverse events, the mid-term functional results were satisfactory, with no revisions needed. Between 2009 and 2018, 6 APCs implanted with a semi-constrained Coonrad Morrey prosthesis were carried out in 5 women and 1 man. Median patient age was 70 years.
Hill et al. <sup>20</sup>	2022	Proximal ulnar deficiency after revision TEA: Radial forearm vascularized osteomuscular flap	These authors reported a 61-year-old woman that presented with a failed proximal ulna allograft-prosthetic composite following revision TEA.	The ulnar deficiency was solved utilizing an osteomuscular flap from the distal radius pedicled on the radial artery. This technique offered an alternative option for the problem of a failed TEA with ulnar bone loss.

TEA, total elbow arthroplasty; OA, osteoarthritis; RA, rheumatoid arthritis; DHFs, distal humerus fractures; ORIF, open reduction and internal fixation; DHH, distal humeral hemiarthroplasty; PROMs, patient-reported outcomes; ROM, range of movement; PJI, periprosthetic joint infection; DAIR, debridement antibiotics and implant retention; APC, allograft prosthetic composite.

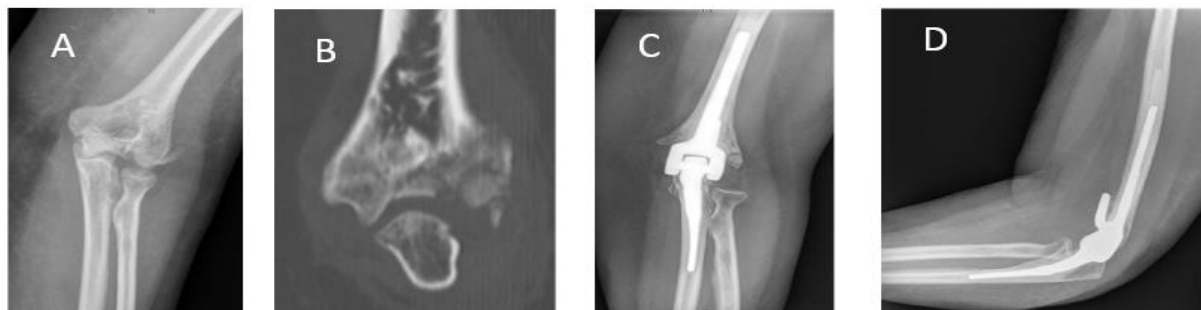

Figure 2. 69-year-old female with a comminuted, displaced, distal humerus fracture. Due to the fracture pattern, reconstruction was deemed impossible during surgery, and therefore patient underwent total elbow arthroplasty (TEA): (A-B) preoperative views; (C-D) postoperative radiographs

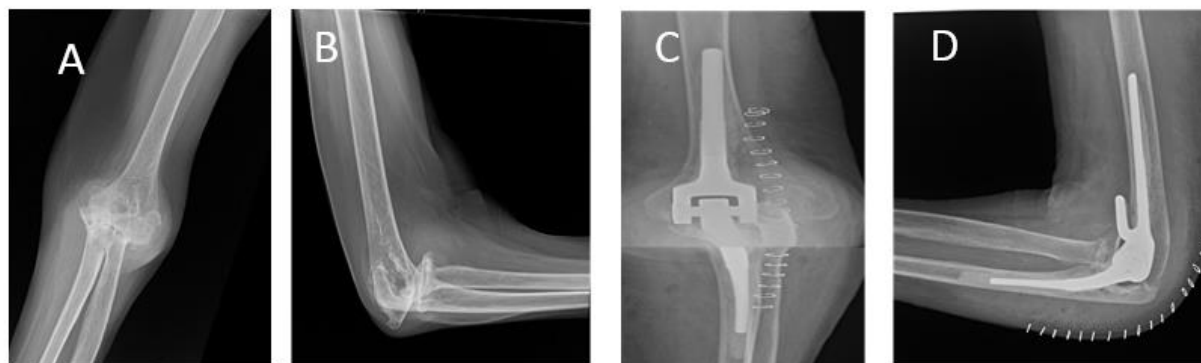


Figure 3. 75-year-old female with a long history of elbow pain in a setting of rheumatoid arthritis, not responding to conservative measures. The patient underwent uncomplicated total elbow arthroplasty (TEA): (A-B) preoperative radiographs; (C-D) postoperative views

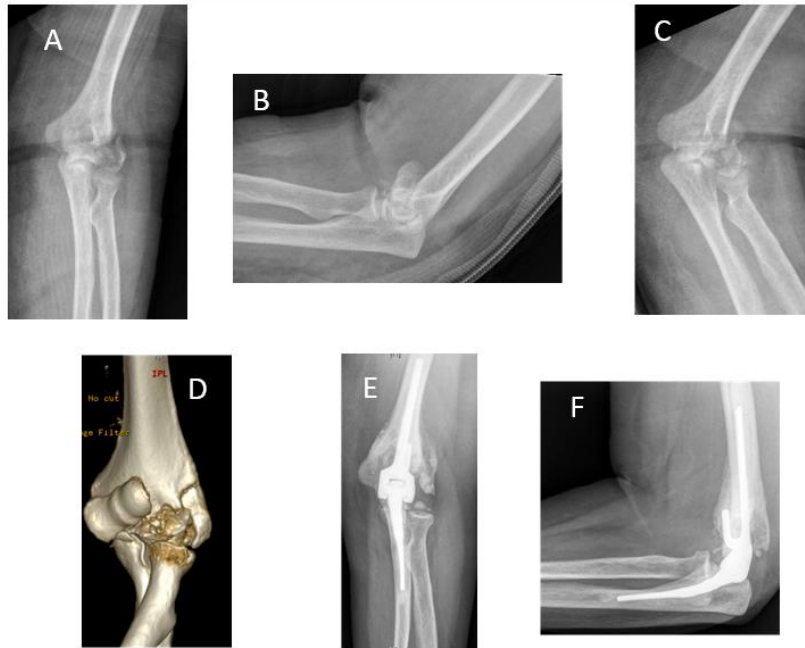

Figure 4. 72-year-old female with a comminuted, displaced, distal humerus fracture. Due to the fracture pattern, reconstruction was deemed impossible during surgery, and therefore patient underwent total elbow arthroplasty (TEA): (A-D) preoperative views; (E-F) postoperative radiographs



Figure 5. Latitude total elbow arthroplasty (Tornier Surgical Implants, Stafford, TX 77477, USA)



Figure 6. Nexel total elbow arthroplasty (Zimmer Biomet, Warsaw, IN 46581-0708, USA)

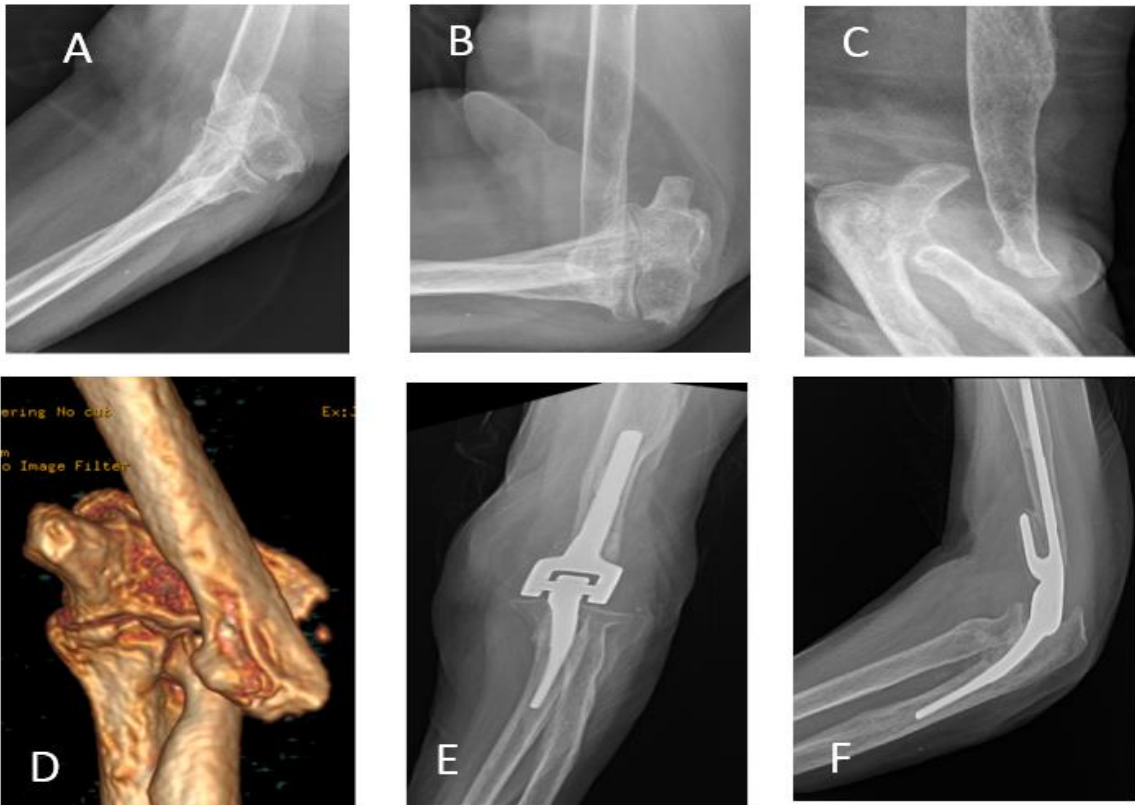


Figure 7. A 81-year-old female sustained a distal humerus fracture three years before. Due to medical comorbidities, surgical treatment was not possible at that time. She returned to the office with complaints of elbow instability, and therefore total elbow arthroplasty (TEA) was performed: (A-D) preoperative views; (E-F) postoperative radiographs

Only two of the studies that were published in 2022 and have been analyzed in this article were systematic reviews and meta-analyses. The remaining articles were case series and therefore of limited evidence. The first systematic review analyzed the survival of TEA and showed that the estimated 10-year survival for linked TEAs was 92% and 84% for unlinked TEAs. Besides, they found that the 10-year PROMs from TEAs (linked and unlinked) improved substantially from baseline scores [EVANS].

The second systematic review analyzed revision surgery by PJI. With a grade of evidence of 4, it was found that *Staphylococcus aureus* was the most usual bacteria (40%). The Coonrad-Morrey TEA represented 41% of the infected implant and the most usual design utilized for the PJI revision TEA. Two-stage revision and DAIR were the most frequent surgical techniques carried out for PJI, and, on the whole, they represented 36% and 33%, respectively. The eradication rate was 76% with two-stage, 71% with resection arthroplasty, 67% with one-stage, 58% with DAIR, and 40% with elbow fusion. Reoperations happened in 40% of individuals after elbow fusion, 33% after one-stage revision, 27% after DAIR and resection arthroplasty, and 24% after two-stage revision. Conversion to amputation happened in 2.2% of individuals after resection arthroplasty and 1% after DAIR.

In short, more studies with a higher degree of evidence are needed to confirm the main findings and conclusions

presented in this article: that approximately 90% of TEAs are implanted in patients with RA and that prosthetic survival at 10 years is 92% for linked TEAs and 84% for unlinked TEAs. Also, that two-stage revision and DAIR are the most usual procedures to treat PJI; however, the former displayed a substantially higher eradication percentage.

### Acknowledgement

Not applicable

**Conflict of interest:** None

**Funding:** None

E. Carlos Rodriguez-Merchan MD, PhD <sup>1</sup>

Amir R. Kachooei MD <sup>2</sup>

Eloy Tabeayo, MD <sup>3</sup>

<sup>1</sup> Department of Orthopedic Surgery, La Paz University Hospital, Madrid, Spain

<sup>2</sup> Rothman Orthopedics Florida at AdventHealth, Orlando, FL, USA

<sup>3</sup> Department of Orthopedic Surgery, Montefiore Medical Center, Albert Einstein College of Medicine, Bronx, NY, USA

### References

- Gambhir N, Alben MG, Shankar D, Larose G, Kwon YW, Virk MS. Comparison of 90-day complication rates and readmissions of primary total elbow arthroplasty in elective and traumatic cases: a single center experience. *Eur J Orthop Surg Traumatol.* 2022 Nov 8. doi: 10.1007/s00590-022-03425-6.
- Davey MS, Hurley ET, Gaafar M, Molony D, Mullett H, Pauzenberger L. Long-term outcomes of total elbow arthroplasty: a systematic review of studies at 10-year follow-up. *J Shoulder Elbow Surg.* 2021; 30(6):1423-1430. doi: 10.1016/j.jse.2020.11.014.
- Seok HG, Park JJ, Park SG. Comparison of the complications, reoperations, and clinical outcomes between open reduction and internal fixation and total elbow arthroplasty for distal humeral fractures in the elderly: a systematic review and meta-analysis. *J Clin Med.* 2022; 11(19):5775. doi: 10.3390/jcm11195775.
- Meijering D, Boerboom AL, Gerritsma CLE, et al. Mid-term results of the Latitude primary total elbow arthroplasty. *J Shoulder Elbow Surg.* 2022; 31(2):382-390. doi: 10.1016/j.jse.2021.08.028.
- Bhat MG, Desai A, Patel VR. Functional outcomes and complications following convertible primary total elbow arthroplasty: a single surgeon series. *Shoulder Elbow.* 2022; 14(3):304-316. doi: 10.1177/1758573221991511.
- Morrey ME, Songy C, Triplet JJ, et al. Unexpected high early failure rate of the Nexel total elbow arthroplasty. *JSES Int.* 2022; 6(4):690-695. doi: 10.1016/j.jseint.2022.04.001.
- Evans JP, Evans JT, Mohammad HR, et al. How long does an elbow replacement last? A systematic review and meta-analysis of case-series and national registry reports with more than 10 years of follow-up. *Acta Orthop.* 2022;93:495-502. doi: 10.2340/17453674.2022.2753.
- Patrick CM, Tadlock JC, Nesti LJ, Dunn JC, Parnes N. Treatment trends in distal humerus fractures between ABOS part II candidates. *Injury.* 2022; 53(3):1044-1048. doi: 10.1016/j.injury.2021.09.058.
- Stone A, Chan G, Sinclair L, Phadnis J. Elbow arthroplasty in trauma-current concepts review. *J Orthop.* 2022; 35:126-133. doi: 10.1016/j.jor.2022.11.013.
- Burden EG, Batten T, Smith C, Evans JP. Hemiarthroplasty or total elbow arthroplasty for unreconstructable distal humeral fractures in patients aged over 65 years: a systematic review and meta-analysis of patient outcomes and complications. *Bone Joint J.* 2022; 104-B (5):559-566. doi: 10.1302/0301-620X.104B5.BJJ-2021-1207.R2.
- Leschinger T, Hackl M, Lanzerath F, et al. Elbow prosthesis after acute fractures: Indications and technique. *Unfallchirurgie (Heidelb).* 2022; 125(9):699-708. doi: 10.1007/s00113-022-01215-7.
- Calderazzi F, Schiavi P, Pogliacomì F, Tacci F, Vaienti E, Ceccarelli F. Involvement of the medial and lateral epicondyles in distal humeral coronal shear fractures: Case series and literature review. *Eur J Orthop Surg Traumatol.*

- 2022;32(7):1341-1356. doi: 10.1007/s00590-021-03113-x.
13. Aliyev AG, Tikhilov RM, Shubnyakov II, et al. Coonrad Morrey total elbow arthroplasty implications in young patients with posttraumatic sequelae. *J Shoulder Elbow Surg.* 2022; 31(9):1874-1883. doi: 10.1016/j.jse.2022.03.021.
  14. Gupta P, Quan T, Manzi JE, Zimmer ZR. Thirty-day morbidity and mortality following primary total elbow arthroplasty in octogenarians. *Shoulder Elbow.* 2022; 14(5):562-567. doi: 10.1177/17585732221077668.
  15. Tai DBG, Hanson S, Brennan P, Suh GA, Esper RN, Sanchez-Sotelo J. Outcomes and risk factors for failure after debridement, antibiotics, and implant retention (DAIR) for elbow periprosthetic joint infection. *J Shoulder Elbow Surg.* 2022 Dec 21:S1058-2746(22)00904-1. doi: 10.1016/j.jse.2022.11.009.
  16. Mercurio M, Castioni D, Cosentino O, Familiari F, Iannò B, Gasparini G, Galasso O. Revision surgery for periprosthetic elbow infection: eradication rate, complications, and functional outcomes-a systematic review. *Arch Orthop Trauma Surg.* 2022 Jul 1. doi: 10.1007/s00402-022-04512-3.
  17. Martinez-Catalan N, Nguyen NTV, Morrey ME, O'Driscoll SW, Sanchez-Sotelo J. Two-stage reimplantation for deep infection after total elbow arthroplasty. *Shoulder Elbow.* 2022; 14(6):668-676. doi: 10.1177/17585732211043524.
  18. Kwak JM, So SP, Jeon IH. Staged revision still works for chronic and deep infection of total elbow arthroplasty? *SICOT J.* 2022; 8:21. doi: 10.1051/sicotj/2022019.
  19. Laumonerie P, Granjou J, Tibbo ME, Massin V, Bonneville N, Mansat P. Midterm outcomes allograft prosthetic composite reconstruction for massive bone loss at the elbow. *Orthop Traumatol Surg Res.* 2022 Dec 10:103517. doi: 10.1016/j.otsr.2022.103517. Online ahead of print.PMID: 36513324
  20. Hill JR, Boyer MI, Chamberlain AM. Radial forearm vascularized osteomuscular flap for proximal ulnar deficiency after revision total elbow arthroplasty: a case report. *JBJS Case Connect.* 2022; 12(1). doi: 10.2106/JBJS.CC.21.00558.