

TECHNICAL NOTE

How to Avoid Common Complications in Hamstrings Harvest for Anterior Cruciate Ligament Reconstruction: A Practical Guide

Filippo Familiari, MD; Michelangelo Palco, MD; Raffaella Russo, MD; Robert F. LaPrade, MD, PhD; Roberto Simonetta, MD

Research performed at Magna Graecia University of Catanzaro (CZ) Italy, Casa di Cura Caminiti, Villa San Giovanni (RC) Italy, and Edina, Minnesota, USA

Received: 19 February 2023

Accepted: 2 May 2023

Abstract

More than 100,000 anterior cruciate ligament (ACL) reconstructions are performed annually in the United States and one of the most common autografts for ACL reconstruction (ACLR) is the HS tendons. Nevertheless, proper HS harvest can be challenging, and several complications can be encountered, including, iatrogenic neurovascular damage, premature amputation of the tendons, graft contamination, and postoperative hematoma. The aim of this technical note is to describe a safe and effective technique for autologous HS tendon harvest in ACLR.

Level of evidence: V

Keywords: ACL, ACLR, Complication, Hamstring harvest, Hamstring, Knee

Introduction

Between 100,000 and 130,000 anterior cruciate ligament (ACL) reconstructions are performed every year in the U.S.A.,¹ and hamstring (HS) autografts and patellar tendon autografts are the most frequent options for reconstruction.²

While on the one hand autologous patellar tendon width is fairly uniform in size, on the other HS tendons have been stated to possess inconstant calibers. An appropriate graft size is needed for restoring of damage and for the biomechanical role and it has been recommended to use grafts with a minimum caliber of 8 mm to reproduce the native ACL.^{3,4}

Except for the primary tendinous attachment onto the tibial crest, many accessory bands originate from the distal ends of the tendons which crossing to the fascia of the medial gastrocnemius or tibial crest. From researches on cadavers has been recorded these accessory bands to be very changeable⁵ but the existence of an accessory band from the semitendinosus tendon to the medial gastrocnemius has been consistently demonstrated.⁶ The awareness about the existence of accessory bands of these tendons is crucial to avoid accidental deviation of the tendon harvester, then a premature amputation of the graft. This could be conducted to a shorter and smaller diameter of the graft and maybe lead to a different graft option.

Additionally, the adjacency of the HS tendons in the pes anserinus zone to the infrapatellar branch of the saphenous nerve (IPBSN) predisposes to injure the nerve while harvesting. There is a mutable branching pattern over the anteroinferior and medial sides of the knee.⁷ On the medial aspect of the knee, a lot of small arborizing branches merge to constitute two major nerve trunks. These trunks, successively, join together in the distal region of the medial thigh and join the saphenous nerve, which rises to get into the adductor hiatus. Thus, vertical, horizontal, and even oblique incision techniques have been suggested to lowering the risk of IPBSN injury; however, no consensus has been achieved concerning the best incision placement in the pes anserinus zone for HS tendon harvest.^{8,9} Therefore, knowledge of peri-pes anserine region, neurovascular and musculoskeletal anatomy is essential for an efficacious HS harvest with minimal postoperative morbidity.¹⁰

Finally, it has been proposed that graft infection with skin flora is the principal contributing agent to infection;¹¹ several papers report that pre-soaking grafts in vancomycin may lead to lowering deep infection rates.¹²⁻¹⁴ Present literature shows no complications in ACL grafts with vancomycin use.¹⁴

This technical note describes a safe and effective

Corresponding Author: Michelangelo Palco, Department of Orthopedic and Trauma Surgery, Casa di Cura Caminiti, Villa San Giovanni (RC), Italy

Email: michelangelo.palco@gmail.com



THE ONLINE VERSION OF THIS ARTICLE
ABJS.MUMS.AC.IR

technique of autologous HS tendons harvest for ACLR to minimize the risk of iatrogenic neurovascular damage, premature amputation of tendons, graft contamination, and postoperative hematoma.

Surgical Technique

Patient Positioning and Anesthesia

A bilateral knee examination is carried out to evaluate any concomitant ligament instability and to evaluate range of motion. After the under-anesthesia examination, a padded non-sterile tourniquet is placed high around the thigh to operate. The patient is placed in the usual arthroscopy position, with lateral backing at the tourniquet height and a foot stop to permit the knee to be maintained at 90° of flexion when needed. The leg to operate is prepared and draped in a standard fashion [Figure 1].

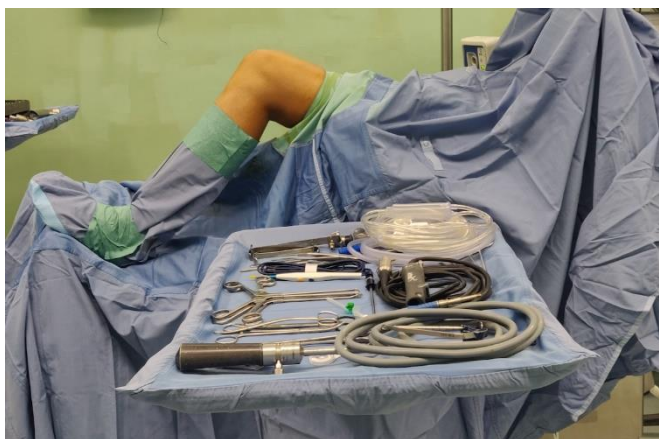

Figure 1. Patient positioning and room setup for knee arthroscopy

Diabolik technique

A previous diagnostic arthroscopy can be carried out before the harvesting of the HS tendons. After treating any concurrent intra-articular pathology (i.e., meniscal or chondral injuries), a 10 × 10 cm gauze is applied over the standard arthroscopic portals (anterolateral and anteromedial) to prevent liquid leakage onto the surgical field. Then, an antimicrobial, adhesive incise drape with iodine (Ioban 2; 3M Health Care, Neuss, Germany) is applied over the gauze and the surrounding skin to reduce the risk of infection [Figure 2]. After HS tendon harvest, to resume the arthroscopic procedure it will be sufficient to remove the portion of the incision drape that covers the gauze, thus resulting in a “Diabolik”-like appearance of the knee [Figure 3]; the remaining skin will be still covered by the incision drape and the risk of infection will be reduced.¹⁵

Skin incision and IPBSN preservation

With the knee at 90° of flexion, the HS tendons are palpated from the posterior thigh to the anteromedial aspect of the tibia. A 2.5 cm vertical anteromedial incision is then performed at tibial tubercle height to reveal the sartorius fascia and pes anserine bursa, which covers the HS tendons. This represents the critical moment to pursue IPBSN preservation. After incising the skin (just epidermis and dermis), the fatty layer that embeds the IPBSN is pulled away

to get to the aponeurosis [Figure 4]. Moreover, it can be later easily retracted proximally using one Farabeuf retractor to provide access to the tibial drill guide (Arthrex, Naples, FL).

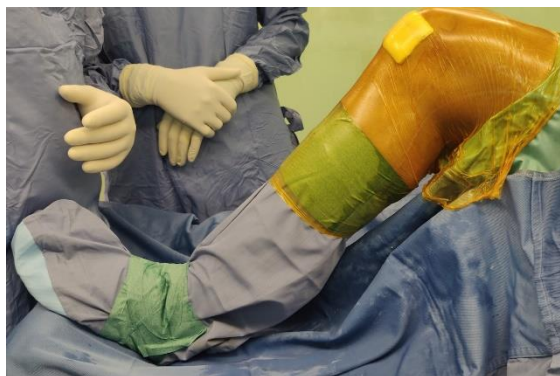

Figure 2. Left knee draped in an antimicrobial incise drape



Figure 3. “Diabolik”-like appearance of the knee

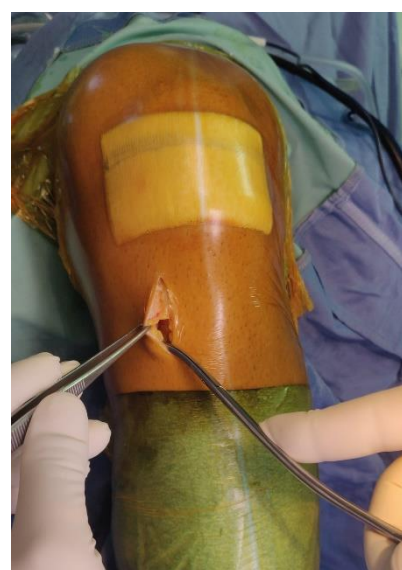


Figure 4. Skin incision and surgical approach to pes anserinus

HS identification

A bright white plane should be obtained on a good work surface before going further. Only one Farabeuf retractor positioned on the medial edge of the skin incision is sufficient to obtain adequate exposure. Then, a gloved finger efficiently palpates the superior edge of the “speed-bump” which represents the superior border of the sartorius fascia, overlaying the HS tendons. The upper border of the “speed-bump” is firmly taken hold by dissection forceps and gently incised using Metzenbaum scissors: it will resemble the bursting of a bubble as it enters the pes anserine bursa [Figure 5]. Still grasping the bump with the forceps, the Metzenbaum scissor slides proximally for 3 cm along the superior border of the bump. The dissection forceps now retract the inferior lip of the bump downwards. This is the sartorius fascia, on the deep side of which two tendons are visible: the gracilis is above and proximal to the semitendinosus and has a rounded-shaped muscular belly; the semitendinosus is deep and distal to the gracilis and has a U-shaped muscular belly. Sometimes, identification of the individual tendons can be difficult with the fascia getting in the way or due to the tendon-like appearance of the fascia [Figure 6]. The authors suggest to carefully evaluate the elasticity of these structures, with the more elastic ones representing the tendons, and the stiffer one representing the fascia. The opted tendon can now be grasped, with the help of a hook.

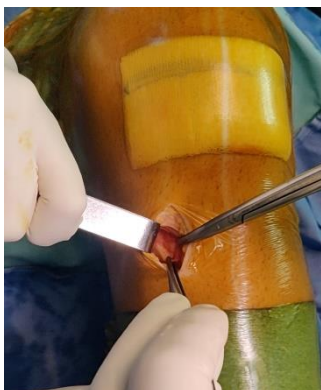

Figure 5. Dissection using Metzenbaum scissors and “bubble-sign”

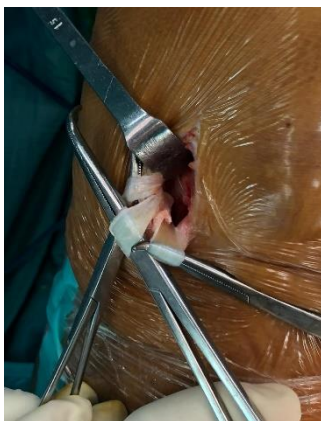

Figure 6. Visualization of the pes anserinus tendons and “fascia”-like appearance of sartorius tendon

Expansions

Maintaining the tibial attachment of the tendons intact, a hook is used to pull the tendons outside the wound. The index finger easily replaces the hook in applying tension to the tendons and the hook is now used to expose the expansions, one after the other. These expansions can be cut using a Mayo scissor under direct visual control until perfect elastic freedom is gained. It is critical to ensure that the visible part of tendon is free from any extratendinous reins. A mix of blunt and cautious sharp dissection, with scissors and elevator, is used to be sure that the tendons are free from any adhered soft tissue. It is mandatory to avoid prematurely amputating the tendon while using the tendon stripper (Tendon Harvester; ConMed Linvatec, Largo, FL).

HS harvest

Usually, the gracilis is harvested first. Current anatomic ACLR and fixation techniques use multiple-stranded HS autografts with an ideal tendon length greater than 21 cm.¹⁶ The tendon can be pulled when the stripper is at the desired length to avoid damage to the muscle bellies of the HS tendons [Figure 7]. The stripper should not be used if it does not flow smoothly along the tendon: it may be halted by expansions and is responsible to cut the tendon rather than the expansion, resulting in a short graft. Maintaining distal insertion can be helpful to leave the tendons inserted distally on onto the tibia to eradicate muscle fragments using an open Mayo scissor, in a maneuver that resembles curling a ribbon for a birthday present [Figure 8].

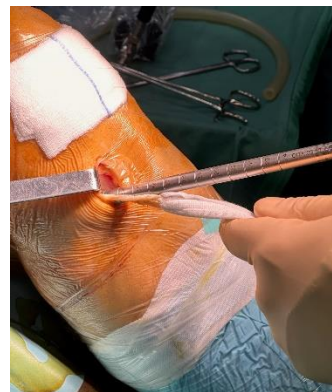

Figure 7. Stripping of gracilis tendon

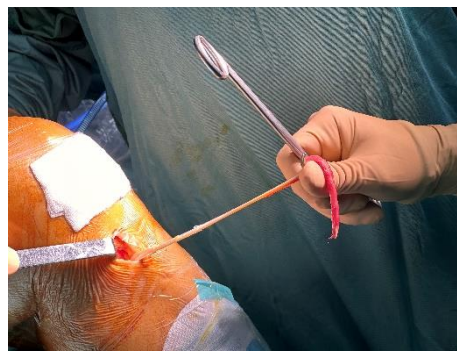

Figure 8. Cleaning muscles fragments out of tendon with a ribbon-present maneuver

HS whipstitching

Skin edge contact with the HS grafts during harvest is avoided to reduce the risk of infection. With both tendons still attached to the tibia, whipstitching of the four ends of the graft with No. 2 absorbable sutures (Vicryl; Ethicon, Somerville, NJ) is performed by the surgeon and his/her assistant, thus limiting the amount of time that the graft will be on the back table outside of the surgeon's visualization, preventing accidental droppage,¹⁷ and reducing surgical time needed for graft preparation. A long and thin Raytec gauze pre-soaked in 10 mL of tranexamic acid (Tranex, 500 mg/5 mL; Malesci SpA, Bagno a Ripoli, Italy) is placed through the wound toward the HS origin at the pelvis to reduce postoperative hematoma in the posterior thigh. Afterwards, both tendons are released from the tibia, loaded in a suspensory device (TightRope RT, Arthrex, Naples, FL) to obtain a quadrupled graft, and draped in a Raytec gauze, with the swab pre-soaked in 5 mg/mL vancomycin solution.¹⁸

Wound closure

After completion of the ACLR, the tibial harvest site incision is generously irrigated and closed in layers in standard fashion. The sartorius fascia is not sutured. Careful hemostatis and coagulation of small vessels at the donor site, around the tibial tunnel, is performed to lowering the risk of postoperative bleeding and hematoma formation and an intra-articular drain can be placed through an anterolateral arthroscopic portal. Subcutaneous sutures should be restricted so as not to hurt the saphenous nerve which lies within the fatty layer.

Discussion

This technical note describes an easy and effective method for HS harvest, reducing at the same time the risk of potential complications. In addition, it can be an effective method for HS tendon graft harvest for lateral and medial collateral ligament reconstructions.^{19,20}

The first step of ACLR is represented by diagnostic arthroscopy with possible treatment of any concurrent intra-articular pathology; then, if HS are the graft of choice, it's the turn of tendons harvesting. Despite using standard techniques, like pre-operative scrubbing and prepping with Povidone-iodine solution with the aim to reduce surgical field contamination, complete skin sterilization is impossible. It has been demonstrated that live microorganisms persist in the deeper areas of the skin, like hair follicles, and, during surgery they could migrate to the skin surface, thus possibly polluting the surgical field.²¹ In addition, the liquid leakage from arthroscopic portals during the procedure might carry these microorganisms to the incision wound of HS harvest. For this reason, the authors recommend applying a gauze over the arthroscopic portals and an antimicrobial adhesive incise drape with iodine to physically seal the exposed skin surface. In fact, it has been demonstrated by several studies that the use of antimicrobial drapes reduces intraoperative contamination in any orthopedic procedures.^{15,22,23}

Several studies have shown the effectiveness of the pre-soaking of the HS graft with topical Vancomycin compared to the use of antibiotic prophylaxis alone in reducing the

post-operative infection rate.^{18,24,25} But if the graft drops on the floor or it is contaminated in any way, Pasque et al.,¹⁷ largely basing on the paper of Goebel et al.,²⁶ reported the protocol used in this unfortunate event: the graft was drenched in a chlorhexidine solution for 15 minutes, then it was soaked in a triple antibiotic (gentamicin, clindamycin, polymyxin) solution for further 15 minutes, and finally it was rinsed in normal saline before implantation.

Injury to the IPBSN represents one of the commonest complications of HS tendon harvest. The IPBSN allows sensory innervation to the medial infrapatellar area and during its course it can penetrate the sartorius muscle or it can course anterior or posterior to it.²⁷ Due to its subcutaneous position and horizontal course along the medial knee, the IPBSN is at risk of damage during skin incision, HS tendon harvest and tibial drilling during ACLR. Different authors²⁸⁻³³ approached this issue, but no-one was able to determine the optimal way to position a HS harvest skin incision. Sanders et al.³⁴ stated that a vertical skin incision should be avoided because there is a high (19%) rate of iatrogenic nervous lesions. Also, Grassi et al.³⁵ states that the risk of iatrogenic injury to the IPBSN during HS harvest is greater when a vertical incision was made instead of an oblique or a horizontal incision. Nevertheless the authors believe that, supported by the study of Babu et al.³⁶, a little (2.5 cm) vertical incision is sufficient to expose the pes anserinus and to harvest HS tendons and it minimizes damage to the IPBSN due to its distribution into the fatty layer; in fact, with a gentle dissection and with protection with a Farabeuf retractor, as described above, it is possible to perform the procedure in safe manner.

Moreover, it is crucial to identify the pes anserinus. According to the anatomical analysis of the medial side of the knee made by Warren and Marshall,³⁷ the sartorius tendon rests intimate with the fascia cruris, and the gracilis and semitendinosus are placed on the deep surface of this superficial layer over the medial tibia. Importantly, the pes anserinus lies superficial too and attaches proximally and anteriorly to the sMCL.²⁷ As already explained earlier, the superior edge of the sartorius fascia is considered the proximal HS tendon landmark. An artery, so-called by Babu et al.³⁶ the "sentinel vessel", is also a useful landmark to identify the pes anserinus. The authors reported that in 98 of the 100 observed knees, this vessel passed from the superficial fascia to the periosteum at the pes attachment at a mean perpendicular gap of 8 mm from the upper edge of the pes tendons.

Another common complication in HS harvest is the premature amputation of the graft when availing a tendon stripper; the most important cause is represented by tendinous expansions. From the dissection of 102 lower limbs Olewnik et al.³⁸ described six types of pes anserinus, based on the distribution of tendons and accessory bands. The most frequent type was Type 1-1-1 (monotendinous sartorius tendon, gracilis and semitendinosus) followed by Type 1-1-2 (monotendinous sartorius tendon, gracilis and one accessory band from the semitendinosus) and Type 1-1-3 (monotendinous sartorius and gracilis and two accessory

bands from the semitendinosus).³⁸ In addition, they indicated three types of insertion: short, band-shaped and fan-shaped.³⁸ In 2012, Reina et al. described the anatomy of the HS tendons and of their accessory bands. They stated that the semitendinosus has a constant anatomy; it is possible to find one accessory band, in one third of the cases two bands, but didn't find three bands. The course of these bands usually goes from the fascia of gastrocnemius medialis to the HS tendons and they attach forming an acute angle; they are always existent and they are only extraordinarily found at a distance greater than 100 mm. The gracilis showed a greater anatomical changeability. When present (75% of cases), the bands ranged from one to three. The angle of attachment and their direction was variable. Moreover, it has been reported that if a band existing on the gracilis very close to the tibial insertion, a second or even a third band should be attempted, because sometimes these could be very large (up to 42mm), and the stripper may be misdirected when the gracilis is harvested.³⁹ In literature, it is conventionally accepted that proximal dissection should be performed further than 100 mm.⁴⁰ After changing gloves the authors recommend to use the index finger to feel the elastic sensation that is typical of tendons, but not of accessory bands.

Finally, it is recommended to place an intra-articular drain, to administrate intravenous tranexamic acid, and to perform a very meticulous hemostasis. It is crucial to minimize the risk of a postoperative hemarthrosis and its potential implications: infection, pain, inflammation, and loss of ROM in the knee joint.⁴¹⁻⁴⁵ Since hematoma is a very opportune culture medium for the growth of bacteria, minimizing the hematoma in the surgical field could lead to lowering the risk of infection.⁴⁶ The results of drainage-use on preventing infection has been disputed.⁴⁷⁻⁴⁹ McCormack⁵⁰ found that the haemarthrosis score was significantly smaller at week 1 in the drained group (P= 0.02), but not at weeks 4 or 8. Some

authors found a significant increment in knee circumference in undrained knees after ACLR at 1 and 2 weeks.^{51,52} for all of these reasons, the authors recommend placing an intra-articular drain, but it must be removed after the second postoperative day.

Conclusion

In conclusion, the authors believe that this practical guide can be helpful for every surgeon, from the younger and less experienced to the more mature and with more experience thanks to its simplicity and reproducibility. The showed tips and tricks of this guide could be very successful when used by the authors in their daily surgical activities.

Acknowledgement

Not applicable

Conflict of interest: None

Funding: None

Filippo Familiari MD ¹
Michelangelo Palco MD ²
Raffaella Russo MD ³
Robert F. LaPrade MD, PhD ⁴
Roberto Simonetta, MD ²

1 Department of Orthopedic and Trauma Surgery, Magna Graecia University, Catanzaro, Italy

2 Department of Orthopedic and Trauma Surgery, Casa di Cura Caminiti, Villa San Giovanni (RC), Italy

3 Department of Medical and Surgical Sciences, Nutrition Unit, Magna Graecia University, Catanzaro, Italy

4 Twin Cities Orthopedics, Edina, Minnesota, USA

References

- Mall NA, Chalmers PN, Moric M, et al. Incidence and trends of anterior cruciate ligament reconstruction in the United States. *Am J Sports Med.* 2014; 42(10):2363-2370. doi: 10.1177/0363546514542796.
- Goldblatt JP, Fitzsimmons SE, Balk E, Richmond JC. Reconstruction of the anterior cruciate ligament: meta-analysis of patellar tendon versus hamstring tendon autograft. *Arthroscopy.* 2005; 21(7):791-803. doi:10.1016/j.arthro.2005.04.107.
- Maeda A, Shino K, Horibe S, Nakata K, Buccafusca G. Anterior cruciate ligament reconstruction with multi-stranded autogenous semitendinosus tendon. *Am J Sports Med.* 1996; 24(4):504-509. doi:10.1177/036354659602400416.
- Mariscalco MW, Flanigan DC, Mitchell J, et al. The influence of hamstring autograft size on patient-reported outcomes and risk of revision after anterior cruciate ligament reconstruction: a Multicenter Orthopaedic Outcomes Network (MOON) Cohort Study. *Arthroscopy.* 2013; 29(12):1948-1953. doi:10.1016/j.arthro.2013.08.025.
- Candal-Couto JJ, Deehan DJ. The accessory bands of Gracilis and Semitendinosus: an anatomical study. *Knee.* 2003; 10(4):325-328. doi: 10.1016/S0968-0160(02)00154-0.
- Tuncay I, Kucuker H, Uzun I, Karalezli N. The fascial band from semitendinosus to gastrocnemius: the critical point of hamstring harvesting an anatomical study of 23 cadavers. *Acta Orthopaedica.* 2007; 78(3):361-363. doi:10.1080/17453670710013933.
- Tifford CD, Spero L, Luke T, Plancher KD. The relationship of the infrapatellar branches of the saphenous nerve to arthroscopy portals and incisions for anterior cruciate ligament surgery. An anatomic study. *Am J Sports Med.* 2000; 28(4):562-567. doi:10.1177/03635465000280042001.
- Yucens M, Aydemir AN. Trends in Anterior Cruciate Ligament Reconstruction in the Last Decade: A Web-Based Analysis. *J Knee Surg.* 2019; 32(6):519-524. doi: 10.1055/s-0038-1655764.
- Olivos-Meza A, Suarez-Ahedo C, Jiménez-Aroche CA, et al. Anatomic Considerations in Hamstring Tendon Harvesting

- for Ligament Reconstruction. *Arthrosc Tech.* 2020; 9(1):e191-e198. doi:10.1016/j.eats.2019.09.021.
10. LaPrade RF, Engebretsen AH, Ly TV, Johansen S, Wentorf FA, Engebretsen L. The anatomy of the medial part of the knee. *J Bone Joint Surg Am.* 2007; 89(9):2000-2010. doi:10.2106/JBJS.F.01176.
 11. Judd D, Bottoni C, Kim D, Burke M, Hooker S. Infections following arthroscopic anterior cruciate ligament reconstruction. *Arthroscopy.* 2006; 22(4):375-384. doi:10.1016/j.arthro.2005.12.002.
 12. Baron JE, Shamrock AG, Cates WT, et al. Graft Preparation with Intraoperative Vancomycin Decreases Infection after ACL Reconstruction: A Review of 1,640 Cases. *J Bone Joint Surg Am.* 2019; 101(24):2187-2193. doi:10.2106/JBJS.19.00270.
 13. Naendrup JH, Marche B, de Sa D, et al. Vancomycin-soaking of the graft reduces the incidence of septic arthritis following ACL reconstruction: results of a systematic review and meta-analysis. *Knee Surg Sports Traumatol Arthrosc.* 2020; 28(4):1005-1013. doi: 10.1007/s00167-019-05353-1.
 14. Offerhaus C, Balke M, Hente J, Gehling M, Blendl S, Höher J. Vancomycin pre-soaking of the graft reduces postoperative infection rate without increasing risk of graft failure and arthrofibrosis in ACL reconstruction. *Knee Surg Sports Traumatol Arthrosc.* 2019; 27(9):3014-3021. doi: 10.1007/s00167-018-5323-6.
 15. Hesselvig AB, Arpi M, Madsen F, Bjarnsholt T, Odgaard A, the ICON Study Group. Does an Antimicrobial Incision Drape Prevent Intraoperative Contamination? A Randomized Controlled Trial of 1187 Patients. *Clin Orthop Relat Res.* 2020; 478(5):1007-1015. doi:10.1097/CORR.0000000000001142.
 16. Lubowitz JH. All-inside anterior cruciate ligament graft link-graft preparation technique. *Arthrosc Tech.* 2012; 1(2):e165-168. doi:10.1016/j.eats.2012.06.002.
 17. Pasque CB, Geib TM. Intraoperative anterior cruciate ligament graft contamination. *Arthroscopy.* 2007; 23(3):329-331. doi:10.1016/j.arthro.2005.12.010.
 18. Phegan M, Grayson JE, Vertullo CJ. No infections in 1300 anterior cruciate ligament reconstructions with vancomycin pre-soaking of hamstring grafts. *Knee Surg Sports Traumatol Arthrosc.* 2016; 24(9):2729-2735. doi: 10.1007/s00167-015-3558-z.
 19. Laprade RF, Wijdicks CA. Surgical technique: development of an anatomic medial knee reconstruction. *Clin Orthop Relat Res.* 2012; 470(3):806-814. doi: 10.1007/s11999-011-2061-1.
 20. LaPrade RF, Spiridonov SI, Coobs BR, Ruckert PR, Griffith CJ. Fibular collateral ligament anatomical reconstructions: a prospective outcomes study. *Am J Sports Med.* 2010; 38(10):2005-2011. doi: 10.1177/0363546510370200.
 21. Lange-Asschenfeldt B, Marenbach D, Lang C, et al. Distribution of Bacteria in the Epidermal Layers and Hair Follicles of the Human Skin. *Skin Pharmacol Physiol.* 2011; 24(6):305-311. doi: 10.1159/000328728.
 22. Rezapoor M, Tan TL, Maltenfort MG, Parvizi J. Incise Draping Reduces the Rate of Contamination of the Surgical Site During Hip Surgery: A Prospective, Randomized Trial. *J Arthroplasty.* 2018; 33(6):1891-1895. doi:10.1016/j.arth.2018.01.013.
 23. Jacobson C, Osmon DR, Hanssen A, et al. Prevention of wound contamination using DuraPrep solution plus Ioban 2 drapes. *Clin Orthop Relat Res.* 2005; 439:32-37. doi:10.1097/01.blo.0000182245.29830.bc.
 24. Grayson JE, Grant GD, Dukie S, Vertullo CJ. The in vitro elution characteristics of vancomycin from tendons. *Clin Orthop Relat Res.* 2011; 469(10):2948-2952. doi: 10.1007/s11999-011-1768-3.
 25. Pérez-Prieto D, Torres-Claramunt R, Gelber PE, Shehata TMA, Pelfort X, Monllau JC. Autograft soaking in vancomycin reduces the risk of infection after anterior cruciate ligament reconstruction. *Knee Surg Sports Traumatol Arthrosc.* 2016; 24(9):2724-2728. doi: 10.1007/s00167-014-3438-y.
 26. Goebel ME, Drez D, Heck SB, Stoma MK. Contaminated rabbit patellar tendon grafts. In vivo analysis of disinfecting methods. *Am J Sports Med.* 1994; 22(3):387-391. doi: 10.1177/036354659402200315.
 27. Curtis BR, Huang BK, Pathria MN, Resnick DL, Smitaman E. Pes Anserinus: Anatomy and Pathology of Native and Harvested Tendons. *AJR Am J Roentgenol.* 2019; 213(5):1107-1116. doi:10.2214/AJR.19.21315.
 28. Sabat D, Kumar V. Nerve injury during hamstring graft harvest: a prospective comparative study of three different incisions. *Knee Surg Sports Traumatol Arthrosc.* 2013; 21(9):2089-2095. doi: 10.1007/s00167-012-2243-8.
 29. Ruffilli A, De Fine M, Traina F, Pilla F, Fenga D, Faldini C. Saphenous nerve injury during hamstring tendons harvest: Does the incision matter? A systematic review. *Knee Surg Sports Traumatol Arthrosc.* 2017; 25(10):3140-3145. doi: 10.1007/s00167-016-4217-8.
 30. Luo H, Yu J kuo, Ao Y fang, et al. Relationship between different skin incisions and the injury of the infrapatellar branch of the saphenous nerve during anterior cruciate ligament reconstruction. *Chin Med J (Engl).* 2007; 120(13):1127-1130.
 31. Tavakoli Darestani R, Bagherian Lemraski MM, Hosseinpour M, Kamrani-Rad A. Electrophysiological Assessment of Injury to the Infra-patellar Branch(es) of the Saphenous Nerve during Anterior Cruciate Ligament Reconstruction Using Medial Hamstring Auto-grafts: Vertical versus Oblique Harvest Site Incisions. *Arch Trauma Res.* 2013; 2(3):118-123. doi:10.5812/at.11146.
 32. Kjaergaard J, Faunø LZ, Faunø P. Sensibility loss after ACL reconstruction with hamstring graft. *Int J Sports Med.* 2008; 29(6):507-511. doi: 10.1055/s-2008-1038338.
 33. Papastergiou SG, Voulgaropoulos H, Mikalef P, Ziogas E, Pappis G, Giannakopoulos I. Injuries to the infrapatellar branch(es) of the saphenous nerve in anterior cruciate ligament reconstruction with four-strand hamstring tendon autograft: vertical versus horizontal incision for harvest. *Knee Surg Sports Traumatol Arthrosc.* 2006; 14(8):789-793. doi: 10.1007/s00167-005-0008-3.
 34. Sanders B, Rolf R, McClelland W, Xerogeanes J. Prevalence of Saphenous Nerve Injury After Autogenous Hamstring Harvest: An Anatomic and Clinical Study of Sartorial Branch Injury. *Arthroscopy.* 2007; 23(9):956-963. doi:10.1016/j.arthro.2007.03.099.
 35. Grassi A, Perdisa F, Samuelsson K, et al. Association between incision technique for hamstring tendon harvest in anterior

- cruciate ligament reconstruction and the risk of injury to the infra-patellar branch of the saphenous nerve: a meta-analysis. *Knee Surg Sports Traumatol Arthrosc.* 2018; 26(8):2410-2423. doi: 10.1007/s00167-018-4858-x.
36. Babu S, Gupte C, Gajjar S, Morris H. The 'sentinel' vessel: an anatomical landmark to identify the pes anserinus during hamstrings harvest for ACL reconstruction. *Eur J Orthop Surg Traumatol.* 2019; 29(5):1115-1118. doi: 10.1007/s00590-019-02408-4.
37. Warren LF, Marshall JL. The supporting structures and layers on the medial side of the knee: an anatomical analysis. *J Bone Joint Surg Am.* 1979; 61(1):56-62.
38. Olewnik Ł, Gonera B, Podgórski M, Polguy M, Jezierski H, Topol M. A proposal for a new classification of pes anserinus morphology. *Knee Surg Sports Traumatol Arthrosc.* 2019; 27(9):2984-2993. doi: 10.1007/s00167-018-5318-3.
39. Reina N, Abbo O, Gomez-Brouchet A, Chiron P, Moscovici J, Laffosse JM. Anatomy of the bands of the hamstring tendon: How can we improve harvest quality? *Knee.* 2013; 20(2):90-95. doi:10.1016/j.knee.2012.06.003.
40. Solman CG, Pagnani MJ. Hamstring tendon harvesting. Reviewing anatomic relationships and avoiding pitfalls. *Orthop Clin North Am.* 2003; 34(1):1-8. doi:10.1016/s0030-5898(02)00025-1.
41. Felli L, Revello S, Burastero G, et al. Single Intravenous Administration of Tranexamic Acid in Anterior Cruciate Ligament Reconstruction to Reduce Postoperative Hemarthrosis and Increase Functional Outcomes in the Early Phase of Postoperative Rehabilitation: A Randomized Controlled Trial. *Arthroscopy.* 2019; 35(1):149-157. doi:10.1016/j.arthro.2018.07.050.
42. Karaaslan F, Karaoğlu S, Yurdakul E. Reducing Intra-articular Hemarthrosis After Arthroscopic Anterior Cruciate Ligament Reconstruction by the Administration of Intravenous Tranexamic Acid: A Prospective, Randomized Controlled Trial. *Am J Sports Med.* 2015; 43(11):2720-2726. doi:10.1177/0363546515599629.
43. Chiang ER, Chen KH, Wang ST, et al. Intra-articular Injection of Tranexamic Acid Reduced Postoperative Hemarthrosis in Arthroscopic Anterior Cruciate Ligament Reconstruction: A Prospective Randomized Study. *Arthroscopy.* 2019; 35(7):2127-2132. doi:10.1016/j.arthro.2019.02.018.
44. Nugent M, May JH, Parker JD, et al. Does Tranexamic Acid Reduce Knee Swelling and Improve Early Function Following Arthroscopic Meniscectomy? A Double-Blind Randomized Controlled Trial. *Orthop J Sports Med.* 2019; 7(8):2325967119866122. doi: 10.1177/2325967119866122.
45. Joos H, Leucht F, Riegger J, et al. Differential Interactive Effects of Cartilage Traumatization and Blood Exposure In Vitro and In Vivo. *Am J Sports Med.* 2015; 43(11):2822-2832. doi: 10.1177/0363546515602248.
46. Sever GB. Can infection after anterior cruciate ligament surgery be prevented by inserting a Hemovac drain into graft donor site? *Jt Dis Relat Surg.* 2020; 31(1). doi:10.5606/ehc.2020.71334.
47. Kanayama M, Oha F, Togawa D, Shigenobu K, Hashimoto T. Is closed-suction drainage necessary for single-level lumbar decompression? Review of 560 cases. *Clin Orthop Relat Res.* 2010; 468(10). doi: 10.1007/s11999-010-1235-6.
48. Poorman CE, Passias PG, Bianco KM, Boniello A, Yang S, Gerling MC. Effectiveness of postoperative wound drains in one- and two-level cervical spine fusions. *Int J Spine Surg.* 2014; 8:34. doi: 10.14444/1034.
49. Zhou X die, Li J, Xiong Y, Jiang L feng, Li W jun, Wu L dong. Do we really need closed-suction drainage in total hip arthroplasty? A meta-analysis. *Int Orthop.* 2013; 37(11):2109-2118. doi: 10.1007/s00264-013-2053-8.
50. McCormack RG, Greenhow RJ, Fogagnolo F, Shrier I. Intra-articular drain versus no drain after arthroscopic anterior cruciate ligament reconstruction: a randomized, prospective clinical trial. *Arthroscopy.* 2006; 22(8):889-893. doi:10.1016/j.arthro.2006.05.004.
51. Karahan M, Erol B, Bekiroğlu N, Uyan D. Effect of drain placed in the donor site in the early postoperative period after arthroscopically assisted anterior cruciate ligament reconstruction with quadrupled hamstring tendons. *Am J Sports Med.* 2005; 33(6):900-906. doi: 10.1177/0363546504271503.
52. Straw R, Colclough K, Geutjens GG. Arthroscopically assisted ACL reconstruction. Is a drain necessary? *Knee.* 2003; 10(3):283-285. doi: 10.1016/s0968-0160(02)00150-3.