

CASE REPORT

Spontaneous Avascular Necrosis of the Humeral Head Following COVID-19 Vaccination

Abdulrahman KASHKOSH, MBBS¹; Christopher M. PEAKE, MBBS BSc MRCS²;
A. Ali NARVANI, MBBS MSc (Sports Med) FRCS (Tr & Orth)³; MA IMAM, MD MSc DSportMed PhD FRCS (Tr & Orth)³

Research performed at the Department of Orthopaedics Ashford and St Peter's Hospitals NHS Foundation Trust, Chertsey, United Kingdom

Received: 22 October 2022

Accepted: 16 November 2022

Abstract

We report a case of a 40-year-old man who presented with left shoulder pain and marked functional impairment two days after receiving the second dose of the Pfizer COVID-19 vaccine. Advanced imaging demonstrated focal avascular necrosis (AVN) of his humeral head. Initial management included simple analgesics, activity modification, and an ultrasound-guided intra-articular hydrodilatation injection. The patient subsequently had an improved range of motion but persistent severe shoulder pain. He has now been offered surgical intervention. Despite having risk factors for developing AVN previously, the patient did not demonstrate any recent risk factors for developing the disease. COVID-19 vaccination is known to cause severe joint pain and stiffness rarely. However, avascular necrosis is not a known or documented side effect. His symptoms arose directly after the administration of the vaccine, with no other demonstrable cause. Therefore, we are reporting COVID-19 vaccination as a potential new risk factor for AVN of the humeral head.

Level of evidence: V

Keywords: Avascular necrosis, COVID-19 vaccine, Hypercoagulability, Orthopaedics, Shoulder

Introduction

The severe acute respiratory syndrome coronavirus 2 (SARS-CoV-2) "COVID-19" has caused a pandemic that has claimed over 5 million lives worldwide.¹ An acceleration of operations related to clinical trials took place to answer the global crisis, and increased funding during the pandemic, resulted in the development of many vaccines, with vaccination programs becoming widespread. Consequently, it became essential to communicate and document any potential serious vaccine-related events timely.²

The three major vaccines used in the United Kingdom (UK) are Vaxzevria (previously AstraZeneca), Moderna, and Pfizer/BioNTech. Significant attention has been drawn to the adverse effects of COVID-19 vaccination in scientific journals and international media. Joint pain and stiffness are very common (may affect 1 in 10 people) side effects that have been reported in all three major vaccines used in the UK. The majority of cases

affected with joint pain have been reported to be mild to moderate, with a very small number of severe cases. However, many other possible adverse effects cannot be estimated from the available data due to lesser incidence. Avascular Necrosis (AVN) is not known to be a side effect of COVID-19 Vaccination.³

Although relatively uncommon, AVN can cause significant shoulder pain, functional limitation, and poor quality of life in young patients. With the very high volume administration of the COVID-19 vaccine, an awareness of all possible side effects or associated diseases is crucial for clinicians in both primary and secondary care. Early identification of AVN leads to earlier diagnosis, investigation, referral, management, and, therefore, better patient outcomes.

Case Presentation

A 40-year-old white-British man presented to the

Corresponding Author: Abdulrahman Kashkosh, Bradford Teaching Hospital Foundation Trust, United Kingdom
Email: Abdulrahman975@outlook.com



THE ONLINE VERSION OF THIS ARTICLE
ABJS.MUMS.AC.IR

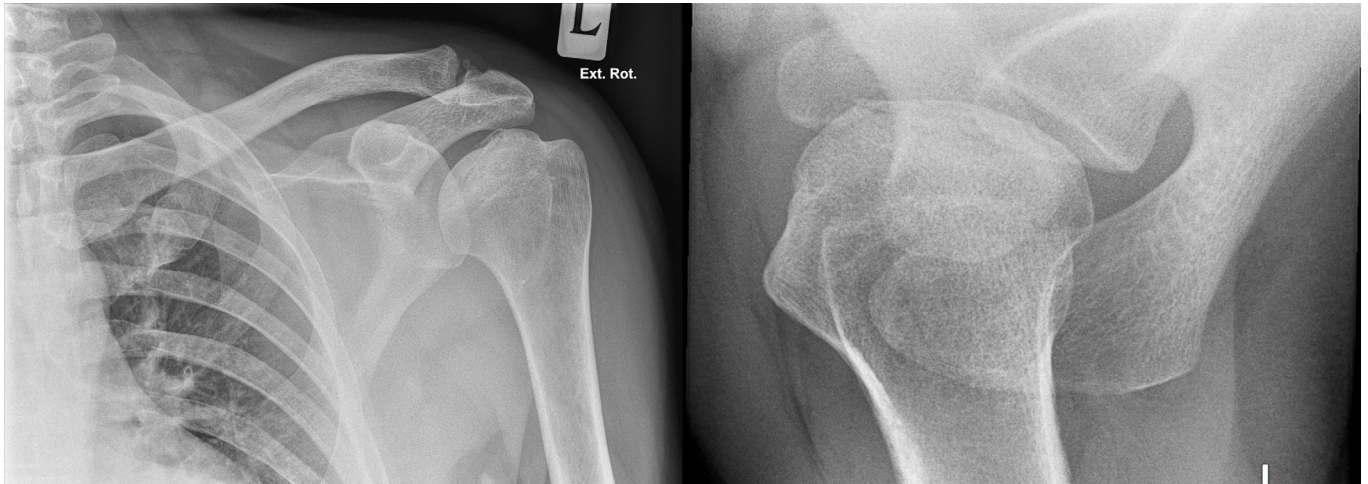


Figure 1. Plain radiographs of the left shoulder, AP (Left) and Trans -axillary views (Right). Subchondral lucency and periarticular sclerosis can be seen as suggestive of AVN.

specialist upper-limb clinic having developed sudden onset pain of the left shoulder with severely restricted range of motion two days following his second dose of the Pfizer COVID vaccine. The patient was administered the vaccine, in the left shoulder, at a vaccination center at the recommended dose using the conventional technique by trained staff. He presented face-to-face in the clinic 12 weeks after the onset. There was no history of shoulder trauma in the past or directly prior to the onset of symptoms. There was no previous history of ipsilateral shoulder pain. Examination of the left shoulder revealed loss of external rotation, internal rotation, abduction, adduction, and forward flexion. Both active and passive movements were affected, and pain in the passive movement was noted. No abnormality was detected in the right shoulder. The patient had already undergone a plain radiograph of his shoulder, organized by his general practitioner, which on the axillary view, showed subchondral lucency and periarticular sclerosis

suggestive of AVN [Figure 1].

While he had never undergone imaging of his shoulder in the past, he had undergone a computer tomography (CT) scan three months prior to the onset of symptoms, including his left shoulder. The CT scan was performed to investigate an episode of acute abdominal pain. No obvious signs of AVN of the humeral head were present at this scan [Figure 2]. He had his first dose of the Pfizer COVID vaccine four months prior to the second dose and experienced only mild side effects, which were self-limiting within 72 hours.

Our differential diagnosis included adhesive capsulitis, supraspinatus tendonitis, and AVN of the humerus. A magnetic resonance imaging (MRI) scan had already been performed three days prior to his presentation to the senior author's clinic. This scan confirmed the diagnosis of AVN with associated fragmentation of the humeral head and an underlying subchondral fracture [Figure 3].

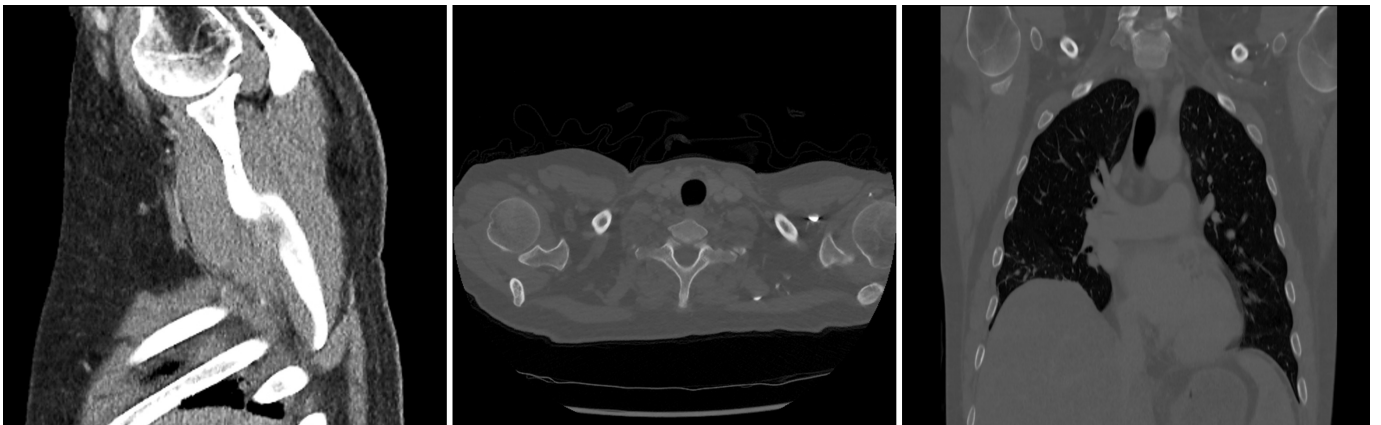


Figure 2. CT body scan (Bone windows) taken 3 months prior to the onset of symptoms. This includes the left humeral head and demonstrates no obvious signs of AVN at the time of the scan. From left to right; Sagittal slice, Axial slice, Coronal Slice.

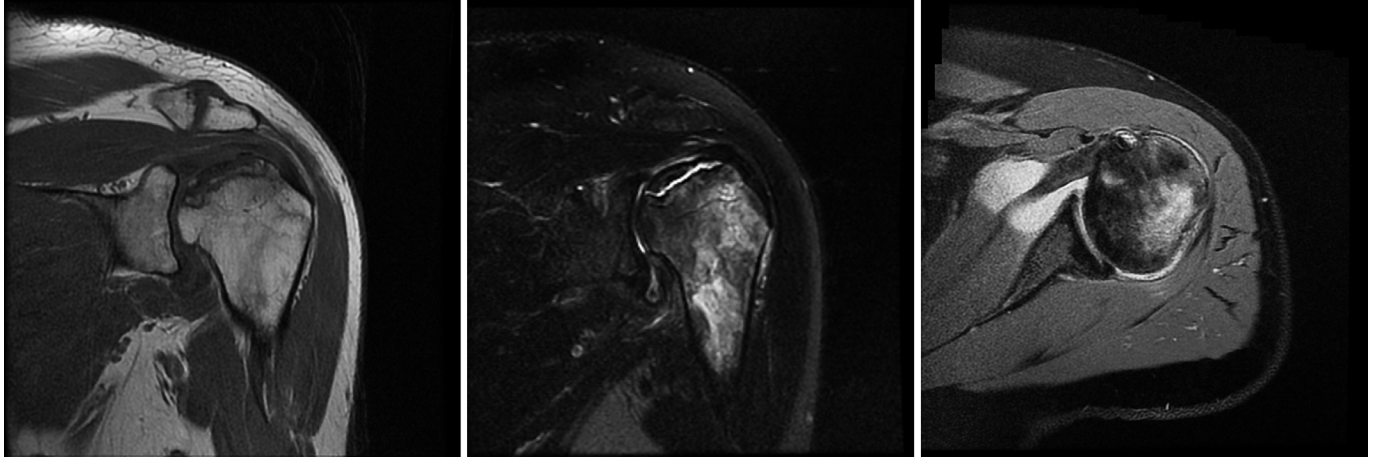


Figure 3. MRI Scan of the left shoulder showing subchondral sclerosis and fracture with bone marrow oedema extending to the proximal humeral shaft. These findings are in keeping with AVN. From left to right; Coronal T1 weighted slice, Coronal T2 weighted slice, Axial proton density fat saturation image.

The agreed management plan focused on pain management, activity modification, and referring the patient for an ultrasound-guided hydrodilatation. Three weeks later, the hydrodilatation of the shoulder was performed, with no complications, by injecting 5mls of 1% lignocaine and 5mls of marcaine 0.25% for local anesthetic and then 40mls of 0.9% saline for the dilatation with ultrasound guidance. There were no corticosteroids used during the procedure.

The patient was followed up at one week via telephone and at six weeks face to face. The treatment has improved the range of motion, but significant pain was still present. On examination, he had a positive impingement test and a positive glenohumeral stress test. The patient was offered the option of a surgical hemiarthroplasty of the shoulder but declined surgical intervention at this stage. The decision was therefore made to perform an interval MRI scan, which is awaited.

Discussion

AVN is debilitating with an insidious onset. AVN most commonly affects the femoral head of the hip joint, with the second most common site being the humeral head. The most commonly reported risk factor for AVN is steroid use. Other common risk factors include alcohol abuse, pancreatitis, and trauma. It is important to remember that a small number of cases are idiopathic with no attributable risk factors.⁴

Common symptoms include pain and loss of motion. On examination, a common finding is a limited range of motion, crepitus, and weakness of the rotator cuff and deltoid muscles. AVN is investigated and diagnosed clinically and radiologically. Initially, plain radiographs of the shoulder should be ordered, including AP, lateral and axillary-Y views. Radiological signs are best demonstrated on an AP view with the shoulder in neutral rotation. At the early stages of AVN, no findings on X-ray are present. However, as the condition progresses, osteolytic lesions develop, demonstrating resorption of the subchondral

necrosis. The most common initial site is the superior middle portion of the humeral head. The 'Crescent sign' indicates subchondral collapse and may progress to depression of the articular surface and consequent osteoarthritic changes. The gold standard imaging modality is MRI, which carries around 100% sensitivity in detecting bone edema at the site of subchondral sclerosis. MRI can also be useful for the detection of early or subclinical AVN. Treatment may be close observation for very early and minimally symptomatic disease. Initially, this includes pain management and activity modification with physiotherapy. Surgical management is indicated for progressive symptoms in the setting of moderate to advanced disease.^{4,5}

Certainly, we cannot establish singular or general causality between our patient developing AVN of the humeral head and receiving the COVID-19 vaccine. However, the sudden onset of symptoms directly after vaccination and the absence of known AVN raises the possibility of a potential new side of the vaccine or risk factor for AVN.

It is important to question the assumption of causality in this case as the patient had risk factors for developing AVN in his past medical history. These included previous alcohol excess, chronic pancreatitis, and previous corticosteroid treatment for hepatitis. Firstly, it is unlikely that his alcohol excess added significant risk as he had been abstinent for almost a year before the onset of his symptoms. Secondly, his history of corticosteroid treatment; although the most common risk factor, his treatment had ceased at least two years prior to the onset of symptoms. Steroids usually increase the risk of developing AVN for six months to 1-year post-treatment.⁶ Lastly, the patient's chronic pancreatitis; his last acute episode was over one year prior to his shoulder symptoms. Nevertheless, he had presented to the emergency department with an episode of abdominal pain four months prior, but an acute flare-up was not

confirmed at this time. It is important to mention that a CT scan performed during this episode and prior to the second vaccination did not show obvious AVN in the left shoulder or any radiological signs of pancreatitis. A review of his medical notes revealed that his abdominal pain spontaneously resolved within 24 hours, and the only treatment he received was simple analgesics. The timing of his symptoms and administration of his vaccine suggest vaccination is a much more likely cause compared to his other risk factors.

The pathogenesis of AVN remains to be fully understood. A possible mechanism behind the development of AVN, in this case, could be related to hypercoagulability. Several studies have suggested that increased intravascular coagulation due to hypercoagulability is the potential pathogenic mechanism, hypothesizing that microvascular thrombosis forms as a result of endothelial damage, resulting in AVN distal to the site of arterial obstruction.^{7,8}

Sequentially, a systematic review looking at the relationship between COVID-19 and AVN suggested that infection can induce endothelial dysfunction, resulting in hypercoagulability. In turn, this hypercoagulability increases the risk of thrombosis and, thus, avascular necrosis.⁹ Importantly, as observed in COVID-19 infection, COVID-19 vaccines may induce a hypercoagulable state,

with multiple cases of post-vaccination thrombosis being reported. Though studies reported the incidence of such cases is low.¹⁰

We are therefore concluding that there is a strong possibility that the COVID vaccine increased the risk of this 40-year-old man developing AVN of the humeral head. Considering a large number of vaccinated patients and the lack of reporting of this association, this is an exceptional case. Due to the insidious nature of the disease, often without a clear inciting event, other cases have been missed or under-reported. Even without being able to confirm causality, this report should serve to increase awareness and raise suspicion so that cases of AVN may be recognized, diagnosed, and managed early.

Abdulrahman KASHKOSH MBBS¹
Christopher M. PEAKE MBBS BSc MRCS²
A. Ali NARVANI, MBBS MSc (Sports Med) FRCS (Tr & Orth)²
MA IMAM MD MSc DSportMed PhD FRCS (Tr & Orth)²
1 Bradford Teaching Hospital Foundation Trust, United Kingdom
2 Department of Orthopaedics Ashford and St Peter's Hospitals NHS Foundation Trust, Chertsey, United Kingdom

References

1. ECDC. COVID-19 situation update worldwide. European Centre for Disease Prevention and Control An agency of the European Union. Available at: <https://www.ecdc.europa.eu/en/geographical-distribution-2019-ncov-cases>. Accessed June 21, 2022.
2. Baden LR, El Sahly HM, Essink B, et al. Efficacy and safety of the mRNA-1273 SARS-CoV-2 vaccine. *New England Journal of Medicine*. 2021 4;384(5):403-16. DOI: 10.1056/NEJMoa2035389
3. GOV.UK. ARCHIVE: Information for UK recipients on Pfizer/BioNTech COVID-19 vaccine (Regulation 174). Available at: <https://www.gov.uk/government/publications/regulatory-approval-of-pfizer-biontech-vaccine-for-covid-19/information-for-uk-recipients-on-pfizerbiontech-covid-19-vaccine>. Accessed January 6, 2023.
4. Hasan SS, Romeo AA. Nontraumatic osteonecrosis of the humeral head. *J Shoulder Elbow Surg*. 2002;11(3):281-98. doi: 10.1067/mse.2002.124347. <https://doi.org/10.1067/mse.2002.124347>
5. Herman K, Pękala P, Szwedowski D, Grabowski R, Cholewiński J. Avascular Necrosis. *In Joint Function Preservation 2022* (pp. 161-171). Springer, Cham. DOI: 10.1007/978-3-030-82958-2_14
6. Assouline-Dayan Y, Chang C, Greenspan A, Shoenfeld Y, Gershwin ME. Pathogenesis and natural history of osteonecrosis. *Semin Arthritis Rheum*. 2002;32(2):94-124.
7. Lykissas MG, Gelalis ID, Kostas-Agnantis IP, Vozonelos G, Korompilias AV. The role of hypercoagulability in the development of osteonecrosis of the femoral head. 2012;4(2):e17. doi: 10.4081/or.2012.e17.
8. Kerachian MA, Harvey EJ, Cournoyer D, Chow TY, Séguin C. Avascular necrosis of the femoral head: vascular hypotheses. *Endothelium*. 2006;13(4):237-44. doi: 10.1080/10623320600904211.
9. Daltro G, Silva IC, Daltro PB, Silva IC, Botelho VL. SARS-CoV-2/COVID-19 and its implications in the development of osteonecrosis. *J Regen Biol Med*. 2020;2(4):1-9. [https://doi.org/10.37191/Mapsci-2582-385X-2\(4\)-035](https://doi.org/10.37191/Mapsci-2582-385X-2(4)-035)
10. Long B, Bridwell R, Gottlieb M. Thrombosis with thrombocytopenia syndrome associated with COVID-19 vaccines. *Am J Emerg Med*. 2021;49:58-61. doi: 10.1016/j.ajem.2021.05.054.