

**CURRENT CONCEPTS REVIEW****Modern Treatment Principles for Multiligament Knee Injuries**Jacob A. Braaten, BA<sup>1,2</sup>; Foley J. Schreier, B.S<sup>1,3</sup>; Ariel N. Rodriguez MS<sup>1,4</sup>; Jill Monson, PT<sup>5,6</sup>; Robert F. LaPrade, MD, PhD<sup>1</sup>*Research performed at the Research was performed at Twin Cities Orthopedics, Edina, Minnesota, USA**Received: 06 September 2021**Accepted: 13 December 2021***Abstract**

Multiligament knee injuries are complex injuries that must be addressed with a comprehensive diagnostic workup and treatment plan. Multiligament injuries are commonly observed with concomitant meniscal, chondral, and neurovascular injuries, requiring a thorough clinical assessment and radiographic evaluation. Due to the higher failure rates associated with knee ligament repair following multiligament knee injury, the current literature favors single-stage anatomic knee reconstructions. Recent studies have also optimized graft sequencing and reconstruction tunnel orientation to prevent graft elongation and reduce the risk of tunnel convergence. In addition, anatomic-based ligament reconstruction techniques and the usage of suture anchors now allow for early postoperative knee motion without the risk of stretching out the graft. Rehabilitation following multiligament knee reconstruction should begin on postoperative day one and typically requires 9-12 months. The purpose of this article is to review the latest principles of the surgically relevant anatomy, biomechanics, evaluation, treatment, rehabilitation, and outcomes of multiligament knee injuries.

**Level of evidence:** V**Keywords:** Anterior cruciate, Multiple ligament reconstruction, Posterior cruciate**Introduction**

A multiligament knee injury is defined as a tear of at least two of the four major structures of the knee: the anterior cruciate ligament (ACL), posterior cruciate ligament (PCL), posteromedial corner (PMC), and the posterolateral corner (PLC), which stabilize the knee throughout the full range of motion. Multiligament knee injuries can be caused by a variety of mechanisms, including high and low-energy accidents, and are generally classified by a system that categorizes the anatomical patterns of torn ligaments [Table 1].<sup>1</sup> The approach to treatment and rehabilitation of multiligament knee injuries has evolved over the past decade. Recent studies have demonstrated improved outcomes associated with anatomic-based reconstructions that utilize a biomechanically validated approach.<sup>2-6</sup> These findings are reinforced by additional studies which report improved outcomes following single-stage multiligament reconstructions and rehabilitation which emphasizes early knee movement and proper bracing.<sup>7-9</sup>

**Table 1. Classification of Knee Dislocation**

Classification	Criteria
KD I	Injury to single cruciate ligament and collaterals
KD II	Injury to ACL and PCL with intact collaterals
KD III M	Injury to ACL, PCL, and MCL
KD III L	Injury to ACL, PCL, and FCL
KD IV	Injury to ACL, PCL, MCL, and FCL
KD V	Periarticular fracture dislocation

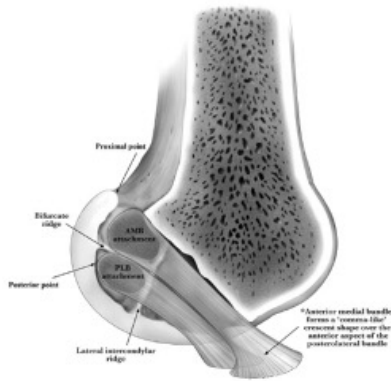
**Surgically Relevant Anatomy for Multiple Ligament Knee Injuries****Anterior Cruciate Ligament (ACL)**

The ACL has two functional bundles which attach posteriorly to the femoral lateral intercondylar ridge: the anteromedial (AM) and posterolateral (PL) bundles.

**Corresponding Author:** Robert F. LaPrade, Twin Cities Orthopedics, Edina-Crosstown, Edina, MN 55435, USA  
Email: laprademdphd@gmail.com



THE ONLINE VERSION OF THIS ARTICLE  
ABJS.MUMS.AC.IR



**Figure 1.** A diagram of the lateral femoral condyle of the left knee in extension. The relationship of the anteromedial bundle (AMB) and posterolateral bundle (PMB) to surgically-relevant bony landmarks is illustrated.<sup>10</sup>

The AM and PL bundles are separated by the bifurcate ridge at the site of femoral attachment.<sup>10</sup> On the tibia, the ACL center inserts 10.5 mm posterior to the ACL ridge, 13.0 mm anterior to the retro-emergence ridge, 7.5 mm medial to the anterior horn of the lateral meniscus, and 15.7 mm anterior to the posterior root attachment of the lateral meniscus.<sup>10</sup> It is surgically relevant to note that the ACL tibial attachment is essentially adjacent to the anterior horn of the lateral meniscus. Furthermore, in an electron microscopy study, Steineman et al reported a significant overlap of the ACL and anterolateral meniscal root tibial footprints. This is critically important because the lateral placement of the tibial ACL tunnel may cause iatrogenic injury to the anterior lateral root attachment during ACL reconstruction.<sup>11</sup> In relation to the AM and PL bundles, the center of the ACL attaches to the tibia 4.8 mm posterior to the AM bundle center and 5.6 mm anterior to the center of the PL bundle [Figure 1].<sup>10</sup> The principal blood supply to the ACL is the middle genicular artery.<sup>12</sup>

### Posterior Cruciate Ligament (PCL)

As the largest and strongest intra-capsular ligament of the knee, the primary function of the PCL is to restrain posterior tibial translation. The PCL consists of two co-dependent bundles: an anterolateral bundle (AL) and a posteromedial bundle (PM). The femoral attachment of the AL bundle is on the roof of the notch, with its distal edge adjacent to the articular cartilage, and its center located 7.4 mm from the trochlear point, 11.0 mm from the medial arch point, 7.9 mm from the distal articular cartilage, and 12.1 mm from the PM bundle center.<sup>13,14</sup> The femoral attachment of the PM bundle is on the wall of the medial aspect of the intercondylar notch, 18.8 mm from the trochlear point, 11.1 mm from the medial arch point, and 10.8 mm from the posterior point of the articular cartilage margin.<sup>13,14</sup> On the tibia, the PCL bundles are more compact, with the mean distance between AL and PM bundle centers being 8.9 mm.<sup>14</sup> The tibial bundles are separated by the bundle ridge, which

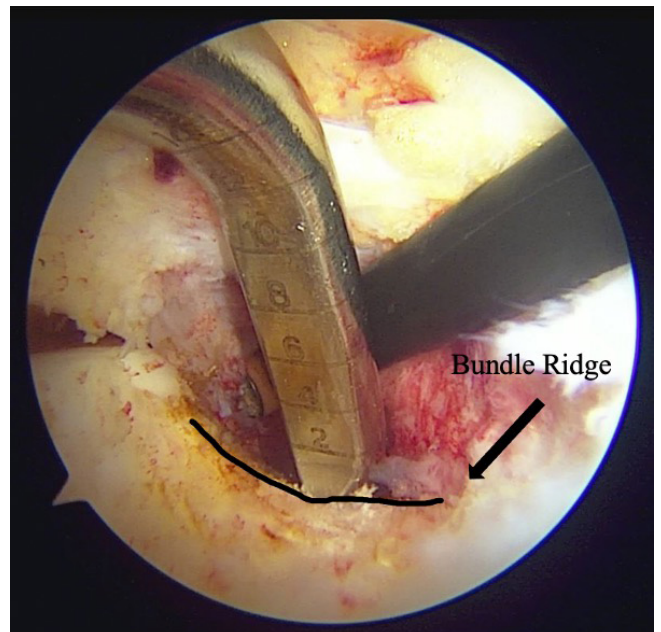
is an important intra-operative surgical landmark [Figure 2]. The PCL is innervated by branches of the tibial nerve and the principal blood supply of the PCL is the medial genicular artery.

### Posteromedial Corner (PMC)

The main structures of the posteromedial corner (PMC) of the knee consist of the superficial MCL (sMCL), deep MCL (dMCL), and posterior oblique ligament (POL). The femoral attachment of the sMCL is in an osseous depression 3.2 mm proximal and 4.8 mm posterior to the medial epicondyle.<sup>15</sup> The femoral attachment of the sMCL can also be identified by palpating the adductor tubercle, which is found by isolating out the adductor magnus tendon, which is known as the "lighthouse of the medial knee." From there, the sMCL is located 12 mm distal and 8 mm anterior to the adductor tubercle.<sup>16</sup>

The sMCL has two tibial attachments. The proximal tibial attachment of the sMCL primarily attaches to the soft tissue anterior arm of the semimembranosus tendon, one cm distal to the joint line.<sup>15,16</sup> The distal tibial attachment of the sMCL forms the floor of the pes anserine bursa and attaches 6 cm distal to the joint line.<sup>16</sup>

The dMCL consists of a thickening of the medial joint capsule that is distinct from the sMCL. The dMCL originates on the femur, 1 cm distal to the femoral attachment of the sMCL, where it runs deep to the sMCL to attach to the medial meniscus, forming the meniscotibial and meniscofemoral divisions. The meniscotibial division of the dMCL attaches 3.2 mm



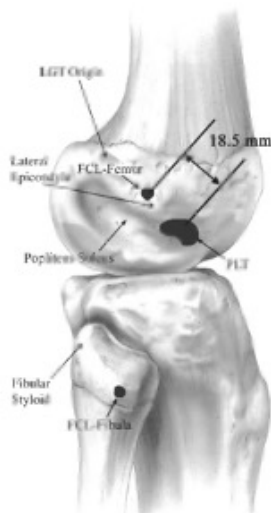
**Figure 2.** Intraoperative arthroscopic image of a right knee double-bundle posterior cruciate ligament (PCL) reconstruction. The surgeon is seen cauterizing the PCL tibial attachment site slightly above the bundle ridge with the PCL tibial guide anchored on the bundle ridge. The recommended posterior exit point for the guide pin is just proximal to the bundle ridge.<sup>73</sup>

distal to the tibial joint line and the menisofemoral division of the dmCL attaches 15.7 mm proximal to the femoral joint line.<sup>16,17</sup>

The POL consists of three fascial attachments which reinforce the posteromedial aspect of the joint capsule.<sup>17</sup> The central arm is the thickest and most important portion of the POL and originates from the distal tibial expansion of the semimembranosus tendon. As it fans out posterolaterally, the central arm reinforces the dmCL and attaches to the femur 7.7 mm distal and 2.9 mm anterior to the gastrocnemius tubercle.<sup>15-17</sup>

### Posterolateral Corner (PLC)

The posterolateral corner of the knee is comprised of three major static stabilizers: the fibular collateral ligament (FCL), popliteus tendon (PLT), and popliteofibular ligament (PFL) [Figure 3]. The FCL originates on the lateral aspect of the femur, 1.4 mm proximal and 3.1 mm posterior to the lateral epicondyle.<sup>3,18</sup> Along its course, the FCL runs deep to the iliotibial (IT) band and inserts on a depression located 8.2 mm posterior to the anterior margin of the fibular head and 28.4 mm distal to the fibular styloid tip.<sup>19</sup> In comparison, the PLT originates 18.5 mm anterior to the femoral attachment of the FCL within the anterior half of the popliteal sulcus, a relationship that is highly useful during anatomic reconstruction.<sup>3</sup> As it departs its femoral attachment, the PLT courses under the FCL and wraps posterodistally around the popliteal sulcus until it inserts on the posteromedial tibia. The musculotendinous junction of the popliteus tendon is located approximately 54.5 mm from the femoral attachment and gives rise to the anterior and



**Figure 3.** A lateral view illustration of the right knee fibular collateral ligament (FCL) attachment sites on the femur and fibula. The popliteus tendon (PLT) originates in the popliteus sulcus, which is located, on average, 18.5 mm from the FCL femoral attachment site. The origin of the lateral gastrocnemius tendon (LGT) is also noted.<sup>2</sup>

posterior divisions of the PFL.<sup>19</sup> The anterior division of the PFL attaches on the anteromedial downslope of the fibula, 2.8 mm distal to the tip of the styloid process. The posterior division of the PFL attaches 1.6 mm distal to the posteromedial aspect of the apex of the fibular styloid.<sup>3,5</sup>

### Clinically and Surgically Relevant Biomechanics

Understanding the surgically relevant biomechanical function of the major ligaments of the knee is necessary for a successful multiligament reconstruction. This is increasingly true as surgical management moves towards anatomic-based reconstructions which emphasize the reproduction of native knee biomechanics and allow for early knee motion postoperatively without a risk of the grafts stretching out. Previous studies have demonstrated that biomechanically validated anatomic reconstructions effectively restore knee range of motion and stability; anatomic reconstruction also facilitates early passive knee motion and is associated with decreased rates of arthrofibrosis without concern of stretching out the graft.<sup>2,4,6,7,9,20,21</sup>

It is important to recognize that the biomechanical function of the major ligaments of the knee is highly interconnected and co-dependent upon the integrity of other structures. Thus, staged surgery, rather than reconstruction of all torn ligaments in one stage, runs the risk of having reconstruction grafts stretch out due to their co-dependent nature.

In addition, concurrent ligament reconstruction poses a unique challenge to the surgeon in that proper graft fixation sequencing is critical in restoring native tibiofemoral orientation. A recent tensioning sequence study by Moatshe et al reported that in the case of bicruciate and PLC reconstruction, tensioning the PLC prior to the cruciate ligaments should be avoided due to excessive internal rotation of the tibia. The authors recommended that the PCL bundles be tensioned first, followed by the ACL to prevent posterior translation of the tibia, and then the PLC structures last.<sup>22</sup>

The ACL is the primary restraint against anterior tibial translation and internal rotation of the knee.<sup>23</sup> The length of the ACL bundles is highly dependent upon knee position. To prevent graft stretching during ACL reconstruction, the ACL graft is tightened in full knee extension. This is because the AM bundle shortens 1.9 mm and the PL bundle shortens 7.1 mm as the knee begins to flex until 60° of flexion is reached.<sup>24</sup> Tightening in flexion could overconstrain the graft, which would increase the risk of it stretching out. In addition, the force transmitted through the AM bundle is greatest at 60° and 90° of flexion, whereas the force transmitted through the PL bundle is greatest in full knee extension.<sup>12</sup> The mediolateral fibers of the ACL also provide rotational stability of the knee by resisting internal rotation of the tibia relative to the femur.

Concomitant injury to the medial and lateral structures of the knee can increase the risk of ACL graft failure. In a study of 19,457 patients, Svantesson et al reported that, compared to an isolated ACL injury, concomitant MCL injury was associated with an increased risk

of undergoing ACL revision.<sup>25</sup> Injury to the PLC has also been recognized as a predominant cause of ACL graft failure.<sup>26</sup> In a biomechanical study, LaPrade et al reported that following sectioning of the PLC, isolated varus and combined varus/internal rotation forces led to significantly increased joint loads on the ACL graft. To decrease the risk of graft failure, the authors advocated that PLC reconstruction should be strongly considered at the same time as ACL reconstruction.<sup>27</sup>

The primary function of the PCL was to resist posterior translation of the tibia relative to the femur at all angles of knee flexion. It was previously believed that the functions of the AL and PM bundles of the PCL were independent, yet reciprocal.<sup>28</sup> However, recent studies now suggest that the bundles function synergistically to resist posterior tibial translation at all angles of knee flexion.<sup>13,29</sup> This finding implies the significance of both bundles in maintaining knee stability. As a result, the latest principles of operative management now emphasize reproducing native knee anatomy and biomechanics.

Wijdicks et al concluded that, compared to a single-bundle PCL reconstruction (PCLR), anatomic double-bundle PCLR was superior in restoring near-native knee kinematics and resulted in decreased posterior tibial translation at all angles of knee flexion tested (15° - 120°), other than full extension.<sup>30</sup> Furthermore, the PCL also works in conjunction with the PLC to stabilize the knee against a coupled external rotation torque and posterior translation forces.<sup>31</sup> LaPrade et al reported that injury to the PLC resulted in significantly increased PCL loading forces on the posterior drawer and external rotation analysis. Therefore, to decrease the risk of graft failure, the PLC should be reconstructed at the same time as PCL reconstruction in patients who demonstrate combined varus laxity and/or posterior drawer and external rotation instability.<sup>32</sup> While some feel that a double bundle PCLR may be too complicated to perform at the time of an MLI reconstruction, it does increase the chance of an improved objective outcome and a more stable knee over time.

The load-sharing relationship among the sMCL, dMCL, and POL is complex and highly dependent on the angle of knee flexion. Overall, the MCL is the primary static restraint to valgus stress and stabilizes the knee against secondary rotary and translational forces.<sup>17</sup> Specifically, the proximal sMCL is the primary static stabilizer to valgus motion between 0° and 90° of knee flexion.<sup>16,17</sup> The proximal sMCL also serves as a secondary stabilizer against internal and external rotation at specific knee flexion angles.<sup>16</sup> The distal sMCL serves as a secondary

stabilizer against internal rotation at 0°, 30°, and 90° of knee flexion and external rotation at 90°. The dMCL has been shown to contain a lower load-at-failure and displacement-at-failure than the sMCL.<sup>17</sup> In addition, the dMCL experiences maximum strain at full knee extension and serves as a secondary stabilizer against valgus movement and external rotation.<sup>17,34</sup> The POL functions primarily as a stabilizer for internal rotation and also serves as a secondary stabilizer for external rotation and valgus stress.<sup>16</sup>

The main function of the FCL is to stabilize the knee against varus stress throughout the entire range of motion. Previous sectioning studies have reported that when the FCL is cut, the ACL and PCL secondarily stabilize against abnormal varus opening.<sup>18</sup> The FCL also functions to restrain anterior translation of the tibia, particularly when the ACL is torn.<sup>18</sup> In addition, the FCL, in conjunction with the PLT and the PFL, serves as a primary source of stabilization against external rotational forces on the tibia effect and is maximized at 30° of knee flexion.<sup>18</sup> The primary function of the PLT is to stabilize the knee against external rotation. A popliteus cutting study performed by LaPrade et al reported significant increases in external rotation following cutting of the popliteus tendon. This effect was maximized at 90° of knee flexion when a 5-N·m applied torque resulted in 5.9° of increased external rotation, compared to the intact state.<sup>35</sup>

### Clinical Assessment

A comprehensive clinical assessment is invaluable in determining the extent of injury in a multiligament injury. When a multiligament knee injury is suspected, several clinical tests must be used in conjunction with a history of the injury and radiologic evaluation to arrive at an optimal treatment strategy [Tables 2; 3]. In the case of multiple ligament knee injuries, incomplete clinical assessment of the knee may result in unrecognized or mismanaged injury, oftentimes leading to prolonged pain and recurrent knee instability.

In addition, it is paramount to assess the neurovascular status of the patient. In a review of 303 patients with a multiligament knee injury, Moatshe et al reported that vascular injuries were recorded in 5.0% of patients and injuries to the common peroneal nerve were recorded in 19.2% of cases. The authors found that associated vascular injury was 20 times greater among patients with injury to the common peroneal nerve than those without.<sup>36,37</sup> The bottom line is that, while imperfect, clinical assessment of the four main ligamentous structures of the knee remains the best test for knee

**Table 2. Grades of ligamentous laxity by measurement on radiograph**

Grade of ligamentous laxity	ACL ATT (in mm)	PCL PTT (in mm)	MCL valgus gapping (in mm)	LCL (FCL) varus gapping (in mm)
1	3-5 mm	3-5 mm	3-5 mm	3-5 mm
2	5-10 mm	5-10 mm	5-10 mm	5-10 mm
3	>10 mm	>10 mm	>10 mm	>10 mm

**Table 3. Clinical Assessment of Knee Ligament Injuries**

Structure	Test
ACL	Lachman's Test, pivot shift test
PCL	Posterior drawer, posterior sag sign
MCL	Valgus stress test performed at 0° and 30° of flexion; dial test; anteromedial drawer test
LCL (FCL)	Varus stress test performed at 30° of flexion
PLC	Posterolateral drawer, dial tests

patholaxity.<sup>38</sup>

The ACL is typically examined by the Lachman test and the pivot shift test. To determine the degree of laxity, these tests grade the extent of anterior tibial translation relative to the contralateral knee. A positive Lachman is characterized by a soft endpoint and increased anterior tibial translation when the knee is flexed at 20° to 30°. <sup>9</sup> The pivot shift test is also used to test ACL integrity. The pivot shift test applies a combination of axial load and valgus force to reproduce the rotational and translational instability that occurs with an ACL deficiency. During the pivot shift test, the knee is flexed from the full extension with an axial load, internal rotation, and valgus stress. A positive test involves anterior subluxation of the tibia. <sup>39</sup> Increased motion on the Lachman and pivot shift tests usually indicates concomitant meniscal pathology, such as root or ramp tears.

The PCL is examined by the posterior drawer test and the posterior sag test. To perform the posterior drawer test, the examiner should place thumbs on the joint line and apply a posteriorly directed force while the knee is flexed at 90° and the foot is stabilized in a neutral position. <sup>39</sup> To perform the posterior sag test, the patient should lie supine with both knees flexed at 90° such that the examiner can appreciate the loss of anterior tibial step-off without manipulation of the joint. The severe posterior tibial translation is indicative of a combined PCL tear with other pathology (or a flat or anteriorly positioned tibial slope). One cm of subjective anterior tibiofemoral step-off is the standard subjective assessment in uninjured patients and recent studies suggest that the sensitivity and specificity of this test are 79% and 100% respectively. <sup>39,40</sup>

Valgus and varus stress tests are performed to evaluate the MCL and LCL, respectively. When valgus and varus stress are applied, the extent to which medial and lateral joint opening occurs should be appreciated and compared to the contralateral side to assess for physiologic knee laxity. The quality of the endpoint should also be assessed. <sup>40</sup> The patient's knee should be flexed at 30° to isolate the collateral ligaments. Valgus and varus stress should also be applied at full extension to evaluate for concomitant cruciate injury. For valgus stress testing, excessive femorotibial gapping at full extension signals posteromedial capsule injury and associated injury to the cruciate ligaments. <sup>38,39</sup>

The posterolateral drawer and dial tests are performed to evaluate for posterolateral corner (PLC) integrity. To perform the posterolateral drawer test, have the patient

flex their knee 90° and stabilize the foot in a slightly externally rotated position while the clinician applies an external rotation force through the foot and ankle. The amount of posterolateral rotation of the knee should be quantified and compared to the contralateral knee. <sup>40</sup> Additional rotatory instability may be suggestive of isolated PLC injury because the PCL augments translational stability in a neutral position. <sup>39</sup>

The dial test is commonly used to distinguish combined PLC and PCL injury from an isolated PLC injury. With the patient supine or prone, the clinician should externally rotate the patient's tibia flexed first at 30° and then at 90°, compared to the uninjured knee. Furthermore, it can be difficult to distinguish between a PLC and PMC injury. As Griffith et al have noted, a medial-sided knee injury can also result in a positive dial test and cause misdiagnosis of a PMC for a PLC injury. To determine the exact location of the injury, the authors proposed concurrently assessing the extent of anteromedial and posterolateral tibial rotation while performing the dial test in the supine position. <sup>33</sup>

### Radiologic Assessment

In the setting of a multiligament knee injury, there are multiple factors that can influence the reliability and reproducibility of the clinical assessment. The examiner's technique, degree of soft tissue swelling, the patient's pain tolerance and ability to relax during the exam, and the presence of concomitant injury can all contribute as potential sources of error in clinical examination. <sup>41</sup> Therefore, radiologic evaluation is an essential step to provide objective and retrievable information to assist in clinical decision-making. <sup>41,42</sup>

Conventional radiography has proven to be a reliable, reproducible, and inexpensive option for initial radiologic assessment in multiligament knee injuries. <sup>41</sup> When a multiligament injury is suspected, stress radiograph views of the PCL, MCL, and FCL must be obtained and compared to the contralateral knee to objectively determine the extent of a knee injury. MRI is also commonly used to characterize multi-ligamentous knee injuries through precise identification of ligament tears and meniscal pathology [Figure 4]. <sup>43</sup> It is important to note that while beneficial, stress radiography is imperfect. As noted by LaPrade et al, patient guarding and muscle contractions due to pain can lead to varying radiographic results. <sup>44</sup>

Varus and valgus stress radiographs are commonly performed to identify the degree of laxity and gapping

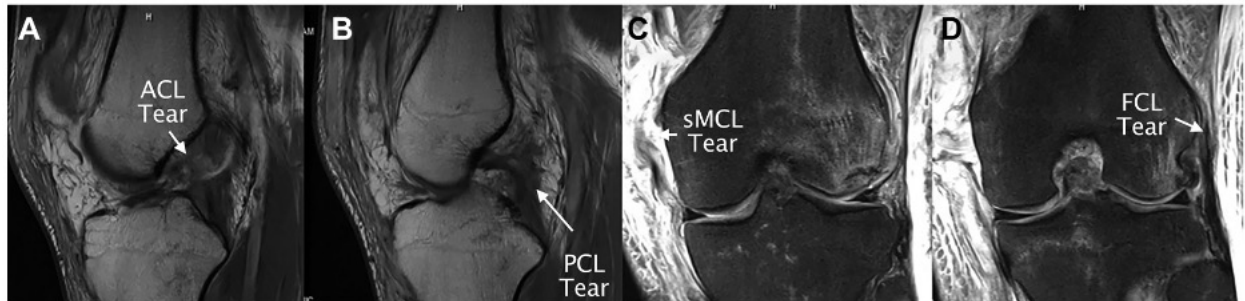


Figure 4. Preoperative T2-weighted magnetic resonance imaging (MRI) series of the left knee in a single patient. An ACL tear (A) and a PCL tear (B) are observed in the sagittal plane. A proximal sMCL tear (C) and a FCL tear (D) are also present in the coronal plane. ACL, anterior cruciate ligament; PCL, posterior cruciate ligament; sMCL, superficial medial collateral ligament; FCL, fibular collateral ligament.<sup>9</sup>

Table 4. Knee stress radiograph assessment and indication					
Varus stress test		Valgus stress test		Kneeling stress radiographs	
< 2.7 mm	None or partial FCL tear	< 3.2 mm	None or partial MCL tear	0 – 7 mm PTT	None to high grade partial PCL tear
2.7 – 4.0 mm	Isolated FCL tear	3.2 – 9.8 mm	Complete tear of superficial MCL	8 – 11 mm PTT	Complete PCL tear
≥ 4.0 mm	Complete PLC injury	≥ 9.8 mm	Complete tear of all medial structures	≥ 12 mm PTT	Combined ligament injury or flat tibial slope

in the collateral ligaments (MCL and LCL) of the knee [Table 4]. Varus and valgus stress radiographs are performed at 20° of knee flexion by placing a radiotransparent cushion immediately posterior to the knee.

When valgus stress is applied to the knee flexed at 20°, an opening of the femorotibial space greater than 3.2 mm

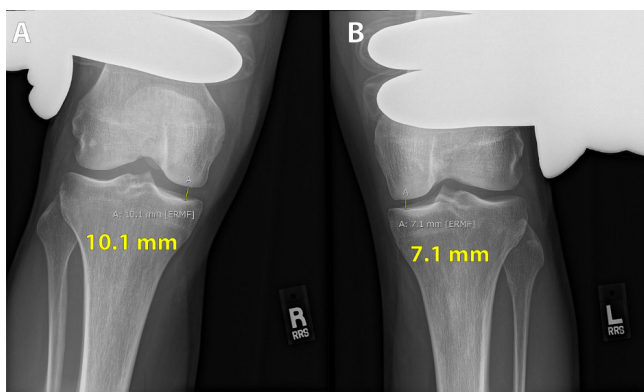


Figure 5. Valgus stress radiographs of the right (A) and left (B) knee at 20° of knee flexion which show a 3.0 mm difference of side-to-side medial compartment gapping compared to the uninjured left knee. LaPrade et al described a threshold of 3.2 mm of side-to-side differences of medial compartment gapping for the diagnosis of a grade III medial collateral ligament (MCL) tear.<sup>44</sup>

indicates at least an isolated MCL lesion. [Figure 5] When the knee is flexed at 20° and varus stress is applied, gapping of greater than 2.7 mm is indicative of an isolated FCL tear. [Figure 6] If lateral compartment gapping of greater than 4.0 mm is appreciated, this is indicative of a combined FCL and posterolateral corner lesion.<sup>41,43,44</sup>

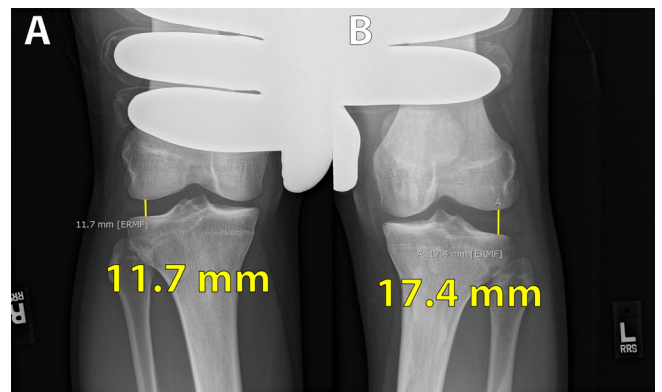
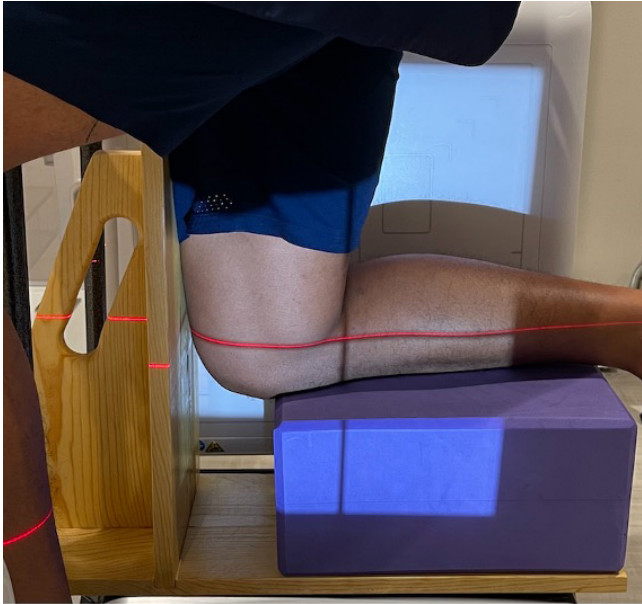


Figure 6. Varus stress radiographs of the right (A) and left (B) knee which show a 5.7 mm difference of side-to-side lateral compartment gapping compared to the uninjured right knee. A difference greater than 2.7 mm is suggestive of an isolated FCL lesion, while a difference greater than 4.0 mm is suggestive of a combined PLC and FCL lesion.



**Figure 7.** The setup for posterior cruciate ligament (PCL) kneeling stress radiographs. The right tibial tubercle is aligned with the left edge of the blue cushion and the entirety of the patient's weight is placed on the right knee flexed at 90°. Since the anterior femoral aspect is unsupported, the PCL restrains distal displacement of the femur. A PCL injury will lead to increased displacement compared to an uninjured knee.<sup>74</sup>

Kneeling stress radiographs are used to assess for increased posterior tibial translation due to PCL injury. To obtain this image, the patient positions their flexed knee at 90° and on a flat, elevated surface. The tibial joint line should align with the edge of the surface and all of the patient's body weight should be placed on the flexed knee such that their condyles are superimposed on the image [Figure 7].<sup>41</sup> To determine the extent of posterior tibial translation, a line should be drawn along the posterior tibial cortex to at least 15 cm distal to the joint line and then another perpendicular line drawn from this line to the posterior point of the Blumensaat line.<sup>13</sup> Isolated PCL injury is commonly associated with the posterior tibial translation of 5 to 12 mm. Posterior tibial translation of greater than 12 mm is typically indicative of combined PCL and posterolateral or posteromedial structure injury but can also be observed with a flatter tibial slope.<sup>41,45</sup>

### Treatment of Multiligament Knee Injuries

The objective of treating a multiligament knee injury is to provide the patient with improved long-term knee stability and function. Past systematic reviews have reported that surgical management outcomes are superior to the outcomes of non-surgical treatment of multiligament knee injuries.<sup>46-48</sup> Nonetheless, factors like advanced age, comorbidity, additional trauma, and poor patient compliance contribute to the continuation of non-surgical treatment.<sup>46</sup> In a systematic review of

31 studies comparing operative and non-operative outcomes following multiligament injury, Peskin et al found superior surgical outcomes associated with various activities.<sup>46</sup> They reported that 80.9% of surgical patients returned to employment vs 57.8% for the nonoperative cohort. Fifty percent of surgical patients returned to athletic activity compared to 22.2% of non-operative cohorts. The authors also found that Lysholm scores were significantly different at 84.3 and 67.2, respectively for the surgical and non-surgical cohorts.<sup>46,48</sup>

There has been much debate in the literature regarding the surgical treatment of multiligament knee injuries. When comparing surgical repair and reconstruction, several studies have demonstrated that reproducing the native anatomy via reconstruction provides superior stability outcomes.<sup>21</sup> Mariani et al found that patients who underwent repair of cruciate ligaments experienced increased rates of flexion deficit greater than 60, posterior tibial instability, and decreased rates of return to pre-injury.<sup>36,49</sup> Direct repair of combined ACL/PCL injury was also reported to have a higher rate of a posterior sag sign than reconstruction.<sup>48</sup>

In a study of 63 patients with a multiligament injury, Stannard et al reported posterolateral corner injury reconstruction failure rates of 9% compared to 37% in patients who underwent repair.<sup>50</sup> Levy et al found failure rates of 40% in the repair group vs 6% in the reconstruction group.<sup>51</sup> Overall, reconstruction of the cruciate ligaments is widely accepted, whereas, in some cases (such as bony avulsion injuries), repair of the collateral ligaments may occasionally be recommended.<sup>36,52</sup>

There is currently no consensus on the optimal timing of surgery for multiligament knee injuries. Acute surgery is generally considered to be within three weeks of injury.<sup>48</sup> In delaying operative treatment, surgeons must consider the risk of increased scarring and tissue necrosis which can lead to poorer outcomes.<sup>36</sup> However, especially in the case of high energy trauma, operative treatment may be delayed due to life-threatening polytrauma or excessive injury to the soft tissue of the knee, limiting range of motion. In a systematic review which included five studies, Levy et al found that patients demonstrated appropriate final mean range of motion and flexion loss regardless of surgical timing.<sup>48</sup> However, in a report of patient outcomes following single-stage multiligament reconstruction, LaPrade et al found that early surgery (<4 weeks) and early knee range of motion was associated with significantly improved Lysholm scores compared to delayed surgery (>4 weeks).<sup>9</sup> In those cases where surgery may need to be delayed, placement of the patient into a PCL dynamic brace is often indicated to avoid posterior tibial subluxation in patients with a severe PCL tear.

The distal femur and proximal tibia are structures of limited bone volume and density. Therefore, during knee reconstruction it is imperative to avoid tunnel convergence which may result in compromise of reconstruction graft integrity and knee stability [Table 5]. Moatshe et al

**Table 5. Pearls of Multiligament Knee Injury Treatment****Treatment Pearls**

Position the patient to allow for full flexion and extension of the knee.

It is critical that the grafts are the correct diameters and lengths to ensure smooth passage through the tunnel.

Reconstruction tunnels should be drilled at the anatomic footprint of the injured ligaments.

Tunnel orientation should be pre-planned to avoid convergence. To reduce the risk of convergence with the ACL tunnel, the femoral FCL and popliteus tunnels should be aimed anteriorly.

The usage of acorn reamers allows for minor adjustments to the tunnel path, eliminating the need for repositioning of guide pins.

The PCL should be tensioned first at 90° to restore the normal tibial step-off, followed by the ACL, FCL, popliteus components and the PMC.

Early protected range of motion is critical to decrease stiffness and risk of arthrofibrosis.

defined that a 2 mm clearance between tunnels was the minimum safe distance to maintain bone mass integrity during knee reconstruction.<sup>52</sup> This study found the highest risk of femoral tunnel convergence occurred when the PMC and PLC reconstruction tunnels were angled 0° along both the axial and coronal planes. To avoid convergence with the ACL tunnel, the FCL tunnel should be aimed at 35° to 40° in the axial plane and 0° in the coronal plane [Figure 8].<sup>52</sup> On the medial side of the knee, avoidance was maximized in sMCL and PCL reconstruction when the sMCL tunnel was aimed at 40° proximally and 20° to 40° anteriorly. When considering a POL-associated reconstruction, the femoral tunnel for the posterior oblique femoral tunnel and the sMCL should be drilled 20°/20° and 40°/40° in the axial and coronal planes, respectively [Figure 9].<sup>52,53</sup>

The tensioning sequence of grafts can significantly affect tibiofemoral orientation. Wentorf et al conducted

a biomechanical study that found that tensioning of the ACL can increase external tibial rotation in patients with posterolateral corner deficiency.<sup>54</sup> The authors advocated for PLC sequencing followed by the ACL graft. Furthermore, Markolf et al reported that the PCL should be fixed prior to ACL reconstruction.<sup>55</sup>

Moatshe et al proposed a biomechanically validated and optimized tensioning sequence. First, the ALB of the PCL should be fixed at 90° with the tibia in a reduced position and distal traction applied.<sup>36</sup> Then, the PMB of the PCL should be fixed in full extension with distal traction applied. The ACL should then be fixed near full extension. Next, the FCL should be fixed at 20°-30° of flexion with an applied slight valgus reduction force. Finally, the rest of the PLC structures should be fixed at 60° of knee flexion with the foot in neutral rotation.<sup>21,22,30</sup>

The use of allografts vs autografts is a current topic

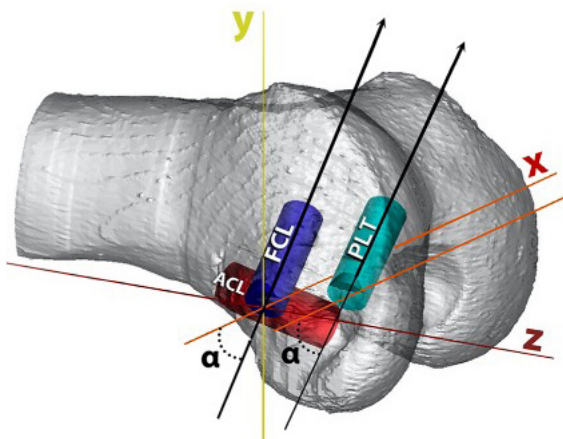


Figure 8. With the patient in the supine position, the fibular collateral ligament (FCL) tunnel should be aimed 35° anteriorly ( $\alpha = 35^\circ$ ) to avoid tunnel convergence with the anterior cruciate ligament (ACL). The popliteus tendon (PLT) tunnel is drilled parallel to the FCL tunnel, at a 35° angle anterior ( $\alpha = 35^\circ$ ) to the horizontal plane (x-axis).<sup>52</sup>

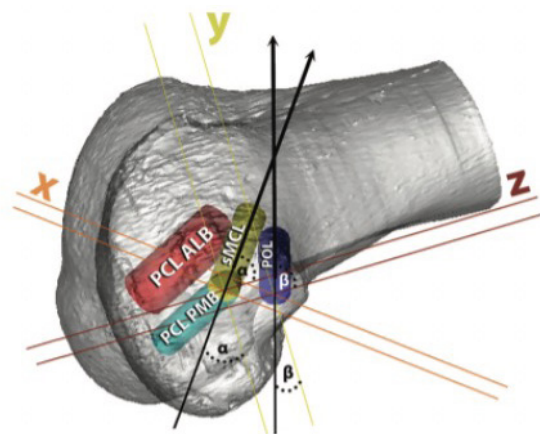
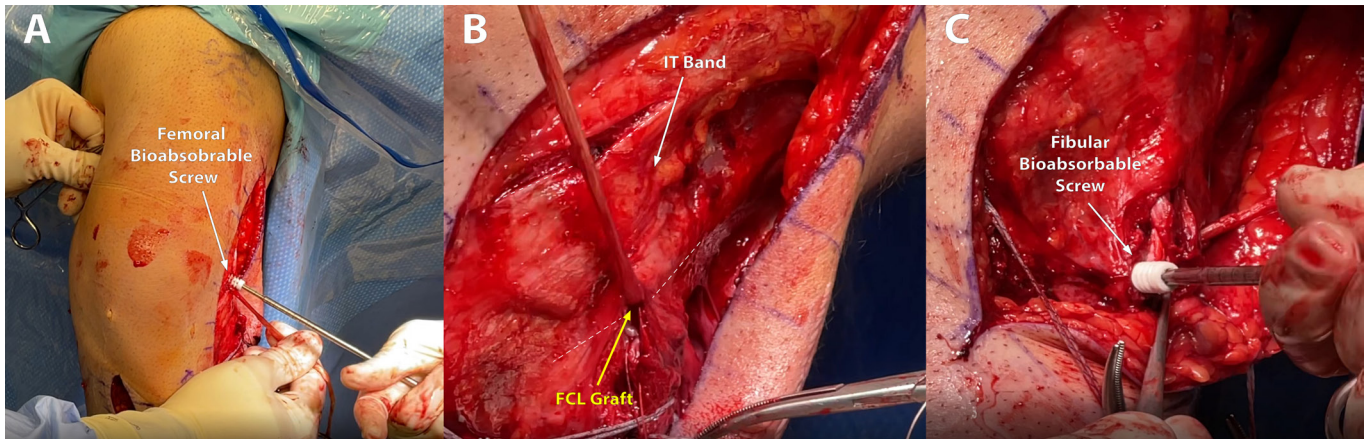


Figure 9. With the patient in the supine position, the superficial medial collateral ligament (sMCL) tunnel should be aimed 40° anteriorly and proximally ( $\alpha = 40^\circ$ ) to avoid collision with the posteromedial bundle (PMB) of the posterior cruciate ligament (PCL). To avoid the sMCL tunnel, the posterior oblique ligament (POL) should be aimed 20° anteriorly and proximally ( $\alpha = 20^\circ$ ). PCL ALB, posterior cruciate ligament anterolateral bundle; PCL PMB, posterior cruciate ligament posteromedial bundle.<sup>52</sup>





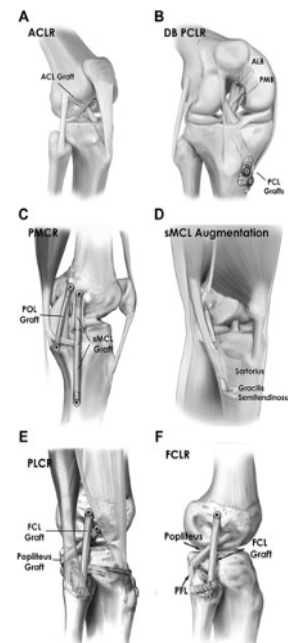
**Figure 10.** Intraoperative imaging of FCL graft reconstruction. (A) illustrates the fixation of the FCL graft to the femoral tunnel utilizing a 7mm by 20 mm bioabsorbable screw; (B) illustrates passage of the FCL graft through a channel created by the surgeon under the iliotibial band and the long head of the biceps, followed by passage through the fibular head tunnel; (C) illustrates fixation of the FCL graft within the fibular head tunnel using a 7 mm by 20 mm bioabsorbable screw, while the knee is held in 20° flexion, neutral rotation, and with valgus force.

of debate in the literature. Allograft usage in ACL replacement is associated with decreased surgical time, fewer postoperative complications, and a faster pace of recovery. However, allograft usage has also been associated with increased risk of graft failure, higher risk of disease transmission, and is typically more expensive.<sup>56</sup> Therefore, it is the senior author's preference to utilize BTB autografts in almost all patients with a multiligament knee injury. The surgeon must also consider the type of injury and availability of autografts as part of the treatment workup for multiple ligament knee injuries.

Initially, the surgeon typically performs an open approach to the injured medial and/or lateral knee structures prior to arthroscopy. This allows for easier soft tissue visualization, identification, and tagging of torn structures, and decreases fluid extravasation [Figure 10].

For the treatment of complete medial knee injuries (involving the sMCL, dMCL, and POL), past studies have recommended an anatomic reconstruction of the superficial MCL and POL. This approach utilizes two individual grafts and four reconstruction tunnels to reproduce native knee anatomy. To access the femoral and tibial superficial MCL attachment points, an anteromedial incision is made along the medial side of the knee. The incision should originate between the patella and the adductor tubercle and extend 8 cm distally to the medial tibia.<sup>36,57</sup>

On the lateral side of the knee, we recommend an anatomic-based surgical technique developed by LaPrade et al<sup>4</sup> which uses a split Achilles graft to reconstruct the FCL, popliteofibular ligament and popliteus tendon.<sup>4</sup> Finally, anatomic single-bundle ACL and double bundle PCL reconstructions are performed [Figure 11]. It is essential that all present meniscal and chondral lesions be addressed prior to graft fixation [Table 6].<sup>36</sup>



**Figure 11.** Illustration of several reconstruction techniques used for multiligament knee reconstruction. (A) Single-bundle ACL reconstruction with a patellar tendon graft. (B) Double-bundle PCL reconstruction of the right knee using allografts. (C) Left knee reconstruction of the sMCL and POL based on a technique developed by LaPrade et al.<sup>(4)</sup> (D) Left knee sMCL augmentation using gracilis and semitendinosus autograft. (E) A complete posterolateral knee reconstruction. (F) Isolated FCL reconstruction.<sup>(9)</sup> ACL, anterior cruciate ligament; ACLR, anterior cruciate ligament reconstruction; DB PCLR, double-bundle posterior cruciate ligament reconstruction; ALB, anterolateral bundle; PMB, posteromedial bundle; PMCR, posteromedial corner reconstruction; POL, posterior oblique ligament; sMCL, superficial medial collateral ligament; PLCR, posterolateral corner reconstruction; FCL, fibular collateral ligament; FCLR, fibular collateral ligament reconstruction; PFL, popliteofibular ligament.

**Table 6. Pitfalls of Multiligament Knee Injury Treatment****Treatment Pitfalls**

Incorrect sizing of grafts may complicate graft passage through the tunnels and decrease knee stability.
Life-threatening complications can result if the neurovascular status of the patient isn't sufficiently evaluated.
Failure to recognize associated meniscal injury can limit long-term knee stability and function.
Malpositioning of the PCL and ACL tibial tunnels can potentially injure the posterior root of the medial and anterior horn of the lateral menisci.
Anterior to posterior placement of fibular tunnel orientation results in short and nonanatomic graft placement.

**Outcomes**

Restoring knee stability and function after dislocation or multiligament injury can be complex due to the heterogeneity of injury patterns. Surgical treatment has been shown to be significantly better at improving outcomes than nonsurgical treatment.<sup>46,47,58</sup> Surgical treatment of the cruciate ligaments in patients with traumatic multiligament injuries is reported to lead to superior subjective knee scores and improved rates of working and sports ability after treatment than nonoperative options.<sup>58</sup>

Hatch et al sought to determine factors that influence the quality of life outcomes in patients after multiligament knee reconstruction.<sup>8</sup> They reported that patients with a prior history of knee ligament reconstruction had significantly worse quality of life based on the Multiligament Quality of Life assessment (ML-QOL). It was also reported that patients with a Schenk classification III or IV had worse ML-QOL scores than patients classified with Schenk I or II. According to Levy et al, patients under 30 years of age at the time of multiligament reconstruction have better IKDC and Lysholm scores at long-term follow-up compared to a cohort older than 30 years of age.<sup>59</sup> This information may be useful in counseling patients prior to reconstruction and to help set expectations for recovery. It should be stated clearly that surgical reconstruction has demonstrated superior outcomes to nonoperative management.

Anatomic reconstruction of multiligament injuries has been found to be significantly better at restoring knee function and is associated with lower failure rates than repair.<sup>36,49-51</sup> Early functional rehabilitation has been shown to be a critical factor for predicting prognosis after traumatic multiligament injury. Multiligament reconstruction is necessary to establish stability to allow for functional rehabilitation.<sup>58</sup> It has been reported that early reconstruction (within 3 weeks of injury) results in better outcomes than delayed reconstruction (greater than 3 weeks after injury).<sup>60</sup> Significant trauma, life-threatening injuries, soft tissue swelling, or other orthopedic injuries may be rationale for delaying initial reconstruction. LaPrade et al showed in a biomechanical study that an injured PLC affects PCL graft forces.<sup>32</sup> These findings suggest that staging surgery could lead to graft failure. Additionally, LaPrade et al reported that single-stage anatomic reconstructions lead to significantly improved outcomes with low complication rates.<sup>9</sup> In addition, postoperative stress

radiographs demonstrated that an early range of motion program starting on day one was safe and did not result in any grafts stretching out. Arthrofibrosis occurred in about 10% of patients, all treated in the acute phase, which is in accordance with previous reports that showed acutely treated MLI resulted in higher rates of arthrofibrosis than chronically treated MLI. These patients were treated with reintervention surgery. In conclusion, acute, single-stage anatomic reconstruction with early functional rehabilitation is the preferred treatment method in the setting of multiligament knee injuries.

**Postoperative Rehabilitation**

Due to the various patterns of injury and extensive damage to the soft tissue structures of the knee, rehabilitation following multiligament reconstruction is challenging. Critical rehabilitation goals in the early recovery period include protecting the reconstructions through bracing and weight bearing (WB) precautions, symptom management, early range of motion (ROM), quadriceps muscle activation, and patient education regarding precautions and expectations. Patients remain non-weight bearing (NWB) for the first 6 weeks following surgery with a knee immobilizer to stabilize the joint. Patients with PCL reconstruction (PCLR) will transition into a dynamic PCL brace to support the healing grafts as soon as swelling reduces sufficiently for proper brace fit. Bracing is advocated until stress x-rays demonstrate satisfactory joint stability 6 months after surgery and throughout the first year after surgery for patients returning to sports.

Starting on day one after surgery, the patient can initiate ROM gradually working up to, but not beyond, 90° of flexion within the "critical period" of the first two weeks following surgery.<sup>36</sup> Flexion progresses beyond 90° after 2 weeks. Hyperextension is avoided in the first 8 weeks following reconstruction of structures that natively restrict knee hyperextension (PCL, PLC, FCL) to avoid graft elongation.<sup>61</sup> A meta-analysis by Mook et al, reported that early knee mobilization was associated with decreased posterior instability as well as decreased varus and valgus laxity in a group of acutely treated patients.<sup>7</sup> Moreover, a recent trend towards single-staged concurrent ligament reconstruction has allowed for early knee mobilization which helps avoid graft failure and decrease joint stiffness.<sup>9,36</sup> In the case of PCLR, a prone passive range of motion is advocated in the first 2 weeks after surgery to minimize excessive

posterior tibial sag-related limb position and excessive posterior tibial translation (PTT) associated with hamstring muscle activation.<sup>62,63</sup>

Early ROM has become feasible in recent years, as emergent anatomic-based knee ligament reconstruction techniques and increased usage of suture anchors for capsular and tendon repairs reduce the risk of potential graft disruption and repair elongation, thereby decreasing the risk of developing arthrofibrosis due to an extended period of immobilization.<sup>21</sup> Emerging evidence supports the safety and efficacy of early ROM including a recent study by LaPrade et al examining the patient outcomes of 194 single-stage multiligament knee reconstructions.<sup>9</sup> Patients followed a rehabilitation protocol utilizing immediate post-operative knee ROM and graft elongation was not observed.<sup>9</sup>

Recovery from multiligament knee reconstruction typically requires 9-12 months. After the initial recovery period, the rehabilitation program focuses on rebuilding muscular strength and restoring balance and joint proprioception, cardiovascular fitness, power, and athletic capacity per the extent of the injury, prior level of function, and the joint's tolerance to therapy progressions. Muscle strengthening efforts can be maximized and muscular atrophy mitigated during the early WB restricted phase through modalities such as neuromuscular electrical stimulation (NMES) and blood flow restriction (BFR) therapy.<sup>64-66</sup> Beyond that time, the progression of a well-designed loading program is advocated for ongoing strength gains. Progression through rehabilitation phases and the return to sport process, when appropriate, should be gradual and criteria based. Testing is conducted at intervals throughout the first year of recovery and should be comprehensive, including patient-reported outcome measures, functional testing (balance, squat, hop testing), isolated muscle strength testing, and motion analysis if available.<sup>67</sup> Return to sport, as best described in ACL literature, is advocated if a patient tolerates progressions into more challenging and sport-specific activities and exhibits a recovery to 90% muscle strength and hop performance compared to

the uninjured limb.<sup>68,69</sup> Strength and hop performance should also reach a sufficient threshold relative to the patient's physical size (height, weight), pre-injury performance levels, or the performance of age/sex/sport-matched healthy patients.<sup>70-72</sup>

Multiligament knee injuries are complex and present unique challenges to the surgeon due to the frequent involvement of meniscal and neurovascular injuries. Proper treatment requires a thorough clinical and radiographic evaluation prior to operative management. Single-stage anatomic knee reconstruction is currently the preferred surgical treatment for multiligament knee injuries. Optimal graft sequencing and reconstruction orientation is essential to reduce the risk of tunnel convergence and graft failure. Anatomically oriented techniques for multiligament knee injury reconstruction now allow for early knee motion that is initiated on day one of the postoperative period. Early knee motion has been shown to decrease the risk of joint arthrofibrosis and does not increase the risk of stretching out the graft.

Jacob A. Braaten BA<sup>1,2</sup>

Foley J. Schreier BS<sup>1,3</sup>

Ariel N. Rodriguez MS<sup>1,4</sup>

Jill Monson PT<sup>5,6</sup>

Robert F. LaPrade MD PhD<sup>1</sup>

1 Twin Cities Orthopedics, Edina-Crosstown, 4010 W 65th St, Edina, MN 55435, USA

2 University of Minnesota Medical School, 420 Delaware St SE, Minneapolis, MN 55455 USA

3 University of North Dakota School of Medicine and Health Sciences, 1301 N Columbia Rd, Grand Forks, ND 58203, USA

4 Georgetown University School of Medicine, 3900 Reservoir Rd NW, Washington, DC 20007, USA

5 Twin Cities Orthopedics, 2700 Vikings Cir, Eagan, MN 55121, USA

6 Training Haus, 2645 Vikings Cir Suite 200, Eagan, MN 55121, USA

## References

1. Schenck R. Classification of knee dislocation. *Operative Techniques in Sports Medicine*. 2003;11:193-8. <https://doi.org/10.1053/otsm.2003.35918>
2. LaPrade RF, Johansen S, Wentorf FA, Engebretsen L, Esterberg JL, Tso A. An analysis of an anatomical posterolateral knee reconstruction: an in vitro biomechanical study and development of a surgical technique. *Am J Sports Med*. 2004;32(6):1405-14. doi: 10.1177/0363546503262687.
3. James EW, LaPrade CM, LaPrade RF. Anatomy and biomechanics of the lateral side of the knee and surgical implications. *Sports Med Arthrosc Rev*. 2015;23(1):2-9. doi: 10.1097/JSA.0000000000000040.
4. LaPrade RF, Wijdicks CA. Surgical technique: development of an anatomic medial knee reconstruction. *Clin Orthop Relat Res*. 2012;470(3):806-14. doi: 10.1007/s11999-011-2061-1.
5. LaPrade RF, Ly TV, Wentorf FA, Engebretsen L. The posterolateral attachments of the knee: a qualitative and quantitative morphologic analysis of the fibular collateral ligament, popliteus tendon, popliteofibular ligament, and lateral gastrocnemius

- tendon. *Am J Sports Med.* 2003;31(6):854-60. doi: 10.1177/03635465030310062101.
6. Kennedy NI, LaPrade RF, Goldsmith MT, et al. Posterior cruciate ligament graft fixation angles, part 2: biomechanical evaluation for anatomic double-bundle reconstruction. *Am J Sports Med.* 2014;42(10):2346-55. doi: 10.1177/0363546514541226.
  7. Mook WR, Miller MD, Diduch DR, Hertel J, Boachie-Adjei Y, Hart JM. Multiple-ligament knee injuries: a systematic review of the timing of operative intervention and postoperative rehabilitation. *J Bone Joint Surg Am.* 2009;91(12):2946-57. doi: 10.2106/JBJS.H.01328.
  8. Hatch GFR, 3rd, Villacis D, Damodar D, Dacey M, Yi A. Quality of Life and Functional Outcomes after Multiligament Knee Reconstruction. *J Knee Surg.* 2018;31(10):970-8. doi: 10.1055/s-0038-1626737.
  9. LaPrade RF, Chahla J, DePhillipo NN, Cram T, Kennedy MI, Cinque M, et al. Single-Stage Multiple-Ligament Knee Reconstructions for Sports-Related Injuries: Outcomes in 194 Patients. *Am J Sports Med.* 2019;47(11):2563-71. doi: 10.1177/0363546519864539.
  10. Ziegler CG, Pietrini SD, Westerhaus BD, et al. Arthroscopically pertinent landmarks for tunnel positioning in single-bundle and double-bundle anterior cruciate ligament reconstructions. *Am J Sports Med.* 2011;39(4):743-52. doi: 10.1177/0363546510387511.
  11. Steineman BD, Moulton SG, Haut Donahue TL, et al. Overlap Between Anterior Cruciate Ligament and Anterolateral Meniscal Root Insertions: A Scanning Electron Microscopy Study. *Am J Sports Med.* 2017;45(2):362-8. doi: 10.1177/0363546516666817.
  12. Siegel L, Vandenakker-Albanese C, Siegel D. Anterior cruciate ligament injuries: anatomy, physiology, biomechanics, and management. *Clin J Sport Med.* 2012;22(4):349-55. doi: 10.1097/JSM.0b013e3182580cd0.
  13. Pache S, Aman ZS, Kennedy M, et al. Posterior Cruciate Ligament: Current Concepts Review. *Arch Bone Jt Surg.* 2018;6(1):8-18.
  14. Anderson CJ, Ziegler CG, Wijdicks CA, Engebretsen L, LaPrade RF. Arthroscopically pertinent anatomy of the anterolateral and posteromedial bundles of the posterior cruciate ligament. *J Bone Joint Surg Am.* 2012;94(21):1936-45. doi: 10.2106/JBJS.K.01710.
  15. LaPrade RF, Engebretsen AH, Ly TV, Johansen S, Wentorf FA, Engebretsen L. The anatomy of the medial part of the knee. *J Bone Joint Surg Am.* 2007;89(9):2000-10. doi: 10.2106/JBJS.F.01176.
  16. Cinque ME, Chahla J, Kruckeberg BM, DePhillipo NN, Moatshe G, LaPrade RF. Posteromedial Corner Knee Injuries: Diagnosis, Management, and Outcomes: A Critical Analysis Review. *JBJS Rev.* 2017;5(11):e4. doi: 10.2106/JBJS.RVW.17.00004.
  17. LaPrade MD, Kennedy MI, Wijdicks CA, LaPrade RF. Anatomy and biomechanics of the medial side of the knee and their surgical implications. *Sports Med Arthrosc Rev.* 2015;23(2):63-70. doi: 10.1097/JSA.0000000000000054.
  18. Moorman CT, 3rd, LaPrade RF. Anatomy and biomechanics of the posterolateral corner of the knee. *J Knee Surg.* 2005;18(2):137-45. doi: 10.1055/s-0030-1248172.
  19. Chahla J, Moatshe G, Dean CS, LaPrade RF. Posterolateral Corner of the Knee: Current Concepts. *Arch Bone Jt Surg.* 2016;4(2):97-103.
  20. Serra Cruz R, Mitchell JJ, Dean CS, Chahla J, Moatshe G, LaPrade RF. Anatomic Posterolateral Corner Reconstruction. *Arthrosc Tech.* 2016;5(3):e563-72. doi: 10.1016/j.eats.2016.02.006.
  21. Geeslin AG, LaPrade RF. Outcomes of treatment of acute grade-III isolated and combined posterolateral knee injuries: a prospective case series and surgical technique. *J Bone Joint Surg Am.* 2011;93(18):1672-83. doi: 10.2106/JBJS.J.01639.
  22. Moatshe G, Chahla J, Brady AW, et al. The Influence of Graft Tensioning Sequence on Tibiofemoral Orientation During Bicuruciate and Posterolateral Corner Knee Ligament Reconstruction: A Biomechanical Study. *Am J Sports Med.* 2018;46(8):1863-9. doi: 10.1177/0363546517751917.
  23. Domnick C, Raschke MJ, Herbolt M. Biomechanics of the anterior cruciate ligament: Physiology, rupture and reconstruction techniques. *World J Orthop.* 2016;7(2):82-93. doi: 10.5312/wjo.v7.i2.82.
  24. Duthon VB, Barea C, Abrassart S, Fasel JH, Fritschy D, Ménétrey J. Anatomy of the anterior cruciate ligament. *Knee Surg Sports Traumatol Arthrosc.* 2006;14(3):204-13. doi: 10.1007/s00167-005-0679-9.
  25. Svantesson E, Hamrin Senorski E, Alentorn-Geli E, et al. Increased risk of ACL revision with non-surgical treatment of a concomitant medial collateral ligament injury: a study on 19,457 patients from the Swedish National Knee Ligament Registry. *Knee Surg Sports Traumatol Arthrosc.* 2019;27(8):2450-9. doi: 10.1007/s00167-018-5237-3.
  26. O'Brien SJ, Warren RF, Pavlov H, Panariello R, Wickiewicz TL. Reconstruction of the chronically insufficient anterior cruciate ligament with the central third of the patellar ligament. *J Bone Joint Surg Am.* 1991;73(2):278-86.
  27. LaPrade RF, Resig S, Wentorf F, Lewis JL. The effects of grade III posterolateral knee complex injuries on anterior cruciate ligament graft force. A biomechanical analysis. *Am J Sports Med.* 1999;27(4):469-75. doi: 10.1177/03635465990270041101.
  28. Boutefnouchet T, Bentayeb M, Qadri Q, Ali S. Long-term outcomes following single-bundle transtibial arthroscopic posterior cruciate ligament reconstruction. *Int Orthop.* 2013;37(2):337-43. doi: 10.1007/s00264-012-1609-3.
  29. Fox RJ, Harner CD, Sakane M, Carlin GJ, Woo SL. Determination of the in situ forces in the human posterior cruciate ligament using robotic technology. A cadaveric study. *Am J Sports Med.* 1998;26(3):395-401. doi: 10.1177/03635465980260030901.
  30. Wijdicks CA, Kennedy NI, Goldsmith MT, et al. Kinematic analysis of the posterior cruciate ligament, part 2: a comparison of anatomic single- versus double-bundle

- reconstruction. *Am J Sports Med.* 2013;41(12):2839-48. doi: 10.1177/0363546513504384.
31. Logterman SL, Wydra FB, Frank RM. Posterior Cruciate Ligament: Anatomy and Biomechanics. *Curr Rev Musculoskelet Med.* 2018;11(3):510-4. doi: 10.1007/s12178-018-9492-1.
  32. LaPrade RF, Muench C, Wentorf F, Lewis JL. The effect of injury to the posterolateral structures of the knee on force in a posterior cruciate ligament graft: a biomechanical study. *Am J Sports Med.* 2002;30(2):233-8. doi: 10.1177/03635465020300021501.
  33. Griffith CJ, LaPrade RF, Johansen S, Armitage B, Wijdicks C, Engebretsen L. Medial knee injury: Part 1, static function of the individual components of the main medial knee structures. *Am J Sports Med.* 2009;37(9):1762-70. doi: 10.1177/0363546509333852.
  34. Robinson JR, Bull AM, Thomas RR, Amis AA. The role of the medial collateral ligament and posteromedial capsule in controlling knee laxity. *Am J Sports Med.* 2006;34(11):1815-23. doi: 10.1177/0363546506289433.
  35. LaPrade RF, Wozniczka JK, Stellmaker MP, Wijdicks CA. Analysis of the static function of the popliteus tendon and evaluation of an anatomic reconstruction: the "fifth ligament" of the knee. *Am J Sports Med.* 2010;38(3):543-9. doi: 10.1177/0363546509349493.
  36. Moatshe G, Chahla J, LaPrade RF, Engebretsen L. Diagnosis and treatment of multiligament knee injury: state of the art. *Journal of ISAKOS.* 2017;2(3):152-61. <https://doi.org/10.1136/jisakos-2016-000072>
  37. Moatshe G, Dornan GJ, Løken S, Ludvigsen TC, LaPrade RF, Engebretsen L. Demographics and Injuries Associated With Knee Dislocation: A Prospective Review of 303 Patients. *Orthop J Sports Med.* 2017;5(5):2325967117706521. doi: 10.1177/2325967117706521.
  38. Skendzel JG, Sekiya JK, Wojtys EM. Diagnosis and management of the multiligament-injured knee. *J Orthop Sports Phys Ther.* 2012;42(3):234-42. doi: 10.2519/jospt.2012.3678.
  39. Buyukdogan K, Laidlaw MS, Miller MD. Surgical Management of the Multiple-Ligament Knee Injury. *Arthrosc Tech.* 2018;7(2):e147-e64. doi: 10.1016/j.eats.2017.08.079.
  40. Bronstein RD, Schaffer JC. Physical Examination of Knee Ligament Injuries. *J Am Acad Orthop Surg.* 2017;25(4):280-7. doi: 10.5435/JAAOS-D-15-00463.
  41. Rocha de Faria JL, Pedrinha ISM, Pavão DM, et al. Stress Radiography for Multiligament Knee Injuries: A Standardized, Step-by-Step Technique. *Arthrosc Tech.* 2020;9(12):e1885-e92. doi: 10.1016/j.eats.2020.08.015.
  42. James EW, Williams BT, LaPrade RF. Stress radiography for the diagnosis of knee ligament injuries: a systematic review. *Clin Orthop Relat Res.* 2014;472(9):2644-57. doi: 10.1007/s11999-014-3470-8.
  43. Helito P, Peters B, Helito C, Dyck P. Imaging evaluation of the multiligament injured knee. *Annals of Joint.* 2018;3(9):UNSP-80.
  44. LaPrade RF, Bernhardtson AS, Griffith CJ, Macalena JA, Wijdicks CA. Correlation of valgus stress radiographs with medial knee ligament injuries: an in vitro biomechanical study. *Am J Sports Med.* 2010;38(2):330-8. doi: 10.1177/0363546509349347.
  45. Jackman T, LaPrade RF, Pontinen T, Lender PA. Intraobserver and interobserver reliability of the kneeling technique of stress radiography for the evaluation of posterior knee laxity. *Am J Sports Med.* 2008;36(8):1571-6. doi: 10.1177/0363546508315897.
  46. Peskun CJ, Whelan DB. Outcomes of operative and nonoperative treatment of multiligament knee injuries: an evidence-based review. *Sports Med Arthrosc Rev.* 2011;19(2):167-73. doi: 10.1097/JSA.0b013e3182107d5f.
  47. Dedmond BT, Almekinders LC. Operative versus nonoperative treatment of knee dislocations: a meta-analysis. *Am J Knee Surg.* 2001;14(1):33-8.
  48. Levy BA, Dajani KA, Whelan DB, et al. Decision making in the multiligament-injured knee: an evidence-based systematic review. *Arthroscopy.* 2009;25(4):430-8. doi: 10.1016/j.arthro.2009.01.008.
  49. Mariani PP, Santoriello P, Iannone S, Condello V, Adriani E. Comparison of surgical treatments for knee dislocation. *Am J Knee Surg.* 1999;12(4):214-21.
  50. Stannard JP, Brown SL, Farris RC, McGwin G, Jr, Volgas DA. The posterolateral corner of the knee: repair versus reconstruction. *Am J Sports Med.* 2005;33(6):881-8. doi: 10.1177/0363546504271208.
  51. Levy BA, Dajani KA, Morgan JA, Shah JP, Dahm DL, Stuart MJ. Repair versus reconstruction of the fibular collateral ligament and posterolateral corner in the multiligament-injured knee. *Am J Sports Med.* 2010;38(4):804-9. doi: 10.1177/0363546509352459.
  52. Moatshe G, Brady AW, Slette EL, et al. Multiple Ligament Reconstruction Femoral Tunnels: Intertunnel Relationships and Guidelines to Avoid Convergence. *Am J Sports Med.* 2017;45(3):563-9. doi: 10.1177/0363546516673616.
  53. Moatshe G, Slette EL, Engebretsen L, LaPrade RF. Intertunnel Relationships in the Tibia During Reconstruction of Multiple Knee Ligaments: How to Avoid Tunnel Convergence. *Am J Sports Med.* 2016;44(11):2864-9. doi: 10.1177/0363546516656371.
  54. Wentorf FA, LaPrade RF, Lewis JL, Resig S. The influence of the integrity of posterolateral structures on tibiofemoral orientation when an anterior cruciate ligament graft is tensioned. *Am J Sports Med.* 2002;30(6):796-9. doi: 10.1177/03635465020300060701.
  55. Markolf KL, O'Neill G, Jackson SR, McAllister DR. Reconstruction of knees with combined cruciate deficiencies: a biomechanical study. *J Bone Joint Surg Am.* 2003;85(9):1768-74. doi: 10.2106/00004623-200309000-00016.
  56. Sun J, Wei XC, Li L, et al. Autografts vs Synthetics for Cruciate Ligament Reconstruction: A Systematic Review and Meta-Analysis. *Orthop Surg.* 2020;12(2):378-87. doi: 10.1111/os.12662.

57. Wijdicks CA, Griffith CJ, Johansen S, Engebretsen L, LaPrade RF. Injuries to the medial collateral ligament and associated medial structures of the knee. *J Bone Joint Surg Am.* 2010;92(5):1266-80. doi: 10.2106/JBJS.I.01229.
58. Richter M, Bosch U, Wippermann B, Hofmann A, Krettek C. Comparison of surgical repair or reconstruction of the cruciate ligaments versus nonsurgical treatment in patients with traumatic knee dislocations. *Am J Sports Med.* 2002;30(5):718-27. doi: 10.1177/03635465020300051601.
59. Levy NM, Krych AJ, Hevesi M, et al. Does age predict outcome after multiligament knee reconstruction for the dislocated knee? 2- to 22-year follow-up. *Knee Surg Sports Traumatol Arthrosc.* 2015;23(10):3003-7. doi: 10.1007/s00167-015-3750-1.
60. Hohmann E, Glatt V, Tetsworth K. Early or delayed reconstruction in multi-ligament knee injuries: A systematic review and meta-analysis. *Knee.* 2017;24(5):909-16. doi: 10.1016/j.knee.2017.06.011.
61. Halewood C, Amis AA. Clinically relevant biomechanics of the knee capsule and ligaments. *Knee Surg Sports Traumatol Arthrosc.* 2015;23(10):2789-96. doi: 10.1007/s00167-015-3594-8.
62. Lutz GE, Palmitier RA, An KN, Chao EY. Comparison of tibiofemoral joint forces during open-kinetic-chain and closed-kinetic-chain exercises. *J Bone Joint Surg Am.* 1993;75(5):732-9. doi: 10.2106/00004623-199305000-00014.
63. Markolf KL, O'Neill G, Jackson SR, McAllister DR. Effects of applied quadriceps and hamstrings muscle loads on forces in the anterior and posterior cruciate ligaments. *Am J Sports Med.* 2004;32(5):1144-9. doi: 10.1177/0363546503262198.
64. Hart JM, Pietrosimone B, Hertel J, Ingersoll CD. Quadriceps activation following knee injuries: a systematic review. *J Athl Train.* 2010;45(1):87-97. doi: 10.4085/1062-6050-45.1.87.
65. Toth MJ, Tourville TW, Voigt TB, et al. Utility of Neuromuscular Electrical Stimulation to Preserve Quadriceps Muscle Fiber Size and Contractility After Anterior Cruciate Ligament Injuries and Reconstruction: A Randomized, Sham-Controlled, Blinded Trial. *Am J Sports Med.* 2020;48(10):2429-37. doi: 10.1177/0363546520933622.
66. Hughes L, Paton B, Rosenblatt B, Gissane C, Patterson SD. Blood flow restriction training in clinical musculoskeletal rehabilitation: a systematic review and meta-analysis. *Br J Sports Med.* 2017;51(13):1003-11. doi: 10.1136/bjsports-2016-097071.
67. Ardern CL, Glasgow P, Schneiders A, et al. 2016 Consensus statement on return to sport from the First World Congress in Sports Physical Therapy, Bern. *Br J Sports Med.* 2016;50(14):853-64. doi: 10.1136/bjsports-2016-096278.
68. Buckthorpe M. Optimising the Late-Stage Rehabilitation and Return-to-Sport Training and Testing Process After ACL Reconstruction. *Sports Med.* 2019;49(7):1043-58. doi: 10.1007/s40279-019-01102-z.
69. Grindem H, Snyder-Mackler L, Moksnes H, Engebretsen L, Risberg MA. Simple decision rules can reduce reinjury risk by 84% after ACL reconstruction: the Delaware-Oslo ACL cohort study. *Br J Sports Med.* 2016;50(13):804-8. doi: 10.1136/bjsports-2016-096031.
70. Davies GJ, McCarty E, Provencher M, Manske RC. ACL Return to Sport Guidelines and Criteria. *Curr Rev Musculoskelet Med.* 2017;10(3):307-14. doi: 10.1007/s12178-017-9420-9.
71. Wellsandt E, Failla MJ, Snyder-Mackler L. Limb Symmetry Indexes Can Overestimate Knee Function After Anterior Cruciate Ligament Injury. *J Orthop Sports Phys Ther.* 2017;47(5):334-8. doi: 10.2519/jospt.2017.7285.
72. Gokeler A, Welling W, Benjaminse A, Lemmink K, Seil R, Zaffagnini S. A critical analysis of limb symmetry indices of hop tests in athletes after anterior cruciate ligament reconstruction: A case control study. *Orthop Traumatol Surg Res.* 2017;103(6):947-51. doi: 10.1016/j.otsr.2017.02.015.
73. LaPrade R, Floyd E, Falaas K, et al. The Posterior Cruciate Ligament: Anatomy, Biomechanics, and Double-Bundle Reconstruction. *Journal of Arthroscopic Surgery and Sports Medicine.* 2021;2(2):94-107.
74. LaPrade RF, Cinque ME, Dornan GJ, et al. Double-Bundle Posterior Cruciate Ligament Reconstruction in 100 Patients at a Mean 3 Years' Follow-up: Outcomes Were Comparable to Anterior Cruciate Ligament Reconstructions. *Am J Sports Med.* 2018;46(8):1809-18. doi: 10.1177/0363546517750855.