

**CURRENT CONCEPTS REVIEW**

# Meniscal Root Tears: A Decade of Research on their Relevant Anatomy, Biomechanics, Diagnosis, and Treatment

Mark T. Banovetz BS<sup>1,2</sup>; Lindsay C. Roethke BS<sup>1,2</sup>; Ariel N. Rodriguez MS<sup>1,3</sup>; Robert F LaPrade MD PhD<sup>1</sup>*Research performed at Twin Cities Orthopedics, Edina, MN, USA**Received: 02 February 2021**Accepted: 11 November 2021***Abstract**

A foundational knowledge of the anatomy and biomechanics of meniscal root tears is warranted for proper repair of meniscal root tears and for preventing some of their commonly described iatrogenic causes. Meniscal root tears are defined as either a radial tear occurring within one cm of the root attachment site of the meniscus or a complete bony or soft tissue avulsion of the root attachment altogether. Meniscal root tears disrupt the protective biomechanical function of the native meniscus. Biomechanical analyses of the current techniques for meniscal root repair highlight the importance of restoring menisci to their correct anatomic orientation, thereby restoring their biomechanical function. A comprehensive understanding of the clinical and radiographic presentations of these injuries is critical to preventing their underdiagnosis. The poor long-term outcomes associated with conservative treatment measures, namely, ipsilateral compartment osteoarthritis, warrants the surgical repair of meniscal root tears whenever possible. While excellent patient-reported outcomes exist for the various surgical repair techniques, adherence to stringent post-operative rehabilitation protocols is critical for patients to avoid damaging the integrity of a repaired root. This review will focus on current concepts pertaining to the anatomy, biomechanics, diagnosis, treatment, and postoperative rehabilitation for meniscal root tears.

**Level of evidence:** V**Keywords:** Anterior cruciate ligament, Meniscus, Root**Introduction**

Having been described as a “silent epidemic,” meniscal root tears have gained recent attention for their diagnostic difficulty, inconsistent clinical presentation, and often rapid progression to osteoarthritis (OA) when left untreated (1-3). Past studies have found that meniscal tears are the most common knee abnormality, and they have estimated that tears of the meniscal root account for 10-21% of all meniscal tears (1, 4). Despite their fairly high prevalence, meniscal root tears often go undiagnosed (5). A meniscal root tear is defined as either a radial tear occurring within one cm of the root attachment of the meniscus or a complete bony or soft tissue avulsion of the root

attachment altogether (1, 3, 5-8). Once avulsed from the root attachment site, the meniscus is no longer capable of sufficiently converting axial tibiofemoral loads into hoop stresses (2, 5, 8-15). Extrusion of the meniscus out of the joint space, along with altered load distribution across the tibial plateau, are often the result. This is evidenced by the decreased tibiofemoral contact area and increased contact pressure observed in biomechanical models of the root-deficient knee (1, 2, 4, 6, 11, 16). Increased contact pressure has been linked to insufficiency fractures commonly seen on magnetic resonance imaging (MRI) in the context of meniscal root pathology (14). This finding on MRI has traditionally been referred

**Corresponding Author:** Robert F LaPrade, Twin Cities Orthopedics, Edina-Crosstown, Edina, MN, USA  
Email: laprademdphd@gmail.com



THE ONLINE VERSION OF THIS ARTICLE  
ABJS.MUMS.AC.IR

to as spontaneous osteonecrosis of the knee (SONK), however, recent analysis of the etiology of SONK has led to the suggestion that "SONK" be replaced with the term "subchondral insufficiency fracture" (SIFK) (14). While meniscal extrusion and SONK are helpful for diagnosing meniscal root tears on MRI, these same pathological findings are also associated with the rapid degradation of the articular cartilage and progression to OA seen in meniscus-deficient patients (11, 14).

It is now widely recognized that total meniscectomy reliably leads to rapid progression to OA of the knee, with total knee arthroplasty being the final treatment option. For this reason, treatment measures for meniscal injuries have shifted focus in recent decades toward preserving, repairing, and in some cases, replacing, the menisci. Studies have found that meniscal root tears lead to a biomechanical state that is equivalent to that of a meniscectomized patient (13, 17-19). Furthermore, non-anatomic repair of a torn meniscal root has been shown to be biomechanically equivalent to meniscectomy (20). Together, these findings underscore the importance of preserving the menisci and ensuring that all surgical repairs, especially those of meniscal root tears, return the menisci to their native orientation. Currently, there are several techniques for surgical repair of meniscal root tears described in the literature. This review will focus on the detailed studies over the past decade on the surgically relevant anatomy, biomechanics, and diagnosis of meniscal root tears, as well as the treatments, outcomes, and rehabilitation protocol for patients who experience this injury.

### Anatomy

Traditionally, the medial meniscus has been described as "C-shaped" and the lateral meniscus as "U-shaped." Both menisci have anterior and posterior segments of their curvatures, referred to individually as a "horn," and a central portion of their curvature, referred to as the "body." Each horn is firmly attached to the tibial plateau via a meniscal root. Each root attachment consists of a dense, central fiber attachment with surrounding "supplementary" fibers. Recent anatomic analyses of the meniscal root attachments have elucidated the existence of these supplementary fibers, also referred to as "shiny white fibers," belonging to both the anterior and posterior roots (21). Therefore, anatomic analyses of the meniscal root attachment sites must take into account the footprint of both of these fiber types. Ellman et al. found that these shiny white fibers occupy the posteromedial and posterolateral aspects of the root attachment sites for both posterior roots, making up 46.5% of the attachment surface area and contributing 37.4% of the strength of the native root attachment (22).

Also notable to meniscal anatomy is the anterior intermeniscal ligament, which was reported by Nelson et al. to be the primary attachment site for the anterior horn of the medial meniscus in 24% of knees (23). Because the tibial footprints of the anterior cruciate ligament (ACL) and posterior cruciate ligament (PCL) are in close proximity to the root attachment sites of the menisci, the meniscal roots are at significant risk of

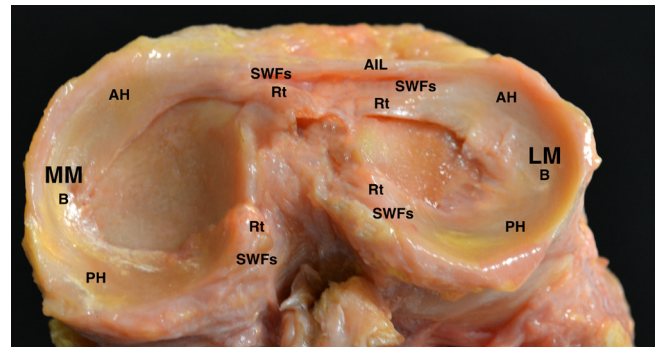


Figure 1. Photograph of a superoposterior view of the tibial plateau demonstrating the qualitative anatomic relationships between important fibrocartilaginous structures and ligamentous insertions. MM, medial meniscus; LM, lateral meniscus; B, body; AH, anterior horn; PH, posterior horn; Rt, root; SWFs, shiny white fibers; AIL, anterior intermeniscal ligament.

injury during procedures to repair these ligaments (1, 10, 24-26). Furthermore, the meniscal roots have also been described to be at risk for experiencing damage during procedures that use intramedullary nailing to fixate tibial shaft fractures [Figure 1] (27).

Vascularity of the menisci has important implications for their ability to heal. A classic 3-zone model has been used to describe the vascularity of the menisci [Figure 2] (4, 28). From innermost to outermost, the three zones (white-white, red-white, and red-red, respectively) are oriented along the circumferential course of each meniscus, spanning from horn-to-horn and progressively increase in vascularity approaching the outer margin of the meniscus (4, 28). The meniscal roots themselves have been noted to be well-vascularized, favoring the success of surgical repairs of meniscal root tears (29).

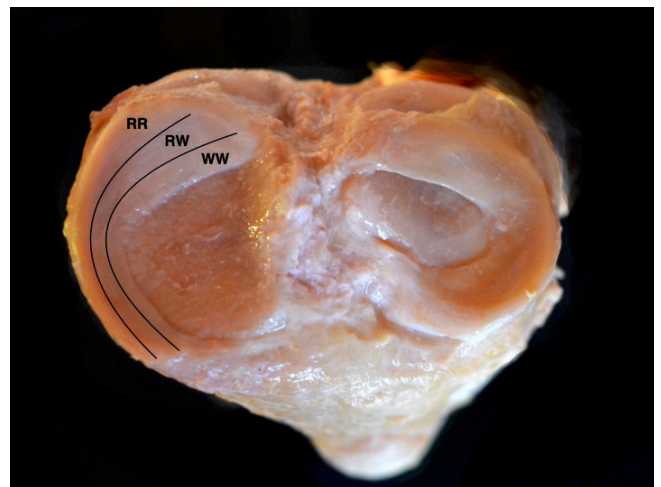
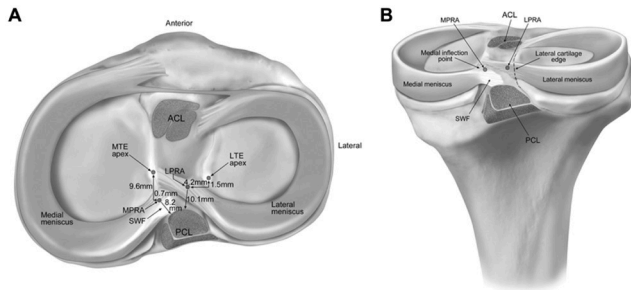


Figure 2. Photograph of a superoanterior view of the tibial plateau with lines superimposed on the medial meniscus approximating the boundaries of the three vascular zones of the meniscus. WW, white-white zone; RW, red-white zone; RR, red-red zone.



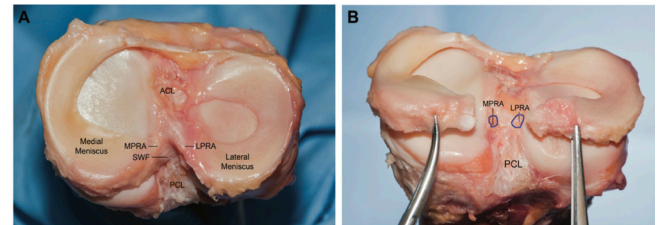
**Figure 3.** Illustration of the tibial plateau from a superior view (A) and posterior view (B). The quantitative anatomical dimensions of the LPRA and MPRA are superimposed upon (A). In both (A) and (B), the footprints of the tibial insertions for both the ACL and PCL are depicted as darkened areas in their respective locations. The shiny white fibers of the MPRA are denoted SWF in both (A) and (B). Reproduced with permission from *AJSM Vol. 40 Issue 10, 2342-2347*.

### Medial Meniscus Posterior Root Attachment (MPRA)

The medial meniscus posterior root attachment (MPRA) is located 9.6 mm posterior and 0.7 mm lateral to the apex of the medial tibial eminence, 3.5 mm lateral to the articular cartilage inflection point of the medial tibial plateau, and 8.2 mm from the superior-most tibial insertion site of the PCL [Figures 3; 4] (9). The MPRA occupies an area of 30.4 mm<sup>2</sup>, while the shiny white (supplementary) fibers belonging to the MPRA are estimated to occupy an area ranging from 47.3 to 69.6 mm<sup>2</sup> up to 80 mm<sup>2</sup> (9). This highlights the importance of using the insertion of the densest fibers as a landmark for choosing tunnel placement when repairing a meniscal root, rather than the geometric center of the entire root attachment site (9). The footprint of the densest fibers of the MPRA indicates the use of a 6mm diameter zone for repairing a tear of the medial posterior meniscal root (9).

### Lateral Meniscus Posterior Root Attachment (LPRA)

The lateral meniscus posterior root attachment (LPRA) is much closer to its anterior counterpart than the MPRA is to the MARA, which is consistent with the medial and lateral menisci being described as “C-” and “U-shaped,” respectively. The LPRA is 10.1 mm from the anterior root attachment (1). Estimates of the LPRA’s posteromedial distance from the apex of the lateral tibial eminence range from 4.2 mm to 5.3 mm (1, 9). The LPRA is located 4.3 mm directly medial to the articular cartilage margin of the lateral tibial plateau, 12.7 mm anterior to the most proximal margin of the PCL’s tibial insertion site, and posteromedial to the lateral tibial eminence (9). Notably, a subset of the LPRA’s posterior fibers continue past the main root attachment and insert on the posterior segment of the lateral aspect of the medial tibial eminence (9). The LPRA occupies an area of 39.2 mm<sup>2</sup>, not including the contribution of the shiny white (supplementary) fibers (9), which comprise 30.7% of the area of the LPRA footprint and 17.6% of its native strength (1). The



**Figure 4.** Photographs depicting the tibial plateau of a human cadaveric dissection from a superior view (A) and posterior view (B). The MPRA and LPRA are shown intact in (A) and severed in (B). The native locations of the MPRA and LPRA are approximated with the blue outlining in (B). Reproduced with permission from *AJSM Vol. 40 Issue 10, 2342-2347*.

footprint of the densest fibers of the LPRA indicates the use of a 7mm reattachment diameter for repairing a root avulsion of the lateral posterior meniscal root (9).

### Medial Meniscus Anterior Root Attachment (MARA)

The medial meniscus anterior root attachment (MARA) is 27.5 mm anterior to the medial tibial eminence apex (1). The center of the MARA is 18.2 mm anteromedial to the center of the ACL, 9.2 mm anteromedial to the nearest margin of the ACL, and 4 mm posterior from the anterior-most margin of the medial tibial plateau (1, 21). The footprint of the MARA has an area of 110.4 mm<sup>2</sup> (21). The anatomic location of the MARA along the anterior margin of the medial tibial plateau has been noted to place it at risk for iatrogenic damage during intramedullary tibial nailing procedures (1, 27).

### Lateral Meniscus Anterior Root Attachment (LARA)

The center point of the lateral meniscus anterior root attachment (LARA) is 5 mm to 7.5 mm anterolateral from the center point of the tibial ACL insertion and 13.4 mm anterior from the anterior-most margin of the lateral posterior root attachment (1, 21). The footprint of the LARA has an area of 140.7 mm<sup>2</sup> (21). The LARA has a notably intimate anatomical relationship to the ACL, as their insertional fibers interdigitate and overlap upon inserting into the tibial cortex [Figure 5] (1, 21). Their insertional overlap comprises 63.2% of the LARA and 40.7% of the ACL tibial insertion (21). It is for this reason that LaPrade et al. suggested that a minor iatrogenic injury of the LARA during reconstruction of the ACL may not be avoidable, while also noting that the significance of a tear occurring at the LARA is not currently well understood (1).

### Biomechanics

Several foundational studies have analyzed the ultrastructural characteristics of the menisci, from which a few key interpretations for the biomechanical function of the menisci have been derived (30, 31). Vectorial analysis of axial loads across the knee demonstrate that force transmitted across the meniscotibial articulation is always less than the force transmitted across the meniscofemoral articulation (30). This difference in force



transmission across the two interfaces is accounted for by the conversion of axial compressive loads into radial tangential stresses called hoop stresses (30-32). These hoop stresses exert tensile stress on the circumferentially oriented collagen fibrils in the menisci (30, 32). As a result, the menisci experience circular traction due to the fixation to the tibial plateau via the meniscal roots (30). This conversion of axial compressive loads into tensile hoop stresses sustained by collagen fibrils of the menisci reduces the compressive loads experienced by the chondral cartilage of the knee (30, 31). Thus, the menisci act, as they are often described in the literature, as shock absorbers (17, 30). By anchoring the menisci to the tibial plateau, the meniscal roots ensure the proper functioning of the menisci by normalizing load distribution across the knee joint and converting axial compressive loads into tensile hoop stresses (30).

When a meniscal root attachment is compromised in the event of a meniscal root tear, axial compressive forces are no longer distributed intrinsically as tensile hoop stresses within the meniscus, as this requires anchoring of the horns to the tibial plateau by their roots so that the meniscus can experience circular traction (8). Instead, the

axial compressive forces cause extrusion of the meniscus out of the joint space (6, 8-10, 12, 16, 27, 33, 34). Meniscal extrusion pathologically alters the kinematic loading profile of the knee joint and renders the chondroprotective force-converting and load-distributing functions of the meniscus essentially nonexistent (6, 8-10, 12, 16, 27, 33, 34). Pathological changes in the loading profile of the knee after meniscal root tears have mainly been described by observing changes in contact surface area and contact pressure across the knee joint. Meniscal root tears cause a decrease in contact area over which axial tibiofemoral compressive loads can be distributed (1, 2, 6, 8, 10, 12-15). There is also a corresponding increase in mean and peak tibiofemoral contact pressures (1, 2, 6, 8, 10, 12-15, 17, 33, 35-37). Increases in tibiofemoral contact pressures are likely to be further exacerbated if a meniscal root tear is concomitant with a meniscofemoral ligament tear (36, 38). These characteristic pathologic changes in the loading profile of the knee have been referred to together as "point loading," and have been shown to cause articular cartilage damage (14, 17).

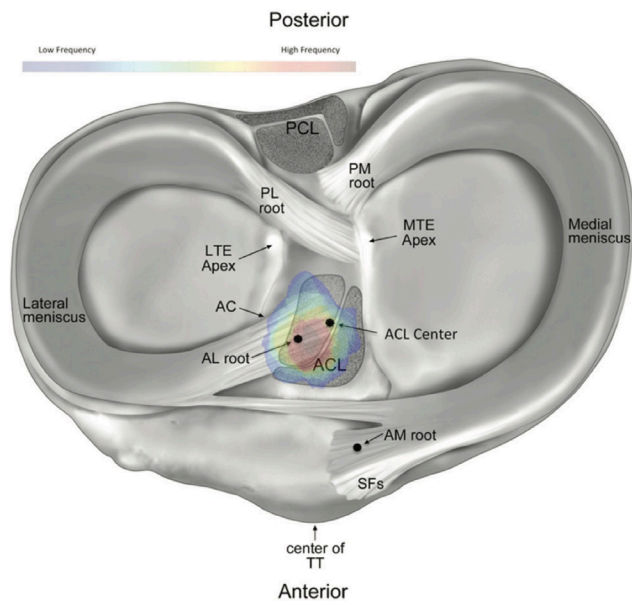
Biomechanical analyses have revealed that the biomechanical profile of the meniscal-root deficient knee is equivalent to a knee that has received a total meniscectomy (13, 17-19). Furthermore, biomechanical models of meniscal root repair have demonstrated that techniques that return the meniscus to its native anatomical orientation restore several key metrics of the loading profile, namely tibiofemoral contact area and pressures, to values indistinguishable from the root-intact state (1, 6, 9, 24). Many of these same studies also emphasize the importance of ensuring that reattachment of the avulsed meniscal root is performed anatomically (1, 6, 9, 24). This is because nonanatomic repairs have been shown to be biomechanically equivalent to the root-avulsed state, and therefore, would likely lead to worse long-term outcomes (6, 24, 36, 37, 39).

Along with their chondroprotective roles in establishing the kinematic and loading profiles of the knee, the menisci also play important roles as secondary stabilizers of the knee. This function is heavily reliant upon their root attachments. Biomechanical analyses have suggested that the menisci stabilize the knee to rotational forces in the axial and sagittal planes (35). The posterior roots, especially the LPRA, have been noted for their role in secondary stabilization of the knee to anterior tibial translation (ATT) (24, 40-42). This is evidenced by the higher rates of graft failure observed in patients undergoing ACL reconstruction who also have a concomitant tear of their LPRA that goes unrepaired (24, 35, 43, 44).

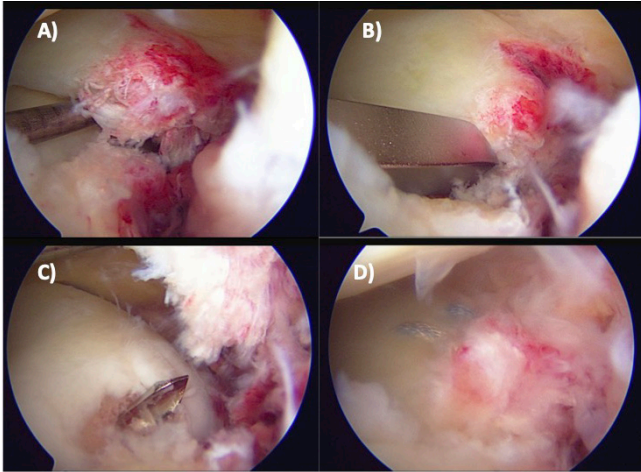
## Presentation & Diagnosis Clinical Evaluation

Tears of the MPRA are the most common meniscal root tears see clinically (13, 45).

While meniscal root tears can have both acute and chronic presentations, they have been classically described as following one of two general presentations based on the age of the patient (33). Meniscal root tears in younger patients tend to be acute and result from a traumatic



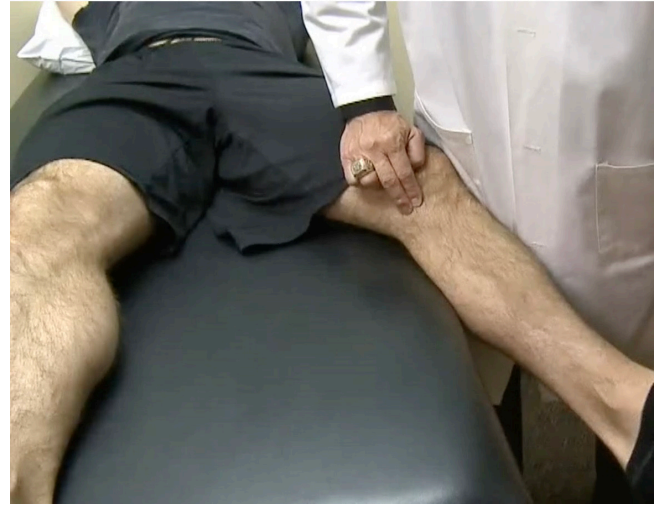**Figure 5.** Illustration created by LaPrade et al. depicting the tibial plateau structures and emphasizing the overlap of the LARA and the tibial insertion of the ACL. The authors created a "danger zone" for repair of the ACL using the quantitative anatomical overlap between the tibial insertions for the two structures, with colors approaching the color red along the provided spectrum indicating a higher frequency of insertion in the cadaveric specimens examined by the authors. SFs, shiny white fibers of the MARA; AM root, MARA center; ACL center, center of the tibial insertion of the ACL; AL root, LARA center; AC, articular cartilage; LTE Apex, apex of the lateral tibial eminence; PL, LPRA center; PM, MPRA center; TT, tibial tubercle. Reproduced with permission from *AJSM* Vol. 42 Issue 10, pp. 2386-2392.



**Figure 6.** Series of photographs depicting a torn meniscal root belonging to a young, healthy patient on arthroscopy, as well its subsequent repair. (A) a probe is used to place superiorly directed tension on the root attachment site. Because the root is completely torn, the torn root is elevated off of the tibial plateau. (B) a guide is placed over the native root attachment site of the tibial plateau in order to guide drilling. (C) a guide pin is drilled through the native root attachment site on the tibial plateau. (D) the meniscal root is secured to its native attachment site by two sutures situated anteroposterior to each other.

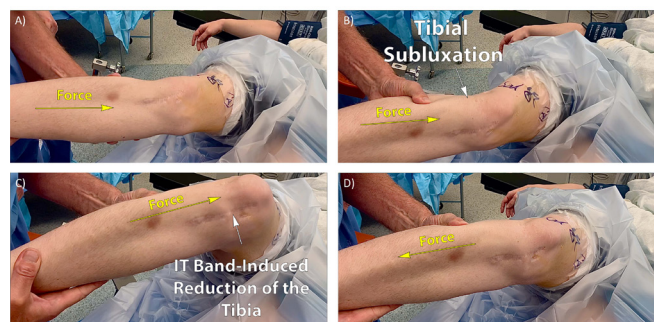
event, such as during a sporting event [Figure 6] (9, 12, 33). A rotatory blow to the flexed knee is thought to be a common underlying biomechanical mechanism for these types of tears, and concomitant multiligament tears are also common (33). Meniscal root tears in older patients tend to present chronically, often following degeneration and occurring via lower-energy mechanisms (e.g. squatting to pick up an object, kneeling down on a floor, etc.) (24, 46). A high degree of knee flexion, especially under increased tibiofemoral loads, is thought to be a common underlying biomechanical mechanism for these types of meniscal root tears, and they are usually seen in isolation (46). The causes of meniscal root tears can also be analyzed in the context of medial versus lateral tears. While tears of the MPRA generally occur in isolation, tears of the LPRA are often concomitant with ACL tears (24, 47). Several iatrogenic etiologies for meniscal root tears have also been described, usually in the context of performing repairs to other ligaments in the knee (1, 10, 24, 25, 27). While these associated etiologies highlight the importance of obtaining a thorough patient history to confirm the diagnosis of a meniscal root tear, it should be noted that an inciting event and mechanical symptoms are not reliably associated with meniscal root tears, making the clinical history and physical exam unreliable tools in diagnosing these tears (1, 12, 15, 38).

On physical exam, important maneuvers include examination for pain on deep flexion, an extruded meniscus on palpation, and a positive McMurray's sign, as some combination of these findings are present in 50-60% of meniscal root tears [Figure 7] (1, 38). Studies have shown that 60% of patients presenting meniscal



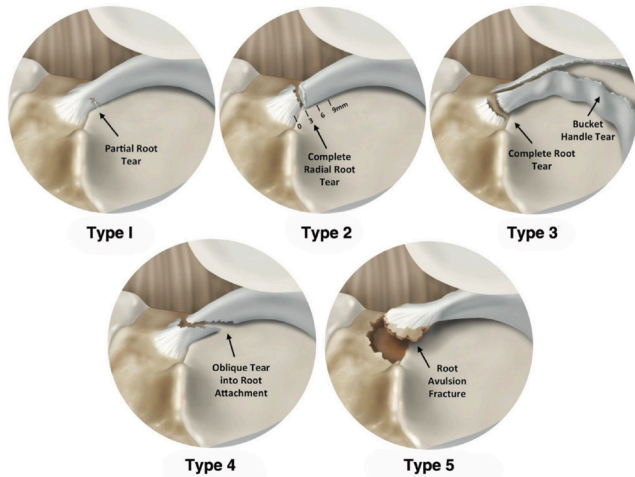
**Figure 7.** Photograph demonstrating palpation of the medial joint line of the knee in order to check for the presence of palpable meniscal extrusion.

root tears also present with concomitant ACL tears, with tears of the lateral meniscal roots being 10 times more likely than medial meniscal roots to be concomitant with ACL tears (38). Furthermore, DePhillipo et al. found that tears of the LPRA had an incidence rate of 12.2% in the case of primary ACL reconstructions and 20.5% in the case of revision ACL reconstructions (42). Tears of the LPRA allow for increased ATT seen on the Lachman's test and increased internal rotation seen on the pivot shift test [Figure 8] (24, 40). Patients who are in varus alignment are at an increased risk of experiencing tears of their medial meniscal root as opposed to their lateral



**Figure 8.** Photographs taken in succession, demonstrating the pivot shift maneuver performed under general anesthesia in the context of a patient with ACL deficiency and concomitant meniscal root pathology. Here, the patient presents with a 3+ "explosive" finding on the pivot shift test. (A) depicts the clinician applying a superomedial force on the leg. (B) demonstrates subluxation of the proximal tibia against the distal femur. (C) is taken immediately following the "explosion" as the tibia is reduced out of its originally subluxated state by the IT band. (D) depicts a reversal of the direction of the force applied by the clinician and is taken immediately following the point where the tibia has returned to its subluxated position.





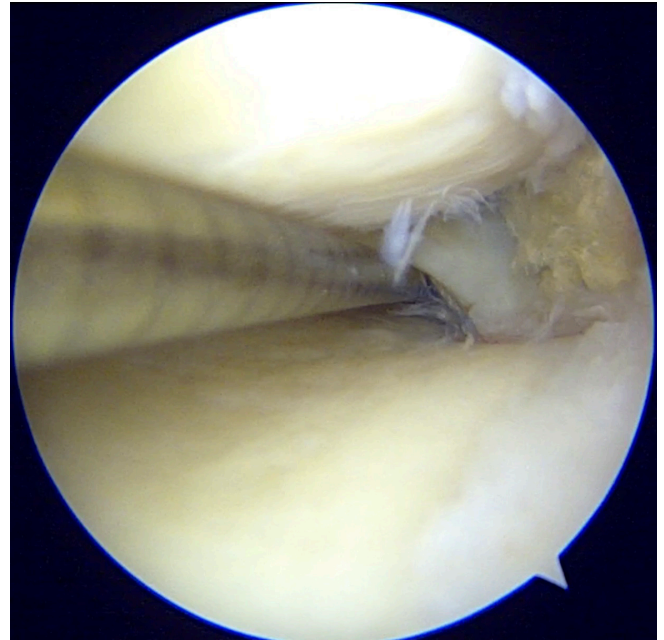
**Figure 9.** Illustration depicting the five types of meniscal root tears as classified by LaPrade et al. All of the tears are depicted as occurring at the MPRA. Reproduced with permission from AJSM Vol. 43 Issue 2, pp. 363-369.

meniscal roots (33). Mechanical symptoms, such as joint line pain, clicking, catching, and instability, have been reported to occur with tears of the meniscal roots (15, 24, 46, 47).

### Classification

Few systems for classifying meniscal root tears have been described in the literature, and these have mainly focused on categorizing tears of the posterior meniscal roots. West et al. describes a classification system for meniscal root tears isolated to the posterior root of the lateral meniscus (48). This review will mainly focus on the classification system developed by LaPrade et al., which classified tears of the posterior meniscal roots into five categories based on tear morphology visualized on arthroscopy [Figure 9] (7).

LaPrade et al. developed the following classification system for meniscal root tears: Type 1 tears are partial, stable tears of the root (occurring within 1 cm of the root attachment site) with no additional concurrent tears of the corresponding meniscal body (7). The frequency of Type 1 tears was noted to be 7% (7). Type 2 tears are the most commonly occurring class of meniscal root tear and were broadly characterized by LaPrade et al. as complete radial tears of the posterior meniscal root occurring within, at most, 9mm from the center of the root attachment site (7, 46). LaPrade et al. further grouped Type 2 tears into three subcategories based on the distance at which they occurred from the center of the meniscal root attachment, with Type 2A tears occurring from 0 to < 3mm from the center of the root attachment, Type 2B tears occurring from 3 to < 6 mm from the center of the root attachment, and Type 2C tears occurring from 6 to 9 mm from the center of the root attachment (7). LaPrade et al. found that Type 2A root tears accounted for 38.0% of all root tears, Type 2B root tears accounted for 16.9% of all root tears, and Type 2C root tears accounted



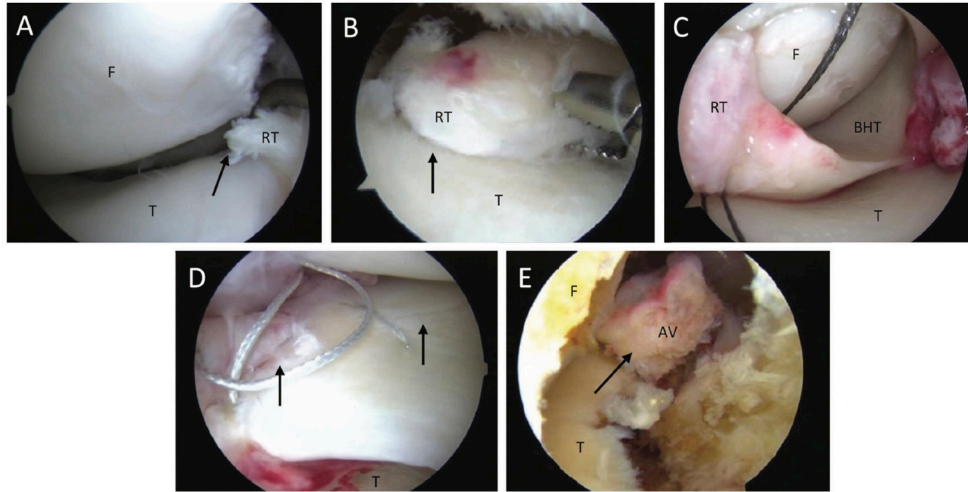
**Figure 10.** Photograph depicting the probing of a posterior meniscal root on arthroscopy. The meniscal root depicted here was previously repaired, and this photograph demonstrates that it is intact.

for 12.7% of all root tears (7).

Type 3 tears are longitudinal or circumferential tears, classically described as “bucket handle” tears, occurring with complete detachment of the meniscal root within 9 mm from the center of the root attachment site (7). The term “bucket handle” refers mainly to tears where there is separation of the superior fibers of the meniscus from the inferior fibers of the meniscus along the circumferential axis of the meniscus. The frequency of Type 3 tears was noted to be 5.6% (7). Type 4 tears are complex oblique tears occurring within 9 mm from the root attachment site that occur with complete detachment of the meniscal root (7). The frequency of Type 4 tears was noted to be 9.9% (7). Type 5 tears are bony avulsion fractures where the root attachment is completely avulsed from the tibial plateau (7). The frequency of Type 5 tears was noted to be 9.9% (7).

### Imaging

Meniscal root tears are often difficult to identify with preoperative imaging studies (24). The gold standard for diagnosing meniscal root tears was originally, and continues to be, confirmation of a tear by probing the root attachments on arthroscopy [Figure 10] (15). LaPrade et al. demonstrated that even with high field (3.0 T) MRI, diagnosing meniscal root tears (especially tears of the LPRA) is difficult and has been shown to have a low positive predictive value. (49) Because of their ease of diagnosis on arthroscopy and their difficulty of diagnosis on MRI, it is the current standard of practice is to probe the root attachments of the menisci on every arthroscopy [Figure 11] (1, 49). Despite this, it is possible to directly



**Figure 11.** Photographs depicting the five types of meniscal root tears visualized arthroscopically. (A) depicts a type 1 meniscal root tear. (B) depicts a type 2 meniscal root tear. (C) depicts a type 3 meniscal root tear. (D) depicts a type 4 meniscal root tear. (E) depicts a type 5 meniscal root tear. Arrows mark the location of the tear depicted in each photograph. F, femur; T, tibia; RT, root tear; BHT, bucket-handle tear; AV, avulsion. Reproduced with permission from *AJSM* Vol. 43 Issue 2, pp. 363-369.

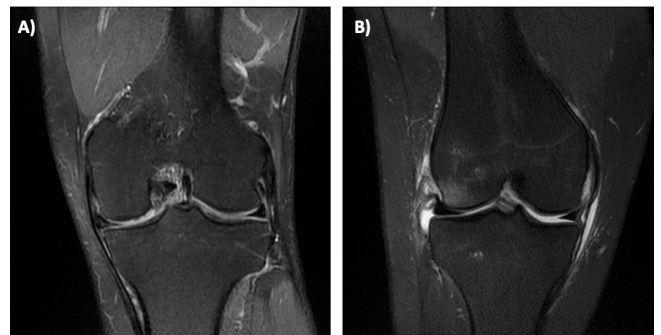visualize meniscal root tears on MRI (50). Type 5 tears have also been referred to as “meniscal ossicles,” and they can be identified directly on standard anteroposterior and lateral radiographs (12, 15). Increased awareness of the importance of meniscal root tears has increased their rate of radiographic diagnosis (10). Furthermore, advanced methods for analyzing MRI studies, and the emergence of diagnostic findings, have increased sensitivity, specificity, and positive and negative predictive values to greater than 0% (33, 51).

In this review, we highlight three important findings on MRI, beyond fluid accumulation and obvious disruption of the root attachment sites, that have been shown to be good secondary indications of meniscal root pathology (1, 12, 14, 15, 27, 33). These findings are 1) meniscal extrusion, 2) SONK/SIFK and 3) the “ghost sign” (1, 12, 14, 15, 27, 33, 50). These findings on MRI have been reported to have a high reproducibility and to have good values of sensitivity and specificity in the diagnosis of meniscal root tears, especially tears of the posterior roots (1).

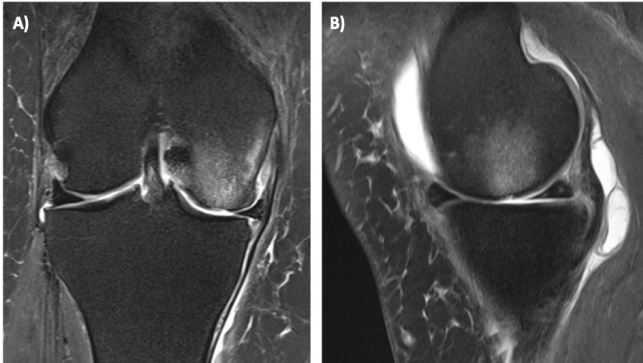
Even in the case where a meniscal root tear is missed on the initial diagnosis or MRI sequence, a finding of > 3 mm of meniscal extrusion should direct the one’s attention to a possible meniscal root tear [Figure 12] (12, 15, 33). This finding on MRI has been correlated with meniscal extrusion found on arthroscopy (52). The extent of meniscal extrusion is measured on a coronal image and is to be measured from the outer margin of the extruded meniscus to the outer margin of the articular cartilage of the ipsilateral tibial plateau (1, 15, 33). DePhillipo et al. describes a slightly different method of measuring extrusion of the medial meniscus using the superficial medial collateral ligament as a landmark (53). Tears of both the anterior and posterior roots can present with meniscal root tears on MRI (12,

15, 27, 33).

There has been recent debate over the etiology behind SONK/SIFK in the context of meniscal pathology [Figure 13]. However, there is now general consensus that the SONK/SIFK lesions, once believed to be idiopathic, are associated with meniscal root tears (1, 14). Hussain et al. described an etiology for SONK/SIFK based on the kinematic alterations of the knee associated with meniscal root tears (14). They proposed that the resultant increase in tibiofemoral contact pressures, combined with alterations in load transmission, results in point loading that causes subchondral insufficiency fractures, making the name SONK a misnomer that ought



**Figure 12.** Coronal MRI radiographs depicting extrusion of the (A) medial, and (B) lateral, meniscus following a meniscal root tear. (A) depicts an MRI radiograph of a left knee with visible medial extrusion of the medial meniscus. (B) depicts an MRI radiograph of a right knee with visible lateral extrusion of the lateral meniscus. The extrusion depicted in both (A) and (B) exceeds the threshold of 3 mm between the outer margin of the tibial plateau articular cartilage and the outer extent of the meniscus.



**Figure 13.** (A) coronal and (B) sagittal MRI radiographs depicting spontaneous osteonecrosis of the knee (SONK)/Subchondral insufficiency fracture (SIFK) of the medial femoral condyle following medial meniscal root tear. Significant medial meniscal extrusion is also present in (A).

to be replaced with the term “subchondral insufficiency fractures of the knee” (SIFK) (14).

Finally, the “ghost sign” is defined as the absence of an identifiable meniscus on sagittal MRI, and it has also been shown to have high reproducibility in the context of meniscal root tears [Figure 14] (1, 38). It should be noted that there is discrepancy in the reported values for sensitivity, specificity, positive predictive value, and negative predictive value in the literature. LaPrade et al. attributes this to the variation in quality of the imaging studies as well as to variation in the musculoskeletal experience of radiologists (38).

### Treatment Rationale

Non-operative treatment, partial meniscectomy, and surgical repair are three of the most common treatment options for treating patients with meniscal root tears. Choice of treatment is largely dependent on the type and extent of meniscal tear; indications and contraindications for surgical repair; and the condition of the chondral cartilage of the knee. Specifically, as it pertains to the condition of the chondral cartilage, one of the aims of repairing meniscal root tears is delaying the onset of OA. Therefore, surgical repair is contraindicated for patients

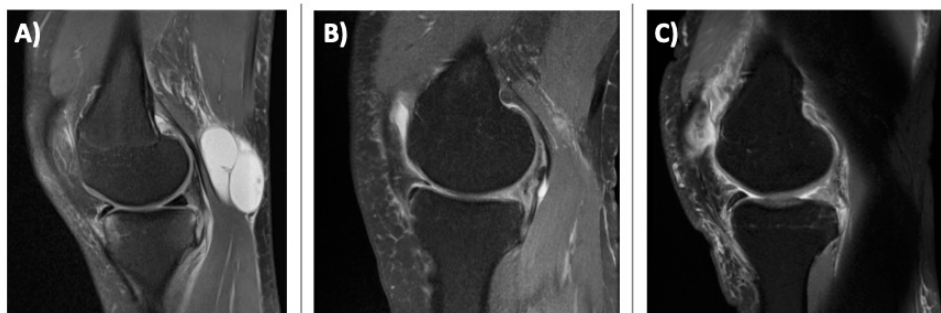
with OA Outerbridge or Kellgren-Lawrence grades 3 to 4 in the ipsilateral compartment (7, 13, 15, 37, 54).

### Nonoperative Treatment

Conservative measures used to treat meniscal root tears nonoperatively generally center around symptom management. Analgesics, NSAIDs and ice can be used to manage pain associated with the injury. Patients for whom surgical repair is contraindicated (e.g. older patients) may benefit from using an unloader brace, especially in the case of medial meniscal root tears. It must be noted that nonoperative measures do not address mechanical symptoms that may be resultant of a meniscal root tear, and most importantly, they do not delay the progression of OA that has been widely noted to follow meniscal root tear (55). Meanwhile, the procedures for repairing the torn root presented in this review have favorable patient-reported outcomes. Furthermore, numerous biomechanical studies have demonstrated the importance of intact and anatomically correct meniscal roots for the function of the meniscus and the kinematics and loading profile of the knee. Consideration of all of these factors makes conservation and repair of the menisci and their roots the priority when treating meniscal root tears. There are, however, several important contraindications to surgical repair. Most notably, patients of advanced age, presenting with OA (Outerbridge or Kellgren-Lawrence 3-4), varus alignment (greater than 3 degrees), and increased BMI are contraindicated for surgical repair. These patients may therefore gain some marginal benefit from non-operative measures (55, 56).

### Meniscectomy

Historically, treatment of meniscal tears mostly involved excising the damaged meniscus through either a partial or total meniscectomy. Although this treatment often achieved short-term relief for patients, the damaging long-term effects were eventually noted, namely, rapid and reliable progression to OA (10, 57). Total meniscectomy has been shown to lead to a 61% increase in peak tibiofemoral contact pressure and a 48% decrease in tibiofemoral contact surface area (15). Outcomes for partial meniscectomy are reportedly equivalent to nonoperative treatment measures in the treatment of medial meniscus tears (58). Increased



**Figure 14.** Sagittal MRI radiographs depicting (A) a normal cross-sectional view of the meniscus versus visible ghost sign of the meniscus in the same sequence (B), and in a different sequence (C).



appreciation for the role of the menisci in modulating these metrics has shifted the standard of care to favor anatomic surgical repair of meniscal root tears. Nevertheless, some patients may still benefit, at least in the short term, from partial or total meniscectomy. Patients with severe pain, locking, and other mechanical changes, and patients who have severe chondromalacia and arthritis (Outerbridge 3-4) might experience short-term benefits from meniscectomy (2).

### Meniscal Root Repair

The two most common technique for surgical repair of a meniscal root tear is the transtibial pull-out repair. At 3.5 years' follow-up, Cinque et al. found that two-tunnel transtibial repairs of radial meniscal tears produced outcomes that were quite comparable to inside-out repair (4). Younger patients, especially those who are more active and those who have not yet developed ipsilateral compartment chondromalacia of Outerbridge 3-4 tend to be indicated for surgical repair (12). As discussed above, biomechanical studies have elucidated the critical importance of restoring the meniscal root to its correct anatomic attachment site, as non-anatomic repairs have been shown to be biomechanically equivalent to the state of meniscectomy (45).

Despite the kinematic measures that are restored following anatomic repair of a meniscal root tear, it has been noted that meniscal extrusion often persists even after a repair is performed [Figure 15] (34, 59-61). Although meniscal extrusion is recognized as one of the elements associated with increased joint degeneration, the significance of this observation remains unclear (18, 34).

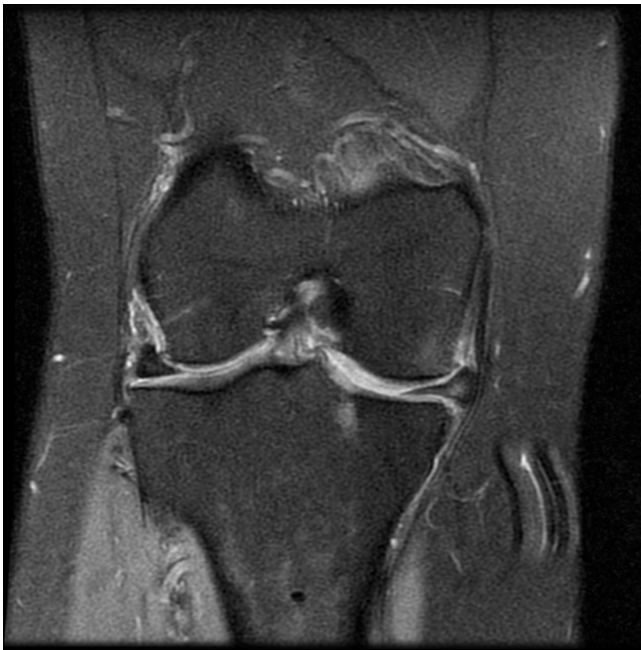

Figure 15. Coronal MRI radiograph following the surgical repair of a meniscal root tear demonstrating persistent meniscal extrusion. The extrusion depicted here is observably significant, measuring greater than 3 mm. This repair underwent subsequent revision.

Studies have analyzed the use of a peripheral centralization suture to minimize extrusion of the meniscus after repair of a meniscal root tear (8, 62). In a cadaveric model, Daney et al. found that the use of a centralization suture may benefit patients by minimizing meniscal extrusion (62). However, further efforts should be made to determine the significance of persistent meniscal extrusion following repair and whether peripheral stabilization of the meniscus improves outcomes for patients undergoing meniscal root repair (8).

### Transtibial Pull-Out Repair

Several studies have detailed the procedures for performing a transtibial pull-out repair of meniscal root tears [Figure 16] (1, 2, 13, 16, 37, 46). This technique involves drilling one or two tunnels from the proximal anterior aspect of the tibia superiorly through the anatomic root attachment site of the torn meniscal root. Sutures are then passed through the torn meniscal root and retrieved through the transosseous tibial tunnel(s). A cortical button is usually then placed over the distal opening of the tunnel(s) in order to minimize suture cut-out through the cortical bone of the tibia. The sutures are pulled tight to draw the meniscus into its anatomically correct position and subsequently tied down over the cortical button.

Nakama et al. performed a biomechanical evaluation of suture techniques in transtibial meniscal tears and found that both suture configurations tested (single-row and double-row) and both suture techniques tested (vertical mattress and cross-stitch) restored tibiofemoral kinematics to within acceptable limits (63). Hapa et al. compared different types of suture material in the use of a horizontal mattress suture to repair a biomechanical porcine model of a meniscus tear (57). They found ultra high-molecular weight polyethylene (UHMWPE) suture materials to be preferable to polyester in terms of fixation

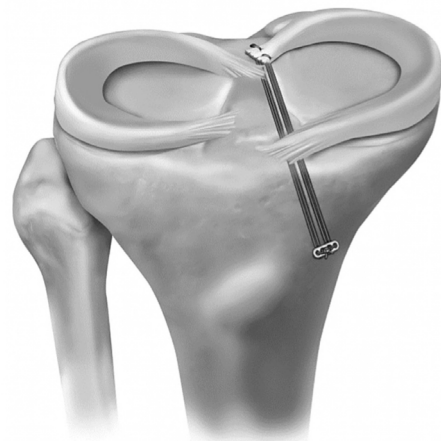
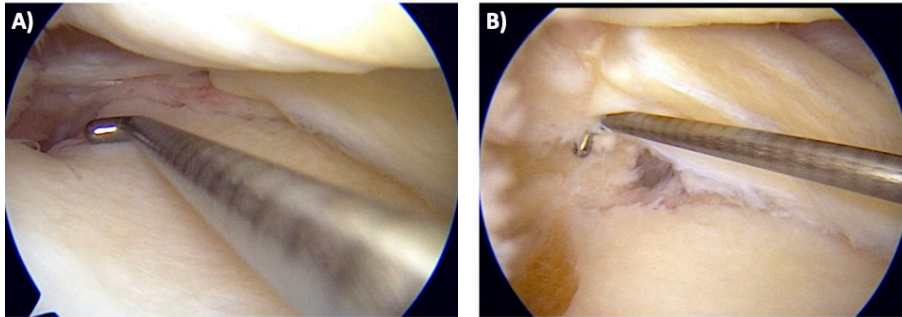


Figure 16. Illustration depicting the repair of a tear to the MPRA using a transtibial pull-out technique. The specific technique depicted above uses two transosseous tunnels and two sutures tied over a cortical button. The sutures are passed through the meniscal root anteroposterior to each other. Reproduced with permission from AJSM Vol. 45 Issue 4, 884-891.



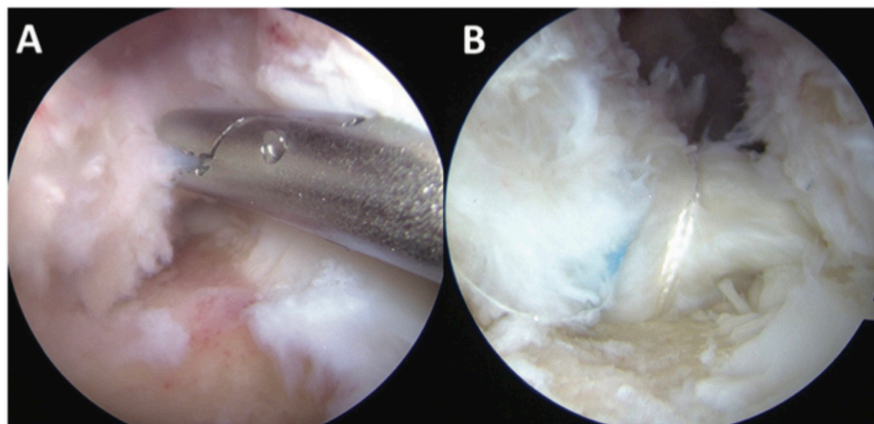
**Figure 17.** Photographs taken on arthroscopy during a transtibial repair of a meniscal root tear. (A) photograph taken before peripheral release of the meniscus has been performed. Peripheral adhesion of the meniscus to the joint capsule has caused apparent subluxation of the meniscus, complicating anatomic reduction of the meniscal root to its native attachment site for repair. (B) photograph taken subsequent to peripheral release of the meniscus from the capsule. Now free of adhesion to the capsule, the meniscus is available to occupy a visibly greater area greater of the joint space and assume a more native orientation, making successful anatomic reduction and fixation of the meniscal root possible.

strength (57). Finally, multiple authors advocate for peripheral release of the meniscus from the joint capsule [Figure 17] (24). They note that meniscal extrusion secondary to a meniscal root tear can lead to scarring of the meniscus to the joint capsule, complicating efforts to reduce the meniscus to its original anatomical position in the joint space before repairing the torn meniscal root (46, 64).

#### **Senior Author's Preferred Technique: Two-Tunnel Transtibial Pull-Out**

The senior author's preferred technique is a pull-out repair using two transosseous tibial tunnels and two simple sutures secured over a cortical button. Standard arthroscopic portals are made anterolaterally and anteromedially next to the patellar tendon, and accessory arthroscopic portals are incised as needed. The torn meniscal root is located and confirmed with

a probe. The corresponding meniscal root attachment site on the tibial plateau is located and decorticated with a curette. A guide apparatus is then used to determine the correct tunnel orientation and to guide drilling such that the proximal orifice of the transtibial tunnel will open into the decorticated root attachment site of the torn root. A drill pin with a cannulated sleeve is drilled through the posterior portion of the root attachment site, followed by a second drill pin with a cannulated sleeve, which is driven approximately 5 mm anterior to the first. Once confirmed to be in the correct positions, the drill pins are removed, and the sutures are passed through the torn root and then retrieved. Each suture is retrieved through its respective tunnel and both are then tensioned and subsequently tied over cortical button on the proximal anterior aspect of the tibia [Figure 18].



**Figure 18:** Images taken on arthroscopy depicting a complete tear of the LPR (A) and subsequent anatomic reapproximation and fixation using two sutures, which have been pulled through transtibial tunnels and secured over the proximal tibial cortex using a cortical button. Reproduced with permission from AJSM Vol. 45 Issue 4, 884-891.

### Outcomes After Meniscal Root Repairs

While it has been established that both the suture anchor technique and the transtibial pull-out technique return joint biomechanics to a state indistinguishable from that of the intact meniscus, there is not a definitive consensus on whether repair of the meniscal roots halts the progression of OA (65). This is mostly due to the lack of studies reporting on long-term patient follow-ups, which would allow for the effects of any osteoarthritic processes to be observed in full and for a definite determination to be made. A literature review performed by Faucett et al. compared the outcomes for surgical repair of meniscal root tears to meniscectomy and non-operative treatment (66). They found that surgical repair leads to significantly less OA at a mean follow-up of 39.9 months compared to meniscectomy and non-operative treatment (66). Studies reviewing the outcomes for transtibial meniscal root repairs estimate that anywhere from 79.7% to 84% of patients experience no further progression of OA following transtibial repair (67-69).

Transtibial repairs of meniscal root tears have a reportedly low failure rate, with an observed revision rate of 6.7% (17, 37). Krych et al. found that patients undergoing repairs of both medial and lateral root repairs experienced good outcomes (evidenced by increased Tegner scores and International Knee Documentation Committee scores at a mean follow-up of 41 months), with those undergoing lateral meniscal root repairs possibly benefiting slightly more from repair than those undergoing medial meniscal root repairs (47). LaPrade et al. reported that patients seen at a mean follow-up of 2.5 years demonstrated significant postoperative improvement, especially with regard to patient-reported measures, Lysholm, Tegner activity scale, and the Western Ontario and McMaster Universities Osteoarthritis index (WOMAC score) (37). Furthermore, they found no significant differences in patient outcomes and patient satisfaction between patients older than 50 years and patients younger than 50 years or between patients receiving repairs for medial versus lateral meniscal root repairs (37).

### Postoperative Rehabilitation

To the authors' knowledge, there have been no long-term studies comparing the efficacy of varying rehabilitation protocols for patients recovering from meniscal root repairs, especially regarding the time course for introducing weight-bearing, increasing range of motion (ROM), and beginning strength training. Biomechanical models of cyclic loading have largely underscored the need for gradual and cautious rehabilitation protocols (29, 48, 70). Woodmass et al. emphasized the need for uniform rehabilitation guidelines to protect repairs of all types of meniscal tears, as the ability of a repair to withstand tibiofemoral loading can be somewhat dependent on the directionality of the tear (71). An in-vitro human model of medial meniscal root repair performed by Starke et al. found that internal rotation of the femur on the tibia, high flexion angles, and increased tibiofemoral loads all significantly increase tensile strain on a repaired root (72). Several recent studies have analyzed the importance of correcting varus malalignment using open-wedge high

tibial osteotomy (OWHTO) in the context of meniscal root pathology and repair (73-76). These studies have shown that patients tend not to benefit from the OWHTO procedure and may experience worse outcomes compared to patients who undergo meniscal root repair alone (73, 74). The senior author's preferred method for rehabilitation following meniscal root repair in the context of varus malalignment is utilizing an unloader brace to reduce tibiofemoral loads in the affected compartment, thereby reducing tensile strain on the newly repaired root.

Mueller et al. describes a five-phase rehabilitation protocol that adheres to a linear periodization approach, with the objective of progressively loading the repair over time (12). Along with pre-defined time periods, they also outline a list of criteria that must be met before the patient may advance from one phase to the next (12). While symmetrical ROM exercises and muscle activation are prioritized early in the first phase, it is critical that patients remain non-weightbearing for the first 6 weeks (12). Lee et al. introduced weightbearing at postoperative week four and used second look arthroscopy (at a mean of 16.4 months) to confirm a reinjury rate of 30.3% (73). Meanwhile, using the protocol outlined by Mueller et al. wherein weightbearing is not introduced until postoperative week six, LaPrade et al. found a reinjury rate of only 6.7% (12, 37).

Flexion ROM should be limited from 0 to 90 degrees and must only be performed passively within the first 6 weeks due to the involvement of the menisci in the anatomical insertion of the hamstrings and popliteus (12, 77). Weight-bearing can be gradually introduced starting postoperative weeks 6-7 (12, 37). Patients must also avoid deep squatting or loaded knee flexion for the first 3-4 months, as these movements have been shown to subject the meniscal roots to increased biomechanical strain (12). Furthermore, findings by Starke et al. indicated that internal rotation of the femur against the tibial plateau creates increased tensile stress on the meniscal roots, and should be avoided during rehabilitation, especially in the case of repairs of the posterior meniscal roots (72).

Foundational studies describing the anatomy and biomechanics of the meniscal roots and their associated pathologies have led to the development of improved treatment measures for meniscal root tears [Table 1]. However, there remains a need for long-term randomized controlled studies examining the efficacy of surgical repair methods. These studies, along with an increasing body of knowledge of the importance of the menisci will lead to better outcomes for patients who experience meniscal root tears.

Mark T. Banovetz BS<sup>1,2</sup>

Lindsay C. Roethke BS<sup>1,2</sup>

Ariel N. Rodriguez MS<sup>1,3</sup>

Robert F LaPrade MD PhD<sup>1</sup>

1 Twin Cities Orthopedics, Edina-Crosstown, Edina, MN, USA

2 University of Minnesota Medical School, Minneapolis, MN, USA

3 Georgetown University School of Medicine, Washington, DC, USA



**Table 1. A Decade of Research on Meniscal Root Tears. Organized chronologically, a list of prominent findings pertaining to meniscal root tears and their associated articles is provided**

Year	Author	Finding
2008	Allaire et al.	Biomechanical analysis demonstrates that a posterior meniscal root tear is biomechanically equivalent to a total meniscectomy.
2009	Marzo et al.	A cadaveric study demonstrates that meniscal root repair restores the function of the meniscus in absorbing hoop stresses.
2010	Starke et al.	Nonanatomic repair of a meniscal root is shown to increase tension on the repaired meniscus.
2011	Kim et al.	Both the transtibial pull-out technique and the suture anchor technique are shown to yield significant functional improvement in a head-to-head evaluation.
2012	Johannsen et al.	Quantitative anatomic description of the posterior meniscal root attachment sites is first described.
2013	Starke et al.	A biomechanical model analyzes and defines the tensile forces experienced by the meniscal roots, guiding future rehabilitation protocols for patients undergoing meniscal root repair.
	LaPrade et al.	Iatrogenic injury to the LPRA due to nonanatomic double-bundle ACL reconstruction is first described.
	LaPrade et al.	Quantitative anatomic description of the anterior meniscal root attachment sites is first described.
2014	LaPrade et al.	A system for classifying meniscal root tear morphology is described based on tear directionality and distance from the center of the root.
	LaPrade et al.	A cadaveric biomechanical model demonstrates that an in situ pull-out repair of the meniscal root restores knee kinematics following a simulated posterior meniscal root tear.
	LaPrade et al.	Nonanatomic root repair is shown to be biomechanically equivalent to the root-torn state.
2015	LaPrade et al.	One- and two-tunnel transtibial repairs of meniscal root tears are shown to be biomechanically equivalent in a cyclic-loading model.
	LaPrade et al.	A low positive predictive value is noted for diagnosing tears of the posterior meniscal roots on high field MRI.
	LaPrade et al.	Patients undergoing transtibial pull-out repair of meniscal root tears are shown to experience significant postoperative improvement and satisfaction.
2016	Mueller et al.	A post-operative rehabilitation protocol is published for patients undergoing meniscal root repair that calls for a 6-week non-weightbearing period.
2017	Hussain et al.	A review of the role of meniscal tears in the finding of SONK on MRI is performed, and a call for replacing SONK with SIFK is made.
2018	Kaplan et al.	Persistent post-operative meniscal extrusion is noted on MRI and described in the literature following repair of meniscal root tears.
	DePhillipo et al.	A technique for addressing meniscal extrusion and ensuring anatomic root repair by releasing the meniscus from the capsule peripherally is described.
2019	Daney et al.	A cadaveric model demonstrates that the use of a peripheral centralization suture may be beneficial for minimizing meniscal extrusion post-root repair.
2020	Dean et al.	A surgical technique for addressing meniscal extrusion in revision meniscal root repair with a peripheral stabilization stitch is first described.

## References

1. LaPrade RF, Floyd ER, Carlson GB, Moatshe G, Chahla J, Monson JK. Meniscal root tears: Solving the silent epidemic. *Journal of Arthroscopic Surgery and Sports Medicine*. 2021;2(1):47-57.
2. LaPrade CM, Jansson KS, Dornan G, Smith SD, Wijdicks CA, LaPrade RF. Altered tibiofemoral contact mechanics due to lateral meniscus posterior horn root avulsions and radial tears can be restored with in situ pull-out suture repairs. *J Bone Joint Surg Am*. 2014;96(6):471-9.
3. Steineman BD, LaPrade RF, Santangelo KS, Warner BT, Goodrich LR, Haut Donahue TL. Early Osteoarthritis After Untreated Anterior Meniscal Root Tears: An In Vivo Animal Study. *Orthop J Sports Med*. 2017;5(4):2325967117702452.
4. Cinque ME, DePhillipo NN, Moatshe G, Chahla J, Kennedy MI, Dornan GJ, et al. Clinical Outcomes of Inside-Out Meniscal Repair According to Anatomic

- Zone of the Meniscal Tear. *Orthop J Sports Med.* 2019;7(7):2325967119860806.
5. Matheny LM, Ockuly AC, Steadman JR, LaPrade RF. Posterior meniscus root tears: associated pathologies to assist as diagnostic tools. *Knee Surg Sports Traumatol Arthrosc.* 2015;23(10):3127-31.
  6. LaPrade CM, Foad A, Smith SD, Turnbull TL, Dornan GJ, Engebretsen L, et al. Biomechanical consequences of a nonanatomic posterior medial meniscal root repair. *Am J Sports Med.* 2015;43(4):912-20.
  7. LaPrade CM, James EW, Cram TR, Feagin JA, Engebretsen L, LaPrade RF. Meniscal root tears: a classification system based on tear morphology. *Am J Sports Med.* 2015;43(2):363-9.
  8. Dean RS, DePhillipo NN, Monson JK, LaPrade RF. Peripheral Stabilization Suture to Address Meniscal Extrusion in a Revision Meniscal Root Repair: Surgical Technique and Rehabilitation Protocol. *Arthrosc Tech.* 2020;9(8):e1211-e8.
  9. Johannsen AM, Civitarese DM, Padalecki JR, Goldsmith MT, Wijdicks CA, LaPrade RF. Qualitative and quantitative anatomic analysis of the posterior root attachments of the medial and lateral menisci. *Am J Sports Med.* 2012;40(10):2342-7.
  10. Kennedy NI, Michalski MP, Engebretsen L, LaPrade RF. Iatrogenic Meniscus Posterior Root Injury Following Reconstruction of the Posterior Cruciate Ligament: A Report of Three Cases. *JBJS Case Connect.* 2014;4(1 Suppl 6):e20-e6.
  11. Griffith CJ, LaPrade RF, Fritts HM, Morgan PM. Posterior root avulsion fracture of the medial meniscus in an adolescent female patient with surgical reattachment. *Am J Sports Med.* 2008;36(4):789-92.
  12. Mueller BT, Moulton SG, O'Brien L, LaPrade RF. Rehabilitation following meniscal root repair: A clinical commentary. *Journal of orthopaedic & sports physical therapy.* 2016;46(2):104-13.
  13. LaPrade RF, LaPrade CM, James EW. Recent advances in posterior meniscal root repair techniques. *J Am Acad Orthop Surg.* 2015;23(2):71-6.
  14. Hussain ZB, Chahla J, Mandelbaum BR, Gomoll AH, LaPrade RF. The Role of Meniscal Tears in Spontaneous Osteonecrosis of the Knee: A Systematic Review of Suspected Etiology and a Call to Revisit Nomenclature. *Am J Sports Med.* 2019;47(2):501-7.
  15. Marzo JM. Medial meniscus posterior horn avulsion. *J Am Acad Orthop Surg.* 2009;17(5):276-83.
  16. LaPrade CM, LaPrade MD, Turnbull TL, Wijdicks CA, LaPrade RF. Biomechanical evaluation of the transtibial pull-out technique for posterior medial meniscal root repairs using 1 and 2 transtibial bone tunnels. *Am J Sports Med.* 2015;43(4):899-904.
  17. Padalecki JR, Jansson KS, Smith SD, Dornan GJ, Pierce CM, Wijdicks CA, et al. Biomechanical consequences of a complete radial tear adjacent to the medial meniscus posterior root attachment site: in situ pull-out repair restores derangement of joint mechanics. *Am J Sports Med.* 2014;42(3):699-707.
  18. Lerer DB, Umans HR, Hu MX, Jones MH. The role of meniscal root pathology and radial meniscal tear in medial meniscal extrusion. *Skeletal Radiol.* 2004;33(10):569-74.
  19. Allaire R, Muriuki M, Gilbertson L, Harner CD. Biomechanical consequences of a tear of the posterior root of the medial meniscus. Similar to total meniscectomy. *J Bone Joint Surg Am.* 2008;90(9):1922-31.
  20. LaPrade RF, Padalecki JR, Jansson K, Smith S, Dornan G, Pierce C, et al. Biomechanical Consequences of a Complete Radial Tear Adjacent to the Medial Meniscus Posterior Root Attachment Site. *Orthop J Sports Med.* 2014;2(3\_suppl).
  21. LaPrade CM, Ellman MB, Rasmussen MT, James EW, Wijdicks CA, Engebretsen L, et al. Anatomy of the anterior root attachments of the medial and lateral menisci: a quantitative analysis. *Am J Sports Med.* 2014;42(10):2386-92.
  22. Ellman MB, LaPrade CM, Smith SD, Rasmussen MT, Engebretsen L, Wijdicks CA, et al. Structural Properties of the Meniscal Roots. *Am J Sports Med.* 2014;42(8):1881-7.
  23. Nelson EW, LaPrade, R.F. The Anterior Intermeniscal Ligament of the Knee: An Anatomic Study. *The American Journal of Sports Medicine.* 2000;28(1):74-6.
  24. LaPrade RF, DePhillipo NN, Larson CM. Editorial Commentary: Comparing Medial and Lateral Meniscal Root Tears Is Like Comparing Apples and Oranges. *Arthroscopy.* 2020;36(4):1142-4.
  25. Steineman BD, Moulton SG, Haut Donahue TL, Fontbote CA, LaPrade CM, Cram TR, et al. Overlap Between Anterior Cruciate Ligament and Anterolateral Meniscal Root Insertions: A Scanning Electron Microscopy Study. *Am J Sports Med.* 2017;45(2):362-8.
  26. Oshima T, Grasso S, Beach A, Fritsch B, Parker DA. Lateral location of the tibial tunnel increases lateral meniscal extrusion after anatomical single-bundle anterior cruciate ligament reconstruction. *Journal of ISAKOS.* 2019;4(6):285-9.
  27. Ellman MB, James EW, LaPrade CM, LaPrade RF. Anterior meniscus root avulsion following intramedullary nailing for a tibial shaft fracture. *Knee Surgery, Sports Traumatology, Arthroscopy.* 2015;23(4):1188-91.
  28. Mow VC, Arnoczky SP, Jackson DW. *Knee meniscus: basic and clinical foundations:* Raven Press New York; 1992.
  29. Papalia R, Vasta S, Franceschi F, D'Adamio S, Maffulli N, Denaro V. Meniscal root tears: from basic science to ultimate surgery. *Br Med Bull.* 2013;106:91-115.
  30. Aspden RM, Yarker YE, Hukins D. Collagen orientations in the meniscus of the knee joint. *Journal of anatomy.* 1985;140(Pt 3):371.
  31. Petersen W, Tillmann B. Collagenous fibril texture of the human knee joint menisci. *Anatomy and Embryology.* 1998;197(4):317-24.
  32. Fox AJ, Bedi A, Rodeo SA. The basic science of human knee menisci: structure, composition, and function. *Sports Health.* 2012;4(4):340-51.
  33. James EWJ, A.M.; Cinque, M.E.; Chahla, J.; LaPrade, R.F. An evidence-based approach to the diagnosis and treatment of meniscal root tears. *Minerva Ortop*

- Traumatol. 2017;68(2):81-90.
34. Costa CR, Morrison WB, Carrino JA. Medial meniscus extrusion on knee MRI: is extent associated with severity of degeneration or type of tear? *AJR Am J Roentgenol.* 2004;183(1):17-23.
  35. Floyd ER, Carlson GB, LaPrade RF. Arthroscopic-Assisted Lateral Meniscal Allograft Transplantation With Open Ligamentous Extra-Articular Tenodesis. *Arthrosc Tech.* 2021;10(3):e903-e8.
  36. Geeslin AG, Civitarese D, Turnbull TL, Dornan GJ, Fuso FA, LaPrade RF. Influence of lateral meniscal posterior root avulsions and the menisiofemoral ligaments on tibiofemoral contact mechanics. *Knee Surg Sports Traumatol Arthrosc.* 2016;24(5):1469-77.
  37. LaPrade RF, Matheny LM, Moulton SG, James EW, Dean CS. Posterior Meniscal Root Repairs: Outcomes of an Anatomic Transtibial Pull-Out Technique. *Am J Sports Med.* 2017;45(4):884-91.
  38. James EW, Johannsen, A.M., Cinque, M.E., Chahla, J., LaPrade, R.F. An evidence-based approach to the diagnosis and treatment of meniscal root tears. *Minerva Ortopedica e Traumatologica.* 2017;68(2):81-90.
  39. Stärke C, Kopf S, Gröbel K-H, Becker R. The Effect of a Nonanatomic Repair of the Meniscal Horn Attachment on Meniscal Tension: A Biomechanical Study. *Arthroscopy: The Journal of Arthroscopic & Related Surgery.* 2010;26(3):358-65.
  40. Shoemaker SC, Markolf KL. The role of the meniscus in the anterior-posterior stability of the loaded anterior cruciate-deficient knee. Effects of partial versus total excision. *J Bone Joint Surg Am.* 1986;68(1):71-9.
  41. Musahl V, Citak M, O'Loughlin PF, Choi D, Bedi A, Pearle AD. The effect of medial versus lateral meniscectomy on the stability of the anterior cruciate ligament-deficient knee. *Am J Sports Med.* 2010;38(8):1591-7.
  42. DePhillipo NN, Dekker TJ, Aman ZS, Bernholt D, Grantham WJ, LaPrade RF. Incidence and Healing Rates of Meniscal Tears in Patients Undergoing Repair During the First Stage of 2-Stage Revision Anterior Cruciate Ligament Reconstruction. *Am J Sports Med.* 2019;47(14):3389-95.
  43. Parkinson B, Robb C, Thomas M, Thompson P, Spalding T. Factors That Predict Failure in Anatomic Single-Bundle Anterior Cruciate Ligament Reconstruction. *Am J Sports Med.* 2017;45(7):1529-36.
  44. Logan CA, Aman ZS, Kemler BR, Storaci HW, Dornan GJ, LaPrade RF. Influence of Medial Meniscus Bucket-Handle Repair in Setting of Anterior Cruciate Ligament Reconstruction on Tibiofemoral Contact Mechanics: A Biomechanical Study. *Arthroscopy.* 2019;35(8):2412-20.
  45. Steineman BD, LaPrade RF, Haut Donahue TL. Nonanatomic Placement of Posteromedial Meniscal Root Repairs: A Finite Element Study. *J Biomech Eng.* 2020;142(8).
  46. DePhillipo NN, Kennedy MI, Chahla J, LaPrade RF. Type II Medial Meniscus Root Repair With Peripheral Release for Addressing Meniscal Extrusion. *Arthrosc Tech.* 2019;8(9):e941-e6.
  47. Krych AJ, Bernard CD, Kennedy NI, Tagliero AJ, Camp CL, Levy BA, et al. Medial Versus Lateral Meniscus Root Tears: Is There a Difference in Injury Presentation, Treatment Decisions, and Surgical Repair Outcomes? *Arthroscopy.* 2020;36(4):1135-41.
  48. LaPrade RF, LaPrade CM, Ellman MB, Turnbull TL, Cerminara AJ, Wijdicks CA. Cyclic displacement after meniscal root repair fixation: a human biomechanical evaluation. *Am J Sports Med.* 2015;43(4):892-8.
  49. LaPrade RF, Ho CP, James E, Crespo B, LaPrade CM, Matheny LM. Diagnostic accuracy of 3.0 T magnetic resonance imaging for the detection of meniscus posterior root pathology. *Knee Surg Sports Traumatol Arthrosc.* 2015;23(1):152-7.
  50. Brody JM, Hulstyn MJ, Fleming BC, Tung GA. The meniscal roots: gross anatomic correlation with 3-T MRI findings. *AJR Am J Roentgenol.* 2007;188(5):W446-50.
  51. Choi SH, Bae S, Ji SK, Chang MJ. The MRI findings of meniscal root tear of the medial meniscus: emphasis on coronal, sagittal and axial images. *Knee Surg Sports Traumatol Arthrosc.* 2012;20(10):2098-103.
  52. Magee T. MR findings of meniscal extrusion correlated with arthroscopy. *J Magn Reson Imaging.* 2008;28(2):466-70.
  53. DePhillipo NN, Kennedy MI, Chahla J, LaPrade RF. Type II Medial Meniscus Root Repair With Peripheral Release for Addressing Meniscal Extrusion. *Arthrosc Tech.* 2019;8(9):e941-e6.
  54. Dean RS, DePhillipo NN, Monson JK, LaPrade RF. Peripheral Stabilization Suture to Address Meniscal Extrusion in a Revision Meniscal Root Repair: Surgical Technique and Rehabilitation Protocol. *Arthrosc Tech.* 2020;9(8):e1211-e8.
  55. Lim HC, Bae JH, Wang JH, Seok CW, Kim MK. Non-operative treatment of degenerative posterior root tear of the medial meniscus. *Knee Surg Sports Traumatol Arthrosc.* 2010;18(4):535-9.
  56. Jung YH, Choi NH, Oh JS, Victoroff BN. All-inside repair for a root tear of the medial meniscus using a suture anchor. *Am J Sports Med.* 2012;40(6):1406-11.
  57. Hapa O, Aksahin E, Erduran M, Davul S, Havitcioglu H, LaPrade RF, et al. The influence of suture material on the strength of horizontal mattress suture configuration for meniscus repair. *Knee.* 2013;20(6):577-80.
  58. Herrlin S, Hällander M, Wange P, Weidenhielm L, Werner S. Arthroscopic or conservative treatment of degenerative medial meniscal tears: a prospective randomised trial. *Knee Surg Sports Traumatol Arthrosc.* 2007;15(4):393-401.
  59. Furumatsu T, Kodama Y, Kamatsuki Y, Hino T, Okazaki Y, Ozaki T. Meniscal Extrusion Progresses Shortly after the Medial Meniscus Posterior Root Tear. *Knee Surg Relat Res.* 2017;29(4):295-301.
  60. Kaplan DJ, Alaia EF, Dold AP, Meislin RJ, Strauss EJ, Jazrawi LM, et al. Increased extrusion and ICRS grades at 2-year follow-up following transtibial medial meniscal root repair evaluated by MRI. *Knee Surg Sports Traumatol Arthrosc.* 2018;26(9):2826-34.
  61. Moon HK, Koh YG, Kim YC, Park YS, Jo SB, Kwon SK. Prognostic factors of arthroscopic pull-out repair for a posterior root tear of the medial meniscus. *Am J*



- Sports Med. 2012;40(5):1138-43.
62. Daney BT, Aman ZS, Krob JJ, Storaci HW, Brady AW, Nakama G, et al. Utilization of Transtibial Centralization Suture Best Minimizes Extrusion and Restores Tibiofemoral Contact Mechanics for Anatomic Medial Meniscal Root Repairs in a Cadaveric Model. *Am J Sports Med.* 2019;47(7):1591-600.
  63. Nakama GY, Kaleka CC, Franciozi CE, Astur DC, Debieux P, Krob JJ, et al. Biomechanical Comparison of Vertical Mattress and Cross-stitch Suture Techniques and Single- and Double-Row Configurations for the Treatment of Bucket-Handle Medial Meniscal Tears. *Am J Sports Med.* 2019;47(5):1194-202.
  64. Feucht MJ, Grande E, Brunhuber J, Rosenstiel N, Burgkart R, Imhoff AB, et al. Biomechanical comparison between suture anchor and transtibial pull-out repair for posterior medial meniscus root tears. *Am J Sports Med.* 2014;42(1):187-93.
  65. Kim JH, Chung JH, Lee DH, Lee YS, Kim JR, Ryu KJ. Arthroscopic suture anchor repair versus pullout suture repair in posterior root tear of the medial meniscus: a prospective comparison study. *Arthroscopy.* 2011;27(12):1644-53.
  66. Faucett SC, Geisler BP, Chahla J, Krych AJ, Kurzweil PR, Garner AM, et al. Meniscus Root Repair vs Meniscectomy or Nonoperative Management to Prevent Knee Osteoarthritis After Medial Meniscus Root Tears: Clinical and Economic Effectiveness. *Am J Sports Med.* 2019;47(3):762-9.
  67. Chung KS, Ha JK, Ra HJ, Kim JG. A meta-analysis of clinical and radiographic outcomes of posterior horn medial meniscus root repairs. *Knee Surg Sports Traumatol Arthrosc.* 2016;24(5):1455-68.
  68. Feucht MJ, Kühle J, Bode G, Mehl J, Schmal H, Südkamp NP, et al. Arthroscopic Transtibial Pullout Repair for Posterior Medial Meniscus Root Tears: A Systematic Review of Clinical, Radiographic, and Second-Look Arthroscopic Results. *Arthroscopy.* 2015;31(9):1808-16.
  69. Lee DW, Ha JK, Kim JG. Medial meniscus posterior root tear: a comprehensive review. *Knee Surg Relat Res.* 2014;26(3):125-34.
  70. Feucht MJ, Grande E, Brunhuber J, Burgkart R, Imhoff AB, Braun S. Biomechanical evaluation of different suture techniques for arthroscopic transtibial pull-out repair of posterior medial meniscus root tears. *Am J Sports Med.* 2013;41(12):2784-90.
  71. Woodmass JM, LaPrade RF, Sgaglione NA, Nakamura N, Krych AJ. Meniscal Repair: Reconsidering Indications, Techniques, and Biologic Augmentation. *J Bone Joint Surg Am.* 2017;99(14):1222-31.
  72. Stärke C, Kopf S, Lippisch R, Lohmann CH, Becker R. Tensile forces on repaired medial meniscal root tears. *Arthroscopy.* 2013;29(2):205-12.
  73. Lee HI, Park D, Cho J. Clinical and Radiological Results with Second-Look Arthroscopic Findings after Open Wedge High Tibial Osteotomy without Arthroscopic Procedures for Medial Meniscal Root Tears. *Knee Surg Relat Res.* 2018;30(1):34-41.
  74. Ke X, Qiu J, Chen S, Sun X, Wu F, Yang G, et al. Concurrent arthroscopic meniscal repair during open-wedge high tibial osteotomy is not clinically beneficial for medial meniscus posterior root tears. *Knee Surg Sports Traumatol Arthrosc.* 2021;29(3):955-65.
  75. Nha KW, Lee YS, Hwang DH, Kwon JH, Chae DJ, Park YJ, et al. Second-look arthroscopic findings after open-wedge high tibia osteotomy focusing on the posterior root tears of the medial meniscus. *Arthroscopy.* 2013;29(2):226-31.
  76. Jing L, Liu K, Wang X, Wang X, Li Z, Zhang X, et al. Second-look arthroscopic findings after medial open-wedge high tibial osteotomy combined with all-inside repair of medial meniscus posterior root tears. *J Orthop Surg (Hong Kong).* 2020;28(1):2309499019888836.
  77. Cinque ME, Geeslin AG, Chahla J, Dornan GJ, LaPrade RF. Two-Tunnel Transtibial Repair of Radial Meniscus Tears Produces Comparable Results to Inside-Out Repair of Vertical Meniscus Tears. *Am J Sports Med.* 2017;45(10):2253-9.