

**SYSTEMATIC REVIEW**

# Intramedullary Nailing Versus Plate Fixation for Humeral Shaft Fractures: A Systematic Review and Meta-Analysis

Kamil M. Amer, MD<sup>1</sup>; Adam M. Kurland, MD, MPH<sup>1</sup>; Brendan Smith, MD<sup>2</sup>; Zuhdi Abdo, MD<sup>1</sup>; Rami Amer, MD<sup>3</sup>; Michael M. Vosbikian, MD<sup>1</sup>; Irfan H. Ahmed, MD<sup>1</sup>

Research performed at the Rutgers New Jersey Medical School, Newark, NJ, USA

Received: 15 March 2021

Accepted: 25 September 2021

**Abstract**

**Background:** The two techniques most utilized in the surgical treatment of humeral shaft fractures are open reduction internal fixation (ORIF) and intramedullary nailing (IMN). Although there have been multiple comparative clinical studies comparing outcomes for these two treatments, studies have not suggested one approach to be superior to the other. The purpose of this study is to perform a systematic literature review and meta-analysis of studies that evaluated the treatment of humeral shaft fractures with either ORIF or intramedullary nail.

**Methods:** We conducted this meta-analysis utilizing stricter inclusion and broader exclusion criteria to examine these two common approaches. We examined those articles which have compared first-time, closed fractures of the humeral diaphysis in adults in fracture patterns that could be treated equivalently by intramedullary nail or plate fixation. The primary outcome of interest was nonunion, and studies that did not report nonunion rates were excluded.

**Results:** There were a total of 1,926 abstracts reviewed and a total of three articles were included in the final analysis after screening. There was no significant difference in the incidence of nonunion between plating (2/111, 1.8%) and nailing (4/104, 3.9%) ( $P>0.05$ ). The mean difference in average time to union for plated fractures and nailed fractures was 1.11 weeks (95% CI 0.82 to 1.40) which was statistically significant ( $P<0.05$ ). There was a significant difference in the incidence of radial nerve palsy (12/111, 10.8%) for plating compared to nailing (0/104, 0%) ( $P=0.0004$ ). There was no difference in incidence of post-operative infection between the two groups intramedullary nailing ( $P>0.05$ ).

**Conclusion:** The results of this analysis demonstrate an increased risk of iatrogenic radial nerve injury, and a significantly shorter time to union when treating humeral shaft fractures with plating as compared to intramedullary nailing. There was no difference in the rates of nonunion or delayed union. Based on the evidence, both plating and nailing can achieve a similar treatment effect on humeral shaft fractures.

**Level of evidence:** II

**Keywords:** Humeral fractures, Intramedullary nailing, Internal fracture fixation, Malunited fractures, Malunited fractures

**Introduction**

Humeral shaft fractures are among the most common orthopedic injuries comprising between 1 and 3% of annual fractures and represent 20% of all humerus fractures (1,2). There is a bimodal presentation, with the greatest concentration occurring

as a result of a fall in the elderly patient and to a lesser but still significant degree high energy trauma in the younger population (3). Most of these fractures can be managed non-operatively with operative treatment indicated for open fractures (seen in approximately 25% of cases),

**Corresponding Author:** Adam M. Kurland, Department of Orthopaedic Surgery, Rutgers New Jersey Medical School, Newark, NJ, USA  
Email: adam.kurland@rutgers.edu



THE ONLINE VERSION OF THIS ARTICLE  
ABJS.MUMS.AC.IR

neurovascular injury, articular involvement, pathologic fractures, and symptomatic malunion or nonunion in non-operatively treated fractures.

The two techniques most utilized in the surgical treatment of humeral shaft fractures are open reduction internal fixation with a plate (ORIF) or antegrade intramedullary nailing (IMN). Although there have been multiple randomized control trials (RCT) and comparative clinical studies examining the rate of nonunion, time to union, iatrogenic injury, anatomic alignment and mechanical function, neurovascular complications, intraoperative radiation exposure, and the technical difficulties of each, there remains no conclusive evidence in support of either ORIF with a plate or IMN due to comparable outcomes and conflicting findings (4-8).

To further the discussion, we are conducting this meta-analysis utilizing stricter inclusion criteria to examine these two common approaches to operative management of humeral shaft fractures. We are examining only those articles which have compared first-time, closed fractures of the humeral diaphysis in adults in fracture patterns that could be treated equivalently by intramedullary nail or plate fixation. Excluded were articles that included in their analysis open fractures, penetrating trauma, radial nerve palsy at the time of examination, as well as fractures of the proximal or distal third of the humeral shaft and alternative fixation techniques.

## Materials and Methods

### Search strategy and inclusion criteria

This study followed the PRISMA 2009 reporting guidelines for systematic reviews and meta-analyses. Pubmed, Web of Science, Cochrane Database and Scopus were searched using the following search string: ((humeral shaft fracture OR humerus diaphyseal fracture OR humerus shaft fracture)) AND (plate OR nail OR intramedullary) in all fields. The search returned 3,066 total hits after filtering for articles in the English language. A total of 1,140 duplicates were identified searching by title or PubMed ID when available, and 1,926 abstracts were reviewed by a single author for inclusion. Studies were included if they were prospective randomized or non-randomized clinical trials on closed traumatic midshaft fractures (AO types 12 A-C) of the humerus in human adults (age > 18 years) comparing treatment with plate fixation (ORIF, MIPO, LISS, DCP, LCP) and intramedullary fixation (Ender's nail, intramedullary nail, Hackethal nail). The primary outcome of interest was nonunion, and studies that did not report nonunion rates were excluded. Exclusion criteria included not reporting union rates, studies treating nonunions of humeral shaft fractures, proximal or distal humerus fractures, penetrating trauma including gunshot wounds, pathologic fractures, and concomitant or existing neurologic injury to ipsilateral extremity.

### Data extraction

Data was extracted for the remaining 3 studies by a single author into an excel sheet for the following prospectively chosen outcomes: nonunion, delayed

union, time to union, iatrogenic radial nerve palsy, infection risk, operative time, and functional shoulder outcomes.

### Statistical Analysis

All statistical analysis was performed in GraphPad Prism [GraphPad Software, San Diego, CA] or Cochrane Review Manager [Cochrane, London, UK]. Categorical variables were assessed using Chi-Squared with  $P < 0.05$  considered statistically significant. Quantitative variables were assessed using unpaired two-tailed t-test and  $P < 0.05$  again considered statistically significant. A Mann-Whitney unpaired test was used in the case of abnormally distributed data. Risk ratios, forest plots, and tests of heterogeneity were completed using the RevMan5 software [Cochrane, London, UK] and the Mantel-Haenszel model with random effects. We examined statistical homogeneity using Cochrane's Q test and  $I^2$  statistics, with  $I^2 > 40\%$  considered having heterogeneity. Heterogeneity in meta-analysis refers to the variation in study outcomes between studies. While there are no absolute values for this variable to indicate amount of heterogeneity between articles, there are established ranges that are agreed upon and are interpreted as follows: Values of  $I^2$  that are between 0% to 40% demonstrates that there is no to mild heterogeneity and it might not play an important factor. Values between 41% to 60% represent moderate heterogeneity; values between 61% to 100% may represent substantial heterogeneity and should be an important factor considered when analyzing data.

### Risk of Bias Assessment

Risk of bias assessment and visual representations were made using the Cochrane Risk of Bias tool which qualitatively assesses for selection bias, performance bias, detection bias, attrition bias, and reporting bias (9).

## Results

### Search results

A total of 1,926 abstracts were reviewed for inclusion, and 1,872 abstracts were excluded. Fifty-four abstracts were found to meet screening criteria and full-text versions were assessed. Forty-eight of the fifty-four articles were excluded: 16 retrospective cohort/database studies, 1 which included distal third humerus fractures, one unavailable in English, three pre-existing neurologic injury, one nonunion treatment, 21 which included open fractures or penetrating trauma, three which did not report nonunion incidence, one review paper, and one full-text version unavailable. Two studies that met all inclusion criteria were subsequently excluded because they utilized flexible nails in the treatment of humeral shaft fractures which is not a widely accepted treatment modality (10,11). One additional study by Wang et. al, was excluded when it came to the author's attention that the data appeared to be reprinted in a paper by Li et al (12, 13). A PRISMA diagram for study inclusion is presented in [Figure 1] (14). The three studies included in the final analysis were all randomized controlled clinical trials with a total of 215 patients, of whom 111 were treated with ORIF, MIPO, LCP, DCP and 104 patients who were

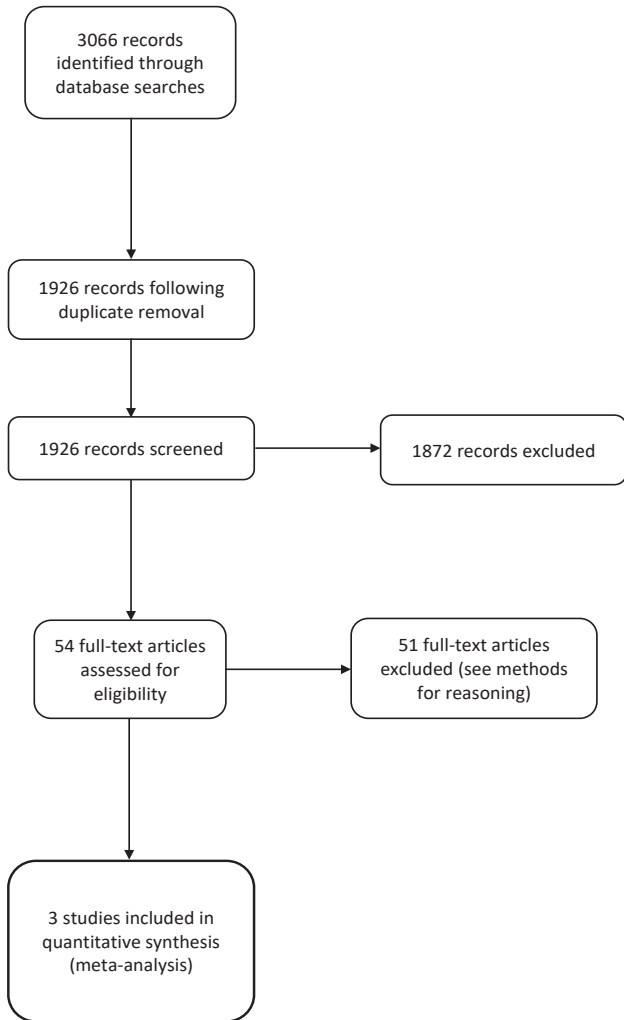


Figure 1. PRISMA diagram detailing review and inclusion/exclusion of articles.

treated with IM nail (simple or expandable). Risk of bias assessment is shown in [Figure 2].

**Nonunion**

All included studies reported incidence of nonunion. The incidence of nonunion in patients treated with

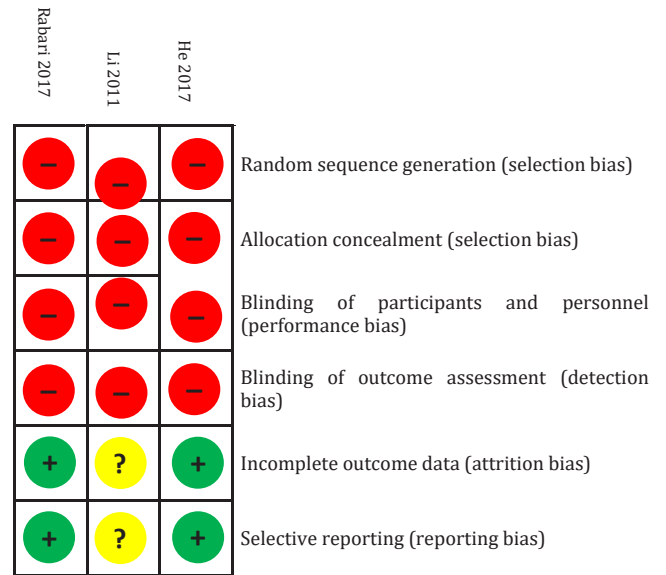


Figure 2. Risk of bias assessment of the included studies.

plating was 2/111 (1.8%) and in patients treated with nailing was 4/104 (3.9%). The difference in proportions was not significant by a Chi-Squared test ( $P=0.3631$ ). The relative risk of nonunion was 0.4685 (95% CI 0.1017 to 2.143) for plating versus nailing, and the NNT is 48.92. is a forest plot of the relative risk for nonunion [Figure 3]. The summary risk ratio is 0.61 (95% CI 0.12 to 3.01). Z-test for overall effect was non-significant ( $P=0.55$ ). There was no significant heterogeneity among the study data ( $I^2=0\%$  variation across studies due to heterogeneity,  $P=0.48$ ) subsequently compromising the generalizability to all patients. One study reported data on delayed union (13). In that study, there were no delayed unions in the plate group and one delayed union in the nail group. Figure 4 shows a funnel plot for reported relative risk of the primary outcome of humeral shaft fracture nonunion and does not suggest publication bias for the included studies [Figure 4].

**Time to Union**

Two studies reported time to union for closed diaphyseal humerus fractures treated by plate or nail

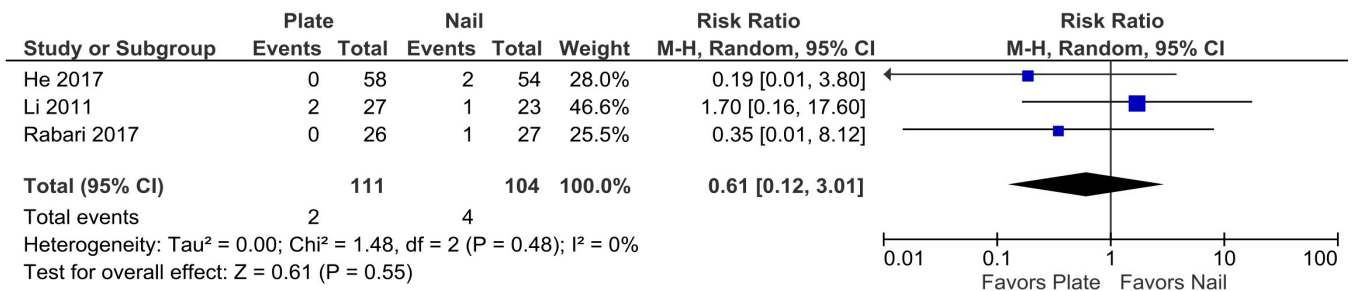


Figure 3. Forest plot of the risk ratio for nonunion.

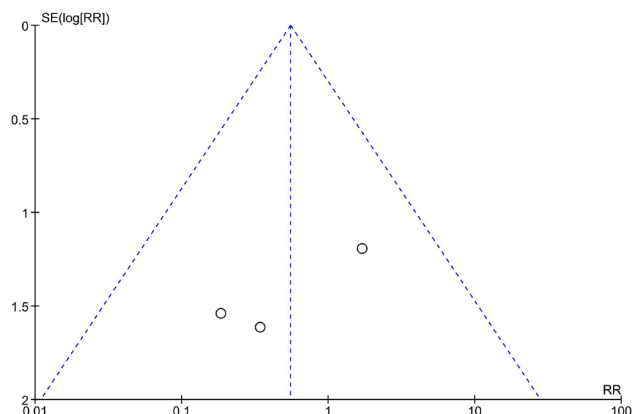


Figure 4. Funnel plot of reported relative risk for nonunion.

(15, 16). The average time to union for plated fractures is 14.61 weeks (95% CI 12.20 to 17.02) and the average time to union for nailed fractures is 13.44 (95% CI 12.35 to 14.52). The difference was significant by two-tailed unpaired t-test of difference of means ( $P=0.03$ ). Figure 5 illustrates the forest plot of the summary mean difference of time to union after plating or nailing [Figure 5]. The summary mean difference of time to radiographic union in weeks was 1.11 (95% CI 0.82 to 1.40) which was significantly lower in the nailing group ( $P<0.00001$ ). There was minimal statistical heterogeneity ( $I^2=0\%$ ,  $P=0.57$ )

### Iatrogenic Radial Nerve Palsy

All three studies reported the incidence of iatrogenic

radial nerve palsy after surgical fixation of the diaphysis of the humeral shaft. The incidence of radial nerve palsy is 12/111 (10.8%) for patients who underwent plating and 0/104 (0%) for nailing. The difference in proportions is significantly different ( $P=0.0004$ ) by Fisher's exact test. Figure 6 is a forest plot comparing the risk ratio of iatrogenic radial nerve palsy after ORIF with a plate and IMN [Figure 6]. The summary risk ratio of iatrogenic radial nerve palsy is 8.45 (95% CI 1.59 to 44.87,  $P=0.01$ ) for plating versus nailing, and there is minimal statistical heterogeneity ( $I^2=0\%$ ,  $P=0.95$ ).

### Post-operative Infection Risk

All three studies reported the incidence of post-operative infection after plating or nailing of humeral shaft fractures. The incidence of post-operative infection was 4/111 (3.6%) after plating and 1/104 (1.0%) after intramedullary nailing. The difference was not significant ( $P=0.1223$ ). Figure 7 is a forest plot comparing the relative risk of post-operative infection after ORIF and IMN [Figure 7]. The summary risk ratio was 4.92 (95% CI 0.59 to 41.09) but the test for overall effect was not significant ( $P=0.14$ ). There was minimal statistical heterogeneity ( $I^2=0\%$ ,  $P=0.96$ ).

### Functional Scores

All three studies reported upper extremity functional outcome scores, but each used a different rating scale, which precluded compilation for meta-analysis. Li et al. reported significantly higher Constant Shoulder scores in the plate group as compared to nailing ( $P=0.004$ ) but found no significant difference in ASES scores between the groups ( $P=0.07$ ).<sup>13</sup> He et al.

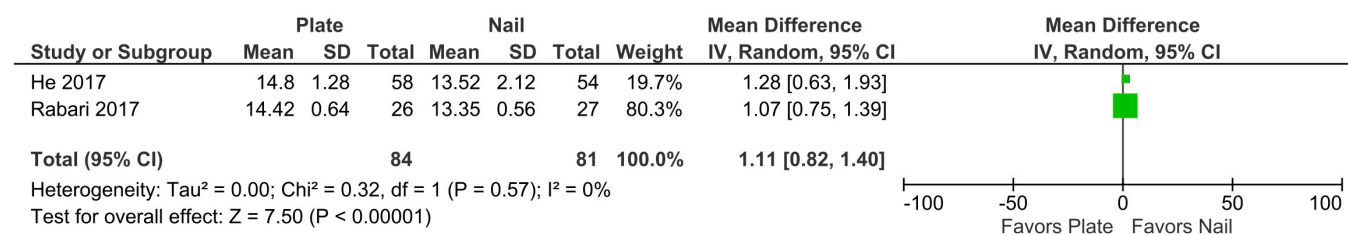


Figure 5. Forest plot of the summary mean difference of time to union after surgical fixation.

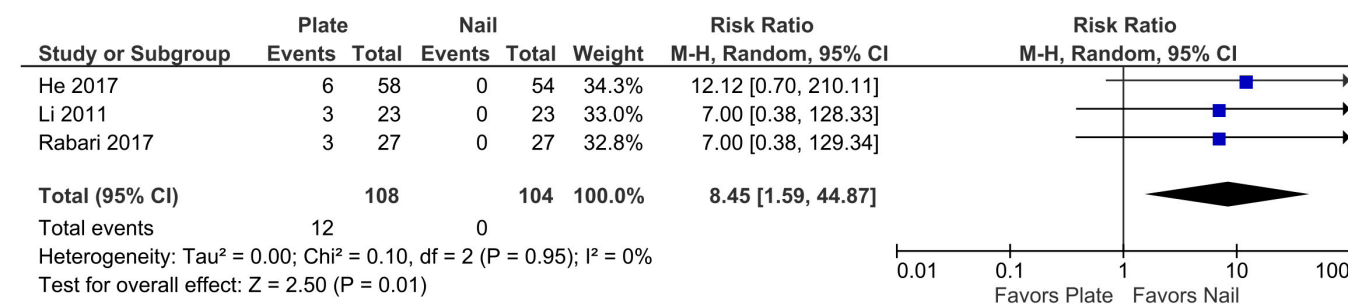


Figure 6. Forest plot for iatrogenic radial nerve palsy following surgical fixation.



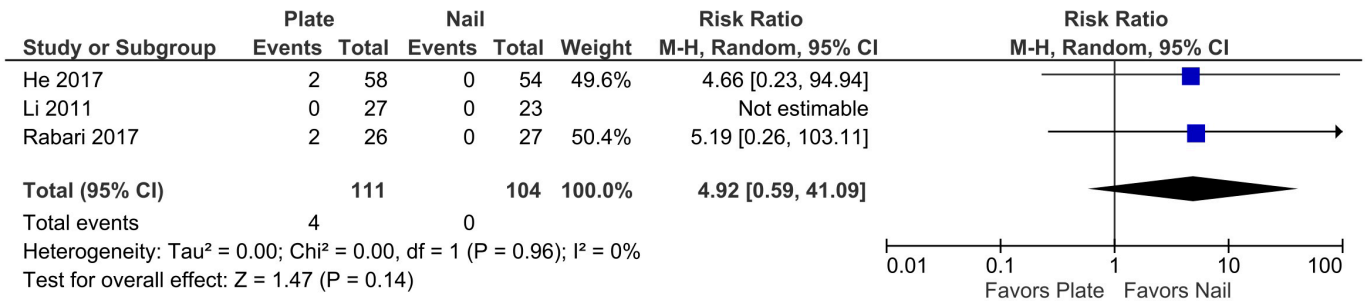


Figure 7. Forest plot of relative risk of post-operative infection.

found a significantly higher proportion of excellent Neer Shoulder scores in patients treated with intramedullary nails as compared to plating (15). Rabari et al. found a significantly higher proportion of excellent (DASH score 0 – 20) DASH scores at final follow-up in closed diaphyseal humerus fractures treated with a plate as compared to an interlocking IM nail ( $P=0.0073$ ) (16).

### Discussion

Although several options exist for the treatment of diaphyseal humeral shaft fractures including plating or intramedullary nailing, which of these provides the best patient outcomes is an area of active research. As a result, a number of prior meta-analyses have attempted to compare the outcomes of plating and nailing of humeral shaft fractures (17-29). However, there are inconsistencies evident in the findings of these previous meta-analyses. While most report no significant difference in the rate of post-operative union between plating and nailing, findings vary regarding post-operative infection risk, shoulder function scores, and the rate of iatrogenic radial nerve palsy. Such inconsistencies can make it difficult for surgeons to utilize the clinical findings of these studies for making patient care decisions. The aim of this meta-analysis was therefore to evaluate the outcomes of plating or nailing of humeral shaft fractures for a very specific subset of humeral shaft fractures in order to guide clinical decision making.

In this meta-analysis of acute, closed, diaphyseal humeral shaft fractures in adult patients without prior radial nerve palsy, the overall relative risk of nonunion was not significantly different when comparing plating to nailing ( $P=0.55$ ). This finding is in agreement with other prior meta-analyses, and suggests that with regard to fracture union rates, that plating and nailing achieve similar outcomes (20-24, 28, 29). However, the present study findings suggest there is a higher relative risk of iatrogenic radial nerve palsy (RR 8.45,  $P=0.01$ ) and longer time to union (1.11 weeks,  $P<0.00001$ ) with plating as compared to nailing of this subset of humerus fractures. There was no difference in post-operative infection risk. Although an important metric for clinical decision making, there were not enough studies reporting on operative time or shoulder

function scores to perform meta-analyses on these secondary outcomes.

Of importance is the present finding that iatrogenic radial nerve palsy risk is significantly higher in patients treated with MIPO or ORIF than with IMN, while a number of previous meta-analyses had reported no significant difference in the incidence of post-operative radial nerve palsy when comparing plating and nailing (22-24, 28). This difference may have resulted from the more stringent inclusion criteria utilized in the present analysis. For example, other studies that found no difference in post-operative radial nerve palsy may have been a result of the inclusion of open fractures or penetrating trauma which can result in significant soft tissue damage and associated traumatic radial nerve palsy (as opposed to iatrogenic). It is important to note that the rate of recovery of humeral shaft fracture associated iatrogenic radial nerve palsy has been found to be 90 – 95% and takes on average 4 months to resolve irrespective of fixation modality (30, 31). Regardless, the possibility of secondary radial nerve palsy is an important discussion to have with patients during surgical counseling.

The low number of studies that met our inclusion/exclusion criteria was a significant limitation to this study, and as a result the risk of shoulder impingement after antegrade intramedullary nailing of diaphyseal humerus fractures could not be studied. The balance of risk of radial nerve palsy, even with high rate of resolution, with plating and the risk of impingement and post-op rotator cuff weakness/pain with antegrade nailing are therefore important avenues for future clinical research.

This meta-analysis, with stricter inclusion and exclusion criteria, found no difference in union rates between the two groups of study, but our findings do suggest that IMN has lower rates of iatrogenic radial nerve injury and shorter time to union. While shorter time to union was statistically significant in IMN this difference was only found to be a single week and as such may not contribute a substantial role in clinical decision-making. Additionally, given the limited sample size, this discrepancy could be readily explained by nonadherence to strict follow up parameters by either group and thus may not be indicative of a true difference in time to union. As such the clinical significance of this

statistical difference remains in question. The decision to utilize a plate versus an IMN for an operative, closed humeral shaft fracture continues to lack a sufficient body of literature to advocate for one method of fixation as definitively superior to another. Further studies examining functional outcomes scoring after ORIF versus IMN as well as reintervention rates are warranted to help surgeons decide which construct is best for their patients.

### Acknowledgment

None.

**Patient Consent:** Due to the nature of this research patient consent is not relevant

**Disclosure:** The authors report no conflict of interest concerning the materials or methods used in this study

or the findings specified in this paper.

Kamil M. Amer MD<sup>1</sup>  
Adam M. Kurland MD MPH<sup>1</sup>  
Brendan Smith MD<sup>2</sup>  
Zuhdi Abdo MD<sup>1</sup>  
Rami Amer MD<sup>3</sup>  
Michael M. Vosbikian MD<sup>1</sup>  
Irfan H. Ahmed MD<sup>1</sup>

1 Department of Orthopaedic Surgery, Rutgers New Jersey Medical School, Newark, NJ, USA

2 Department of Orthopedic Surgery, St. Luke's University Health Network, Bethlehem, PA, USA

3 Drexel University, Philadelphia, PA, USA

### References

- Ekholm R, Adami J, Tidermark J, Hansson K, Törnkvist H, Ponzer S. Fractures of the shaft of the humerus. An epidemiological study of 401 fractures. *J Bone Joint Surg Br.* 2006;88(11):1469-73.
- Rose SH, Melton LJ 3rd, Morrey BF, Ilstrup DM, Riggs BL. Epidemiologic features of humeral fractures. *Clin Orthop Relat Res.* 1982;(168):24-30.
- Sarmiento A, Zagorski JB, Zych GA, Latta LL, Capps CA. Functional bracing for the treatment of fractures of the humeral diaphysis. *J Bone Joint Surg Am.* 2000;82(4):478-86.
- Carroll EA, Schweppe M, Langfitt M, Miller AN, Halvorson JJ. Management of humeral shaft fractures. *J Am Acad Orthop Surg.* 2012;20(7):423-33.
- Koch PP, Gross DF, Gerber C. The results of functional (Sarmiento) bracing of humeral shaft fractures. *J Shoulder Elbow Surg.* 2002;11(2):143-50.
- Wallny T, Westermann K, Sagebiel C, Reimer M, Wagner UA. Functional treatment of humeral shaft fractures: indications and results. *J Orthop Trauma.* 1997;11(4):283-7.
- Ring D, Chin K, Taghinia AH, Jupiter JB. Nonunion after functional brace treatment of diaphyseal humerus fractures. *J Trauma.* 2007;62(5):1157-8.
- Hosseini Khameneh SM, Abbasian M, Abrishamkarzadeh H, Bagheri S, Abdollahimajd F, Safdari F, et al. Humeral shaft fracture: a randomized controlled trial of nonoperative versus operative management (plate fixation). *Orthop Res Rev.* 2019;11:141-7.
- Sterne JAC, Savović J, Page MJ, Elbers RG, Blencowe NS, Boutron I, et al. RoB 2: a revised tool for assessing risk of bias in randomised trials. *BMJ.* 2019;366:14898.
- Chiu FY, Chen CM, Lin CF, Lo WH, Huang YL, Chen TH. Closed humeral shaft fractures: a prospective evaluation of surgical treatment. *J Trauma.* 1997;43(6):947-51.
- Rodríguez-Merchán EC. Compression plating versus hackethal nailing in closed humeral shaft fractures failing nonoperative reduction. *J Orthop Trauma.* 1995;9(3):194-7.
- Wang C, Dai G, Wang S, Liu Q, Liu W. The function and muscle strength recovery of shoulder after humeral diaphysis fracture following plating and intramedullary nailing. *Arch Orthop Trauma Surg.* 2013;133(8):1089-94.
- Li Y, Wang C, Wang M, Huang L, Huang Q. Postoperative malrotation of humeral shaft fracture after plating compared with intramedullary nailing. *J Shoulder Elbow Surg.* 2011;20(6):947-54.
- Moher D, Liberati A, Tetzlaff J, Altman DG, PRISMA Group\*. Preferred reporting items for systematic reviews and meta-analyses: the PRISMA statement. *Annals of internal medicine.* 2009;151(4):264-9.
- He SW, Qinruixian, Li B. Internal fixation of shaft humerus fractures by dynamic compression plate or interlocking intramedullary nail: a prospective, randomised study. *Biomedical Research - India.* 2017;28(14):133-40.
- Rabari YB, Prasad DV, Somanni AM, Kumar P. Comparative study of functional outcome of dynamic compression plating with intramedullary interlocking nailing in close fracture shaft of humerus in adults. *International Journal of Research in Orthopaedics.* 2017;3(4):828.
- Zhao JG, Wang J, Meng XH, Zeng XT, Kan SL. Surgical interventions to treat humerus shaft fractures: A network meta-analysis of randomized controlled trials. *PLoS One.* 2017;12(3):e0173634. Published 2017 Mar 23.
- Qiu H, Wei Z, Liu Y, Dong J, Zhou X, Yin L, et al. A Bayesian network meta-analysis of three different surgical procedures for the treatment of humeral shaft fractures. *Medicine (Baltimore).* 2016;95(51):e5464.

19. Kurup H, Hossain M, Andrew JG. Dynamic compression plating versus locked intramedullary nailing for humeral shaft fractures in adults. *Cochrane Database Syst Rev.* 2011;(6):CD005959. Published 2011 Jun 15.
20. Zhao JG, Wang J, Wang C, Kan SL. Intramedullary nail versus plate fixation for humeral shaft fractures: a systematic review of overlapping meta-analyses. *Medicine (Baltimore).* 2015;94(11):e599.
21. Dai J, Chai Y, Wang C, Wen G. Dynamic compression plating versus locked intramedullary nailing for humeral shaft fractures: a meta-analysis of RCTs and nonrandomized studies. *J Orthop Sci.* 2014;19(2):282-91.
22. Ma J, Xing D, Ma X, Gao F, Wei Q, Jia H, et al. Intramedullary nail versus dynamic compression plate fixation in treating humeral shaft fractures: grading the evidence through a meta-analysis. *PLoS One.* 2013;8(12):e82075.
23. Liu GD, Zhang QG, Ou S, Zhou LS, Fei J, Chen HW, et al. Meta-analysis of the outcomes of intramedullary nailing and plate fixation of humeral shaft fractures. *Int J Surg.* 2013;11(9):864-8.
24. Ouyang H, Xiong J, Xiang P, Cui Z, Chen L, Yu B. Plate versus intramedullary nail fixation in the treatment of humeral shaft fractures: an updated meta-analysis. *J Shoulder Elbow Surg.* 2013;22(3):387-95.
25. Wang X, Chen Z, Shao Y, Ma Y, Fu D, Xia Q. A meta-analysis of plate fixation versus intramedullary nailing for humeral shaft fractures. *J Orthop Sci.* 2013;18(3):388-97.
26. Hohmann E, Glatt V, Tetsworth K. Minimally invasive plating versus either open reduction and plate fixation or intramedullary nailing of humeral shaft fractures: a systematic review and meta-analysis of randomized controlled trials. *J Shoulder Elbow Surg.* 2016;25(10):1634-42.
27. Zhang Q, Sun N, Huang Q, Zhu S, Wu X. Minimally Invasive Plating Osteosynthesis in the Treatment of Humeral Shaft Fractures: A Meta-Analysis. *J Invest Surg.* 2017;30(2):133-42.
28. Zheng X, Liu M, Duan X, Shu T, Xiang Z. Antegrade locked intramedullary nailing versus dynamic compression plating for humeral shaft fractures in adults: a meta-analysis of randomized controlled trials. *European Journal of Orthopaedic Surgery & Traumatology.* 2012;22(6):443-7.
29. Hu X, Xu S, Lu H, Chen B, Zhou X, He X, et al. Minimally invasive plate osteosynthesis vs conventional fixation techniques for surgically treated humeral shaft fractures: a meta-analysis. *J Orthop Surg Res.* 2016;11(1):59.
30. Wang JP, Shen WJ, Chen WM, Huang CK, Shen YS, Chen TH. Iatrogenic radial nerve palsy after operative management of humeral shaft fractures. *J Trauma.* 2009; 66(3):800-3.
31. Streufert BD, Eaford I, Sellers TR, Christensen JT, Maxson B, Infante A, et al. Iatrogenic Nerve Palsy Occurs With Anterior and Posterior Approaches for Humeral Shaft Fixation. *J Orthop Trauma.* 2020;34(3):163-8.