

SYSTEMATIC REVIEW

Tantalum Versus Titanium Acetabular Cups in Primary Total Hip Arthroplasty: Current Concept and a Review of the Current Literature

Rohit rambani, MBBS, MRCS (Eng), MS (Orthopaedics), FIMSA, FRCS (Tr & Orth)¹; Mayur Nayak, MBBS, MRCSEd, MS (Orthopaedics)¹; Miss Sheweidin Aziz, MBBS, MRCS (Eng)²; Krishan Almeida, MBChB²

Research performed at the Pilgrim Hospital, United Lincolnshire NHS trust, Boston, UK

Received: 28 January 2021

Accepted: 24 July 2021

Abstract

Background: Primary total hip arthroplasty (THA) is becoming an increasingly popular and efficacious medical procedure. There have been a number of studies evaluating tantalum acetabular cups compared with the conventional titanium acetabular cups for use in total hip arthroplasties. We conducted a systematic review and summarize clinical studies comparing tantalum acetabular cups with the conventional titanium acetabular cups for use in primary total hip arthroplasties.

Methods: A literature search was performed to find all relevant clinical studies until March 2020, which then underwent a further selection criteria. The inclusion criteria was set as follows: Reporting on human patients undergoing primary total hip arthroplasty; Direct comparison between tantalum acetabular cups with conventional titanium acetabular cups for use in primary total hip arthroplasty; Radiological evaluation (cup migration, osteointegration); Clinical (functional scores, need for subsequent revision, patient-reported outcomes); Post-operative complications; Reporting findings in the English Language. After a thorough search a total of six studies were included in the review. The primary outcome measures were clinical outcomes, implant migration, change in bone mineral density and rate of revision and infection.

Results: Tantalum is superior to titanium with regards to fewer radiolucencies, 100% survivorship at 12 years post-operatively, improved long-term implant osteointegration and survivorship as well as decreasing osteolysis and mechanical loosening. There has been no significant difference in radioisometric analysis, bone mineral density or Harris Hip Score. Revision and infection rates were found to be significantly lower in tantalum group at 10 years from pooled data of national joint registry (England and Wales), while it was found to be higher in the same at 9 years from pooled data of Swedish and Australian registry although this is not statistically significant.

Conclusion: The use of tantalum should be reserved for cases of high risk of failure or mechanical loosening, where failure of a contralateral joint occurred. The use of Tantalum carries lower risk of failure and infection. Further studies with longer follow-up would be useful in drawing further conclusions.

Level of evidence: II

Keywords: Acetabular cup, Primary total hip arthroplasty, Tantalum, Titanium

Introduction

Total hip arthroplasty (THA) is undoubtedly one of the most efficacious medical procedures in clinical medicine (1, 2). With demand growing exponentially, it is estimated that the United States will

perform around 174% more total hip arthroplasties, reaching 572,000 cases by the year 2030 (3). Advances in acetabular cap design have improved the longevity of the procedure, mainly through reduced aseptic cup

Corresponding Author: Rohit Rambani, Department of Orthopaedics, Pilgrim Hospital, Boston, United Lincolnshire NHS trust, Lincolnshire, UK
Email: rohitrambani@gmail.com



THE ONLINE VERSION OF THIS ARTICLE
ABJS.MUMS.AC.IR

loosening rates (4–6). However, younger and more active patients have often found that their results aren't nearly as impressive as those for elderly patients (7, 8). As the rate of hip replacements continues to grow, alternative technology can help improve the outcomes in these patients.

In 1997 tantalum was introduced in the hope of increased longevity compared to the less porous alternative of conventional titanium acetabular cups (9). While conventional porous materials such as titanium promise acetabular stability through formation of bone within the irregular surface of the implant, improving the implant integration into the host bone referred to as biological fixation through tissue ingrowth and ongrowth; highly porous tantalum works by augmenting structural and functional connection by tissue infiltration and attachment called as osseointegration (10, 11). Tantalum has a three-dimensional porous surface, with an average pore size of 550 μm and a porosity of 75%–80% (12–14). The modulus of elasticity is 3Gpa lying between cortical and subchondral bone (10, 15). Tantalum use in revision total hip arthroplasties has become a favourable alternative, associated with promising mid-term results by several studies, including absence of radiolucency, reduction of polyethylene wear and decreased acetabular cup migration (12–14, 16, 17). Moreover, long-term studies on titanium have demonstrated aseptic loosening and high revision rates (18, 19). In addition, tantalum has also been shown to have a higher coefficient of friction against cancellous bone than its titanium counterpart, ultimately improving stability and survivorship rates (20). Porous tantalum monoblock cups have been proposed to improve survivorship of cementless primary THA. However, there are few direct comparative trials to establish such implants.

The introduction of a promising alternative has prompted several studies to be conducted comparing the true effectiveness of titanium versus tantalum acetabular cups. However, to the best of authors' knowledge, there has yet to be a published review of literature that accumulates all relevant publications comparing the value of tantalum versus titanium acetabular cups in primary hip replacements. As such, we present a general review and summary of clinical studies comparing tantalum acetabular cups with the conventional titanium acetabular cups for use in total hip arthroplasties.

Materials and Methods

Search strategy

The study was conducted in United Lincolnshire NHS trust. Clinical trials were graded according to grade and level of evidence. The authors identified published studies in the English language designed to compare survivorship with tantalum acetabular components versus titanium acetabular components in patients undergoing a primary total hip replacement. A comprehensive and systematic search for articles published in computerized literature databases (MEDLINE, EMBASE and Pubmed) from inception to March 2020, containing the keyword terms tantalum AND titanium AND hip arthroplasty was performed.

Reference lists from articles that met the inclusion data was further investigated for other publications of interest. The search using the aforementioned keywords in the databases Embase, Ovid MEDLINE® In-Process & Other Non-Indexed Citations, Ovid MEDLINE® Daily and Ovid MEDLINE® and Ovid OLDMEDLINE® and Pubmed yielded 632 unique articles, as of March 1, 2020.

Identification of eligibility

Relevant clinical studies were selected for inclusion in this summary based on the following pre-determined eligibility criteria:

- Reporting on human patients undergoing primary total hip arthroplasty
- Direct comparison between tantalum acetabular cups with conventional titanium acetabular cups for use in total hip arthroplasty
- Radiological evaluation (cup migration, osseointegration)
- Clinical (functional scores, need for subsequent revision, patient-reported outcomes)
- Post-operative complications
- Reporting findings in the English Language

Study identification and selection

The studies were analyzed for duplication with resulting number of studies to 466. The authors independently reviewed the titles and abstract of each result, and those that were clearly irrelevant and/or failed to pertain to the pre-determined inclusion criteria (n=426) were eliminated. The remaining forty articles were further scrutinized for clearly relevant trials that indisputably met the inclusion criteria, eliminating a further thirty-four trials. The full-texts of the remaining six articles was independently reviewed by two authors who agreed upon all six remaining articles to be objectively relevant to this summary in discussion [Figure 1].

The characteristics of the six studies included in this review are outlined in [Tables 1; 2]. The references section of the remaining three randomized control trials (RCTs) were consulted for any further articles that may pertain to the inclusion criteria, though no additional studies were identified to be relevant.

Results

Patient demographics

Wegrzyn et al. excluded patients with severe acetabular deformity related to acetabular fracture, severe acetabular dysplasia, acetabular segmental defect, and severe osteoarthritis only including patients with sufficient periacetabular bone stock for peripheral rim fixation (21). A total of 111 hips were randomised into the porous tantalum monoblock cup (TM, n=56) and porous-coated titanium monoblock cup (control, n=55) groups. The mean age in years was 60 +/- 12 and 59 +/- 13 for the TM and control groups with a mean follow up of 143 +/- 7 months and 145 +/- 10 months for the TM and control groups respectively. The total patients lost to follow-up were 7 in the TM group and 9 in control group. 5 patients in the control group and 3 patients in the TM group died before 10-year follow-up. Therefore, a total of 45 patients in TM group and 41 patients in the control

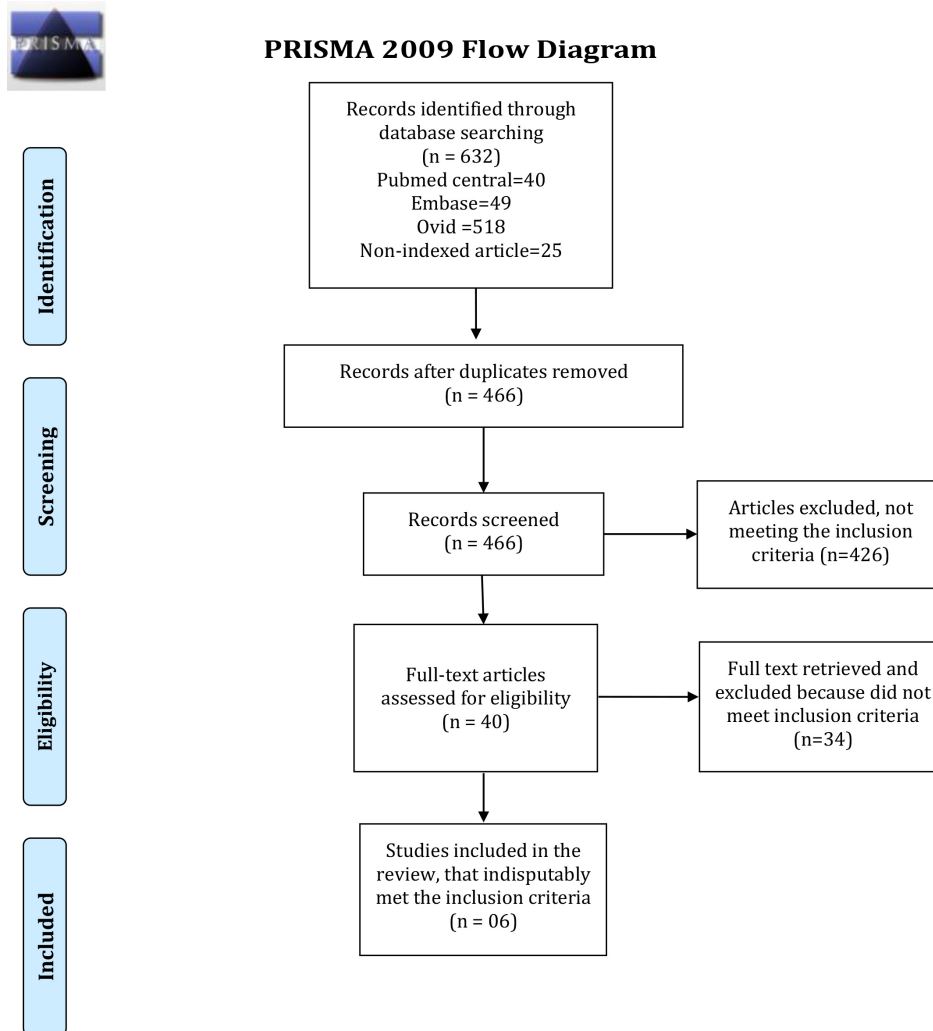


Figure 1. Flow diagram showing study selection.

group could be analyzed at a final follow up of 10 years [Table 1]. Significant difference between both groups lacked in the following pre-operative parameters: BMI, gender ratio, age at surgery and preoperative Harris hip score.

Baad-Hansen et al. (22) randomized patients to either a cementless implant with a titanium fiber-mesh surface (Trilogy cup; Zimmer, Warsaw, IN) or an implant with a trabecular tantalum surface (Monoblock cup; Zimmer) and had a total of 60 patients with a median age 62 (52–76) years, with a random allocation to either group (n=30); All patients received a 28-mm cobalt-chromium alloy head. 2 patients in the Monoblock group and 3 patients in the Trilogy group were lost to follow up. A further 4 patients in the Monoblock and 1 patient in the Trilogy group were excluded from analysis for too few tantalum markers [Table 1]. Ayers et al. randomised a total of 46 patients with a mean age of 58 years, with half allocated to each tantalum or titanium groups with

a minimum follow up of 5 years [Table 1] (23). Patients in this study had a comparable preoperative parameters such as sex distribution, age, BMI, Harris hip score, WOMAC subscores, SF-36 PCS, SF-36 MCS, and UCLA activity score.

Meneghini et al started with 100 patients, with half placed in each, the titanium and porous tantalum groups although the method of randomisation was not specified (24). Only 17 patients met the inclusion criteria and underwent the bone mineral assessment, 10 of which were female. Exclusion criteria included age less than 50 years, THR on the opposite hip, medications effecting bone metabolism, and being unable to attend follow up. Five patients were lost to follow up and the mean follow-up was 7.7 years [Table 1]. A retrospective study was conducted by Laaksonen et al from joint replacement registers i.e., the Swedish Hip Arthroplasty Register (SHAR) and the Australian Orthopaedic Association National Joint Replacement Registry (AOANJRR) between

Table 1. Characteristics of the clinical trials included in the review comparing tantalum acetabular cups with titanium acetabular cups in primary total hip arthroplasties

Study	Study design	Measured Factors	Total number of patients recruited	Final number of patients with Male (n)/ Female (n)	Treatment groups : n	Mean age (yrs)	Follow-up	Results
Wegrzyn et al	Level I Randomized Trial	Osseointegration, migration, radiolucency, osteolytic lesions and gap filling	110 patients	86 M/F=34/52	TM group: 45 Porous Tantalum monoblock cup (Hedrocel, Implex Crop) Non TM group:41 Porous-coated titanium monoblock cup (Elliptical, Implex Crop)	60±12 in TM group 59±13 in Control group	143±7 months TM group and 145±10 months control group	Porous tantalum monoblock cups demonstrated 100% survivorship, and significantly less radiolucency as compared to porouscoated titanium monoblock cups at 12 years
Baad-Hansen et al	Level I Randomized Trial	Cup migration, Bone mineral density and HHS at 3 months	60 patients	60 M/F=34/26	TM group: 30 (Triology cup, Zimmer) Non TM group:30 Trabecular tantalum surface (Monoblock cup, Zimmer)	62 years	2 years	No significant difference in radiostereometry, bone mineral density or Harris Hip Score.
Ayers et al	Level I Randomised Trial	Cup migration	45 patients	45 M/F=19/26	TM group: 23 (Triology, Zimmer) Non TM group: 22 (Trabecular Metal Modular Acetabular System, Zimmer)	58±7years	5 years	No significant difference in radiostereometry analysis
Laaksonen et al	Collaborative registry study SHAR and AOANJRR taken between January 2006 and December 2014	Revision rates vs uncemented cups, and risk of revision due to post-operative infection	Total number of cups analysed uncemented n = 83,596, SHAR n = 13,156, AOANJRR n = 70,440.	95,309 based on registry data SHAR registry; M/F= 8,830/7,922 AOANJRR M/F= 32,750/45,807	TM group: 10,113 Non TM group: 85,196	SHAR registry; (tantalum =61; other=60) AOANJRR (tantalum =70; other=71)	3 years in the TM group and 3.8 years in the uncemented control group	Overall survivorship up to 8 years was slightly higher for uncemented cups and risk of revision was higher for tantalum cup group, with no evidence suggesting a reduced risk of post-operative infection in this group
Meneghini et al	Randomized, prospective trial	Bone mineral density	17 patients	17 M/F=7/10	TM group:9 Monoblock porous tantalum acetabular component Non TM group:8	64 (46-76 years)	7.7 years (6.1 to 8.8 years) (tantalum=7.4 years and titanium 7.9 years)	Tantalum provided significantly improved BMD in posterosuperior zones.
Matharu et al	Retrospective observational study National joint registry (NJR), England and Wales between April 1, 2003 and July 30, 2015	Revision for all-cause acetabular indications, aseptic acetabular loosening, and infection	4 cementless acetabular component (TM and Non TM) designs included; n= 51,966 and were matched for multiple potential confounding factors using propensity Scores after which the final numbers included were 18,200.	18,200 cups and their data were finally analysed M/ F=6,909/11,291	TM group:9100Modular and Continuum) Non TM group:9100(Triology and Triology IT) surface coating	TM=67.2 years Non TM=68.8 years	5 years	TM-coated acetabular implants had a reduced risk of both aseptic and septic revision compared with non-TM implants.

Table 2. Summary of the clinical studies included in the review comparing tantalum acetabular cups with titanium acetabular cups in primary total hip arthroplasties elucidating various measured parameters

Study	Surgical Technique	Radioisometric Analysis	Bone Mineral Density	Radiological Analysis	Clinical Outcomes	Radiological outcomes	Complications
J.Wegrzyn et al.	1) Hardinge's lateral transgluteal approach 2) Anteversion of 15° to 20° 3) Cup abduction of 40° to 45°	None	None	Standard AP and cross table lateral hip radiographs postoperatively, 6 weeks and at regular intervals until latest follow up.	Significant improvement of the Harris Hip Score at 2 months and at latest follow up but not significantly different.	Tantalum demonstrated significantly fewer radiolucencies, 100 % survivorship at a 12 year period, improved long-term implant osteointegration and survivorship while decreasing osteolysis and mechanical loosening	In the TM group, one THA was revised without cup removal for instability with repeated subluxation events associated with mild PE wear at 117 months In titanium one THA was revised for acetabular aseptic loosening at 144 months
Baad-Hansen et al.	1) Single surgeon 2) Posterlateral approach Anteversion 15° and Abduction 45°	- Six to eight 1.0mm Tantalum markers inserted intraoperatively. - RSA measurements done during the first week after surgery and at 3, 12, and 24 months.	- Patients scanned shortly after operation and 1 and 2 years post operatively.	None	- Similar improvement in Harris Hip Score with no significant difference	Both cup types showed excellent fixation. There was no statistically significant difference between the cup types with regard to translation. However, less rotation along the transverse axis was seen in the tantalum cups than in the titanium cups	One hip revised in the titanium group (Trilogy) for small femoral implant causing subsidence
Ayers et al.	Tantalum markers on the femoral implant + Tantalum beads in innominate bone, greater & lesser trochanters and dispersed arrangements.	- Fourteen Tantalum 1.0mm beads in a dispersed arrangement. - Measurements at 6 months and yearly thereafter for 5 years.	None	None	- Improvement in Harris Hip Score, UCLA activity score, pain and SF-36 PCS scores. - No change in SF-36 MCS score. - Significant improvement in WOMAC score. - No significant difference between the cohorts.	There was no significant difference in proximal migration between the tantalum and titanium acetabular cups through the five-year follow-up	None of the patients underwent revision in any of the group. However 2 patients in the titanium group had proximal migration more than 2 mm.
Laaksonen et al.	Compared tantalum cups with various other uncemented cups via SHAR and AONJRR registry Surgical procedure was not described	none	none	none	none	none	Revision [SHAR (%) (TM/Non-TM)]: Infection: 43/36 Fracture:8/16 Dislocation:36/22 Loosening:1/11 Others:12/16 Revision [AONJRR (%): (TM/Non-TM)]: Infection: 16/25 Fracture:19/22 Dislocation:39/25 Loosening:15/20 Others:11/07

Table 2. Continued

Meneghini et al	Not described	None	Bone mineral density was quantified in the five 3-mm cross-sectional slices in the 2 regions (anterosuperior and posterosuperior) of interest adjacent to the acetabular component and these were categorized into various zones. Contralateral hip BMD was taken as control	none	None	The absolute and relative decrease in BMD from preoperative level was less in zones 9 to 15 mm adjacent to the porous tantalum compared to the titanium component significantly and predominated posteriorly	None described
Matharu et al	67.2% used posterior approach in TM group and 66.6% used posterior approach in non TM group	none	none	none	none	none	Revision in whole cohort Dislocation/subluxation = n 100; 47.4% Infection n = 32; 15.2%, Malalignment n= 29; 13.7%, Aseptic loosening n =23; 10.9% All these complications were significantly less in the tantalum group as compared to the non-tantalum group.

January 2006 and December 2014 and Matharu et al who extracted data from the National joint registry (NJR), England and Wales between April 1, 2003 and July 30, 2015 [Table 1] (25, 26).

Surgical technique

Hardinge's lateral transgluteal approach was used in all the patients by Wegrzyn et al. (21) et al. Reaming for acetabular component was performed to the size of the final implant followed by cup positioning in accordance with the neighbouring structures at an abduction of 40° to 45° and anteversion of 15° to 20° [Table 2]. Factors such as autologous bone graft, cement, screws or other osteogenic factors were not used for acetabular fixation. A 28-mm f cobalt-chromium alloy (CoCr) or zirconia ceramic femoral head was used in all cases. Baad-Hansen et al. used a posterolateral approach implanting cups at 45° of abduction and 15° of anteversion [Table 2] (22). The Trilogy cup was inserted with a 1–2 mm under-reaming technique and the Monoblock cup

chosen for implantation had the same size as the last-used reamer. Ayers et al. added tantalum beads into the periarticular bone and each trochanter in addition to the tantalum markers on the femoral implant (24). There were additional beads implanted on the periphery of the polyethylene liners [Table 2].

Radioisometric analysis

Both Baad-Hansen et al. and Ayers et al. used 1.0 mm tantalum markers placed intraoperatively in the periacetabular bone (22, 23). While Baad-Hansen et al. inserted six to eight markers to form a reference rigid body (22). Ayers et al. inserted 7 beads in the periacetabular bone, 5 beads in the greater trochanter and 2 beads in the lesser trochanter in a dispersed arrangement to confer precise radiostereometric analysis (RSA) measurements; eighteen tantalum beads were also implanted along the periphery of each polyethylene liner [Table 2] (23). Baad-Hansen et al. performed radiostereometric examinations within the first week after surgery and at 3, 12, and

24 months after surgery (22). Both groups showed a small magnitude of translation in all 3 directions at 2 years, without any statistical significance. Significant differences were observed for rotation, between groups along the transverse axis [mean -0.01 (95% CI: -0.11 to 0.12)] for Monoblock and [-0.60 (-0.72 to -0.48)] for Trilogy ($P=0.04$). Ayers et al. (23) used the method of intraoperative marker implantation validated in a prior study in regards to adverse events of tantalum markers and calculated the median proximal translation for both the titanium acetabular cups and the tantalum acetabular cups at six months and yearly thereafter through the five-year follow-up (26, 27). They found insignificant difference between the two cups ($P>0.19$); however, the median translation for the tantalum mesh cups was greater at all-time points except at the three-year follow-up. Ayers et al. reported 2 outliers in the titanium cup group where there was over 2 mm of proximal migration at the 5 year follow-up; both patients did not have any clinical symptoms or limitations nor did they have any evidence of osteolysis or loosening on plain radiographs (23). There were no outliers in the tantalum cup group.

Bone Mineral Density (BMD)

Baad-Hansen et al. were the only group to have measured the BMD using a Dual-energy X-ray absorptiometry DEXA with a Norland XR 36 Scanner (22). Patients were scanned shortly after the operation, and 1 and 2 years postoperatively [Table 2]. The scanner was calibrated to the manufacturer's guidelines and Illuminatus DXA version 4.2 software (Norland Corporation) was used to define the regions of interest (ROIs). ROI was created by forming 4 separate rectangles along the region of interest

on the pelvis and acetabulum according to Wilkinson et al. (28). The medial and lateral borders were created by two line projection, one along medial border of the obturator foramen, and the other along the lateral border of the femoral prosthesis at the shoulder. Region 1 (ROI 1) was defined by a rectangle with horizontal line 30 pixels superior to a horizontal line touching the top surface of the cup which defined its lower limit. Region 2 (ROI 2) extended from the top surface of the cup there to a line bisecting the centre of the cup. Region 3 (ROI 3) extends from the bisector to the lower border of the cup and region 4 (ROI 4) from there to a horizontal line 30 pixels inferior to the cup. This was done for all the scans and the BMD was calculated for all 4 ROIs [Figure 2]. The superior and the inferior line extent was taken to be 30 pixels as the following area has been shown to correspond to change in BMI around the prosthesis (28).

A decrease in BMD in all 4 ROIs was observed for both implant types. Periprosthetic bone loss observed was seen to be highest in the first year with continued but diminished loss of BMD thereafter. Acetabular bone had the highest BMD loss in ROI 1 and 2 at the 2-year follow-up regardless of cup type. The estimated group difference showed narrow confidence intervals (95% CI: -0.11 to 0.12) for tantalum Monoblock and -0.60 (95% CI: -0.72 to -0.48) for Trilogy (titanium) supporting the conclusion that there was similar bone loss with both cup types. Low BMI had a greater tendency to lose periprosthetic bone as evident by significant positive correlation between body mass index (BMI) and change in BMD loss in ROI 3 ($r = 0.6, P = 0.03$).

Radiological analysis

Radiological analysis using a standard anteroposterior (AP) and cross-table lateral hip radiographs were utilized preoperatively, six weeks postoperatively and then at regular intervals thereafter until latest follow-up by Wegrzyn et al. [Table 2] (21). They were evaluated by a single independent surgeon, not involved in patient care. The difference in hip abduction angle at 2 months, and at the latest follow-up were insignificant indicating lack of implant migration. Baseline radiograph analysis showed 11% (5/45) and 19% (8/41) initial postoperative gaps in the tantalum and titanium groups with a P value of 0.206 thus lacking significance. Additionally, evidence of gap filling was seen for both groups at latest follow-up. 4% (2/45) porous tantalum monoblock cups and 33% (13/40) porous-coated titanium monoblock cups presented with radiolucent lines ($P<0.001$) and no major polyethylene wear was seen in any group at latest follow-up.

Clinical outcomes

Wegrzyn et al. reported significant improvement of the Harris Hip Score at two months and at latest follow-up in both tantalum and the titanium groups (21). However, there was no significant difference detected between the two groups at two months and at latest follow-up ($P=0.454$ and 0.104 , respectively). Baad-Hansen et al. also looked at the Harris hip score and found a similar increase in both groups at the 3-month follow-up, from




Figure 2. Four regions of interest for DEXA measurements, "the Wilkinson regions".

50 (28–70) to 92 (76–100) in the Monoblock (tantalum) group and from 48 (34–64) to 95 (77–100) in the Trilogy (titanium) group [Table 2] (22).

Ayers et al. also reported improvement in Harris Hip Score, patient activity measured by the UCLA activity score, patient pain and physical function (SF-36 PCS) scores at one year following surgery which remained elevated through the five-year follow-up in both the titanium and tantalum cohort (23). However SF-36 MCS score which measures patient's emotional health, did not change significantly throughout the five-year follow-up ($P>0.05$) in either of the group. A significant improvement in WOMAC scores was observed in both groups ($P<0.05$) and remained low through the five-year follow-up. No significant differences in these scores were observed between the titanium and the tantalum group [Table 2].

Revision

Wegrzyn et al. reported two revisions in his series, one from each of the cohort. In the tantalum group one patient underwent liner exchange for repeated instability/subluxation at 117 months and in the titanium group one patient underwent acetabular cup revision at 144 months for aseptic loosening (21).

Baad-hansen et al. reported one patient in their series to undergo revision in the titanium group on the account of use of smaller femoral implants that resulted in subsidence (23). Matharu et al. reported significantly lower cause of revision for all causes in the tantalum group as compared to the non-tantalum (non-TM) group [Table 2] (26). The 5-year cumulative acetabular component survival rate following primary THA was 99.0% (95% CI 98.7-99.2) in the Tantalum group compared with 98.2% (95% CI 97.8-98.5) in the non-TM group (SHR 0.57, 95% CI 0.43-0.76, $P<0.001$). The revision rate of infection in this series was found to be significantly lower than the non-TM group with a 99.5% (95% CI 99.3-99.7) implant survival rate at 5 years in the TM group compared with 99.1% (95% CI 98.8- 99.3) in the non-TM group (SHR 0.51, 95% CI 0.34-0.76, $P=<0.001$). One the other hand Laaksonen et al. (25) found the tantalum group to have 1.5 times the revision rate (CI 1.4–1.7, $P=< 0.001$) compared to the uncemented non tantalum group in 93,709 hips analyzed across the Swedish Hip Arthroplasty Register (SHAR) and the Australian Orthopaedic Association National Joint Replacement Registry (AOANJRR). The rate of revision due infection in this series was found to be higher in the TM group although this was not statistically significant (HR = 1.2, CI 1.0--1.6, $P = 0.09$)

Discussion

The objective of this review was to broadly illustrate the clinical and radiological differences of overall stability with the use of titanium and tantalum acetabular cups, based on the highest quality evidence available. This was performed on the theoretical advantage that tantalum provided over titanium; specifically designed to reduce polyethylene wear, acetabular osteolysis and overall cup survivorship (17). The results demonstrated that while tantalum shows promising long-term results, there is little advantage in using tantalum over titanium in short-

to mid-term follow-ups (21, 23-25). Additional evidence through means published RCTs would be required to illustrate with certainty the advantageous effects of long term usage of tantalum acetabular cups in primary THA. As it stands, there appears to be clinical equivalence between the use of tantalum and titanium acetabular cups.

This is the first published study to review current literature and summarise the differences in tantalum versus titanium acetabular cups for use in primary hip arthroplasty. However, there are several published systematic reviews illustrating the difference between the porous materials when used in revision hip arthroplasty; Banerjee et al. reported that there were excellent results in highly porous materials such as tantalum in terms of aseptic loosening and major or minor periacetabular bone loss in revision hip arthroplasty, but also note that additional data is required to justify the potential advantages associated with tantalum acetabular cups (12).

Wegrzyn et al. showed some limitations in their study. The main limitation of this study was the use of plain radiographs to assess osteolysis (21). There was a loss to follow up in 12.5% in the Tantalum Monoblock group and 16.4% in the control group at 10 years. There was also technical variation between 2 surgeons could have led to variability in outcome; the use of different components and types of fixations on the femoral side were not evaluated. Wegrzyn et al. did manage to confirm excellent long-term clinic-radiological results that could be expected with a porous tantalum monoblock cup (21).

Baad-Hansen et al. also found promising results both clinically and with regard to fixation of trabecular metal components to the acetabular host bone, but the study is limited to a 2-year follow up (22). They acknowledged that longer observation periods are necessary to evaluate the long-term migration pattern and clinical outcome for this specific implant.

Ayers et al. (23) at the time of publication had only one radiostereometric analysis study (23) to compare migration in patients randomized to receive either titanium cups or trabecular metal cups and found no significant difference. They concluded that in their young population who had undergone total hip replacement, it was rather the use of type of liner rather than the type of acetabular cup that may have bearing on the future revision surgery as they found significant difference in femoral head penetration due to the type of liner used (Ultra-high molecular weight VS high molecular weight polyethylene liners), however no significant difference in migration of the of the type of acetabular cups.

With regards to the failure rates, studies have favored the use of tantalum cups in both primary and revision THAs primarily due its attractive properties such as high porosity, high frictional coefficient and similar modulus of elasticity with the bone. Both Matharu et al. and Toraski et al. observed reduced failure rate for all causes in tantalum acetabular cups as compared to non-tantalum cups in primary THA and revision THA respectively, however cautioned that regular follow up should be done in patients receiving tantalum cup to detect aseptic loosening as it generally occurs in long term (26, 29).

Infection rate has also been reported to be significantly

low in THA with tantalum cups by Matharu et al. and Toraski et al. due to its property of higher osteointegration with subsequent decrease in the dead space and its three dimensional structure creating a hostile environment for organism colonization (26, 29). However, Laakonsen et al. found a higher rate of revision both for infective and non-infective causes in the tantalum group; however this study is limited by the observation that they used these cups in complex primary THAs which can itself act as risk factor (25).

Our evaluation has been able to demonstrate tantalum may be superior to titanium in some regards; there are significantly fewer radiolucencies, 100% survivorship at 12 years post-operatively, improved long-term implant osteointegration and survivorship as well as decreasing osteolysis and mechanical loosening (21). However, there has been no significant difference in radioisometric analysis, Bone Mineral Density or Harris Hip Score (22-26). Therefore the use of tantalum should be reserved for cases of high risk of failure or mechanical loosening.

Limitation

Given the limited number of resources currently available and published to the public, there was a very small number of RCTs that correlated with the pre-determined inclusion criteria and may pose a risk to

selection bias. In addition, one of the included papers written by Baad-Hansen et al. et al, was a RCT with a relatively short follow-up of only two years (26). This short follow-up may also risk introducing bias, and as such longer follow-ups are always preferred in terms of the quality of the RCT. The conclusions drawn were only pooled from the three level 1 RCTs, found during the initial search strategy, which resulted in review only 217 hips from this study. As such, not only are more RCTs needed to form a conclusive response, but also ones that are designed to have a longer follow-up period.

Rohit Rambani MBBS MRCS (Eng) MS (Orthopaedics)
FIMSA FRCS (Tr & Orth)¹
Mayur Nayak MBBS MRCSEd MS (Orthopaedics)¹
Miss Sheweidin Aziz MBBS MRCS (Eng)²
Krishan Almeida MBChB²
1 Department of Orthopaedics, Pilgrim Hospital, Boston, United Lincolnshire NHS trust, Lincolnshire, UK
2 University Hospitals Leicester NHS Trusts, Leicester Royal Infirmary, Infirmary Square, Leicester, LE1 5WW

References

- Liang MH, Cullen KE, Larson MG, Thompson MS, Schwartz JA, Fossel AH, et al. Cost-effectiveness of total joint arthroplasty in osteoarthritis. *Arthritis Rheum.* 1986 Aug;29(8):937-43.
- Jonsson B, Larsson SE. Functional improvement and costs of hip and knee arthroplasty in destructive rheumatoid arthritis. *Scand J Rheumatol.* 1991;20(5):351-7.
- Kurtz S, Ong K, Lau E, Mowat F, Halpern M. Projections of primary and revision hip and knee arthroplasty in the United States from 2005 to 2030. *J Bone Joint Surg Am.* 2007 Apr;89(4):780-5.
- Della Valle CJ, Mesko NW, Quigley L, Rosenberg AG, Jacobs JJ, Galante JO. Primary total hip arthroplasty with a porous-coated acetabular component. A concise follow-up, at a minimum of twenty years, of previous reports. *J Bone Joint Surg Am.* 2009 May;91(5):1130-5.
- Engh CA, Hopper RH, Engh CA. Long-term porous-coated cup survivorship using spikes, screws, and press-fitting for initial fixation. *J Arthroplasty.* 2004 Oct;19(7 Suppl 2):54-60.
- Udomkiat P, Dorr LD, Wan Z. Cementless hemispherical porous-coated sockets implanted with press-fit technique without screws: average ten-year follow-up. *J Bone Joint Surg Am.* 2002 Jul;84(7):1195-200.
- Eskelinen A, Remes V, Helenius I, Pulkkinen P, Nevalainen J, Paavolainen P. Uncemented total hip arthroplasty for primary osteoarthritis in young patients: a mid-to long-term follow-up study from the Finnish Arthroplasty Register. *Acta Orthop.* 2006 Feb;77(1):57-70.
- Utting MR, Raghuvanshi M, Amirfeyz R, Blom AW, Learmonth ID, Bannister GC. The Harris-Galante porous-coated, hemispherical, polyethylene-lined acetabular component in patients under 50 years of age: a 12- to 16-year review. *J Bone Joint Surg Br.* 2008 Nov;90(11):1422-7.
- Bobynd JD, Toh KK, Hacking SA, Tanzer M, Krygier JJ. Tissue response to porous tantalum acetabular cups: a canine model. *J Arthroplasty.* 1999 Apr;14(3):347-54.
- Bobynd JD, Stackpool GJ, Hacking SA, Tanzer M, Krygier JJ. Characteristics of bone ingrowth and interface mechanics of a new porous tantalum biomaterial. *J Bone Joint Surg Br.* 1999 Sep;81(5):907-14.
- Nakashima Y, Mashima N, Imai H, Mitsugi N, Taki N, Mochida Y, et al. Clinical and radiographic evaluation of total hip arthroplasties using porous tantalum modular acetabular components: 5-year follow-up of clinical trial. *Mod Rheumatol.* 2013 Jan;23(1):112-8.
- Komarasamy B, Vadivelu R, Bruce A, Kershaw C, Davison J. Clinical and radiological outcome following total hip arthroplasty with an uncemented trabecular metal monoblock acetabular cup. *Acta Orthop Belg.* 2006 Jun;72(3):320-5.
- Mulier M, Rys B, Moke L. Hedrocel trabecular metal

- monoblock acetabular cups: mid-term results. *Acta Orthop Belg.* 2006 Jun;72(3):326-31.
14. Macheras G, Kateros K, Kostakos A, Koutsostathis S, Danomaras D, Papagelopoulos PJ. Eight- to ten-year clinical and radiographic outcome of a porous tantalum monoblock acetabular component. *J Arthroplasty.* 2009 Aug;24(5):705-9.
 15. Banerjee S, Issa K, Kapadia BH, Pivec R, Khanuja HS, Mont MA. Systematic review on outcomes of acetabular revisions with highly-porous metals. *Int Orthop.* 2014 Apr;38(4):689-702.
 16. Bobyn JD, Poggie RA, Krygier JJ, Lewallen DG, Hanssen AD, Lewis RJ, et al. Clinical validation of a structural porous tantalum biomaterial for adult reconstruction. *J Bone Joint Surg Am.* 2004;86-A Suppl 2:123-9.
 17. Kamada T, Mashima N, Nakashima Y, Imai H, Takeba J, Miura H. Mid-term clinical and radiographic outcomes of porous tantalum modular acetabular components for hip dysplasia. *J Arthroplasty.* 2015 Apr;30(4):607-10.
 18. Harris WH, White RE. Socket fixation using a metal-backed acetabular component for total hip replacement. A minimum five-year follow-up. *J Bone Joint Surg Am.* 1982 Jun;64(5):745-8.
 19. Harris WH, Penenberg BL. Further follow-up on socket fixation using a metal-backed acetabular component for total hip replacement. A minimum ten-year follow-up study. *J Bone Joint Surg Am.* 1987 Oct;69(8):1140-3.
 20. Shirazi-Adl A, Dammak M, Paiement G. Experimental determination of friction characteristics at the trabecular bone/porous-coated metal interface in cementless implants. *J Biomed Mater Res.* 1993 Feb;27(2):167-75.
 21. Wegrzyn J, Kaufman KR, Hanssen AD, Lewallen DG. Performance of Porous Tantalum vs. Titanium Cup in Total Hip Arthroplasty: Randomized Trial with Minimum 10-Year Follow-Up. *J Arthroplasty.* 2015 Jun;30(6):1008-13.
 22. Baad-Hansen T, Kold S, Nielsen PT, Laursen MB, Christensen PH, Soballe K. Comparison of trabecular metal cups and titanium fiber-mesh cups in primary hip arthroplasty: a randomized RSA and bone mineral densitometry study of 50 hips. *Acta Orthop.* 2011 Apr;82(2):155-60.
 23. Ayers DC, Greene M, Snyder B, Aubin M, Drew J, Bragdon C. Radiostereometric analysis study of tantalum compared with titanium acetabular cups and highly cross-linked compared with conventional liners in young patients undergoing total hip replacement. *J Bone Joint Surg Am.* 2015 Apr 15;97(8):627-34.
 24. Meneghini RM, Ford KS, McCollough CH, Hanssen AD, Lewallen DG. Bone remodeling around porous metal cementless acetabular components. *J Arthroplasty.* 2010 Aug;25(5):741-7.
 25. Laaksonen I, Lorimer M, Gromov K, Eskelinen A, Rolfson O, Graves SE, et al. Trabecular metal acetabular components in primary total hip arthroplasty. *Acta Orthop.* 2018 Jun;89(3):259-64.
 26. Matharu GS, Judge A, Pandit HG, Murray DW. Which factors influence the rate of failure following metal-on-metal hip arthroplasty revision surgery performed for adverse reactions to metal debris? an analysis from the National Joint Registry for England and Wales. *Bone Jt J.* 2017 Aug;99-B(8):1020-7.
 27. Poggie RA, Brown TD, Pedersen DR. Finite elements analysis of peri-acetabular stress of cemented, metal-backed, and porous tantalum backed acetabular components. *Trans Orthop Res Soc.* 1999; 24:747
 28. Wilkinson JM, Peel NF, Elson RA, Stockley I, Eastell R. Measuring bone mineral density of the pelvis and proximal femur after total hip arthroplasty. *J Bone Joint Surg Br.* 2001 Mar;83(2):283-8.
 29. Tokarski AT, Novack TA, Parvizi J. Is tantalum protective against infection in revision total hip arthroplasty? *Bone Jt J.* 2015 Jan;97-B(1):45-9.