

CASE REPORT

Cubitus Varus Corrective Osteotomy and Graft Fashioning Using Computer Simulated Bone Reconstruction and 3D Printed Custom-Made Cutting Guides

Ashkan Sedigh, MS^{1,2}; Mohammad Zohoori, BS¹; Mohammad Ebrahimzadeh, MD¹; Amir Kachooei, MD PhD^{1,2}

Research performed at Orthopedic Research Center, Mashhad University of Medical Sciences, Mashhad, Iran

Received: 29 September 2020

Accepted: 04 November 2020

Abstract

Preoperative planning is of paramount importance in saving time as well as helping achieve a more precise correction of the deformities. Along with preoperative measurements, customized cutting guides can facilitate intraoperative correction of the deformity with higher confidence. In this report, we are presenting the application of preoperative planning and 3D printed customized cutting guides for correcting cubitus varus alignment of the elbow in an 18 year old male with satisfactory intraoperative and postoperative results.

Level of evidence: IV

Keywords: 3D-printing, Computer-aided-design, Cubitus varus, Elbow, Osteotomy, Pre-operative planning

Introduction

3D-printing technology is an emerging field in the healthcare industry. In this process, extruded material is printed layer over layer to make the 3D model. The 3D model is designed and converts to G-code which translates into the 3D-printing machine. This technology has wide application in orthopedic clinical use as orthoses, patient-specific osteotomy instrument, orthopedic implant, and tissue engineering (1).

With the help of computer simulation, design tools, computational algorithms, and imaging techniques as Computed Tomography (CT) scans, 3D models of various tissues can be simulated, reconstructed, and 3D printed. This technology has also different applications in dental surgery, maxillofacial reconstruction, cranioplasty, and vascular surgery (2, 3).

Preoperative planning is one of the significant method in managing orthopedic surgery. In this report, we used both virtual preoperative planning and 3D-printing

technology in understanding the osteotomy and planning out a strategy. This technique can be helpful both in increasing the efficiency and reducing the surgical morbidity.

Case presentation

An 18-year-old man was referred with left elbow cubitus varus following a supracondylar fracture in childhood [Figure 1]. He also had mild lateral elbow pain but no sign or symptom of ulnar nerve palsy was present. The visual analogue score of pain at rest was 0 and with activity was 3 out of 10 which was mostly fatigue rather than pain. Clinical carrying angle was 35 degree of varus. Elbow range of motion was 0-135 degrees and comparable to the other side. In order to be precise in varus correction, we decided to use the preoperative planning using the computer-based software. We applied the computed tomographic (CT) cuts of both normal and the affected

Corresponding Author: Amir Kachooei, Orthopedic Research Center, Mashhad University of Medical Sciences, Mashhad, Iran
Email: ARKachooei@gmail.com



THE ONLINE VERSION OF THIS ARTICLE
ABJS.MUMS.AC.IR

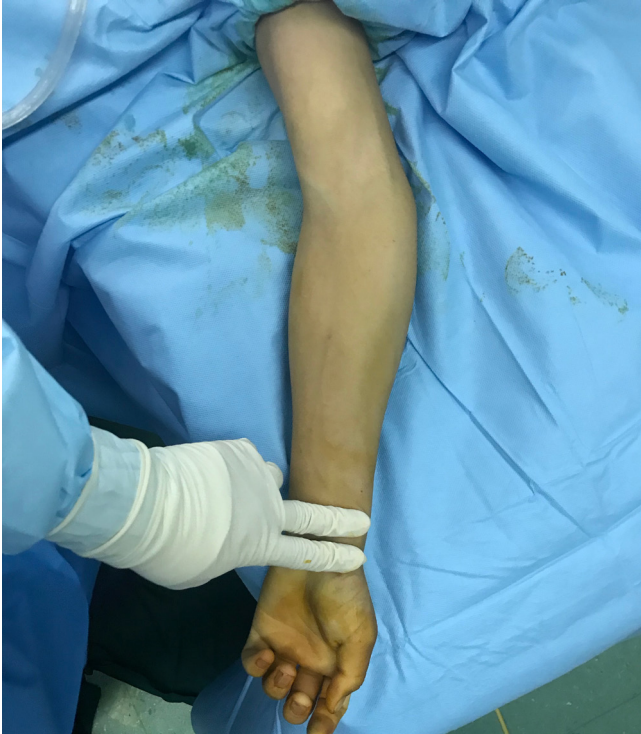

Figure 1. Preoperative cubitus varus deformity with varus alignment of the carrying angle is noted with elbow extension.

elbow to reconstruct the elbow joint.

Materials and Methods

In this case, the 3D model of the bone is generated by the CT scan raw data. This toolkit which is used by an open-source software (Fiji) helped orthopedic surgeons to make a 3D model of the scan data within the required Hounsfield unit. This threshold separates the compact and spongy bone in the CT-scan data. In this study, which is implemented by 3D point cloud registration algorithm; we aimed to correct the deformed humerus patient bone.

3D models of both humerus bones in the left and right upper extremities is post-processed in order to drive smooth and solid objects for the further measurement and processing. The following steps are done to produce the cutting guides with the use of 3D printing. DICOM images were imported in the Mimics™ (Materialise, Belgium) software. The desired 3D model was segmented and edited with the “edit mask” command. The segmented 3D model was exported as STL file and imported into the 3-matics™ (Materialise, Belgium) software to design the jigs. Both deformed and healthy upper extremity STL files aligned together in the proximal part [Figure 2a].

Based on this modeling, 40 degrees of angulation was measured and a wedge of the same degrees was designed to be cut and move. Given that, we designed a cutting jig to guide for the wedge to be cut [Figure 3 a-b]. This has been performed with designing a base on the cutting surface. During surgery, the wedge was cut (Pink Part in [Figure 3a]) and placed over the lateral border of the distal

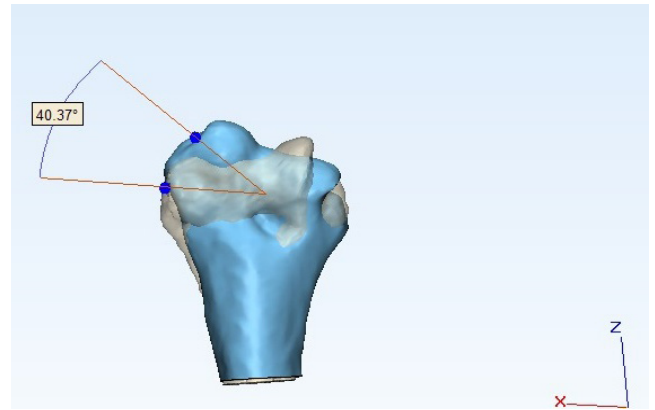


Figure 2. Overlapping the healthy and the affected humerus shows a 40.37 degrees varus deformity of the distal humerus in the coronal plane.

humerus fragment to create the distal segment [Figure 4]. In order to locate the wedge precisely, the pink part was rotated in two planes. The center of rotation was the point between two legs of the cutting triangle [Figure 3a]. By rotating the bone wedge, the grey part was slipped along the wedge as the lower edge meets the yellow distal bone to maintain a solid bone with corrected angle [Figure 4]. By reducing the distal segment to the proximal humerus, the 40 degrees deformity was corrected and alignment was achieved precisely [Figure 5 a-d]. Because there was a negligible deformity in the sagittal plane, we made cuts perpendicular to the shaft. The goal after rotating the wedge was complete contact of bone surfaces. Range of motion was tested after provisional fixation to make sure the reduction is in appropriate position. There was no appreciable anterior tilt of the distal fragment at surgery, however, due to the difference in bone diameters in the new set-up of the fragments, there is a seemingly anterior tilt of the distal fragment in the sagittal plane. Moreover, the surface area of the wedge is triangular with the posterior base and

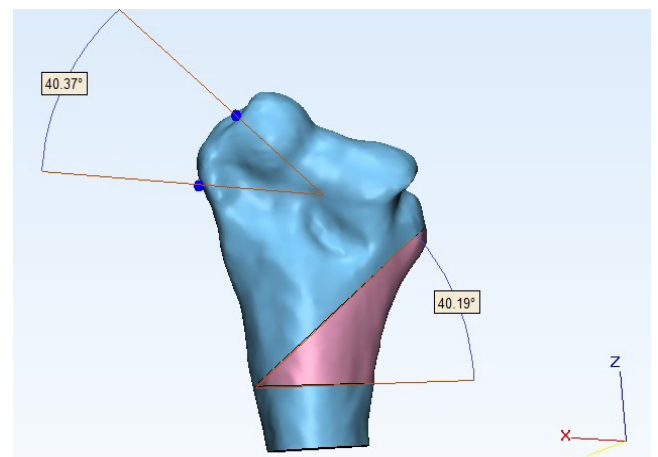


Figure 3a. The planned wedge osteotomy in the metaphysis is equal to the degree of deformity.

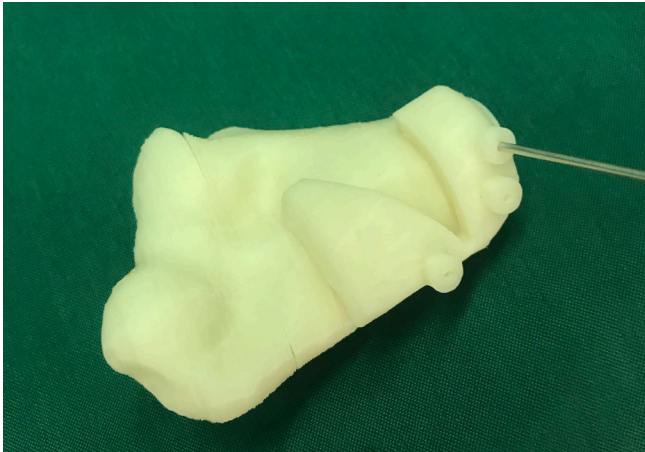


Figure 3b. The cutting guide is designed and testes on a printed model.

anterior angle which contributes to the appearance of anterior tilting of the distal fragment after 180 rotation of the wedge to be aligned with the anterior cortex of the distal fragment.

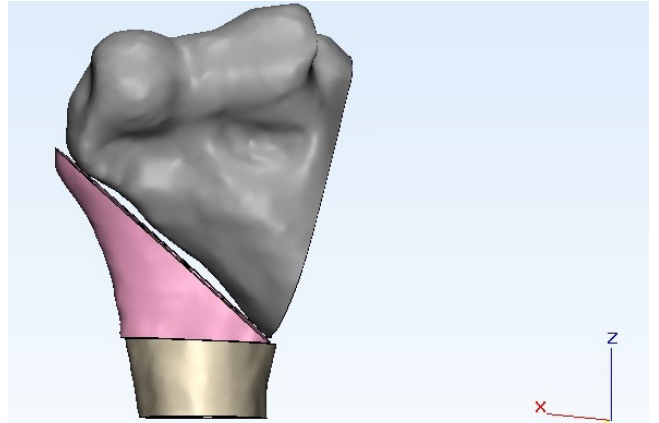


Figure 4. The wedge is flipped 180 degrees in the coronal plane. The medial border of the wedge is aligned with the lateral border of the humerus shaft. Therefore the distal humerus is titled to valgus which is equal to the degree of the deformity.

Results

Patient was followed up for 4 months. A complete bone healing was evident at the last visit on the final radiographs [Figure 6 a-b]. Range of motion was 0-135

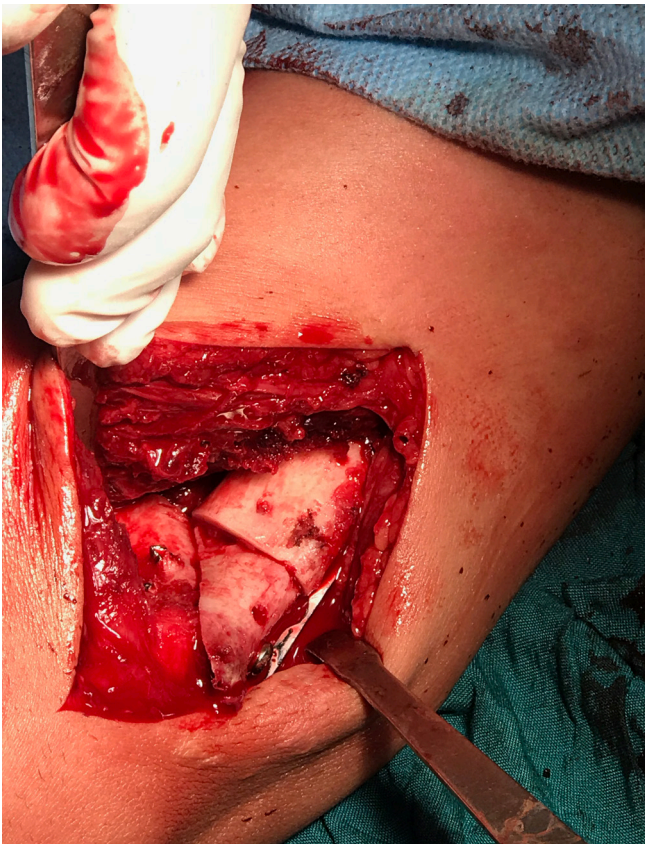

Figure 5a. Intraoperative view of the osteotomy after the wedge is rotated 180 degrees.

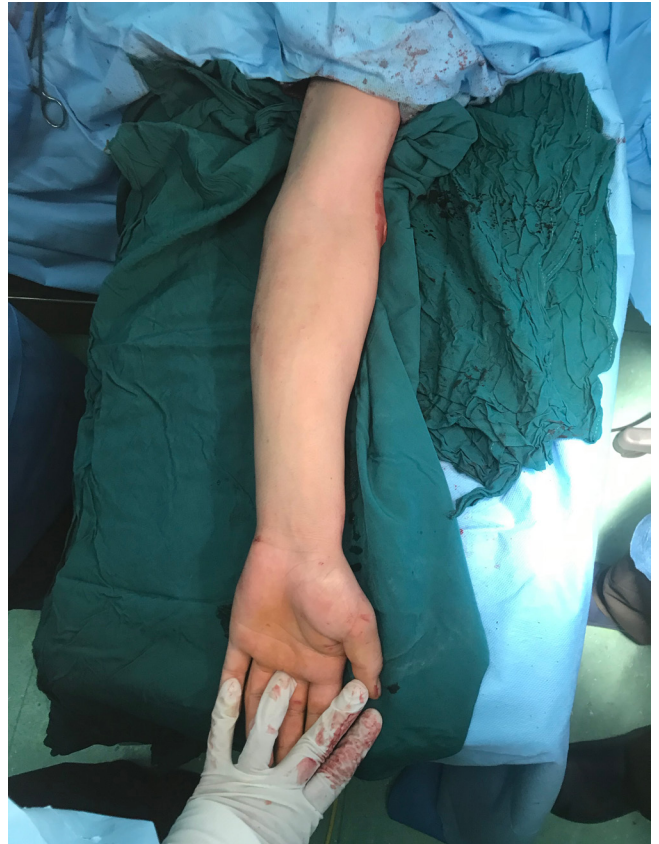

Figure 5b. Normal elbow carrying angle after the corrective osteotomy.

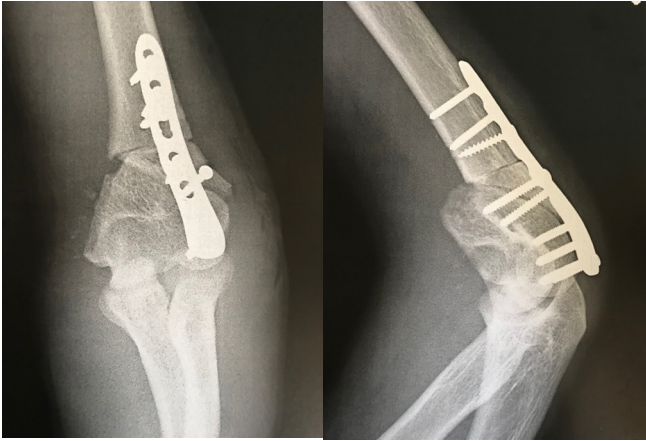


Figure 5 c,d. Elbow anteroposterior (5c) and lateral (5d) view showing corrected ulnohumeral angle

degrees of extension to flexion, 85 degrees of pronation and 80 degrees of supination which was comparable to preoperative motion and the contralateral side [Figure 7 a-d]. Force of flexion and extension was 5 out of 5 eliciting no pain with resisted motion. Visual analogue scale (VAS) with activity was 2 and at rest was 0 out of 10. Clinical carrying angle was 5 degrees of valgus. He did not develop any sign or symptoms of injury or entrapment of ulnar, radial or median nerve. The patient was completely satisfied with the outcome of surgery.

Discussion

Preoperative planning is one of the significant methods in managing orthopedic surgeries. In this report, we used both virtual preoperative planning and 3D-printing technology in lieu of planning the cuts prior to the actual surgery.

There are some reports using custom-made cutting

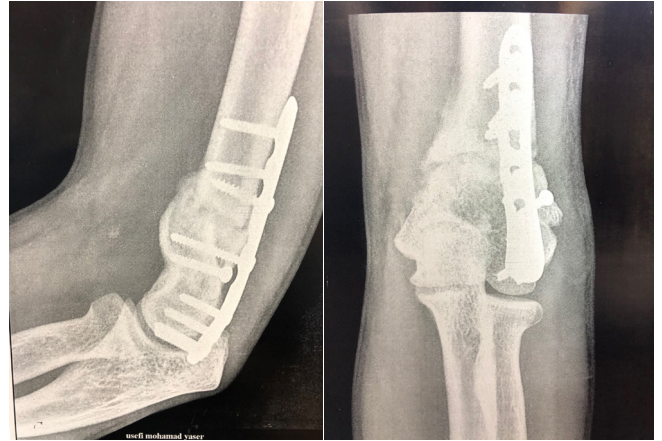
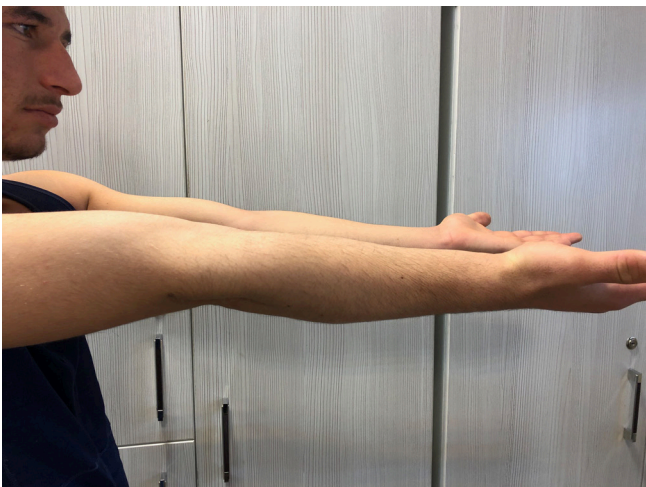

Figure 6 a,b. Follow-up anteroposterior (6a) and lateral (6b) radiographic views four months after corrective osteotomy showing progressive healing with maintained alignment.

guides to correct a cubitus varus with different surgical techniques. Murase et al. used this technique to make custom-made guides for close wedge osteotomy of a cubitus varus deformity in 6 steps. This included creating computer bone models from CT data, evaluating the



Figure 7a, b. Follow-up after four months shows full range of motion almost equal to the healthy side in extension (7a), flexion (7b).



Figure 7c. supination.



Figure 7d. pronation.

3-D deformity, planning the 3-D corrective osteotomy, operative set up, performing the 3-D osteotomy using the custom-made surgical guides, and postoperative care (4).

In another study, 13 children with cubitus varus underwent preoperative planning using computer simulation. Out of 13, 10 had excellent, 2 had good and 1 had fair results with a mean carrying angle of 11 degrees at the final follow-up (5).

The application of 3D print is extending into orthopedic surgery. 3D printed casts and splints is a brand new method of immobilization that provides more comforts to the patient (6). Besides the application of preoperative planning with 3D printed cutting guides, specific customized implants are currently designed and implanted with successful outcomes. Although the drawback of this new technology is the 'time', this technology is becoming more popular as the advances are emerging.

It seems that bone reconstruction and computer simulation is a reliable method to make custom-made cutting guides for precise correction of deformities. It helps shorten the surgery time and increases the accuracy of deformity correction.

Ashkan Sedigh MS^{1,2}

Mohammad Zohoori BS¹

Mohammad Ebrahimzadeh MD¹

Amir Kachooei MD PhD^{1,2}

1 Orthopedic Research Center, Mashhad University of Medical Sciences, Mashhad, Iran

2 Rothman Institute, Thomas Jefferson University, Philadelphia, PA, USA

References

1. Cai H. Application of 3D printing in orthopedics: status quo and opportunities in China. *Annals of translational medicine*. 2015;3(Suppl 1).
2. Mishra A, Verma T, Vaish A, Vaish R, Vaishya R, Maini L. Virtual preoperative planning and 3D printing are valuable for the management of complex orthopaedic trauma. *Chinese Journal of Traumatology*. 2019;22(6):350-5.
3. Sedigh A, Tulipan JE, Rivlin MR, Tomlinson RE. Utilizing Q-Learning to Generate 3D Vascular Networks for Bioprinting Bone. *bioRxiv*. 2020.
4. Murase T, Takeyasu Y, Oka K, Kataoka T, Tanaka H, Yoshikawa H. Three-dimensional corrective osteotomy for cubitus varus deformity with use of custom-made surgical guides. *JBJS essential surgical techniques*. 2014;4(1).
5. Jiang H, Li M, Wu Y. Application of computer simulation in the treatment of traumatic cubitus varus deformity in children. *Medicine*. 2019;98(1).
6. Sedigh A, Kachooei AR, Beredjikian PK, Vaccaro AR, Rivlin M. Safety and efficacy of casting during COVID-19 pandemic: a comparison of the mechanical properties of polymers used for 3D printing to conventional materials used for the generation of orthopaedic orthoses. *Archives of Bone and Joint Surgery*. 2020;8(Suppl 1):281.