

RESEARCH ARTICLE

Presentation and Management Outcome of Glomus Tumors of the Hand

Muhammad Saaq, FCPS¹*Research performed at National Institute of Rehabilitation Medicine (NIRM), Islamabad, Pakistan**Received: 14 April 2020**Accepted: 11 September 2020***Abstract**

Background: To document the clinical presentation of glomus tumors of the hand and evaluate the outcome of complete surgical excision in terms of relief of symptoms, any postoperative nail deformities and tumor recurrence over a period of one year.

Methods: This descriptive case series spanned over a period of twelve years. All patients of either gender and all ages who had histologically confirmed glomus tumors of the hands were included. All of them underwent surgical excision under local anesthesia.

Results: Out of 17 patients, majority (n=12; 70.58%) were females. The mean age was 41.17±13.7 years. The dominant hand was involved in 11 (64.70%) patients. There were 14 patients (82.35%) with subungual tumors whereas 3(17.64%) had volar pulp glomus tumors. The mean diagnostic delay was 18.88±9.3 months. The tumor size ranged from 2 mm to 1.1cm with a mean of 4.05±4.3mm. All the patients (n=17,100%) experienced complete symptomatic relief within 2-4 weeks after surgical excision. There were no postoperative nail deformities. There was no recurrence over a period of one year.

Conclusion: Glomus tumors of the hands were more frequently found among women in their fourth and fifth decades. Dominant hand, index finger and distal phalanx represented the commonest affected anatomic locales. Majority of the tumors were subungual. Majority of the patients suffered over 12 months in distressful pain before being diagnosed. Complete surgical excision under local anesthesia provided rapid relief of the symptoms. Creation of awareness about the tumor among doctors as well as public would help to ensure early presentation to plastic surgeon, prompt diagnosis and hence avoidance of the prolonged periods of agonizing misery.

Level of evidence: III

Keywords: Glomus bodies, Glomus tumor, Hand tumors, Subungual glomus, Volar pulp glomus

Introduction

Glomus tumors are relatively rare benign tumors that originate from the glomus bodies. The glomus bodies are highly specialized neuromyoarterial structures that contain delicate network of arteriovenous anastomoses. These serve to regulate body temperature and blood pressure by controlling the cutaneous blood flow. These bodies are found in abundance in the fingertips of the hands (1-3).

Though glomus tumors can occur anywhere in the

body, their greatest majority are found in the fingers and thumbs, accounting for 1%-5% of the total hand tumors. Complete surgical excision constitutes the treatment of choice and offers complete cure. The patients typically experience complete pain relief within 2-4 weeks following surgical resection of the tumor (1-3).

The current study was undertaken to document the clinical presentation of glomus tumors of hands and evaluate the outcome of surgical excision in terms of

Corresponding Author: Muhammad Saaq, Department of Plastic Surgery, NIRM, Islamabad, Pakistan
Email: muhammadsaaq5@gmail.com



THE ONLINE VERSION OF THIS ARTICLE
ABJS.MUMS.AC.IR

relief of symptoms, any postoperative nail deformities and tumor recurrence over a period of one year.

Materials and Methods

This prospective case series study was conducted over a period of twelve years. (i.e. from January 2008 to December 2019). Informed consent was taken from the patients. The study followed the ethical protocols as outlined by the Helsinki's Declaration-2013 revision. Anonymity of the participants was ensured.

The study included all patients of either gender and all ages who presented with histologically confirmed glomus tumors of the hands. The exclusion criteria included patients who were treated surgically in other hospitals.

Initially a focused history was taken and focused clinical examination was performed to ascertain information about key variables of the characteristic pain, tenderness, cold sensitivity, any visible tumor or nail changes, Love's pin test, Hildreth's test, Cold test and trans-illumination test. At presentation, Visual Analogue Scale (VAS) was employed to score the pain subjectively by the patients, using a ten-point visual scale ranging from 0-10. High resolution Magnetic resonance imaging (HR-MRI) with intravenous gadolinium contrast was performed to radiologically confirm the lesions and anatomically locate them preoperatively.

All the patients were operated upon as day care surgery cases. Digital nerve blocks with Xylocaine were performed among all patients. Loupe magnification was routinely employed during surgery. For subungual lesions, the transungual approach was employed. The nail plate was removed in a standard fashion. For raising the nail plate, a fine artery forceps was gently advanced progressively between the nail plate and the nail bed. The eponychium was separated with sharp dissection from the proximal part of nail plate using a size 15 surgical blade. The nail was thus carefully lifted off without damaging the nail bed. In cases where the tumor was located more proximally in the nail bed, one or two 1-cm long skin incisions were made at the junction of the lateral nail folds and eponychium. An eponychial skin flap was elevated to facilitate direct visualization and excision of the

entire tumor. It was observed in five patients with small size tumors that with tourniquet in situ, the tumor was not clearly visible; however upon releasing of the tourniquet the tumor became clearly visible. In the remaining 12 patients the tumor was clearly visible even with the tourniquet in situ. A longitudinal incision was made in the nail bed directly over the tumor. The nail bed flaps were delicately elevated by sharply separating them from the tumor. The tumor was excised completely. Following tumor excision, the nail bed was meticulously repaired with 6/0 vicryl sutures. The eponychial skin flap was sutured with prolene 5/0 sutures. The nail plate was replaced to protect the nail bed and secured temporarily with prolene 4/0 suture. In case of tumors on the volar pulp, a direct incision was made through the volar pulp skin and tumor excision undertaken. The skin was closed with prolene 4/0 sutures. All the resected tumor specimens were subjected to histopathological confirmation.

Postoperatively hand elevation was advised to prevent edema and swelling. The first wound dressing was changed on 5th postoperative day. Skin stitches were removed on 10th postoperative day. The VAS score for pain was recorded postoperatively at 2 weeks and 4 weeks. All the patients were followed up for at one year postoperatively to rule out any recurrence at that point.

The demographic and clinical profile of the patients and outcomes were recorded. The variables analyzed included age, gender, duration of symptoms, involvement of dominant vs non dominant hand, digits affected, location of the tumors whether subungual or volar pulp, location with respect to phalanges, frequency of various diagnostic clinical criteria (i.e. characteristic pain, tenderness, cold sensitivity, visible tumor, nail changes, Love's pin test, Hildreth's test, Cold test and trans-illumination test) and size of the excised tumor. The outcome measures analyzed included relief of symptoms following tumor excision, any postoperative nail deformities and recurrence over a period of one year. The data were subjected to statistical analysis using SPSS version 11.

[Figures 1A] through [Figure 6A] shows some of the patients included in the study.

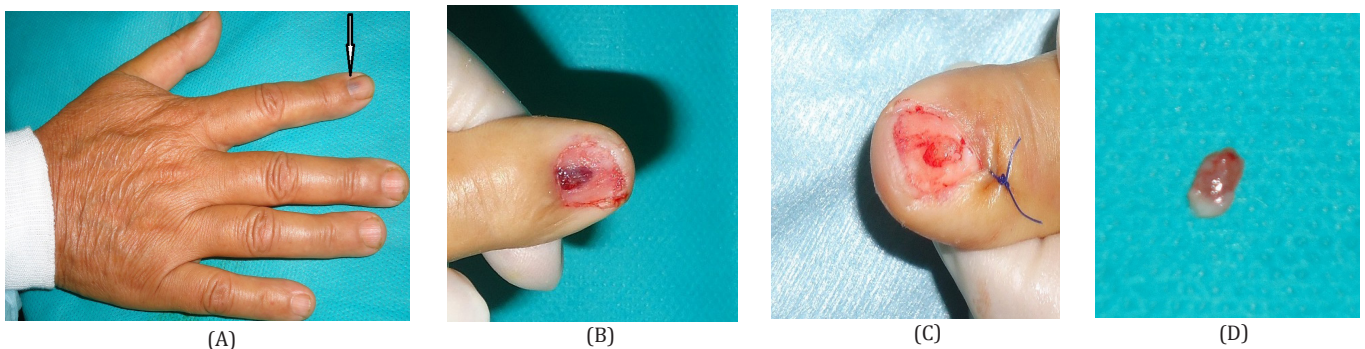


Figure 1(A-D). Glomus tumor of the right index finger in a 45-years old lady. A: Pink-purple colored tumor under the nail plate is noticeable. B: The tumor in situ, after removal of the nail plate. C: The excisional defect following excision of the tumor. D: The excised glomus tumor that measured 7 mm in its greatest dimension.

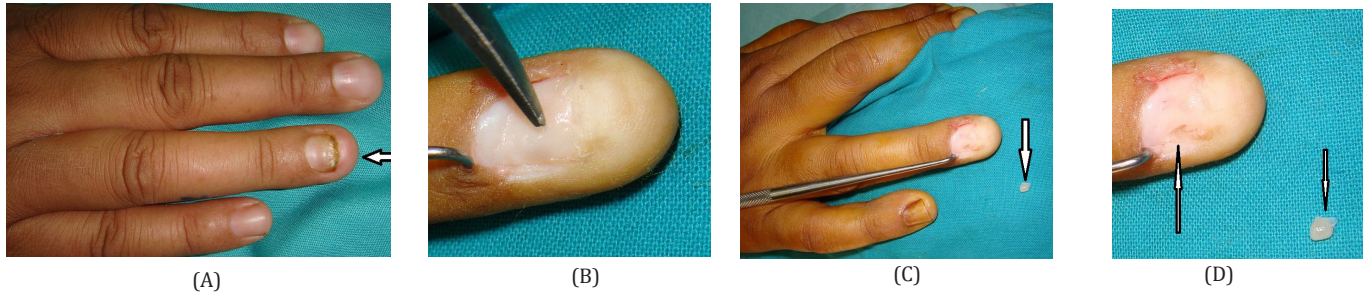


Figure 2(A-D). Glomus tumor of the right ring finger in a 39-years old lady. A: Nail plate changes are remarkable. B: Tumor site is pointed out. With the tourniquet in situ the tumor was not clearly visualized, however when the tourniquet was released, the tumor became visible. C and D: Excisional defect after tumor extirpation and the excised tumor.

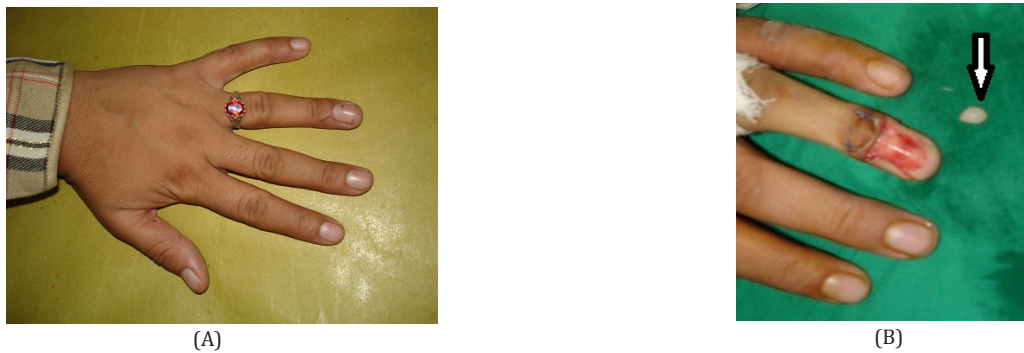


Figure 3(A-B). Glomus tumor of the left ring finger in a 36-years old lady. A: The affected finger. B: Excisional defect with the excised tumor.

Results

There were a total of 17 patients with 12 (70.58 %) females and 5 (29.41 %) males. The age ranged from 27-62 years with a mean age of 41.17 ± 13.7 years.

There was involvement of dominant hand in 11 (64.70%) patients whereas the non-dominant hand was involved among 6 (35.29%) patients. The digits affected included the index finger (n=6; 35.29%), ring finger (n=4; 23.52%), little finger (n=4; 23.52%), thumb (n=2; 11.76%) and the middle finger (n=1; 5.88%).

There were 14 patients (82.35%) with subungual glomus tumors whereas 3 (17.64%) patients had volar pulp glomus tumors. Among all patients (n=17; 100%),

tumors were found in relation to the distal phalanx.

The duration between the first time appearance of symptoms and the correct diagnosis ranged between three months to 3 years. The mean was 18.88 ± 9.3 months.

The frequency of various presenting clinical findings was as follows: Pain (n=17; 100%), tenderness (n=17; 100%), cold sensitivity (n=13; 76.47%), visible tumor (n=4; 23.52%), nail changes (n=2; 11.76%), Love's pin test (n=17; 100%), Cold sensitivity test (n=17; 100%) Hildreth's test (n=12; 70.58%), and trans-illumination test (n=9; 52.94%).

The tumor size ranged from 2 mm to 1.1cm with a mean

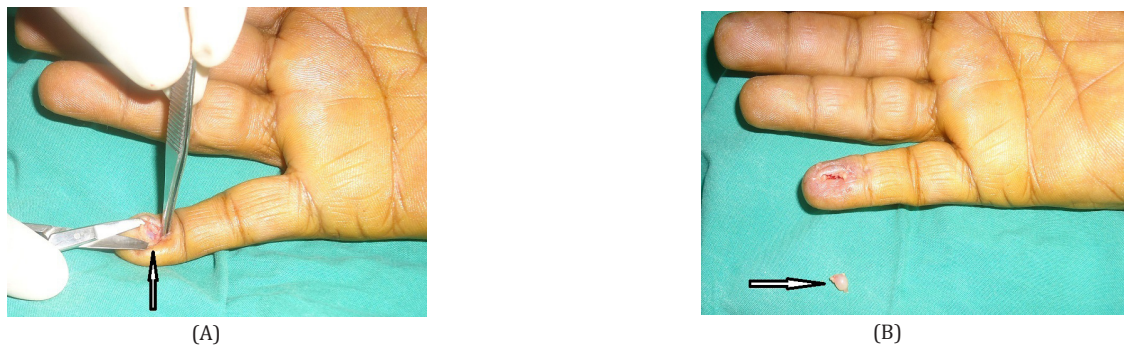


Figure 4(A-B). Glomus tumor of the right little finger in a 62-years old man. A: Tumor is visible through the skin and subcutaneous incision. B: The excised discrete tumor is shown.

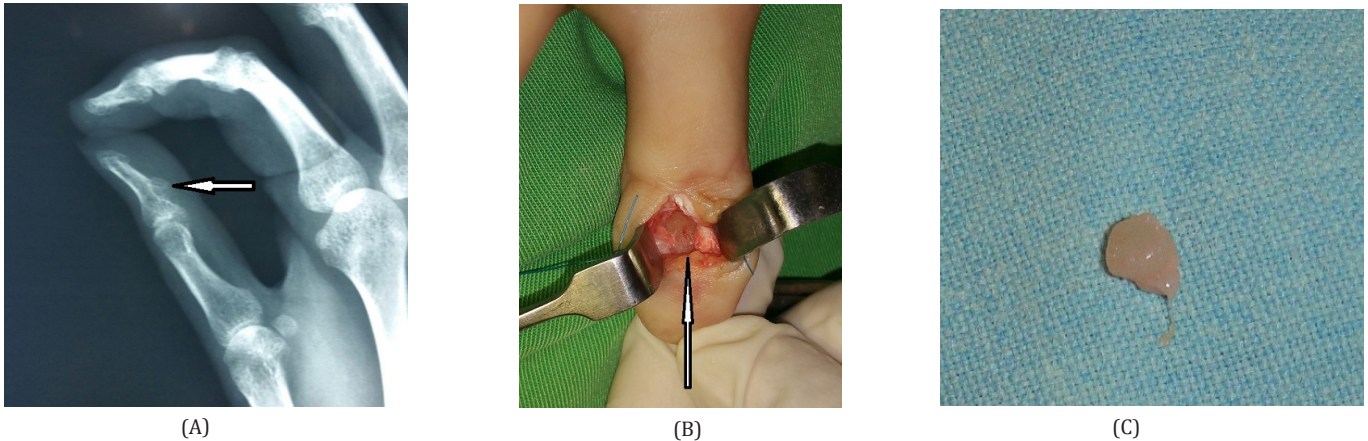


Figure 5(A-C). Glomus tumor of the left thumb in a 27-years old lady. A: The affected distal phalanx of the thumb showed scalloping defect on Plan X-rays. B: Appearance of the excisional defect after complete removal of the tumor and surface curettage of the bone. C: The excised tumor specimen.

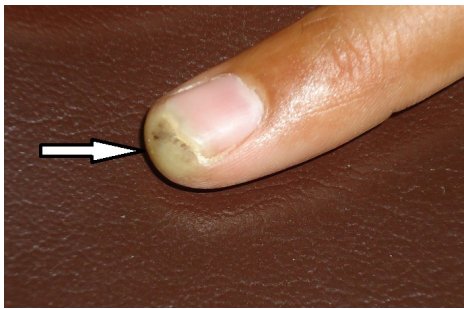


Figure 6. Glomus tumor of the tip of index finger in a 35-years old lady. There is a visible space occupying lesion under the skin along with purplish discoloration. Also elevation of the distal part of the nail plate is appreciable. The excised tumor measured 11mm in its greatest dimension.

of 4.05 ± 4.3 mm.

At presentation the mean VAS score was 9.23 ± 0.56 (range of 8-10). At 2 weeks it improved to 4.35 ± 0.86 (range of 3-5) whereas at 4 weeks it was further reduced to 0.59 ± 0.87 (range of 0-3).

All the patients ($n=17, 100\%$) experienced complete symptomatic relief within 2-4 weeks.

Among all patients ($n=14, 100\%$) with transungual approach, the new nail regrown over 12 weeks. There was no recurrence over a period of one year. There were no postoperative nail deformities.

Discussion

Glomus tumors often pose challenging diagnostic dilemma at the very outset. Not many clinicians are shrewd enough to pick up the classic clinical triad of symptoms that characterize the glomus tumor. These include intense paroxysmal pain, exquisite point tenderness and sensitivity to cold. Pain is the frequent complaint and the remaining two symptoms are found in variable proportion of patients. The tumor is often invisible and impalpable. In rare instances, one may find

a visible space occupying lesion under the nail plate, pink-purplish discoloration lesion under the nail or some noticeable deformation of the nail plate itself. Certain clinical tests are commonly employed to confirm or refute the presenting symptoms and hence establish the clinical diagnosis [Figures 1A; 2B and 6A]. These include the Love's pin test, Hildreth's test, cold sensitivity test and trans-illumination test. The Love's pin test is used to confirm the exquisite point tenderness. A pinhead is used to apply gentle localized pressure to the tender area as pointed out by the patient subjectively. This typically elicits intense tenderness. In the Hildreth's test, transient ischemia is produced at the arm's level with application of a tourniquet. With the ischemia in place, when the Love's pin test is repeated, there is absence of the tenderness of previous magnitude. Upon removal of the tourniquet, there is sharp return of the bothering pain. Cold intolerance is tested by local application of an ice cube to the affected area. The trans-illumination is elicited by shining light through the finger pad preferably in a dark room. This illuminates the lesion (1-5).

The cold sensitivity test is reported to have 100% sensitivity, specificity and diagnostic accuracy. The Love's test has 100% sensitivity and 78% diagnostic accuracy, whereas the Hildreth's test has 71.4% sensitivity, 100% specificity and 78% diagnostic accuracy. The glomus tumor which has been neglected for long periods of time may rarely present with associated nail deformities such as increased curvature or longitudinal split of the nail plate (4, 5).

In this study majority of the patients were in their fourth and fifth decades of life. All the patients were adults and none belonged to the pediatric age group. The published studies have variably reported on the age of affliction among patients with glomus tumors. Santoshi JA et al from India reported 38 years as the mean age at presentation with a range of 16-55 years. Montandon C et al from Brazil reported a mean age of 39 years with a range between 26-51 years. Ham KW et al from Korea observed a mean age of 48.4 years with a range between

36-78 years. Fazwi R et al from Malaysia found a mean age of 49.6 years with a range of 17-74 years. Bargon GA et al reported the mean age of 49 years with a range of 20-86 years. Pandey CR et al from Nepal observed a mean age of 36.66 with a range of 22-53 years. Mravic M et al from the US reported majority of their patients in the fourth to seventh decades of life. In the published literature cases of glomus tumors among children have been reported and unlike adult subjects, these tend to be more commonly multiple rather than solitary (6-12).

In this study females outnumbered the male patients. Several published papers conform to our observation. Santoshi JA et al reported 21 females versus 16 males. Ham KW et al had 17 females and 4 males in their study. Mravic M et al had 9 females and 6 males. Mravic M et al found 64% females and 36% males in their study. Montandon C et al reported a male to female ratio of 7:1, whereas Fujioka H et al reported 2 males and 2 females. Bargon GA et al in their series of 87 patients reported almost equal affliction of either gender with 45 males while 42 were females (6, 7, 9, 10, 12, 13).

In this series more frequent involvement of the dominant hand was observed. Jawalkar H et al also reported similar observation with involvement of right hand among 7 patients and left hand in 5. Santoshi JA et al had 21 patients with left-hand involvement whereas 16 with right hand (6, 14).

In this study index fingers were found to be the most commonly affected fingers. Most of the published studies conform to this observation. Montandon C et al observed involvement of the index finger in 3 cases, middle finger in 2, little finger in 2 and thumb in one case. Jawalkar H et al reported index finger as the most common digit involved in 5 patients, followed by the middle finger and the thumb 3 each and the ring finger in one case. Santoshi JA et al reported ring finger among 14 cases, thumb in 8, index, middle and little fingers each 5 cases (6, 7, 14).

In this study all the glomus tumors were found in relation to the distal phalanx. Our observation conforms to several published studies where distal phalanx has been identified as the most common site for development of glomus tumor. Lee W et al in their series of 15 cases of glomus tumors, observed 11 tumors located in the nail bed, 3 in the volar pulp and 1 in the radial aspect of the fingertip (15, 16).

In this study 14 patients had subungual whereas 3 had pulp glomus tumors. Published studies have reported similar tumor distribution. 10% or fewer glomus tumors are found in the volar pulp of digits (17-21).

In this study all the study subjects had solitary glomus tumors. According to the published studies, the solitary variant is mostly found in the hand. Multiple glomus tumors occur at a rate of 10% and may be encountered in other body parts. Very rarely these may occur as familial disease in an autosomal dominant fashion. The multiple glomus tumors are usually painless (12, 16, 22-25).

In this study the mean tumor was 4.05 mm. Mravic M et al reported the median size of tumors as 6 mm (range of 0.2-5.6 cm). Lee W et al reported 3-9 mm size range. Santoshi JA et al observed the mean size of lesion as 3.8 mm (range 2 to 10 mm) (6, 12, 16).

In this study the mean duration of symptoms before establishing the correct diagnosis was 18 months. The published literature has reported variable durations in this regard. Santoshi JA et al reported 3.8 years (range 2-12 years) as the mean duration of symptoms before presentation. Ham KW et al reported 18 months (ranging 4 to 52 months) as the mean duration. Jawalkar H et al found that the mean duration of symptoms before diagnosis was 3.25 years (range 1-9 years). Pandey CR et al from Nepal found that the mean duration of symptoms before presentation and diagnosis was 15.5 ± 21.80 months (range: 3-72 months). Song M et al reported 4.6 years (range 1 month to 20 years) as the mean duration of symptoms until diagnosis. Muramatsu K et al reported this period as 4.5 years (range, 6 months to 10 years). Bargon GA et al reported an average 3.3 to 5 years. Bargon GA et al observed that an average of 2.5 physicians (range: 0-7) evaluate a patient before the definitive diagnosis of a glomus tumor is confirmed (6,8,10,11,14 26, 27).

The glomus tumor may present a diagnostic dilemma and take years with multiple consultations and investigations before an appropriate diagnosis is made. Early recognition and prompt diagnosis of glomus tumors is extremely important, as the diagnostic delay may lead to the exacerbation of the patient's symptoms, secondary nail changes and prolongation of the patient's misery. The diagnostic delay may result from a number of reasons. For instance, the severe pain may be mistaken for other causes such as neuromuscular pain or even chronic regional pain syndrome (CRPS). These tumors are often small, deep seated and usually impalpable and hence more difficult to diagnose (1-3, 28).

In this study High resolution Magnetic resonance imaging (HR-MRI) with intravenous gadolinium contrast was employed in the preoperative evaluation of the patients. It is currently considered the gold standard diagnostic investigation. It is non-invasive and doesn't involve any exposure to radiation. It can detect early lesions as small as 2 mm. The MRI scan not only detects the symptomatic tumor under scrutiny but also helps to delineate if there are multiple asymptomatic glomus tumors. It also helps to rule out other possible differential diagnoses. Both T1 and T2 images with axial and coronal views are acquired. Characteristically there is low-signal intensity on T1-weighted images whereas marked hyperintensity on T2-weighted images (4, 13, 15, 29).

Except for the cases of volar pulp tumors, a transungual approach was employed for the subungual lesions in the current study. With removal of the nail plate, ideal exposure is obtained. Tumor excision is undertaken in a meticulous manner. Replacing the nail plate in its original position has been suggested to prevent nail deformities. Cosmetically unsatisfying results occur if the nail bed is severely damaged while removing the tumors or the nail bed is not properly repaired. Some authors have employed lateral approaches, either the lateral sub periosteal one or the latero-ungual approach. The major drawback of the lateral approaches is the lesser degree of exposure of the nail bed in subungual lesions. Also it is attended by a recurrence rate of 15.7% (1-3, 30).

In this study no tumor recurrence was observed at a

minimum follow up period of one year. Preoperative MRI, the transungual approach with ideal access to the subungual tumor and use of magnification loupes were probably the factors that all facilitated complete tumor excision and hence no recurrence. Several published studies have similarly reported no recurrence in their operated patients (13, 14). The early recurrence quite often reflects an incomplete excision of the original lesion. When the symptoms recur 2-3 years postoperatively, it may reflect underlying multiple tumors. Additionally other causes such as a postoperative neuroma may also occasionally constitute the reason for recurrent pain. True recurrence of the tumor is relatively rare, and is variably reported, ranging between 4%-50% in various published papers (1-4, 23, 31).

In this study no postoperative nail deformities were observed in the patients. Nail dystrophy may result from a variety of factors. For instance, damage to the nail matrix, adherence of the eponychium to the matrix and surface irregularities in the nail bed following surgery. This complication is more commonly reported following transungual approach. Meticulous repair of the nail bed and repositioning of the nail plate on the nail bed have been proposed as the preventive strategies in this regard. Repositioning of the nail plate also prevents adhesion of the eponychium to the nail matrix. More recently, lateral approaches are advocated by some authors to avoid this complication. The reported incidence of nail deformity after transungual approach varies from 3.3%-26.3% (3, 4, 32-33).

In this study all the resected tumor specimens were benign on histological examination. Malignant transformation of glomus tumors is exceedingly rare and few cases have been reported in the literature (34).

Strengths and limitations

The current study possesses certain strengths as well as

certain limitations. The strength is that it prospectively documented the clinical presentation of glomus tumors of the hand. The main limitation is that the target follow up period was limited to one year. Longer periods of follow up, preferably of 5-10 years may help to detect cases of delayed recurrence, underlying multiple tumors or newer lesions developing over the subsequent years. Future studies with longer follow up periods are recommended to overcome the aforementioned limitation.

Glomus tumors of the hands were more frequently found among women in their fourth and fifth decades. Dominant hand, index finger and distal phalanx represented the commonest affected anatomic locales. Majority of the tumors were subungual. Majority of the patients suffered over 12 months in distressful pain before being diagnosed. Complete surgical excision under local anesthesia provided rapid relief of the symptoms. Creation of awareness about the tumor among doctors as well as public would help to ensure early presentation to plastic surgeon, prompt diagnosis and hence avoidance of the prolonged periods of agonizing misery.

Authors' contribution: MS designed the study and wrote the manuscript. The author performed data collection, analyses and approval of the manuscript.

Conflicts of Interest: The author declares that there is no conflict of interest.

Financial disclosure: None declared.

Ethical Issues: The study followed the ethical protocols of Helsinki's Declaration, 2013 revision. Anonymity of the participants was ensured.

Muhammad Saaq FCPS¹

1 Department of Plastic Surgery, NIRM, Islamabad, Pakistan

References

1. Samaniego E, Crespo A, Sanz A. Key diagnostic features and treatment of subungual glomus tumor. *Actas Dermo-Sifiliográficas (English Edition)*. 2009; 100(10):875-82.
2. Tang CY, Tipoe T, Fung B. Where is the lesion? Glomus tumours of the hand. *Archives of plastic surgery*. 2013; 40(5):492.
3. Morey VM, Garg B, Kotwal PP. Glomus tumours of the hand: review of literature. *Journal of clinical orthopaedics and trauma*. 2016; 7(4):286-91.
4. Netscher DT, Aburto J, Koeplinger M. Subungual glomus tumor. *Journal of Hand Surgery*. 2012; 37(4):821-3.
5. Anakwe RE, McEachan JE. A glomus tumour beneath the painful unpolished nail. *Cmaj*. 2010; 182(12):1329-.
6. Santoshi JA, Kori VK, Khurana U. Glomus tumor of the fingertips: A frequently missed diagnosis. *Journal of Family Medicine and Primary Care*. 2019; 8(3):904.
7. Montandon C, Costa JD, Dias LA, Costa FH, Costa AC, Daher RT, et al. Subungual glomus tumors: imaging findings. *Radiologia Brasileira*. 2009; 42(6):371-4.
8. Ham KW, Yun IS, Tark KC. Glomus tumors: symptom variations and magnetic resonance imaging for diagnosis. *Archives of plastic surgery*. 2013; 40(4):392.
9. Fazwi R, Chandran PA, Ahmad TS. Glomus tumour: a retrospective review of 15 years' experience in a single institution. *Malaysian orthopaedic journal*. 2011; 5(3):8.
10. Bargon CA, Mohamadi A, Talaei-Khoei M, Ring DC, Mudgal CS. Factors Associated with Requesting Magnetic Resonance Imaging during the Management of Glomus Tumors. *Archives of Bone and Joint Surgery*.

- 2019; 7(5):422.
11. Pandey CR, Singh N, Tamang B. Subungual glomus tumours: is magnetic resonance imaging or ultrasound necessary for diagnosis? *Malaysian Orthopaedic Journal*. 2017; 11(1):47.
 12. Mravic M, LaChaud G, Nguyen A, Scott MA, Dry SM, James AW. Clinical and histopathological diagnosis of glomus tumor: an institutional experience of 138 cases. *International journal of surgical pathology*. 2015; 23(3):181-8.
 13. Fujioka H, Kokubu T, Akisue T, Nanura I, Toyokawa N, Inul A, et al. Treatment of subungual glomus tumor. *Kobe J Med Sci*. 2009; 55(1): E1-E4.
 14. Jawalkar H, Maryada VR, Brahmajoshiyula V, Kotha GK. Subungual glomus tumors of the hand: Treated by transungual excision. *Indian journal of orthopaedics*. 2015; 49(4):403.
 15. Al-Qattan MM, Al-Namla A, Al-Thunayan A, Al-Subhi F, El-Shayeb AF. Magnetic resonance imaging in the diagnosis of glomus tumours of the hand. *Journal of Hand Surgery*. 2005; 30(5):535-40.
 16. Lee W, Kwon SB, Cho SH, Eo SR, Kwon C. Glomus tumor of the hand. *Archives of plastic surgery*. 2015; 42(3):295.
 17. Shin DK, Kim MS, Kim SW, Kim SH. A painful glomus tumor on the pulp of the distal phalanx. *Journal of Korean Neurosurgical Society*. 2010; 48(2):185.
 18. LIN YC, HSIAO PF, WU YH, SUN FJ, Scher RK. Recurrent digital glomus tumor: analysis of 75 cases. *Dermatologic surgery*. 2010; 36(9):1396-400.
 19. Dwidmuthe S, Nemade A, Rai S. Glomus tumor of thumb occurring at unusual location. *Journal of Surgical Technique and Case Report*. 2013; 5(2):92-4.
 20. Senhaji G, Gallouj S, El Jouari O, Lamouaffaq A, Rimani M, Mernissi FZ. Rare tumor in unusual location—glomus tumor of the finger pulp (clinical and dermoscopic features): a case report. *Journal of medical case reports*. 2018; 12(1):196.
 21. Rosner IA, Argenta AE, Washington KM. Unusual volar pulp location of glomus tumor. *Plastic and Reconstructive Surgery Global Open*. 2017; 5(1).
 22. Shugart RR. Glomus tumor. *Surg Gynecol Obstet*... 1963; 117:334-40.
 23. Carroll RE, Berman AT. Glomus tumors of the hand: review of the literature and report on twenty-eight cases. *JBJS*. 1972; 54(4):691-703.
 24. Rettig AC, Strickland JW. Glomus tumor of the digits. *The Journal of Hand Surgery*. 1977; 2(4):261-5.
 25. Beasley SW, Mel J, Chow CW, Jones PG. Hereditary multiple glomus tumours. *Archives of disease in childhood*. 1986; 61(8):801-2.
 26. Song M, KO HC, KWON KS, Kim MB. Surgical treatment of subungual glomus tumor: a unique and simple method. *Dermatologic surgery*. 2009; 35(5):786-91.
 27. Muramatsu K, Ihara K, Hashimoto T, Tominaga Y, Taguchi T. Subungual glomus tumours: Diagnosis and microsurgical excision through a lateral subperiosteal approach. *Journal of Plastic, Reconstructive & Aesthetic Surgery*. 2014; 67(3):373-6.
 28. Macharia C, Nthumba PM. Glomus tumor presenting as complex regional pain syndrome of the left upper limb: a case report. *Journal of medical case reports*. 2015; 9(1):1-4.
 29. Koç O, Kivrak AS, Paksoy Y. Subungual glomus tumour: magnetic resonance imaging findings. *Australasian radiology*. 2007; 51:B107-9.
 30. Vasisht B, Watson HK, Joseph E, Lionelli GT. Digital glomus tumors: a 29-year experience with a lateral subperiosteal approach. *Plastic and reconstructive surgery*. 2004; 114(6):1486-9.
 31. Tada H, Hirayama T, Takemitsu Y. Prevention of postoperative nail deformity after subungual glomus resection. *Journal of Hand Surgery*. 1994; 19(3):500-3.
 32. Takata H, Ikuta Y, Ishida O, Kimori K. Treatment of subungual glomus tumour. *Hand Surgery*. 2001; 6(01):25-7.
 33. Grover C, Khurana A, Jain R, Rathi V. Transungual surgical excision of subungual glomus tumour. *Journal of cutaneous and aesthetic surgery*. 2013; 6(4):196.
 34. Rahbari K, Farzan M, Saffar H, Farhoud AR. Glomus Tumor of Uncertain Malignant Potential in Thumb: A Case Report and Review of Literature. *Archives of Bone and Joint Surgery*. 2020; 8(1):117.