

RESEARCH ARTICLE

Infantile Idiopathic Scoliosis: Outcomes of Brace Treatment until Skeletal Maturity or Spinal Fusion

Taher Babaei, PhD¹; Mojtaba Kamyab, PhD¹; Mohammad Saleh Ganjavian, MD²

Research performed at Senior Author Spine Clinic, Tehran, Iran

Received: 27 January 2020

Accepted: 27 March 2020

Abstract

Background: Serial casting under general anesthesia, which is considered as a gold standard of treatment for patients with infantile idiopathic scoliosis (IIS), can lead to significant negative neurodevelopmental effects. Therefore, the appropriateness of this type of treatment is controversial. Brace treatment is one alternative method of treatment for IIS patients. However, long-term studies have not yet verified its effectiveness. Thus, the present study aimed to evaluate the effectiveness of brace treatment in patients with IIS until skeletal maturity or spinal fusion.

Methods: The medical records of all IIS patients with the referral age of 0-3 years who received brace treatment from June 1986 to November 2013 were reviewed. Those patients with pre-brace Cobb angle $> 20^\circ$ were included and followed up to skeletal maturity or the time of spinal fusion. The Cobb angle was recorded at the time of diagnosis before the initiation of bracing, weaning time, brace discontinuation, and final follow-up. In addition, the maximum in-brace curve correction was measured.

Results: Out of 87 patients with IIS, a total of 29 cases (19 males and 10 females) with the average curve magnitude of 35.62° at the time of diagnosis were included in the study. The average best in-brace correction was 57.32% for successfully treated patients and 36.97% for progression/surgery patients. Based on the results, brace treatment failed for a total of 20 patients (69%), with a scoliosis curvature progress $\geq 45^\circ$. Of these patients, 12 cases (60%) reached spinal fusion. Finally, four patients (13%) in the surgery-treated group underwent surgery before the age of 10.

Conclusion: The results revealed that bracing was successful for more than two-thirds of patients with IIS curves, preventing surgery before the age of 10.

Level of evidence: IV

Keywords: Brace treatment, Infantile idiopathic scoliosis, In-brace correction, Skeletal maturity, Spinal fusion

Introduction

Infantile idiopathic scoliosis (IIS) is described as scoliosis of unknown causes appearing in infants aged 0-3 years (1) and includes 0.25-12.8% of all types of idiopathic scoliosis (2). According to natural history studies, 70-92% of infantile curves are resolvable, especially among patients younger than one and in those with milder curves at the time of diagnosis, while the scoliosis is presumably progressive for the patients older

than one and those with double major curves (1, 3, 4).

If left untreated, patients with progressive IIS are exposed to pulmonary compromise due to deformity in the chest wall. Therefore, treatment should be initiated immediately after diagnosis. Serial elongation derotation flexion (EDF) casting and bracing are the most common methods of non-operative treatment for IIS cases, and serial casting is known as the standard

Corresponding Author: Mojtaba Kamyab, Department of Orthotics and Prosthetics, School of Rehabilitation Sciences, Iran University of Medical Sciences, Tehran, Iran
Email: kamyab.m@iums.ac.ir



THE ONLINE VERSION OF THIS ARTICLE
ABJS.MUMS.AC.IR

of care (5). The highest success rate of serial casting was reported in the study of Mehta, where the infantile curves of 100% of patients were treated before age two years (6). Casting is typically performed under general anesthesia and should be changed every 6-12 weeks (1). However, repeated anesthesia can have a negative effect on neurodevelopment in early childhood. In December 2016, the Food and Drug Administration issued a "Drug Safety" announcement warning that general anesthesia and sedation drugs in children under three years of age "may affect the development of the child's brain" (7). In addition, various studies have emphasized the toxicity of general anesthesia to children's nervous system (8-10). Therefore, the usefulness of serial casting in treating children with IIS is controversial.

The early use of a brace (with the ability to make frequent adjustments) can eliminate the need for repeated anesthesia. Accordingly, bracing is recommended for those patients with progressive scoliosis curvatures of larger than 20° (11). However, to the best of our knowledge, no study has evaluated the long-term efficacy of brace treatment for IIS patients. In a short-term study, Thometz and Liu revealed that bracing can potentially be successful in controlling IIS curves. However, the long-term effect of bracing, until skeletal maturity, was not reported (12). Therefore, the present study aimed to evaluate the outcomes of brace treatment in IIS until skeletal maturity or spinal fusion.

Materials and Methods

Patients

The present case series, the retrospective chart review study regarding the effect of brace treatment on the curve progression of IIS patients, was approved by the Ethics Committee of Iran University of Medical Sciences (case no.1398.381). To this end, from June 1986 to November 2013, the medical records of all patients with IIS who were treated with a brace were reviewed to obtain data. The inclusion criteria were the referral age of 0-3, Cobb angle more than 20 degrees at the initiation of brace treatment, following treatment up to the end of skeletal maturity (Risser sign > 4) or spinal fusion, the fulfillment of brace treatment, and the availability of complete radiographic information from initial visit to skeletal maturity or spinal fusion. On the other hand, all patients with missing brace treatment data and the follow-up, those who discontinued their treatment before reaching skeletal maturity, and those who were still under treatment were excluded from the study.

The brace treatment for patients with IIS mainly seeks to control the curve progression and prevent spinal fusion before the age of 10 (13). Therefore, reducing the risk of rapid curve progression and delaying the spine fusion are considered the primary goals of bracing for patients with IIS curves > 45°.

Brace treatment

During the chart review, different data including the patients' sex, age (at the time of diagnosis, before the initiation of bracing, and before surgery), and the Cobb angle (at the time of diagnosis, before the initiation of

bracing, best in-brace, the initiation of weaning, brace discontinuation, final follow-up, and before surgery), brace wearing time, follow-up duration, curve pattern, and the brace type were extracted. The maximum in-brace curve correction was evaluated based on Jarvis *et al.* (14). The physician recorded brace compliance by questioning the patient's parents and the appearance of the brace in every routine visit of the patients (with four- to six-month intervals). To evaluate the results of brace treatment based on the curve severity, the Cobb angle before the initiation of bracing was divided into two groups of $\leq 30^\circ$ and $\geq 31^\circ$. For all patients, the largest curve at the initiation of brace treatment was considered for statistical analysis.

Based on the criteria of the Scoliosis Research Society, brace treatment is considered successful if the curve severity at the final follow-up was measured $< 46^\circ$ (15). The patients were divided into "success" or "failure" groups with regard to treatment outcome.

Statistical analysis

Statistical analyses were conducted using SPSS software, version 17 (SPSS Inc., Chicago IL, USA). Descriptive statistics were reported as mean, standard deviation, and range. Additionally, the chi-squared test and the independent-sample t-test were performed for nominal and continuous variables, respectively. Eventually, the analyses were conducted between the success and failure groups. A *p-value* < 0.05 was considered for statistically significant differences.

Results

Patients

Among the 87 cases with IIS, 58 were excluded from the study. Of these, 16 cases were still under treatment while 42 cases had lost the final follow-up [Figure 1]. Finally, a sample of 29 patients (10 girls and 19 boys) with an average age of 18.58 ± 8.90 months at the time of diagnosis met the inclusion criteria (male to female ratio of 2:1). At the initiation of brace treatment, a custom-made body-jacket was prescribed for all of the patients. Further, adequate space in the anterior chest wall of the orthosis was considered to maintain lung function and allow the expansion of the chest during breathing. A perineal strap was further added to prevent the superior migration of the orthosis on a patient's body. After ensuring the patient's active involvement in the treatment process, the physician prescribed a Thoracolumbosacral Orthosis (TLSO) for scoliosis curves with apex vertebra up to T8 or Milwaukee brace for main thoracic curves with an apex above T8. In general, 21 (72%) and eight (18%) patients were treated with TLSO and Milwaukee brace, respectively. The average scoliosis Cobb angle was $35.6^\circ \pm 11.6^\circ$ (range 15°-60°) and $37.7^\circ \pm 11.1^\circ$ (range 20°-60°) at the initial visit and at the initiation of brace treatment, respectively. Overall, 16 patients (55.1%) had left thoracic curve pattern and three cases (10.4%) had a right thoracic curve pattern. Furthermore, seven patients (24.1%) had a right thoracolumbar curve pattern and three (10.4%) had left thoracolumbar curve patterns. Table 1 presents a summary of the patients' characteristics from the initial

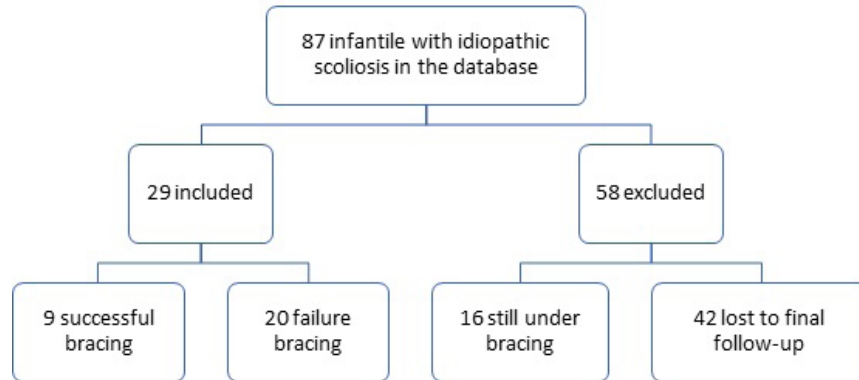


Figure 1. Flow diagram illustrating the included and excluded patients in the present study.

Table 1. Summary of the entire patient's characteristics

Patient no.	Gender	Curve pattern	Age			Cobb angle							Wear- ing time (yr)	Follow- up duration	Brace type
			Baseline (month)	Prebrace (month)	Surgery (yr)	Baseline	Prebrace	In-brace	Weaning	Brace DC	Final follow-up	Before surgery			
1	2	Left Th	26	33	-	28	34	25	44	45	48	-	13	24	TLSO
2	2	Left Th	19	19	-	35	35	10	37	45	48	-	13	25	Milwaukee
3	1	Left Th	22	22	-	23	23	15	17	45	48	-	12	19	TLSO
4	1	Right T/L	4	18	-	58	58	20	15	55	60	-	13	26	TLSO
5	1	Right T/L	15	17	15	55	55	35	-	-	-	80	11	-	TLSO
6	2	Left Th	21	32	-	35	35	10	14	16	22	-	13	20	Milwaukee
7	2	Left Th	36	36	-	30	30	18	42	50	55	-	14	24	TLSO
8	1	Right T/L	32	40	15	40	50	38	50	50	60	60	15	24	TLSO
9	1	Left Th	24	28	-	15	25	10	28	35	35	-	12	24	Milwaukee
10	1	Left Th	11	36	-	38	38	15	24	28	30	-	14	26	TLSO
11	2	Left Th	30	30	-	22	22	5	18	25	26	-	11	27	TLSO
12	1	Right Th	2	24	14	20	40	30	-	-	-	65	11	-	Milwaukee
13	1	Right T/L	12	24	10	35	50	35	-	-	-	67	8	-	TLSO
14	1	Left Th	12	24	9	44	44	40	-	-	-	70	7	-	Milwaukee
15	1	Left Th	12	24	18	40	40	23	55	60	-	62	15	-	TLSO
16	2	Left T/L	12	36	13	45	45	36	-	-	-	81	9	-	TLSO
17	2	Right T/L	24	24	13	30	30	22	-	-	-	52	10	-	TLSO
18	1	Left Th	5	12	3	60	60	44	-	-	-	65	2	-	TLSO
19	2	Right Th	24	24	15	20	20	10	50	-	-	60	12	-	Milwaukee
20	2	Right T/L	30	30	7	36	36	30	-	-	-	70	7	-	TLSO
21	2	Left Th	17	22	-	45	45	35	40	50	50	-	15	29	Milwaukee
22	1	Left Th	3	11	-	50	50	10	35	40	50	-	17	27	TLSO
23	1	Right Th	30	30	-	25	25	12	35	30	32	-	14	30	TLSO
24	2	Right T/L	11	24	6	45	45	28	-	-	-	55	5	-	TLSO
25	1	Left Th	30	32	-	22	22	15	24	25	28	-	15	24	Milwaukee
26	1	Left T/L	15	16	-	35	35	16	37	44	46	-	15	20	TLSO
27	2	Left T/L	14	16	-	40	40	20	28	38	44	-	14	23	TLSO
28	1	Left Th	17	20	-	34	35	18	24	30	36	-	14	24	TLSO
29	1	Left Th	15	18	-	28	28	10	20	28	32	-	15	26	TLSO

Th indicates thoracic; T/L, thoracolumbar; DC, discontinue; TLSO, Thoracolumbosacral orthosis.

Table 2. The mean age and scoliosis Cobb angles at different stages of brace treatment between the success/stable and progression/surgery groups (n=29).

Variables	Success (n=9)	Failure (n=20)	P
Age at baseline (month)	21.33± 7.51	17.35± 9.37	0.30
Age at initiation of bracing (month)	27.33 ± 7.41	24.60 ± 7.69	0.37
Cobb angle at baseline (°)*	28.77 ± 8.46	38.70 ± 11.76	0.03
In-brace curve correction (%)	57.32 ± 13.56	36.97 ± 18.84	0.007
Cobb angle at initiation of bracing (°)	30.00 ± 7.03	41.25 ± 11.00	0.01
Cobb angle at brace discontinue (°)**	28.33 ± 6.30	57.45 ± 12.04	<0.001

*Largest curve was measured.

**For surgery group, preoperative Cobb angle was considered.

visit to the final follow-up or spinal fusion. At the baseline examination, five patients (17%) demonstrated an asymmetric or diminished lower extremity/abdominal reflexes. However, the following magnetic resonance imaging revealed no remarkable intraspinal pathology.

Result of brace treatment

In general, the scoliosis curve progressed in 20 patients (69%), 12 of which (60%) reached spinal fusion. According to the Scoliosis Research Society, the effectiveness of bracing for the samples of the present study was 31%. As shown in Table 2, the mean scoliosis Cobb angle at the initial visit, the initiation of brace treatment, and the weaning time was significantly lower in the success group compared to the failure group ($P<0.05$). In fact, no significant differences were observed at the initial visit and initiation of treatment between the two groups in terms of the patient's age ($P>0.05$). Based on the results, in-brace correction was significantly higher ($P<0.05$) in the success group compared to the failure group (57% and 37%, respectively). Table 3 provides the characteristics of patients in the success group at different stages of treatment.

Among the studied patients, 41% (12 of 29) of cases underwent spinal fusion, who had a mean age of 11.50 ± 4.48 (within the range of 3-18 years) and the mean curve magnitude of $65.5^\circ \pm 8.8^\circ$ (ranging from 52° to 81°) at the time of surgery. Regarding surgery patients, four cases (13%) underwent spinal fusion before the age of 10 years. These patients had a curve magnitude of 55° to 70° at the time of surgery. Considering the factors such as the patient's age, severity of the curve, functional status, and parent's choice, the decision for the operative treatment of a patient with IIS may be difficult and challenging. However, the existence of a curve size $> 50^\circ$ is considered as the routine recommendation for spinal fusion in IIS.

Table 4 represents data related to the role of pre-bracing curve pattern and curve severity on the effectiveness of brace treatment. The progression rate was unexpectedly higher in the patients with thoracolumbar curve pattern (90%) compared to those with thoracic curve pattern (58%). Additionally, the results indicated that before bracing Cobb angle was significantly higher in patients

Table 3. Results of the patients with stable/improved curve (n=9)

Variables	Mean (SD)	Range
Age		
Baseline (month)	21.33 (7.51)	11-30
Initiation of bracing (month)	27.33 (7.41)	16-36
Menarche (yrs.)	12.00 (1.15)	10-13
Weaning (yrs.)	14.00 (1.00)	12-15
Skeletal maturity (yrs.)	15.55 (0.72)	14-16
Cobb angle (°)		
Baseline	28.77 (8.46)	15-40
Initiation of bracing	30.00 (7.03)	22-40
Initiation of weaning	23.88 (6.17)	14-35
Brace discontinue	28.33 (6.30)	16-38
Final follow-up	31.66 (6.36)	22-44
Brace wearing time (yrs.)	13.55 (1.33)	11-15
Follow-up duration (month)	22.88 (4.56)	12-27

SD indicates standard deviation.

Table 4. Impact of pre-brace curve type and curve magnitude on effectiveness of bracing

Variables	Success n/N (%)	Failure n/N (%)	P
Curve pattern			
Thoracic	8/19 (42%)	11/19 (58%)	0.49
Thoracolumbar	1/10 (10%)	9/10 (90%)	0.01
Curve magnitude			
$\leq 30^\circ$	5/9 (55%)	4/9 (45%)	0.73
$\geq 31^\circ$	4/20 (20%)	16/20 (80%)	0.007

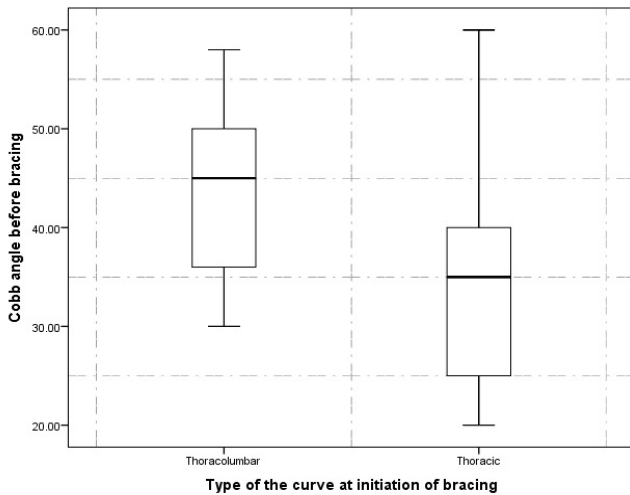


Figure 2. Before bracing curve magnitude between patients with thoracolumbar and thoracic curves pattern.

with a thoracolumbar curve pattern compared to those with a thoracic curve pattern (44.8° and 38.2°, respectively). Figure 2 displays the related data.

As shown in Table 4, nine (31%) and 20 (69%) of patients were observed with the pre-brace Cobb angle $\leq 30^\circ$ and the Cobb angle $\geq 31^\circ$, respectively. The progression rate was significantly higher in the patients with a major Cobb angle of $\geq 31^\circ$ compared to those with a Cobb angle $\leq 30^\circ$ (80%). Therefore, it is noteworthy that the success rate is only 20% if an infantile curve magnitude is more than $\geq 31^\circ$ at the initiation of brace treatment.

Discussion

In the non-operative treatment of IIS, the outcomes are considered excellent if the patients never needed spinal fusion. However, the outcomes are considered good if the patients need surgery during adolescence (13). The present study evaluated the effectiveness of bracing in IIS patients until skeletal maturity or spinal fusion. The results demonstrated that the success rate of brace treatment was good to excellent for 77% of the patients. In addition, 13% of the patients underwent surgery before the age of 10 years.

Serial casting, which is performed under general anesthesia, is recognized as the most effective non-operative treatment of IIS. One of the advantages of casting is that the patient or his/her parents cannot remove it at any time. Thus, its compliance rate represents an increase (12). However, serial casting has several disadvantages. For instance, the cast should be replaced at the interval of 8 to 16 weeks, which should be performed under general anesthesia to apply the optimum corrective forces to the trunk (6). Further, repeated anesthesia can have negative effects on the neurodevelopmental status of the infants and their parents' quality of life (8). Furthermore, the sensitive area cannot be readily inspected when pressure or friction sores occur, since no verbal communication exists between the parents and the infants. A decrease in

physical contact between the infant and parents, which can affect the maternal or paternal attachment attitudes, is considered as another concern about prolonged serial casting which can affect the quality of life among parents and infants. The lack of physical contact raises concerns which may have a negative impact on the social development of growing children in the long term (12). Therefore, the usefulness of serial castings for the treatment of IIS is questionable. The early use of a brace (with the ability to make frequent adjustments) can eliminate the need for repeated anesthesia, increase the daily inspection of the infant's body, and the adjustments to the areas of excessive pressure or friction, and allow cleaning the inside of the brace. Additionally, it helps the parents to embrace and touch their child more easily, which can improve the quality of life of parents and infant for a short time (12). Other benefits of early bracing over casting include low weight, affordable, further convenience, and possibility of its doffing for bathing the baby.

Some studies evaluated the effectiveness of brace treatment in the IIS. However, the follow-up period in these studies was short and the patients were not evaluated until skeletal maturity. For example, Smith *et al.*, in a study on 17 infants with IIS, found that 47% of patients were successfully treated with the brace (11). In addition, Thometz and Liu evaluated the effect of serial CAD/CAM bracing on nine patients with IIS and reported that the curve magnitude of four patients reached less than 10 degrees, and the average Cobb angle improved from 57° to 21° for the other five patients (12). However, the results of this study were only reported for a two-year period while not describing the long-term outcomes of bracing (until skeletal maturity). To the best of our knowledge, the present study is the first one in which patients were reviewed until skeletal maturity or spinal fusion. The results demonstrated that the average in-brace curve correction was 49% and 40% in patients with the Cobb angles of $\leq 30^\circ$ and $\geq 31^\circ$, respectively. In the study of Thometz and Liu, the rate of in-brace curve correction for patients with Cobb angles of $< 30^\circ$ was 81%, which was significantly higher than the obtained value in the present study (12). On the other hand, the results of the present study regarding the Cobb angles of $\geq 31^\circ$ are in line with those of the above-mentioned study (40%). However, considering the long duration of the treatment process for IIS patients, the long-term results of wearing a brace highly differs from the short-term results.

The findings of different studies on idiopathic scoliosis revealed that some parameters such as age at the initiation of bracing, the pre-brace Cobb angle, the curve pattern, and the value of in-brace curve correction can influence the outcomes of the treatment. In the present study, the severity of the scoliosis curve at the initiation of bracing was significantly lower in the success group compared to the failure group. Further, the in-brace curve correction was significantly higher in the success group compared to the failure group. Based on the results of the previous studies on adolescents with idiopathic scoliosis, the thoracic curve pattern is considered a potential risk

factor for the failure of brace treatment. The results of the present study indicated that 58% of patients with thoracic curve patterns experienced curve progression. However, the value of curve progression in patients with thoracolumbar curve pattern was 90%. Furthermore, the results represented that the curve magnitude at the initiation of bracing was significantly higher in patients with a thoracolumbar curve pattern compared to those with thoracic curve patterns (44° vs. 38°). Therefore, the magnitude of a scoliotic curve at the initiation of brace treatment is regarded as a major risk factor for further curve progression in patients with IIS. In addition, the results demonstrated that the maximum in-brace correction occurs during the first year after initiating the brace treatment, which may be related to the viscoelastic changes in the curve over time. Thus, the value of immediate in-brace correction (i.e., curve correction that occurs immediately after wearing the brace) is not an important predictor for the positive outcome of bracing in IIS patients. These results corroborate those of Welborn *et al.* (13).

The patient's age at the initiation of treatment is regarded as another important predictor of success in the non-operative treatment of IIS. Mehta found that the scoliosis curves were resolved for 100% of cases among those who had a mean age of 19 months at the initiation of casting (6). However, for those patients with a mean age of two years and six months at the initiation of treatment, casting could only control the progression of the curve, among which 35.7% finally underwent spinal fusion. In another study, Iorio *et al.* concluded that the earlier age of the child at the initiation of treatment leads to a higher success rate of treatment with casting (16). On the other hand, Welborn *et al.* found no relationship between the age at the initiation of casting and the success rate of treatment (13). The results of the present study are consistent with those of Welborn *et al.* In the present study, the mean age at the initiation of treatment was 21 and 17 months in success and failure groups, respectively. Considering the differences in the pre-brace curve magnitude between failure and success groups (38° vs. 28°), the curve magnitude is a major risk factor for curve progression in IIS compared to the patient's age at the initiation of brace treatment. Furthermore, the finding was confirmed by Iorio *et al.* and Sanders *et al.* (16, 17). However, Welborn *et al.* reported that the curve magnitude at the initiation of treatment is not an important predictor for the success rate of serial casting (13).

The present study had several important limitations. This study was a retrospective review of a 27-year period.

Thus, the retrospective nature of the study inherently limits the quality and quantity of data in patients' clinical records. Brace compliance is another factor affecting the success of brace treatment in idiopathic scoliosis, which was emphasized in various studies (18-20). Subjective and objective methods are used to evaluate brace compliance. Regarding the objective method in which a reliable thermal or pressure data logger is used, more accurate information is obtained from the daily wearing hours of the brace. Lavelle first introduced the use of these sensors in 1996 (21). The measurement of objective compliance was impossible due to the retrospective nature of the present study in which the patient's medical records were evaluated from 1986 to 2013. However, at each follow-up during brace treatment, the treating physician recorded the average hours of brace wearing by evaluating the appearance of the brace and asking the patients and parents. In addition, comparing the results with those of the casting method was impossible since all patients were treated with a brace. Finally, considering the retrospective nature of the study, the statistics were limited to the data available in the clinical records of the patients although the evaluation and documentation of the information of all cases were consistently conducted by a treating physician (M. S. G).

In conclusion, Bracing is a good strategy to preclude the curve progression during infantile and juvenile years. The long-term success rate of brace treatment for IIS was 31% when considering final curve magnitude of $\leq 45^\circ$.

Acknowledgments

We would like to show our gratitude to the Marjan Saedi for proofreading the manuscript.

Conflict of interests and Source of Funding: This work was supported by the Iran National Science Foundation (INSF) under grant number 97011374, and supported by the research committee of Iran University of Medical Sciences. There is no conflict of interest about the study.

Taher Babaee PhD¹

Mojtaba Kamyab PhD¹

Mohammad Saleh Ganjavian MD²

1 Department of Orthotics and Prosthetics, School of Rehabilitation Sciences, Iran University of Medical Sciences, Tehran, Iran

2 Department of Orthopaedic Surgery, Shafa Yahyaiian Hospital, Iran University of Medical Sciences, Tehran, Iran

References

1. James JI. Idiopathic scoliosis; the prognosis, diagnosis, and operative indications related to curve patterns and the age at onset. *J Bone Joint Surg Br.* 1954; 36-b(1):36-49.
2. Scott JC, Morgan TH. The natural history and prognosis of infantile idiopathic scoliosis. *J Bone Joint Surg Br.*

- 1955; 37-b(3):400-13.
3. Ceballos T, Ferrer-Torrelles M, Castillo F, Fernandez-Paredes E. Prognosis in infantile idiopathic scoliosis. *J Bone Joint Surg Am.* 1980; 62(6):863-75.
 4. Thompson SK, Bentley G. Prognosis in infantile idiopathic scoliosis. *J Bone Joint Surg Br.* 1980; 62-b(2):151-4.
 5. Tis JE, Karlin LI, Akbarnia BA, Blakemore LC, Thompson GH, McCarthy RE, et al. Early onset scoliosis: modern treatment and results. *J Pediatr Orthop.* 2012; 32(7):647-57.
 6. Mehta MH. Growth as a corrective force in the early treatment of progressive infantile scoliosis. *J Bone Joint Surg Br.* 2005; 87(9):1237-47.
 7. FDA review results in new warnings about using general anesthetics and sedation drugs in young children and pregnant women. The U.S. Food and Drug Administration (FDA): 2016 [updated 2017 April 27; cited 2016 December 14]. Available from: <https://www.fda.gov/drugs/drug-safety-and-availability/fda-drug-safety-communication-fda-approves-label-changes-use-general-anesthetic-and-sedation-drugs>.
 8. Andropoulos DB, Greene MF. Anesthesia and developing brains: implications of the FDA warning. *N Engl J Med.* 2017; 376(10):905-7.
 9. Derderian CA, Szmuk P, Derderian CK. Behind the Black Box: The evidence for the U.S. food and drug administration warning about the risk of general anesthesia in children younger than 3 years. *Plast Reconstr Surg.* 2017; 140(4):787-92.
 10. Hu D, Flick RP, Zaccariello MJ, Colligan RC, Katusic SK, Schroeder DR, et al. Association between exposure of young children to procedures requiring general anesthesia and learning and behavioral outcomes in a population-based birth cohort. *Anesthesiology.* 2017; 127(2):227-40.
 11. Smith JR, Samdani AF, Pahys J, Ranade A, Asghar J, Cahill P, et al. The role of bracing, casting, and vertical expandable prosthetic titanium rib for the treatment of infantile idiopathic scoliosis: a single-institution experience with 31 consecutive patients. *J Neurosurg Spine.* 2009; 11(1):3-8.
 12. Thometz J, Liu XC. Serial CAD/CAM Bracing: An alternative to serial casting for early onset scoliosis. *J Pediatr Orthop.* 2019; 39(3):e185-e9.
 13. Welborn MC, D'Astous J, Bratton S, Heflin J. Infantile idiopathic scoliosis: factors affecting EDF casting success. *Spine Deform.* 2018; 6(5):614-20.
 14. Jarvis J, Garbedian S, Swamy G. Juvenile idiopathic scoliosis: the effectiveness of part-time bracing. *Spine (Phila Pa 1976).* 2008; 33(10):1074-8.
 15. Richards BS, Bernstein RM, D'Amato CR, Thompson GH. Standardization of criteria for adolescent idiopathic scoliosis brace studies: SRS Committee on bracing and nonoperative management. *Spine (Phila Pa 1976).* 2005; 30(18):2068-75.
 16. Iorio J, Orlando G, Diefenbach C, Gaughan JP, Samdani AF, Pahys JM, et al. Serial casting for infantile idiopathic scoliosis: radiographic outcomes and factors associated with response to treatment. *J Pediatr Orthop.* 2017; 37(5):311-6.
 17. Sanders JO, D'Astous J, Fitzgerald M, Khoury JG, Kishan S, Sturm PF. Derotational casting for progressive infantile scoliosis. *J Pediatr Orthop.* 2009; 29(6):581-7.
 18. van den Bogaart M, van Royen BJ, Haanstra TM, de Kleuver M, Faraj SSA. Predictive factors for brace treatment outcome in adolescent idiopathic scoliosis: a best-evidence synthesis. *Eur Spine J.* 2019; 28(3): 511-525.
 19. Rahimi S, Kiaghadi A, Fallahian N. Effective factors on brace compliance in idiopathic scoliosis: a literature review. *Disabil Rehabil Assist Technol.* 2019:1-7. doi: 10.1080/17483107.2019.1629117. [Epub ahead of print].
 20. Hawary RE, Zaaroor-Regev D, Floman Y, Lonner BS, Alkhalife YI, Betz RR. Brace treatment in ais: risk factors for failure - a literature review. *Spine J.* 2019 ;19(12):1917-25.
 21. Lavelle J. An assessment of brace compliance in adolescent idiopathic scoliosis using a new brace timer. *J Bone Joint Surg Br.* 1996;78(Supp):162.