

CASE REPORT

Early Diagnosis of Giant Solitary Synovial Chondromatosis of the Hip Using Ultrasound-guided Synovial Biopsy: A Case Report

Khodamorad Jamshidi, MD¹; Mehryar Khadem, MD¹; Tina Shooshtarizadeh, MD¹; Alireza Mirzaei, PhD¹

Research performed at Shafa Orthopedic Hospital of Iran University of Medical Sciences, Tehran, Iran

Received: 10 October 2020

Accepted: 15 February 2020

Abstract

The diagnosis of synovial chondromatosis (SCM) is usually delayed, as the arthroscopic-guided synovial biopsy is postponed owing to its invasive nature. We report the timely diagnosis of a giant solitary synovial chondromatosis of the hip in a 32-year-old woman using ultrasound-guided synovial biopsy. This technique revealed to be safe and successful in the diagnosis of SCM, when the imaging studies were obscure. Moreover, it avoided the potential arthroscopy-associated complications. We recommend ultrasound-guided synovium biopsy as a less invasive and less complicated technique for the early diagnosis of SCM in future workouts.

Level of evidence: V

Keywords: Hip, Synovial chondromatosis, Ultrasound-guided synovial biopsy

Introduction

Synovial chondromatosis (SCM), also known as the Reichel syndrome, is a rare, benign, and progressive lesion characterized by the foci of loose cartilaginous bodies within the synovium of joints that could be calcified or ossified (1). Giant solitary synovial chondromatosis (GSSCM) is an unusual and uncommon presentation of SCM, and the term is used when the lesion size exceeds 1 cm (2, 3). To prevent articular and peri-articular destruction and to eliminate symptoms including pain and swelling, surgical removal of the lesion is imperative. Yet, the definitive diagnosis of the lesion is delayed in many cases due to the non-specific characteristics, eventually presented as secondary osteoarthritis (1). Although identifying the mineralized nodules on radiographs is the most commonly used diagnostic tool, an arthroscopic-guided synovial biopsy is necessary if radiographic findings are non-specific (4).

Ultrasound-guided synovial biopsy is encouraged for

more widespread use as it confers many advantages over arthroscopic-guided synovial biopsy. It is less invasive and its complication rate is considerably lower than arthroscopic-guided synovial biopsy. Ultrasound-guided synovial biopsy is also less time-consuming and more economical, as it could be managed with local analgesia (5).

Although ultrasound-guided synovial biopsy has been performed in earlier investigations to obtain synovial tissue, there is no report regarding the application of this technique in the diagnosis of SCM (5). Here, we describe the early and successful diagnosis of a case of GSSCM in a 32-year-old woman that was successfully diagnosed using ultrasound-guided synovial biopsy.

Case presentation

A 32-year-old woman was referred to our center with a history of one-year limping and dull mechanical pain in her left hip. The pain was progressive and gradually

Corresponding Author: Alireza Mirzaei, Bone and Joint Reconstruction Research Center, Shafa Orthopedic Hospital, Iran University of Medical Sciences, Tehran, Iran
Email: mirzaei.ar@iums.ac.ir, mirzaeialireza26@gmail.com



THE ONLINE VERSION OF THIS ARTICLE
ABJS.MUMS.AC.IR

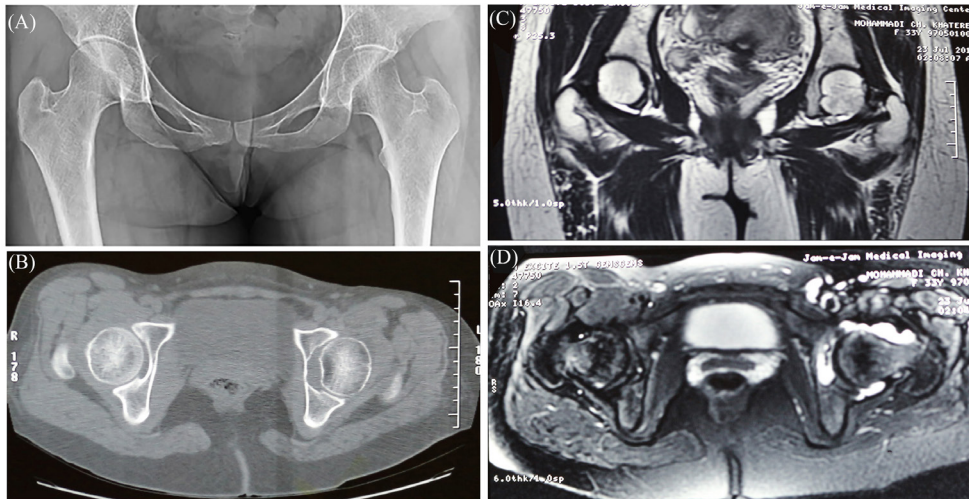


Figure 1. (A) Pre-operative anteroposterior radiograph of the hip showing an increased distance was noticed between the femoral head and the lateral aspect of teardrop; (B) CT scan of the hip showing an enlargement of fovea capitis; (C) Coronal T1-weighted MRI of the hip showing an intermediate signal density in the enlarged fovea capitis; (D) Axial T2-weighted MRI of the hip showing a high-intensity signal around the head and neck of the femur.

radiated to the left trochanteric region and the medial side of the thigh. In the beginning, the pain was only felt during physical exercise. Later, the pain was continuously felt either during activity or at rest. The hip was temporarily locked when the patient stood or sat for a while (more than half an hour). No history of trauma was mentioned by the patient. No sign of fixed deformity, scar, and a bruise was present in the clinical examination, as well. At the joint palpation, tenderness and mild swelling were noticed on the affected groin. The left hip movement was not limited but painful in the extreme range of motion of all directions. The neurovascular examination was normal. Physiotherapy and analgesic medications were not effective in relieving the symptoms. The laboratory tests, including complete blood count, erythrocyte sedimentation rate, and C-reactive protein were all within the normal range.

Fine needle aspiration of the fluid was done for cytopathologic assessment that proved to be negative for malignant cells. The culture of aspirated fluid and polymerase chain reaction (PCR) test for Tuberculosis and Brucella were both negative as well. In plain radiographs, an increased distance was noticed between the femoral head and lateral aspect of teardrop [Figure 1A]. In computed tomography (CT) scan, an enlargement of fovea capitis was observable [Figure 1B]. Coronal T1 weighted MRI showed an intermediate signal density in the enlarged fovea capitis [Figure 1C]. In the axial T2 weighted MRI, there was a high-intensity signal around the head and neck of the femur [Figure 1D]. The bone scan evaluation revealed increased uptake in the affected regions. As the para-clinic and radiologic assessments were not diagnostic, an ultrasound-guided synovial biopsy was planned.

The ultrasound-guided synovial biopsy was performed

using a SuperCore™ Semi-Automatic Biopsy instrument. In this respect, the ultrasound assessment of the joint was done first in order to determine the optimal areas of synovial sampling. After disinfecting the skin and local anesthesia, a portal was created at the appropriate region using a trephine needle. Under the ultrasound guidance, a 20-gauge TSK STARCUT biopsy needle was inserted into the target synovial site via the established portal and the synovial specimen was obtained [Figure 2]. The extracted samples were sent to the pathology department for histological examinations. In the histologic examination of the lesion, nodular proliferation of hyaline cartilage in relation to the synovial lining along with increased



Figure 2. 20-gauge TSK STARCUT biopsy needle that was used for obtaining synovial specimen.

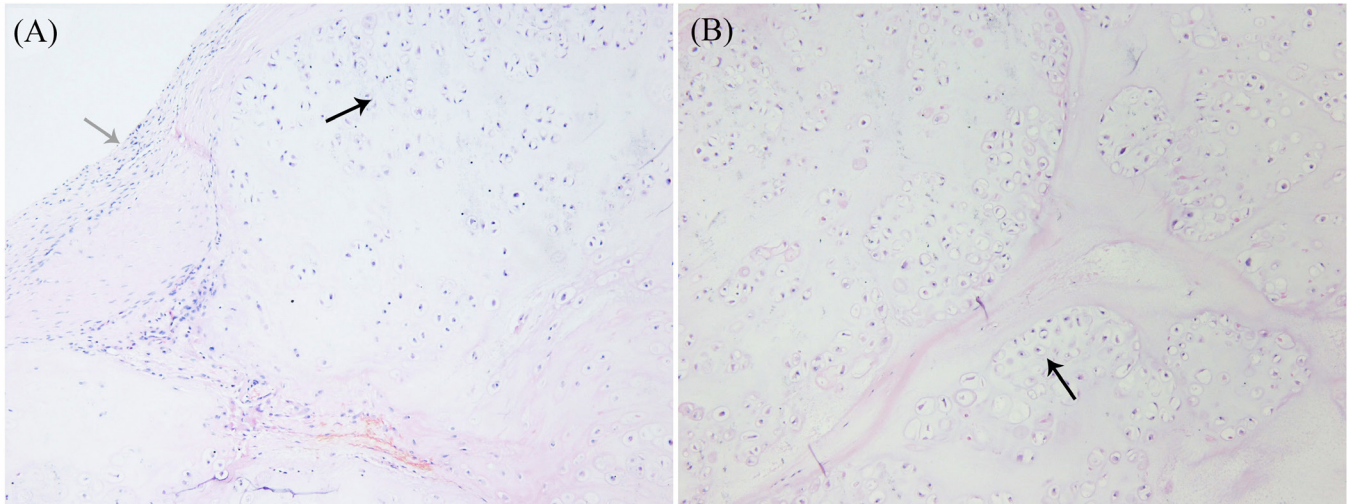


Figure 3. Histologic examination of the lesion showing (A) the nodular proliferation of hyaline cartilage (black arrow) in relation to synovial lining (gray arrow) (x10); (B) increased cellularity with irregular distribution of chondrocytes (black arrow) (x20).

cellularity with irregular distribution of chondrocytes were suggestive of SCM diagnosis [Figure 3A; 3B]. Accordingly, the patient was scheduled for surgical dislocation and synovectomy.

A modified synovectomy was performed as earlier described (6). In brief, after prophylactic antibiotic treatment and under general anesthesia, the patient was placed at lateral position. The surgical hip dislocation was employed as described by Ganz et al. (7). In this respect, the hip was exposed anteriorly and dislocated in the same direction using a Gibson approach. The caution was made to preserve the integrity of the external rotator muscles. The main blood supply to the femoral head was protected in this approach. Subsequently, the

hip was exposed through a transverse capsulotomy and evaluated in detail. A monolithic cartilaginous tissue was found in the fovea around the neck and the acetabulum [Figure 4]. The lesion was extracted with curettage and limited burring around the fovea, head, and femur neck in which some erosion was found. Histopathologic examination confirmed the diagnosis of GSSCM.

Complete weight-bearing was avoided for two weeks after the surgery. Six months after the surgery, the patient was pain-free and had no complaints. The hip range of motion was normal. Two years after the surgery, the pelvis radiograph showed normal hip joint space and no recurrence was found [Figure 5]. Consent for publication was obtained from the patient.

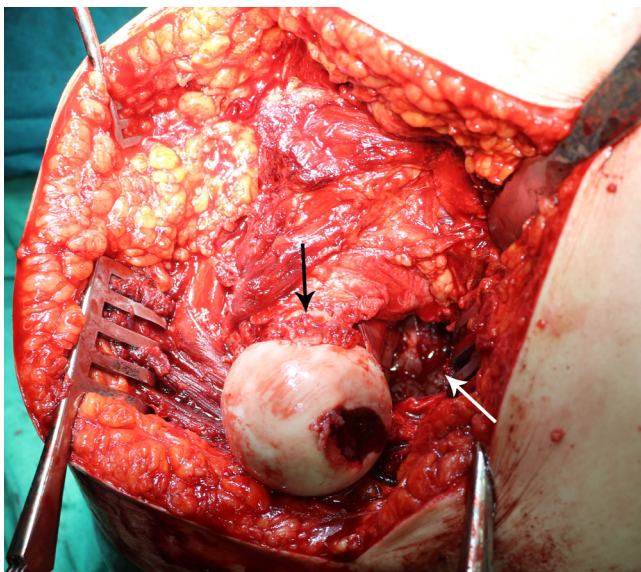


Figure 4. Intraoperative photograph showing a monolithic lesion around the neck (black arrow) and acetabulum (white arrow).

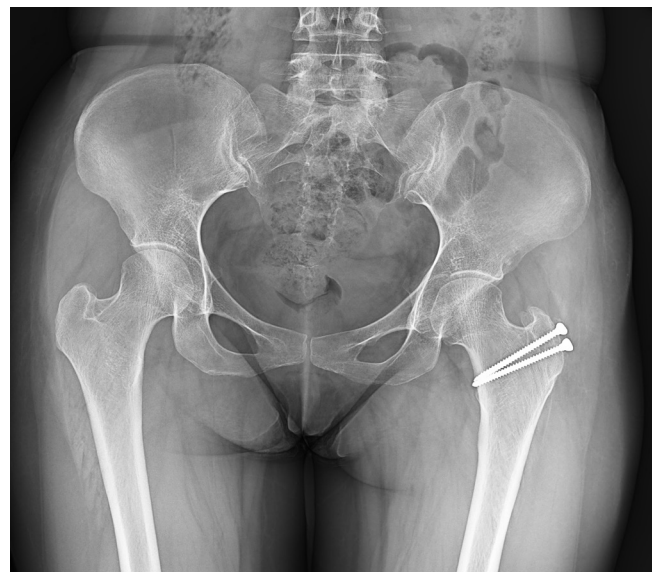

Figure 5. Hip radiograph of the patient two years after the surgery showing normal joint space with no recurrence.

Discussion

After the advancement of chemotherapy and radiation techniques which led to significant improvement of the oncologic outcome of patients, many researchers focused on the improvement of the functional outcome through optimization of the surgical techniques (8-10).

Up to 48% of patients with SCM of the hip may proceed to arthroscopic-guided synovial biopsy as the imaging studies alone fail to establish the diagnosis in these patients (11). Although arthroscopy is considered as a safe and secure procedure, it is not a benign procedure and several intra-operative and post-operative complications have been reported. Salzler et al. reported the surgical and anesthetic complications and infection as the most common complications of arthroscopy (12). Thus, the implication of the less complicated method, whenever possible, is of critical value.

Here, we have described an early and successful diagnosis of GSSCM in a 32-year-old woman. Considering the non-specific imaging findings, an arthroscopic-guided synovial biopsy was indicated. Yet, we decided to perform an ultrasound-guided synovial biopsy in order to avoid potential arthroscopy-associated complications. Our approach revealed to be safe and successful in the timely diagnosis of SCM when the imaging studies were obscure.

Synovial tumors, infection, and inflammation are the three main reasons of synovial thickening. The pigmented villonodular synovitis, synovial chondromatosis are the main tumors involving the synovium. Synovial hemangioma, diffuse articular lipomatosis, synovial chondroma or fibroma, synovial chondrosarcoma, synovial sarcoma, or lymphoma are the less common synovial tumors (13). Regarding the wide differential diagnosis of synovial disorders, the differentiation of joint pain is usually challenging and synovial biopsy is generally used to determine the underlying cause of diffuse or localized synovial thickening (5).

Traditionally, arthroscopic-guided biopsy is the procedure of choice when joints are involved (5). Currently, ultrasound-guided synovial biopsy has attracted much

attention as it provides many advantages over the arthroscopic-guided synovectomy (5). Specifically, no joint infection, neurovascular injury, or exacerbation of disease symptoms have been reported following the ultrasound-guided synovial biopsy (5).

To date, the implication of ultrasound-guided synovial biopsy has been reported in several investigations. The majority of these investigations have used this technique to obtain synovial tissue to study inflammation in patients with rheumatoid arthritis (5). Marin et al. (in France) reported a cohort of 83 synovial biopsies performed largely as a diagnostic procedure for monoarthritis of unknown etiology. No complication was recorded in their patients. They concluded that ultrasound-guided biopsy of synovium is a safe and effective technique that has multiple advantages over the fluoroscopic-guided procedure (14). To date, the only reported adverse reaction of ultrasound-guided synovium biopsy is a vasovagal-type attack in a small number of patients (1-2%) that occurred during the biopsy procedure and erysipelas in one patient which occurred one week after the biopsy (15).

No matter which method of synovial biopsy is used, the ultimate goal is to obtain sufficient synovial tissue for histologic analysis, using the least invasive available technique. Obviously, ultrasound-guided synovium biopsy is a less invasive and less complicated technique when compared with arthroscopic-guided synovium biopsy. Thus, its implication is warranted in the early diagnosis of SCM lesions.

Khodamorad Jamshidi MD¹

Mehryar Khadem MD¹

Tina Shooshtarizadeh MD¹

Alireza Mirzaei PhD¹

1 Bone and Joint Reconstruction Research Center, Shafa Orthopedic Hospital, Iran University of Medical Sciences, Tehran, Iran

References

1. Crotty JM, Monu J, Pope JT. Synovial osteochondromatosis. *Radiologic Clinics of North America*. 1996;34(2):327-42, xi.
2. Edeiken J, Edeiken BS, Ayala AG, Raymond AK, Murray JA, Guo S-Q. Giant solitary synovial chondromatosis. *Skeletal radiology*. 1994;23(1):23-9.
3. Jamshidi K, Barbuto R, Shirazi M, Abolghasemian M. Giant Solitary Synovial Chondromatosis Mimicking Chondrosarcoma: Report of a Rare Histologic Presentation and Literature Review. *American journal of orthopedics (Belle Mead, NJ)*. 2015;44(8):E286-90.
4. Fox C, Hull R, Langdown A, editors. *SYNOVIAL CHONDROMATOSIS: A DIAGNOSIS TO CONSIDER IN PERSISTENT HIP DISEASE WITH NORMAL PLAIN X-RAYS*. RHEUMATOLOGY; 2014: OXFORD UNIV PRESS GREAT CLARENDON ST, OXFORD OX2 6DP, ENGLAND.
5. Sitt JC, Griffith JF, Wong P. Ultrasound-guided synovial biopsy. *The British journal of radiology*. 2015;89(1057):20150363.
6. Schoeniger R, Naudie DD, Siebenrock KA, Trousdale RT, Ganz R. Modified complete synovectomy prevents recurrence in synovial chondromatosis of the hip. *Clinical Orthopaedics and Related Research*. 2006;451:195-200.
7. Ganz R, Gill T, Gautier E, Ganz K, Krügel N, Berlemann

- U. Surgical dislocation of the adult hip: a technique with full access to the femoral head and acetabulum without the risk of avascular necrosis. *The Journal of bone and joint surgery British volume.* 2001;83(8):1119-24.
8. Jamshidi K, Mirkazemi M, Izanloo A, Mirzaei A. Locking plate and fibular strut-graft augmentation in the reconstruction of unicameral bone cyst of proximal femur in the paediatric population. *International orthopaedics.* 2018;42(1):169-74.
 9. Jamshidi K, Shirazi MR, Bagherifard A, Mirzaei A. Curettage, phenolization, and cementation in paediatric Ewing's sarcoma with a complete radiological response to neoadjuvant chemotherapy. *International orthopaedics.* 2019;43(2):467-73.
 10. Jamshidi K, Bahrabadi M, Mirzaei A. Long-term results of osteoarticular allograft reconstruction in children with distal femoral bone tumors. *Archives of Bone and Joint Surgery.* 2017;5(5):296.
 11. Marchie A, Panuncialman I, McCarthy JC. Efficacy of hip arthroscopy in the management of synovial chondromatosis. *The American journal of sports medicine.* 2011;39(1_suppl):126-31.
 12. Salzler MJ, Lin A, Miller CD, Herold S, Irrgang JJ, Harner CD. Complications after arthroscopic knee surgery. *The American journal of sports medicine.* 2014;42(2):292-6.
 13. Kempson R, Fletcher C, Evans H, Hendrickson M, Sibley R. Synovial tumors. *Tumors of the Soft Tissue, Atlas of tumor Pathology Third Series.* 2001;30:387-94.
 14. Marin F, Lasbleiz J, Albert J, Askri A, Werner-Leyval S, Duval H, et al. Synovial biopsy under US guidance: technical considerations and results. *Journal de radiologie.* 2006;87(5):561-5.
 15. Koski JM, Helle M. Ultrasound guided synovial biopsy using portal and forceps. *Annals of the rheumatic diseases.* 2005;64(6):926-9.