

**RESEARCH ARTICLE**

# Modified Camitz versus BRAND Procedures for the Treatment of Severe Carpal Tunnel Syndrome: A Comparative Trial Study

Mohammad Dehghani, MD<sup>1</sup>; Behrooz Fadaei, MD<sup>1</sup>; Shirvan Rastegar, MD<sup>1</sup>; Abolghasem Zarezadeh, MD<sup>1</sup>; Keyvan Ghadimi, MD<sup>2</sup>; Roham Nikkhah, MD<sup>2</sup>; Sepehr Eslami, MD<sup>1</sup>

*Research performed at Isfahan University of Medical Sciences, Isfahan, Iran*

*Received: 01 January 2019*

*Accepted: 08 October 2019*

**Abstract**

**Background:** Carpal tunnel syndrome (CTS) is characterized by complications such as pain, paresthesia, and numbness in the fingers. There are some surgical therapies for the management of severe carpal tunnel, but differences exist between the treatments available for creating the opposition. The current study was conducted to compare the effect of modified Camitz and BRAND techniques on thumb opposition in patients with severe CTS.

**Methods:** A total of 40 patients with severe CTS who were candidates for opponensplasty were enrolled in this clinical trial study at Alzahra and Kashani hospitals, Isfahan, Iran, from 2014 to 2018. The patients were divided into two groups of modified Camitz and BRAND. Quick DASH-9 and Kapandji scores as well as pulp and side pinch and pronation angle were assessed before and after the surgeries.

**Results:** Quick DASH-9 score, Kapandji score, pulp and side pinch and pronation angle significantly improved post-operatively. But, no significant differences were seen in the mentioned variables between both groups pre and post-operative ( $P > 0.05$ , for all the studied variables). No postsurgical complications were seen in any of the groups.

**Conclusion:** The findings of the present study demonstrated that, both Modified Camitz and BRAND techniques are effective and safe techniques, yielding high improvements, but no serious complications. Both techniques can be considered for treatment of patients with severe CTS.

**Level of evidence:** II

**Keywords:** BRAND, Carpal tunnel syndrome, Modified Camitz, Opposition

**Introduction**

The median nerve and flexor tendons of the fingers pass through a space formed by hand structural components and flexor retinaculum of the wrist, interactively making a section called carpal tunnel. Anatomical anomalies, inflammations or non-inflammatory fibrosis of the sub-synovial connective tissue surrounding the flexor tendons may cause increased pressure around the components of the carpal

tunnel and consequently developing a set of symptoms such as pain, paresthesia, and numbness in the fingers generally known as carpal tunnel syndrome (CTS) (1, 2). Along with the sensory symptoms mentioned above, motor symptoms such as abductor pollicis brevis and opponens pollicis deficits are also observed due to the increased pressure on the median nerve, resulting in the disruption of hand movements such as opposition and

**Corresponding Author:** Behrooz Fadaei, Department of Orthopedic, School of Medicine, Isfahan University of Medical Sciences, Isfahan, Iran  
Email: drbfadaei@yahoo.com



THE ONLINE VERSION OF THIS ARTICLE  
ABJS.MUMS.AC.IR

circumduction caused by CTS. Accordingly, conservative treatment is suggested if the symptoms are not severe, but, if the numbness, pain, and motor deficits persist and the patient feels uncomfortable, then surgery is recommended. Diagnosis is usually done based on the clinical symptoms and electrodiagnostic tests are used to confirm the diagnosis. The primary surgical methods include open release and endoscopic surgery of the carpal tunnel. Both approaches have been studied in several studies and have shown similar outcomes. Although the endoscopic technique has been shown to be associated with fewer side effects, there is limited evidence in this regard (3). For performing opponensplasty, different methods have been proposed such as Camitz surgery, Riordan opponensplasty, Extensor Indicis Proprius transfer, and Huber opponensplasty (4-7). Flexor Digitorum Superficialis (FDS) tendon opponensplasty is the standard technique for the treatment of median nerve injuries (8). Through Camitz opponensplasty, the insertion of the palmaris longus tendon along with palmar aponeurosis is transferred into the insertion of abductor pollicis brevis to promote thumb opposition (9). In this technique, creating the longitudinal axis of the pull on the base of the thumb in line with the forearm enhances the opposition. However, this transferred tendon is presumed to be too radial to the ideal axis and may not provide a proper flexion and pronation; therefore modified Camitz surgery was developed, benefiting from the use of a pulley at the radial side of the dissected flexor retinaculum (10). On the other hand, the FDS tendon transfer opponensplasty method is used to treat hypoplasia of the thumb and is commonly used from FDS to the ring finger (11). This technique is based on a combination of Brand's transfer and Fritsch's technique (12). Both methods have advantages and disadvantages discussed in various systematic review studies separately; however, there is no comparative study on these methods. The present study was designed to compare the Modified Camitz with FDS Opponensplasty.

## Materials and Methods

### Patients

This clinical trial study was carried out at Alzahra and Kashani hospitals, Isfahan, Iran, from 2014 to 2018. The study was approved by the Ethics Committee of Isfahan University of Medical Sciences (IR.MUI.REC.1395.3.594). A total of 40 patients with severe CTS who had the indications for opponensplasty surgery were enrolled in the study. CTS was diagnosed for all patients according to the chief complaints such as pain or numbness associated with median nerve, physical examinations, electromyogram (EMG), and nerve conduction study (NCS). All adult patients above 18 years old with CTS and thenar atrophy and Kapandji scores less than or equal to 2 were included in the study. However, the patients with median nerve disturbances caused by other reasons such as trauma; patients with a history of carpal tunnel surgery; patients who had not been regularly followed until eight months; and those who needed re-operation were not included in the study. The demographic and clinical information of the patients such as age, gender, involved side, and the duration of symptoms were recorded. The

patients were divided into two groups of either Camitz or BRAND according to the surgeon's opinion. The patients in the Camitz group underwent operation with modified Camitz technique, and the patients in the BRAND group underwent FDS transfer of 4th finger (ring finger) using BRAND technique.

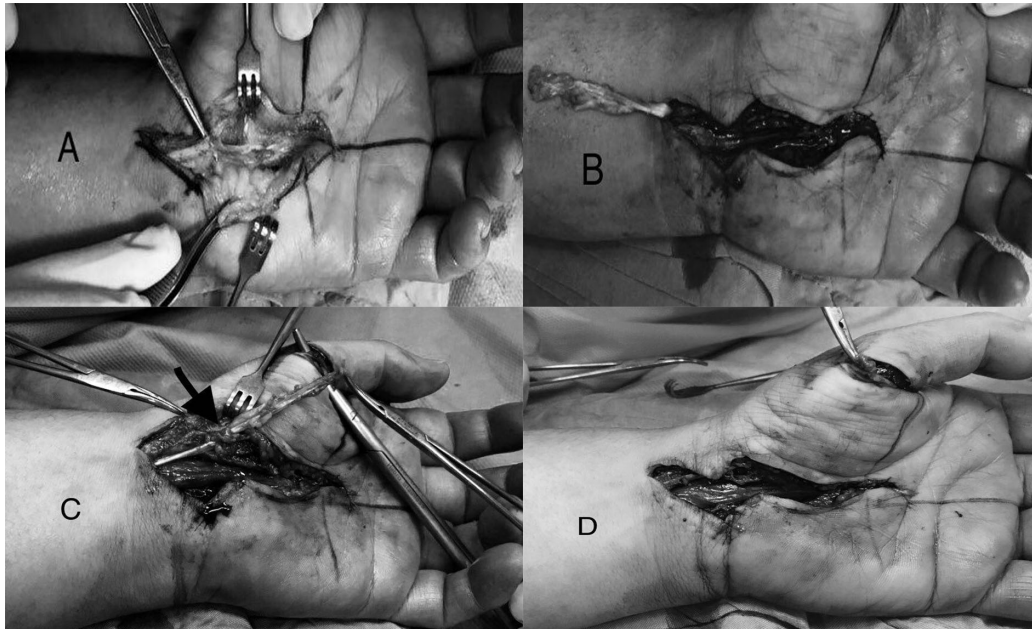
### Surgical Techniques

All patients underwent general anesthesia according to the standard protocols. Simultaneous modified Camitz technique was done according to the study by Kato et al. (10). Initially, a longitudinal cut was done from the proximal palmar crease to the proximal of the thenar area and extended to the wrist. Then, the PL tendon was disconnected from the attachment site with palmar aponeurosis (for sufficient tendon length). The flexor retinaculum was cut 1 cm of the ulnar to the Abductor Pollicis Brevis (APB), and in the remainder of the radial side, a small cut was created as proximal pulley. The PL tendon was transmitted from the undersurface of the flexor retinaculum and passed internally through the pulley (it is noteworthy that the pulley must be placed in a line so that pisiform is connected to the first metacarpophalangeal (MCP)). Then, an incision was made on the surface dorso-radial of the MCP of the thumb and the PL tendon was passed and connected to the APB connection. The brush surface was then repaired using nylon to prevent rupture [Figure 1].

FDS transfer of the 4th finger (BRAND technique) was performed for patients in the BRAND group. In this method, a small mid-lateral incision was made on the midpoint of the 4<sup>th</sup> finger near the interdigital joint. Then, the FDS tendon binding site was determined and removed and a proximal incision of about 5 cm was made on the flexor wrist and the FDS tendon was extracted from it. A small ~6 mm incision was made to insert the distal of pisiform bone, and then the incision was converted to the left side of the superficial fibrous tissue to fat tissue into the wound (where there is a tunnel extending proximal consisting of ulnar nerve branches). The FDS tendon was passed through this tunnel, then an incision was made on the posterior surface of the thumb (it could be seen on the metacarpophalangeal joint and the attachment place of the APB tendons and the extensor pollicis longus (EPL)). The incision was continued from the radial lateral to the volar surface. Then, one head of the FDS was attached in the EPL and APB, and the other one was enclosed in the proximal and distal of the interphalangeal joint (13).

### Assessments

The assessment tools for data collection were the Quick dash-9 questionnaire, Kapandji score, the pulp and side pinch strengths, and the pronation angle. All assessments were done by an orthopedic surgeon. These assessments were performed before and 3 and 8 months after the operation. The Quick dash-9 questionnaire included 9 items in which each item is scored between 0 and 4, and the total score is between 0 and 36. These items were designed to assess the fine and gross activities, pain and weakness in the shoulder, hand, or arm (14, 15). Kapandji score is a tool used for evaluation of the thumb opposition depending on the place of touching the thumb



**Figure 1.** A Surgical technique for modified Camitz opponensplasty; A: a longitudinal incision made from the proximal palmar crease to the proximal of the wrist, then the PL tendon was exposed. B: the PL tendon was detached and reflected proximally, and the carpal tunnel was released. C: the PL tendon was released through the hole which made on the radial surface of flexor retinaculum (the pulley made in the line which pisiform connect MCP). D: transferred tendon sutured to the site which APB inserted.

and ranges between 0 and 10 (16). The strength of pulp and side pinch were calculated by Pinch Dynamometer (manufactured by Jamar® company, PO Box 1500 White Plains, NY 10602, USA) based on pound unit. The pronation angle of the thumb as an angle between the nail axis of the thumb and the index finger was also calculated.

All patients were asked to wear the special splint for their hands (45 degrees of palmar and abducted) for 3-4 weeks. The opposition movement was performed for patients after the surgery. Physiotherapy was suggested after removing the splint.

#### Statistics

All data were analyzed in the SPSS software version 16 and presented as mean±SD or frequency (percentage). Independent Samples T-test and Mann-Whitney U test

were used to compare the quantitative data in the groups (Camitz or BRAND). The Chi-Square test was used to analyze the qualitative data in the groups. ANOVA along with Repeated Measure T-test were used to compare the changes in the results obtained from the tools at different time points (pre and post -operative). A  $P < 0.05$  was considered as statistically significant.

#### Results

In this study, the patients were divided into two groups of modified Camitz (including 6 males and 14 females, with mean age of  $39.55 \pm 5.15$  years old) and BRAND (including 8 males and 12 females, with mean age of  $38.60 \pm 5.01$  years old). There were no significant differences in the age, gender, involved side and duration of symptoms between the groups ( $P > 0.05$ ) (demographic information is presented in Table 1).

**Table 1. Demographic and clinical data of both groups**

Variables	Modified Camitz	BRAND	P-value
N	20	20	-
Gender	6 M/14 F	8 M/ 12 F	0.50*
Age	$39.55 \pm 5.15$	$38.60 \pm 5.01$	0.88**
involved side	12 right/ 8 left	9 right/ 11 left	0.34*
duration of symptoms	$8.01 \pm 2.24$	$8.66 \pm 1.45$	0.37**

\*Chi Square test, \*\*Independent t test

**Table 2. Assessment tools in groups in pre and post operation**

Tools (mean±SD)		Modified Camitz	BRAND	P-value
Quick dash-9 score	Before	31.80±2.06	31.01±1.91	0.18
	After 3 m	22.10±2.10	22.85±2.1	0.31
	After 8 m	15.01±2.23	16.15±2.70	0.20
	P-value	0.0001>	0.0001>	
Kapandji score	Before	3.50±0.51	3.45±0.51	0.75
	After 3 m	5.70±0.73	5.80±0.89	0.68
	After 8 m	7.47±0.96	7.65±0.93	0.8
	P-value	0.0001>	0.0001>	
pulp pinch (pound)	Before	14.41±0.79	14.63±1.07	0.49
	After 3 m	18.67±1.01	19.40±1.23	0.80
	After 8 m	20.62±0.88	21.40±1.43	0.09
	P-value	0.0001>	0.0001>	
side pinch (pound)	Before	16.73±1.04	16.62±1.29	0.71
	After 3 m	19.61±1.32	20.20±1.28	0.12
	After 8 m	23.27±1.11	23.50±1.67	0.80
	P-value	0.0001>	0.0001>	
pronation angle (degree)	Before	25.01±1.12	25.59±1.14	0.11
	After 3 m	35.40±1.87	36.15±2.92	0.09
	After 8 m	44.42±2.16	44.25±2.76	0.95
	P-value	0.0001>	0.0001>	

The ANOVA and repeated measure T-test showed a significant decrease in the Quick dash-9 score, and a significant increase in the Kapandji score, the strength of pulp pinch, the strength of side pinch and pronation angle pre-operation compared to post-operation ( $P<0.0001$ , for all the studied variables). However, no significant differences was seen in the Quick dash-9 score, Kapandji score, the strength of pulp pinch, strength of side pinch, and pronation angle between the two groups before and 3 and 8 months after operation [Table 2]. No complications were seen in any of the two groups after the surgery.

### Discussion

The findings of the present study revealed that, applying both modified Camitz and FDS opponensplasty methods were associated with improved outcomes of the patients after surgery. The Quick dash-9 score and pronation angle were found to be slightly higher in the modified Camitz group, whereas Kapandji score as well as the pulp and side pinch improved slightly in FDS opponensplasty group compared to Modified Camitz group. None of the above differences were statistically significant between the study groups, suggesting that the outcomes of both methods were similar after the surgery.

On the other hand, Camitz technique is not capable to provide a good pronation of thumb because of the radial axis of the transferred tendon. Also, bowstringing of the transferred tendon, a risk of tendinous adhesion and iatrogenic injury associated with the incision site has been reported as another potential complication of Camitz opponensplasty (10, 17-19). Since none of these complications were seen in the current study and their occurrence was not significant compared to the advantages in previous studies, it could be concluded that modified Camitz may be used as an effective technique of opponensplasty. Nobuta et al. studied the effectiveness of a combined surgery consisting of ppen carpal tunnel release (OCTR) and modified Camitz opponensplasty in patients with severe CTS (20). Their findings revealed that, pulp pinch strength was restored effectively after Camitz opponensplasty. These findings are in line with the results obtained in the current study. Kato et al. also evaluated the outcomes of modified Camitz opponensplasty in patients with CTS (10). Their results revealed that, side and pulp pinch, Kapandji and DASH scores, and thumb pronation angle improved significantly after the surgery. Modified Camitz showed better results compared to conventional Camtiz oppomemsplasty,

which is similar to the findings of the present study. Wan et al. showed that, Camitz surgery following OCTR was associated with better pinch power, grip power, hand functions, and Kapandji score (21). Similarly, Nobuta et al did not investigate only on OCTR group. In their study, the mean age of subjects was equal to 70, whereas younger adults were evaluated in our study. However, their findings were similar to other studies evaluating the older patient and also in line with the findings of the present study (22, 23). Hattori et al. also demonstrated that, DASH score and pinch function significantly improved after modified Camitz surgery (4). Although, the recovery pronation of hand was not assessed in their study but their results are similar to the findings of the current study. It should be noted that applying OCTR alone has been shown to be effective in recovering thumb opposition in long-term follow-up (20, 24, 25). However, Camitz can be performed in order to achieve an early improvement in thumb pinch. The accessibility of the palmaris longus tendon through the use of OCTR along with the expandability characteristics and synergistic function of the palmaris longus make the Camitz as an effective technique in which the hand functions are not disturbed (10, 26). Along with these advantages, the short operation time, low postsurgical morbidity rate, and the possibility of implementing regional anesthesia are some other benefits of Camitz opponensplasty (10, 19). Kraker et al. evaluated the outcomes of flexor digitorum superficialis opponensplasty in the treatment of type II and IIIA thumb hypoplasia. Their results indicated that the opposition, grip, pinch, tripod, and key pinch strengths as well as Kapandji scores generally improved after the surgery (27). Their findings were comparative to the results of the studies used abductor digiti minimi in the treatment of thumb hypoplasia, highlighting the need to compare the two techniques with each other in further studies. Although they did not include the patients with CTS, their results are similar to our findings. Lee et al. also revealed that although key-pinch and hand grip did not improve significantly, the DASH and Kapandji scores showed better results after the surgery (28). In this study, the compound muscle action potential was absent in all patients and severe atrophies were present in all of them; however, postoperative outcomes of their patients were similar to the findings of the current study, suggesting the usefulness of FDS opponensplasty in the treatment of CTS. Unlike Camitz opponensplasty, rehabilitation

complications such as tendon pull-out and adhesions are more common in FDS opponensplasty (11). Also, surgical complications may occur in both methods if techniques are done with errors, like inaccurate pulley reconstruction. These complications were not seen in the current study and can be prevented if the operation is done accurately and postoperative cares and follow-ups such as immobilization are implemented. Therefore, both FDS tendon transfer and modified Camitz opponensplasty can be used as effective methods without any significant complications.

The Comitz method and FDS opponensplasty were found to be effective and safe, yielding high improvements for the patients with severe CTS. Also, in patients with CTS with no possibility to apply the BRAND technique, the Camitz method can be used interchangeably. Further studies should include the only OCTR groups and long-term follow-ups to determine the effects of each method accurately.

#### Limitations

There were some limitations in the present study. First, the number of the study subjects was small. Second, the results of the electrophysiological and postoperative nerve conduction examinations were not compared with the preoperative period. Third, the results of the follow-up period were assessed till 8 months after the surgery, despite of other similar studies, in which more extended periods were evaluated. Fourth, the only OCTR group was not assessed in this study to investigate whether the OCTR alone is enough for treatment of CTS or not.

Mohammad Dehghani MD<sup>1</sup>  
Behrooz Fadaei MD<sup>1</sup>  
Shirvan Rastegar MD<sup>1</sup>  
Abolghasem Zarezadeh MD<sup>1</sup>  
Keyvan Ghadimi MD<sup>2</sup>  
Roham Nikkhah MD<sup>2</sup>  
Sepehr Eslami MD<sup>1</sup>

1 Department of Orthopedic, School of Medicine, Isfahan University of Medical Sciences, Isfahan, Iran  
2 School of Medicine, Isfahan University of Medical Sciences, Isfahan, Iran

#### References

1. Bland JD. Carpal tunnel syndrome. *Curr Opin Neurol*. 2005; 18(5):581-5.
2. Abbasi S, Ghasemi M, Khorvash F, Ghadimi K, Madahian P. Evaluation of clinical symptoms in patients with different severities of carpal tunnel syndrome. *Casp J Neurol Sci*. 2017; 3(10):143-50.
3. Vasiliadis HS, Nikolakopoulou A, Shrier I, Lunn MP, Brassington R, Scholten RJ, et al. Endoscopic and open release similarly safe for the treatment of carpal tunnel syndrome. A systematic review and meta-analysis. *PLoS One*. 2015; 10(12):e0143683.
4. Hattori Y, Doi K, Sakamoto S, Kumar K, Koide S. Camitz tendon transfer using flexor retinaculum as a pulley in advanced carpal tunnel syndrome. *J Hand Surg Am*. 2014; 39(12):2454-9.
5. Skie MC, Parent T, Mudge K, Dai Q. Kinematic

- analysis of six different insertion sites for FDS opponensplasty. *Hand*. 2010; 5(3):261-6.
6. Moriya K, Yoshizu T, Maki Y. Immediate thumb opposition following extensor indicis proprius opponensplasty using the wide-awake approach. *Plast Surg Case Stud*. 2016; 2(2):27-30.
  7. de Roode CP, James MA, McCarroll HR Jr. Abductor digit minimi opponensplasty: technique, modifications, and measurement of opposition. *Tech Hand Up Extrem Surg*. 2010; 14(1):51-3.
  8. Al-Qattan MM. Extensor indicis proprius opponensplasty for isolated traumatic low median nerve palsy: a case series. *Can J Plast Surg*. 2012; 20(4):255-7.
  9. Rymer B, Thomas PB. The Camitz transfer and its modifications: a review. *J Hand Surg Eur Vol*. 2016; 41(6):632-7.
  10. Kato N, Yoshizawa T, Sakai H. Simultaneous modified Camitz opponensplasty using a pulley at the radial side of the flexor retinaculum in severe carpal tunnel syndrome. *J Hand Surg Eur Vol*. 2014; 39(6):632-6.
  11. Kozin SH, Ezaki M. Flexor digitorum superficialis opponensplasty with ulnar collateral ligament reconstruction for thumb deficiency. *Tech Hand Up Extrem Surg*. 2010; 14(1):46-50.
  12. Anderson GA, Lee V, Sundararaj GD. Opponensplasty by extensor indicis and flexor digitorum superficialis tendon transfer. *J Hand Surg Br*. 1992; 17(6):611-4.
  13. Sammer DM, Chung KC. Tendon transfers part II: transfers for ulnar nerve palsy and median nerve palsy. *Plast Reconstr Surg*. 2009; 124(3):212e-21e.
  14. Wong JY, Fung BK, Chu MM, Chan RK. The use of disabilities of the arm, shoulder, and hand questionnaire in rehabilitation after acute traumatic hand injuries. *J Hand Ther*. 2007; 20(1):49-55.
  15. Ebrahimzadeh MH, Moradi A, Vahedi E, Kachooei AR, Birjandinejad A. Validity and reliability of the persian version of shortened disabilities of the arm, shoulder and hand questionnaire (Quick-DASH). *Int J Prev Med*. 2015; 6(1):59.
  16. Kapandji A. Clinical test of apposition and counter-apposition of the thumb. *Ann Chir Main*. 1986; 5(1):67-73.
  17. Baluch N, Borschel GH. Use of adjunctive palmaris longus abductorplasty (Camitz) tendon transfer in pediatric median nerve injury. *J Plast Reconstr Aesthet Surg*. 2013; 66(5):726-8.
  18. Park IJ, Kim HM, Lee SU, Lee JY, Jeong C. Opponensplasty using palmaris longus tendon and flexor retinaculum pulley in patients with severe carpal tunnel syndrome. *Arch Orthop Trauma Surg*. 2010; 130(7):829-34.
  19. Naeem R, Lahiri A. Modified Camitz opponensplasty for severe thenar wasting secondary to carpal tunnel syndrome: case series. *J Hand Surg Am*. 2013; 38(4):795-8.
  20. Nobuta S, Sato K, Itoi E. Effects of modified camitz opponensplasty to restore thumb opposition for severe carpal tunnel syndrome. *Int J Phys Med Rehabil*. 2017; 5(444):2.
  21. Wan SH, Wong TC, Yip TH, Ip FK. Clinical experience of open carpal tunnel release and Camitz operation in elderly Chinese patients. *Hong Kong Med J*. 2007; 13(5):348-52.
  22. Terrono AL, Rose JH, Mulroy J, Millender LH. Camitz palmaris longus abductorplasty for severe thenar atrophy secondary to carpal tunnel syndrome. *J Hand Surg Am*. 1993; 18(2):204-6.
  23. Foucher G, Malizos C, Sammut D, Braun FM, Michon J. Primary palmaris longus transfer as an opponensplasty in carpal tunnel release: a series of 73 cases. *J Hand Surg Br*. 1991; 16(1):56-60.
  24. Mondelli M, Reale F, Padua R, Aprile I, Padua L. Clinical and neurophysiological outcome of surgery in extreme carpal tunnel syndrome. *Clin Neurophysiol*. 2001; 112(7):1237-42.
  25. Kamiya H, Kimura M, Hoshino S, Kobayashi M, Sonoo M. Prognosis of severe carpal tunnel syndrome with absent compound muscle action potential. *Muscle Nerve*. 2016; 54(3):427-31.
  26. Uemura T, Hidaka N, Nakamura H. Clinical outcome of carpal tunnel release with and without opposition transfer. *J Hand Surg Eur Vol*. 2010; 35(8):632-6.
  27. de Kraker M, Selles RW, Zuidam JM, Molenaar HM, Stam HJ, Hovius SE. Outcome of flexor digitorum superficialis opponensplasty for type II and IIIA thumb hypoplasia. *J Hand Surg Eur Vol*. 2016; 41(3):258-64.
  28. Lee YS, Cheon HJ, Kim YW, Woo SH. Primary ring flexor digitorum superficialis transfer with open carpal tunnel release in extreme carpal tunnel syndrome. *J Korean Soc Surg Hand*. 2017; 22(1):34-40.