

**CASE REPORT**

# Anterolateral Meniscomfemoral Ligament Associated with Ring-shaped Lateral Meniscus and Congenital Absence of Anterior Cruciate Ligament, Managed with Ligament Reconstruction

Mohammad Razi, MD<sup>1</sup>; Hamed Mazoochy, MD<sup>2</sup>; Elaheh Ziaei Ziabari, MSc<sup>3,4</sup>; Haleh Dadgostar, MD<sup>5</sup>; Alireza Askari, MD<sup>6,7</sup>; Peyman Arasteh, MD, MPH<sup>8,9</sup>

*Research performed at Atieh hospital, Tehran, Iran*

*Received: 11 April 2019*

*Accepted: 20 October 2019*

**Abstract**

A 24 year old otherwise healthy male presented with a chief complaint of giving way in the left knee. MRI reported complete anterior cruciate ligament (ACL) tearing. Arthroscopy showed ACL agenesis, ring-shaped lateral meniscus, and an anomalous thick band extending from the anterior horn of the lateral meniscus to the intercondylar notch of the lateral femoral condyle, which is known as the anterolateral meniscomfemoral ligament (MFL). The MFL was attached to the anatomic site of anteromedial bundle of ACL. ACL reconstruction surgery was performed using central 1/3 bone tendon bone graft.

Practitioners should be aware that ACL reconstruction in lateral meniscomfemoral ligament with associated ACL agenesis is a treatment option in which the preservation of MFL, as the stabilizer of anterior horn of lateral meniscus, should be considered during ACL reconstruction.

**Level of evidence:** V

**Keywords:** Anterior cruciate ligament agenesis, Anterolateral meniscomfemoral ligament, Ring lateral meniscus, Reconstruction

**Introduction**

Meniscomfemoral ligaments (MFL), first described by Poirier and Charpy in 1892, are collagen structures that cross the joint and attach to the bones (1). They are located between the femoral bone and the meniscus. According to their location (anterior or posterior) with regards to the posterior cruciate ligament (PCL), they are referred to as anterior MFL or Humphrey and posterior MFL or Wrisberg. The attachment of these structures to the anterior horn of the medial meniscus (anteromedial MFL) and the anterior horn of the lateral

meniscus (anterolateral MFL) are rare. Inhere the second case of anterolateral MFL associated with ring-shaped lateral meniscus and congenital absence of the anterior cruciate ligament in literature is reported, which was successfully managed using ACL reconstruction.

**Case presentation**

A 24 year old otherwise healthy male presented with a chief complaint of giving way in the left knee. In past medical history the patient had a history of soccer

**Corresponding Author:** Mohammad Razi, Department of Orthopedic Surgery, Rasoul Akram Hospital, Iran University of Medical Sciences, Tehran, Iran  
Email: mrazi@razimd.info



THE ONLINE VERSION OF THIS ARTICLE  
ABJS.MUMS.AC.IR

related injury 5 months prior to his last referral, during which he experienced pain and an episode of giving way. Since the time of injury, the patient mentioned few episodes of trivial giving-way which would resume immediately.

On physical examination, the lower limb alignment was normal. Both knees showed normal passive and active range of motion. The left knee had a two plus Lachman and two plus Pivot shift test compared to the contralateral knee. Knee examination showed no snapping or locking.

Radiography of the left knee showed no significant abnormality. Magnetic resonance imaging (MRI) (Siemens Sonata, Erlangen, Germany) of the left knee was done in a supine position. Multi-slice MRI study

reported complete ACL tearing [Figure 1].

The patient was scheduled for arthroscopic ACL reconstruction according to the MRI report and physical examination findings. Arthroscopic evaluation showed ACL agenesis, ring-shaped lateral meniscus, and an anomalous thick band extending from the anterior horn of the lateral femoral condyle, which is known as the anterior lateral MFL. The meniscus didn't have any tear or degenerative change except for a congenital anomaly of the lateral meniscus. The MFL was attached to the anatomic site of the anteromedial bundle of ACL. Moreover, the medial side of the tibial eminence was prominent (hump shape) and the lateral part was

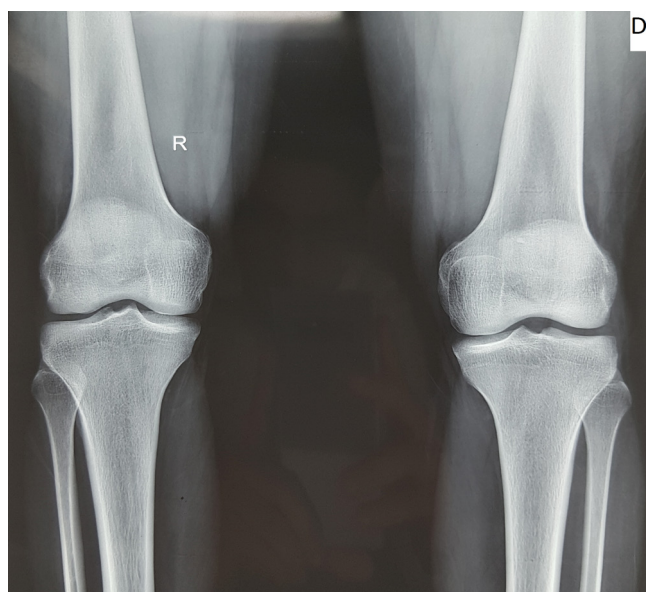
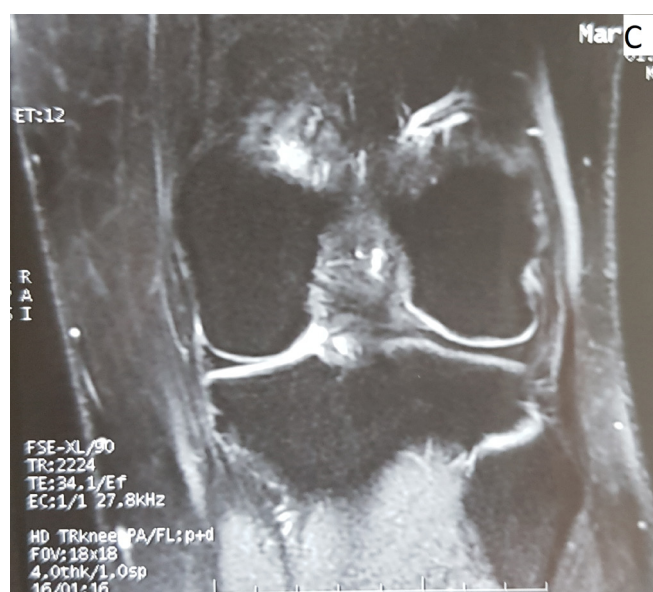
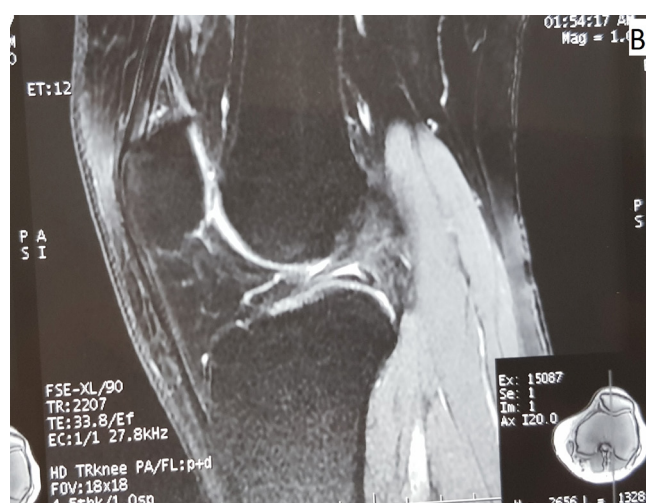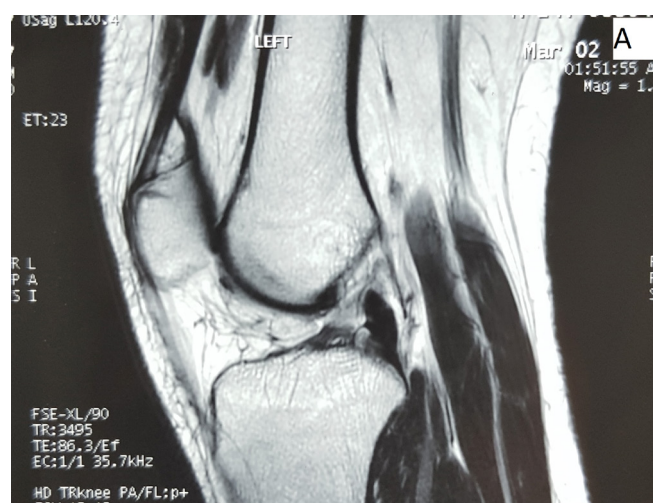
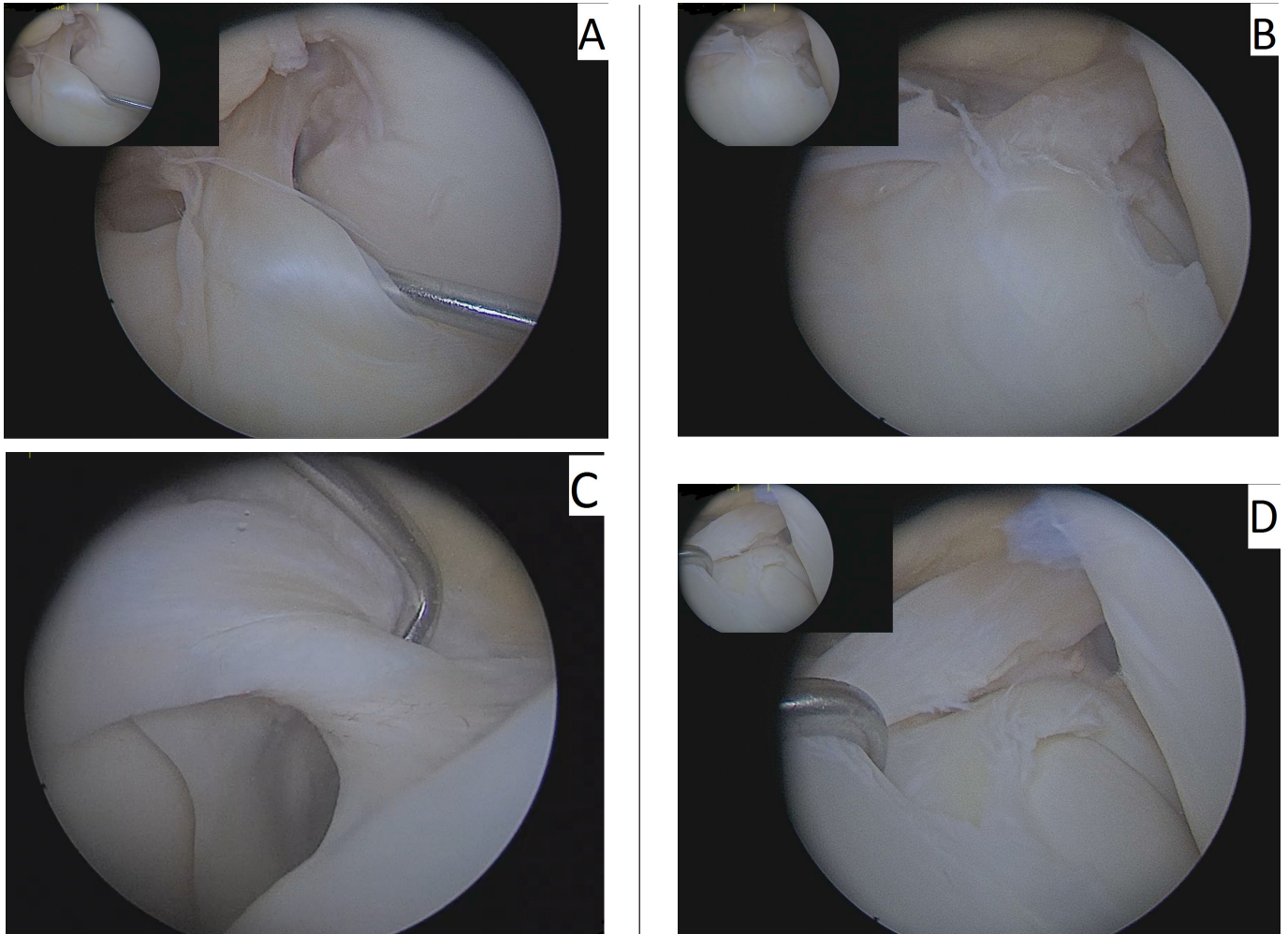


Figure 1. MRI and radiography of the knee.

Figure A and C show loss of anterior cruciate ligament; figure B shows the lateral meniscofemoral ligament which was noticed after surgery; figure D shows radiography of both knees, which shows no abnormality.



**Figure 2.** Arthroscopy images of the meniscofemoral ligament and ring lateral meniscus.

Figure A and B show two different views from the meniscofemoral ligament; figure C shows the meniscofemoral ligament which resembles the anterior cruciate ligament; figure D shows a ring-shaped lateral meniscus.

occupied by the MFL [Figure 2].

Considering the patient's complaint and findings in physical examination, ACL reconstruction surgery was planned. During ACL reconstruction the patello-femoral joint was shown to be intact. There was a loss of ACL or its remnants and the lateral meniscus anterior horn was extended up, simulating the ACL, and was attached to the femoral site of the ACL.

The central 1/3 bone tendon bone was harvested. Arthroscopic femoral and tibial tunnels were created in anatomic positions, preserving the anterior extension of the lateral meniscus. The graft was passed and fixed by bio interference screws. The ring shaped lateral meniscus and the anterolateral MFL were left intact [Figure 3].

Arthroscopy of the patient is shown in supplement file 1.

At 8 months of follow-up the patient showed limitation in range of motion ( $8^{\circ}$  to  $120^{\circ}$ ) and at 10 months he continued to show limitation in range of motion ( $3^{\circ}$  to

$125^{\circ}$ ) and arthroscopic arthrofibrosis was planned. The patient did not refer for the planned treatment and at 14 months of postoperative follow-up he showed full range of motion as well as normal Pivot and Lachman tests. Moreover, MRI and radiography of the knee were unremarkable for any abnormalities.

### Discussion

Some previous literature have reported the existence of a connecting ligament from the medial meniscus to the intercondylar notch as an anteromedial meniscofemoral ligament (2-6). To the best of the authors' knowledge only two cases of anterior lateral meniscofemoral ligament have been reported to date, only one of which had an associated agenesis of ACL (7, 8).

Congenital absence of ACL is an extremely rare finding as well, with an estimated incidence of 0.0017 in every 1000 births, and is more often considered to be an

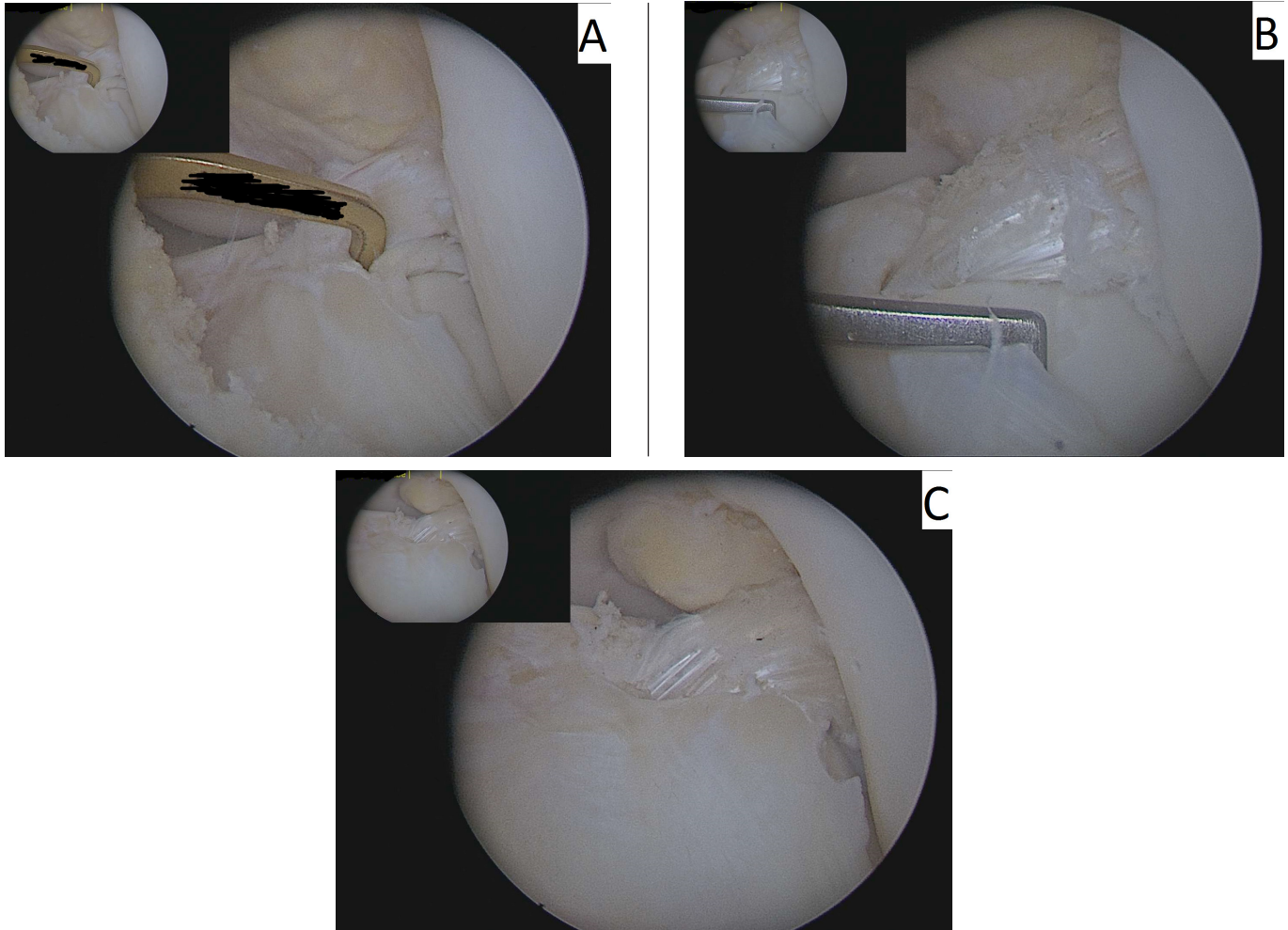


Figure 3. Displays anterior cruciate reconstruction of the involved knee.

associated anomaly with other abnormalities in the knee (9, 10).

Our case had a combination of anterolateral meniscofemoral ligament, agenesis of ACL, and a ring shaped lateral meniscus.

Regarding the treatment of choice in our patient, much controversy exists on the best treatment modality in patients with congenital ACL aplasia and agenesis (11). In a recent report of a case of anterolateral meniscofemoral ligament by Kim et al. in 2016, strengthening exercises and activity modification was chosen as their treatment modality for the patient, as their patient didn't have an associated ACL agenesis (7). In a report by Silva and Sampaio who had a similar patient with ACL agenesis and anterolateral meniscofemoral ligament, they did not report the therapeutic approach in their patient (8). Some previous studies have proposed that the absence of ACL is well tolerated among patients and have advised against the manipulation of the cruciate ligament (12).

Gabos et al., reported postoperative results in four cases of congenital ACL agenesis (13). All patients underwent

reconstruction and they found that patients showed improvement in stability and function in both knees. Although some authors have reported that the natural absence of the ACL would result in the morphological adaptation of the knee and considering that the articular surfaces may be abnormal in these patients, some have concluded that reconstructive surgery may render inconsistent results (14, 15). For the first time, we showed that in our case with congenital absence of ACL and associated anterior lateral MFL, ACL reconstruction had promising postoperative results during 14 months of follow-up. Considering that the resulting instability from ACL agenesis may ultimately lead to meniscus and cartilaginous lesions, ACL reconstruction would seem the appropriate choice of treatment (11, 16). Our patient had a history of trauma; was symptomatic; and had instability in physical examination; thus, ACL reconstructive surgery was done for the him.

Practitioners should be aware that ACL reconstruction in lateral meniscofemoral ligament with associated ACL agenesis is a treatment option which should be

considered and the preservation of MFL, as the stabilizer of the anterior horn of lateral meniscus, during ACL reconstruction is a good treatment option.

**Conflict of interest:** Authors have no conflict of interest to declare regarding the manuscript.

### Acknowledgements

Authors did not receive any funding from any private or governmental organizations.

Mohammad Razi MD<sup>1</sup>  
Hamed Mazoochy MD<sup>2</sup>  
Elaheh Ziaei Ziabari MSc<sup>3,4</sup>  
Haleh Dadgostar MD<sup>5</sup>

Alireza Askari MD<sup>6,7</sup>

Peyman Arasteh MD MPH<sup>8,9</sup>

1 Department of Orthopedic Surgery, Rasoul Akram Hospital, Iran University of Medical Sciences, Tehran, Iran

2 Department of Orthopaedic Surgery, Atieh private Hospital, Tehran, Iran

3 Harvard Medical School, Boston, USA

4 Iran University of Science and Technology, Tehran, Iran

5 Sports Medicine Department, Rasoul Akram Hospital, Iran University of Medical Sciences, Tehran, Iran

6 Bone and Joint Reconstruction Research Center, Shafa Orthopedic Hospital, Iran University of Medical Sciences, Tehran, Iran

7 Department of Orthopedics, School of Medicine, Shiraz University of Medical Sciences, Shiraz, Iran

8 Noncommunicable Diseases Research Center, Fasa University of Medical Sciences, Fasa, Iran

9 Department of MPH, Shiraz University of Medical Sciences, Shiraz, Iran

### References

- Heller L, Langman J. The menisco-femoral ligaments of the human knee. *J Bone Joint Surg Br.* 1964; 46(2):307-13.
- Arjun S, Takahashi S, Tang Y, Nakane N, Yonemitsu H. MR appearance of anomalous insertion of the medial meniscus: a case report. *Acta Radiol.* 1998; 39(5):554-6.
- Jung YB, Yum JK, Bae YJ, Song KS. Anomalous insertion of the medial menisci. *Arthroscopy.* 1998; 14(5):505-7.
- Shea KG, Westin CM, West J. Anomalous insertion of the medial meniscus of the knee. A case report. *J Bone Joint Surg Am.* 1995; 77(12):1894-6.
- Soejima T, Murakami H, Tanaka N, Nagata K. Anteromedial meniscofemoral ligament. *Arthroscopy.* 2003; 19(1):90-5.
- Hamada M, Miyama T, Nagayama Y, Shino K. Repair of a torn medial meniscus with an anteromedial meniscofemoral ligament in an anterior cruciate ligament-injured knee. *Knee Surg Sports Traumatol Arthrosc.* 2011; 19(5):826-8.
- Kim YM, Joo YB, Yeon KW, Lee KY. Anterolateral meniscofemoral ligament of the lateral meniscus. *Knee Surg Relat Res.* 2016; 28(3):245-8.
- Silva A, Sampaio R. Anterior lateral meniscofemoral ligament with congenital absence of the ACL. *Knee Surg Sports Traumatol Arthrosc.* 2011; 19(2):192-5.
- Manner HM, Radler C, Ganger R, Grill F. Dysplasia of the cruciate ligaments: radiographic assessment and classification. *J Bone Joint Surg Am.* 2006; 88(1):130-7.
- Rayar M, Bouillis J, Fraisse B, Marleix S, Chapuis M, Violas P. Discoid meniscus associated with agenesis of the anterior cruciate ligament in an 8-year-old child. *Orthop Traumatol Surg Res.* 2011; 97(8):874-6.
- Davanzo D, Fornaciari P, Barbier G, Maniglio M, Petek D. Review and long-term outcomes of cruciate ligament reconstruction versus conservative treatment in siblings with congenital anterior cruciate ligament aplasia. *Case Rep Orthop.* 2017; 2017:1636578.
- Carlioz H. Description and natural history of severe aplasia of the lower extremities. *Chir Pediatr.* 1978; 19(5-6):306-21.
- Gabos PG, El Rassi G, Pahys J. Knee reconstruction in syndromes with congenital absence of the anterior cruciate ligament. *J Pediatr Orthop.* 2005; 25(2):210-4.
- Dejour H, Neyret P, Eberhard P, Walch G. Bilateral congenital absence of the anterior cruciate ligament and the internal menisci of the knee. A case report. *Rev Chir Orthop Reparatrice Appar Mot.* 1990; 76(5):329-32.
- Carlioz H. Description and natural history of severe aplasia of the lower extremities. *Chir Pediatr.* 1978; 19(5-6):306-21.
- Aichroth PM, Patel DV, Zorrilla P. The natural history and treatment of rupture of the anterior cruciate ligament in children and adolescents: a prospective review. *J Bone Joint Surg Br.* 2002; 84(1):38-41.