

**RESEARCH ARTICLE**

# Chronic Long Head Biceps Tendinitis Secondary to Anomalous Origins in Young Patients: A Case Series

Soheil Sabzevari, MD; Mostafa Khalilipour Roudi, MD; Jay Kalawadia, MD; Albert Lin, MD

*Research performed at the University of Pittsburgh Medical Center, Pittsburgh, Pennsylvania, USA*

Received: 26 May 2019

Accepted: 30 September 2019

**Abstract**

**Background:** To describe a case series of young adult patients with isolated chronic proximal biceps tendinitis refractory to conservative care found to have anatomic long head biceps tendon (LHBT) origin variations who underwent arthroscopic-assisted subpectoral biceps tenodesis.

**Methods:** Patients were included in this retrospective case series if they met all the following criteria: 1) had an anomalous origin of the LHBT without any pre-operative or concurrent pathologies at the time of surgery, 2) had non-traumatic anterior shoulder pain refractory to conservative care for >6 months, 3) pain relief with ultrasound guided steroid injections into the bicipital tendon sheath, and 4) routine radiographs and MRI-arthrogram demonstrating no pathology. All patients underwent arthroscopic assisted mini-open subpectoral biceps tenodesis. Pre- and post-operative active range of motion (ROM), strength, visual analog scale (VAS) for pain, and subjective shoulder values (SSV) were evaluated. Statistical analysis was done using repeated measure ANOVA.

**Results:** Seven patients mean age of  $18.4 \pm 3.5$  years old were included in this study. Arthroscopic examination revealed anomalous origins of the LHBT in all patients with the following distribution: medial to superior labrum (x2), proximal insertion to the supraspinatus confluent with the superior labrum (x2), insertion into the superior capsular tissues at the rotator interval (x2), and bifid LHBT (x1). VAS score and SSV were significantly improved at 3 months ( $P < 0.001$  and  $= 0.024$  respectively) and final follow-up.

**Conclusion:** Anomalous origins of the LHBT may be a predisposing factor for chronic biceps tendinitis refractory to non-operative treatment in young adults. Biceps tenodesis seems to offer improvements in function and pain.

**Level of evidence:** IV

**Keywords:** Anomalous origins, Chronic, Long head biceps tendinitis

**Introduction**

The long head biceps tendon (LHBT) originates from the superior glenoid tubercle and superior labrum, passes obliquely through the glenohumeral joint, and bends as it enters the bicipital groove (1). This unique anatomy places it at high risk for inflammatory,

traumatic, and degenerative pathologies (2).

Anomalous variations of the LHBT origin have been described. Supernumerary heads and congenital absence of the tendon can be seen. Intra- and extra-articular origins, bifurcate origins with limbs to the rotator cable,

**Corresponding Author:** Albert Lin, Department of Orthopaedic Surgery, Division of Shoulder Surgery and Sports Medicine, University of Pittsburgh, UPMC Center for Sports, Pittsburgh, PA, USA  
Email: lina2@upmc.edu



THE ONLINE VERSION OF THIS ARTICLE  
ABJS.MUMS.AC.IR

medial to the supraglenoid tubercle, and/or rotator cuff have been described (3-7). The clinical implication of these variations is unknown. Some authors report these variations as an incidental finding while others believe they are a predisposing factor for shoulder instability and rotator cuff pathology (8-10).

The purpose of this study is to describe a case series of young adult patients with isolated chronic proximal biceps tendinitis refractory to conservative care found to have anatomic LHBT origin variations who underwent arthroscopic-assisted subpectoral biceps tenodesis. We hypothesize anomalous variations of the LHBT may be a predisposing factor for chronic refractory proximal biceps tendinitis.

### Materials and Methods

A retrospective case series was performed on seven young patients with anatomic variations of the LHBT origin who failed conservative care for isolated biceps tendinitis and underwent arthroscopic-assisted subpectoral biceps tenodesis from January 2014 to May 2017. Inclusion criteria included: non-traumatic anterior shoulder pain, bicipital groove tenderness, positive O'Brien's and Speed's signs, unremarkable radiographs and MR arthrogram, persistent symptoms after > 6 months of conservative treatment including physical therapy and anti-inflammatory treatment, and temporary relief following ultrasound guided steroid injection into the bicipital tendon sheath. Exclusion criteria included: positive impingement/instability/rotator cuff integrity tests on physical exam, concurrent pathology seen on diagnostic imaging.

All patients underwent arthroscopic biceps tenotomy with a mini-open subpectoral biceps tenodesis using a unicortical proximal biceps button (Arthrex, Naples, FL, USA).

A standardized post-operative rehabilitation protocol was followed with return to sport at 3-4 months after surgery. Active range of motion (ROM), strength at forward flexion and external rotation, visual analog scale (VAS) pain score, and subjective shoulder values (SSV) were evaluated at preoperative, 3 months, and final follow up. Muscle strength was assessed based on the Medical Research Council Muscle scale between 0 to 5 (11). Prior to start the study institutional review board approval was taken by the University of Pittsburgh (ID: XX).

Statistical analysis was done using SPSS (version 22.0, Armonk, NY: IBM Corp). Repeated measure analysis of variance (ANOVA), and Bonferroni post hoc analysis were used to assess the differences between the pre-and post-operative means. Quantitative variables were presented with mean and standard deviation and qualitative variables with percentage.  $P < 0.05$  was set as statistically significant.

### Results

1 male and 6 females, mean age  $18.4 \pm 3.5$  years old were enrolled in this study. The patients were participating in sports as following: basketball (two), volleyball (one), swimming (two), tennis (two). The mean follow-up was  $17 \pm 13$  months. No concomitant rotator cuff, cartilaginous, or labral pathology was identified in any patient. Arthroscopic evaluation revealed inflammation of the LHBT origin extending through the bicipital groove in all patients. Anomalous origins of the LHBT were found in all patients with the following distribution: medial to superior labrum (x2), proximal insertion to the supraspinatus confluent with the superior labrum (x2), insertion into the superior capsular tissues at the rotator interval just proximal to its insertion site on the superior labrum (x2), and bifid LHBT (x1) [Figure 1a; 1b]; [Figure 2a; 2b].

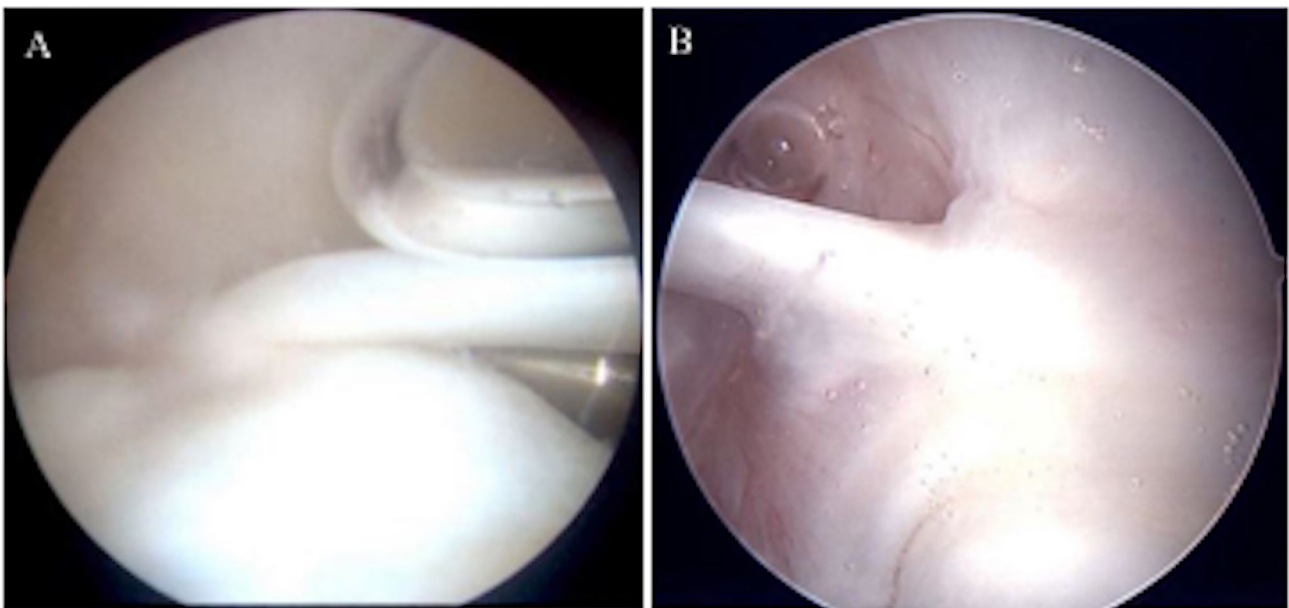


Figure 1. Intraoperative arthroscopic view of anomalous long head biceps tendon (LHBT) proximal insertions. a) medial insertion of LHBT and b) confluent LHBT with supraspinatus.

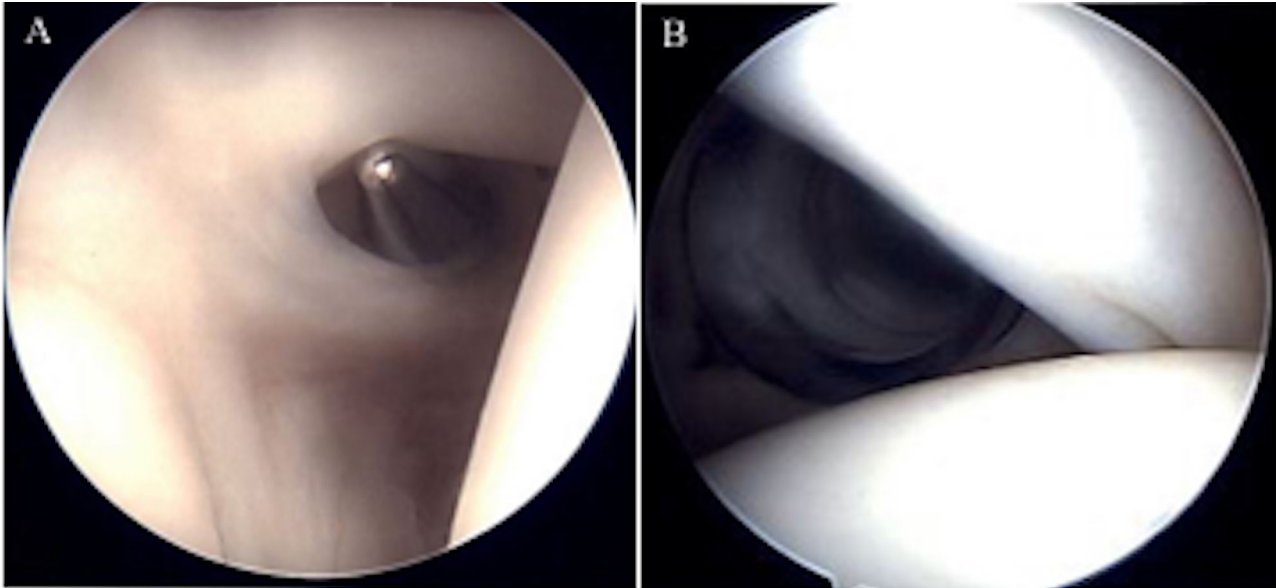


Figure 2. Intraoperative arthroscopic view of anomalous long head biceps tendon (LHBT) proximal insertions. a) confluent LHBT to interval capsule and b) Bifid insertion.

Table 1. Preoperative and postoperative follow-up data for visual analogue scale (VAS) score for pain, strength, subjective shoulder value (SSV). ROM, range of motion; VAS, visual analogue scale; SSV, subjective shoulder value; LHBT, long head biceps tendon

Patient	Age (years old)	Dominant arm	Follow-up (Month)	Preoperative measurements		3 month Postoperative measurements		Last follow up measurement		Description of the anomalous LHBT insertion
				Pain Score	SSV	Pain Score	SSV	Pain Score	SSV	
1	24	No	18	10	10%	6	90%	0	100%	Medial insertion of LHBT
2	21	Yes	5	5	40%	0	100%	0	100%	Medial insertion of LHBT
3	21	Yes	35	6	50%	0	98%	0	90%	Confluent LHBT insertion with supraspinatus
4	16	Yes	34	5	40%	0	98%	0	100%	Attachment of LHBT to interval capsule
5	16	No	16	5	60%	0	80%	0	100%	Bifid insertion of LHBT
6	16	Yes	6	7	70%	0	80%	0	95%	Attachment LHBT to interval capsule
7	15	Yes	5	8	60%	4	70%	0	95%	Confluent LHBT insertion with supraspinatus

There were significant differences between pre-and 3 months postoperative VAS score ( $P<0.001$ ). Complete pain relief was achieved in all patients following surgery. Compared to before surgery, the SSV improved significantly 3-months post-operative ( $p$ -value = 0.024) and at final follow up ( $p=0.003$ ) [Table 1]. There were no significant differences between pre-and post-operative active ROM and muscle strength. Pre-and postoperative muscle strength at forward flexion and external rotation

was 5/5 in all the patients. Preoperative forward flexion, external rotation and internal rotation were  $167.14^\circ \pm 4.87$ ,  $64.28^\circ \pm 11.33$ , and  $T10.71 \pm 1.6$  respectively and changed to  $170^\circ$ ,  $68.57^\circ \pm 3.77$ , and  $T10.57 \pm 1.5$  at final visit postoperatively.

### Discussion

The most important finding of this study is that Anomalous origins of the LHBT may be a predisposing

factor for chronic biceps tendinitis refractory to non-operative treatment in young adults. Anomalous origins of the LHBT has been described in the literature (3, 4, 7, 9, 12-15). However, the clinical relevance is unknown. Some authors believe it is a normal variant, while others believe they predispose the shoulder for other pathologies (4, 5, 9, 10, 16-18). Wittstein *et al.* reported two cases of a bifurcate LHBT (having origins from the rotator cable and scapula instead of superior labrum or supraglenoid tubercle) (16). She addressed other pathologies within the shoulder and found pain resolved, thereby concluding these LHBT variants are asymptomatic. Other authors have suggested LHBT origin anomalies lead to shoulder instability (5, 9, 10, 13, 14). The LHBT is thought to act as a humeral head depressor and dynamic stabilizer of the glenohumeral joint (19-21). Glueck *et al.* and Ghalayini *et al.* both reported cases of shoulder instability in patients with congenital absence of the LHBT (9, 10). Zhang *et al.* noted when the LHBT originated from the anterior edge of the supraspinatus tendon, it led to partial articular-sided supraspinatus lesions (8). The current study suggests that an altered course of the LHBT through the glenohumeral joint due to anomalous origins can be clinically symptomatic.

The present study identified anomalous origins of the LHBT which contributed to pain. Four different types were found. We hypothesize that an atypical origin likely causes a change in shoulder joint biomechanics and increased glenohumeral ligament strain as the humeral head moves anteriorly. In addition, an anomalous insertion may act as a tether altering its normal glide within the bicipital groove and predispose it to tenosynovitis. By addressing this problem with a subpectoral biceps tenodesis, all patients had resolution of their pre-operative symptoms suggesting that their symptoms were causatively linked to the anomalous origins of the LHBT.

Limitations of our study include its retrospective case series design. Due to the rarity of the condition, we were unfortunately unable to randomize treatment or eliminate confounders. However, this study was able to eliminate confounding effects from concurrent pathologies. As well we were unable to determine the

percentage of the asymptomatic patients with anomalous LHBT origin. More research identifying the true prevalence of anomalous origins might further elucidate the relationship between these anomalous origins and tendonitis. The small number of patients in our series is also a limitation, although our case series is the largest of its kind in the literature to our knowledge.

Anomalous origins of the LHBT may be a predisposing factor for chronic biceps tendinitis refractory to non-operative treatment in young adults. Biceps tenodesis seems to offer improvements in function and pain.

"All procedures performed in studies involving human participants were in accordance with the ethical standards of the institutional and/or national research committee and with the 1964 Helsinki declaration and its later amendments or comparable ethical standards."

**Conflicts of Interest:** Soheil Sabzevari, Mostafa Khalilipour Roudi, Jay Kalawadia, Albert Lin declare that they have no conflict of interest.

Soheil Sabzevari MD

Department of Orthopaedic Surgery, Division of Shoulder Surgery and Sports Medicine, University of Pittsburgh, UPMC Center for Sports, Pittsburgh, PA, USA  
Department of Orthopaedic Surgery, Razavi Hospital, Mashhad, Iran

Mostafa Khalilipour Roudi MD

Department of Orthopaedic Surgery, Razavi Hospital, Mashhad, Iran

Jay Kalawadia MD

Department of Orthopaedic Surgery, Advanced Orthopaedic Centers, Woodbury, NJ, USA

Albert Lin MD

Department of Orthopaedic Surgery, Division of Shoulder Surgery and Sports Medicine, University of Pittsburgh, UPMC Center for Sports, Pittsburgh, PA, USA

## References

1. Krupp RJ, Kevern MA, Gaines MD, Kotara S, Singleton SB. Long head of the biceps tendon pain: differential diagnosis and treatment. *J Orthop Sports Phys Ther.* 2009; 39(2):55-70.
2. Longo UG, Loppini M, Marineo G, Khan WS, Maffulli N, Denaro V. Tendinopathy of the tendon of the long head of the biceps. *Sports Med Arthrosc.* 2011; 19(4):321-32.
3. Gaskin CM, Golish SR, Blount KJ, Diduch DR. Anomalies of the long head of the biceps brachii tendon: clinical significance, MR arthrographic findings, and arthroscopic correlation in two patients. *Skeletal Radiol.* 2007; 36(8):785-9.
4. Richards DP, Schwartz M. Anomalous intraarticular origin of the long head of biceps brachii. *Clin J Sport Med.* 2003; 13(2):122-4.
5. Smith EL, Matzkin EG, Kim DH, Harpstrite JK, Kan DM. Congenital absence of the long head of the biceps brachii tendon as a VATER association. *Am J Orthop (Belle Mead NJ).* 2002; 31(8):452-4.
6. Hyman JL, Warren RF. Extra-articular origin of biceps brachii. *Arthroscopy.* 2001; 17(7):E29.
7. Enad JG. Bifurcate origin of the long head of the biceps tendon. *Arthroscopy.* 2004; 20(10):1081-3.

8. Zhang AL, Gates CH, Link TM, Ma CB. Abnormal origins of the long head of the biceps tendon can lead to rotator cuff pathology: a report of two cases. *Skeletal Radiol.* 2014; 43(11):1621-6.
9. Ghalayini SR, Board TN, Srinivasan MS. Anatomic variations in the long head of biceps: contribution to shoulder dysfunction. *Arthroscopy.* 2007; 23(9):1012-8.
10. Glueck DA, Mair SD, Johnson DL. Shoulder instability with absence of the long head of the biceps tendon. *Arthroscopy.* 2003; 19(7):787-9.
11. Compston A. Aids to the investigation of peripheral nerve injuries. Medical Research Council: Nerve Injuries Research Committee. His Majesty's Stationery Office: 1942; pp. 48 (iii) and 74 figures and 7 diagrams; with aids to the examination of the peripheral nervous system. By Michael O'Brien for the Guarantors of Brain. Saunders Elsevier: 2010; pp. [8] 64 and 94 Figures. *Brain.* 2010; 133(10):2838-44.
12. Foad A, Faruqi S. Case report: absence of the long head of the biceps brachii tendon. *Iowa Orthop J.* 2016; 36:88-93.
13. Franco JC, Knapp TP, Mandelbaum BR. Congenital absence of the long head of the biceps tendon. A case report. *J Bone Joint Surg Am.* 2005; 87(7):1584-6.
14. Sayeed SA, Shah JP, Collins MS, Dahm DL. Absence of the long head of the biceps tendon associated with glenoid dysplasia and posterior labral tear. *Clin Anat.* 2008; 21(7):728-32.
15. Kim KC, Rhee KJ, Shin HD. A long head of the biceps tendon confluent with the intra-articular rotator cuff: arthroscopic and MR arthrographic findings. *Arch Orthop Trauma Surg.* 2009; 129(3):311-4.
16. Wittstein J, Lassiter T Jr, Taylor D. Aberrant origin of the long head of the biceps: a case series. *J Shoulder Elbow Surg.* 2012; 21(3):356-60.
17. MacDonald PB. Congenital anomaly of the biceps tendon and anatomy within the shoulder joint. *Arthroscopy.* 1998; 14(7):741-2.
18. Lang JE, Vinson EN, Basamania CJ. Anomalous biceps tendon insertion into the rotator cable: a case report. *J Surg Orthop Adv.* 2008; 17(2):93-5.
19. Pagnani MJ, Deng XH, Warren RF, Torzilli PA, O'Brien SJ. Role of the long head of the biceps brachii in glenohumeral stability: a biomechanical study in cadavera. *J Shoulder Elbow Surg.* 1996; 5(4):255-62.
20. Warner JJ, McMahon PJ. The role of the long head of the biceps brachii in superior stability of the glenohumeral joint. *J Bone Joint Surg Am.* 1995; 77(3):366-72.
21. Itoi E, Motzkin NE, Morrey BF, An KN. Stabilizing function of the long head of the biceps in the hanging arm position. *J Shoulder Elbow Surg.* 1994; 3(3):135-42.