

RESEARCH ARTICLE

Outcomes of Arthroscopic Biceps Tenodesis for the Treatment of Failed Type II SLAP Repair: A Minimum 2-Year Follow-Up

Alexander Kreines, DO¹; Manuel Pontes, PhD¹; Elizabeth Ford, BA¹; Kristen Herbst DO¹; Jeffrey Murray DO¹; Brian Busconi, MD²; Sean McMillan, DO, FAOAO¹

Research performed at Lourdes Medical Center at Our Lady of Lourdes Burlington Campus, NJ, USA

Received: 29 May 2019

Accepted: 30 August 2019

Abstract

Background: To retrospectively review surgical outcomes of prospectively collected data on a series of patients who underwent revision of a type II SLAP repair to arthroscopic biceps tenodesis due to an unsuccessful outcome.

Methods: A retrospective review was performed on a cohort of patients who underwent arthroscopic biceps tenodesis for a failed type II SLAP repair from 2010 to 2014. Range of motion (ROM) in four planes was measured pre-and postoperatively. In addition, all patients completed the American Shoulder Elbow Surgeons (ASES) standardized shoulder assessment form, the Visual Analogue Scale (VAS) for pain, and the Short Form-12 (SF-12) scores.

Results: Overall, 26 patients met inclusion criteria. All 26 patients were available for follow-up at a minimum of two years (100% follow-up). The mean age of the patients was 37(range 26-54), 85% were male, and 58% were overhead laborers. Clinical as well as statistical improvement was noted following tenodesis across all outcome measurements ($P<0.01$). Additionally, ROM improved in all four planes ($P<0.01$). The rate of return to work was 85% with workers' compensation status leading to inferior outcomes. Two complications were noted which required an additional surgery.

Conclusion: Arthroscopic biceps tenodesis demonstrates to be an effective treatment for a failed type II SLAP repair with improved patient satisfaction, pain relief, and range of motion at two-years follow-up with a low complication rate.

Level of evidence: III

Keywords: Biceps, Biceps tenodesis, Revision SLAP repair, Shoulder, Type II SLAP tear

Introduction

Superior labrum anterior-posterior (SLAP) lesions are a common cause of shoulder pain. First described by Andrews et al, and later classified by Snyder et al, there has been increasing attention given to SLAP lesions (1-3). The diagnosis, classification, and indications for surgical intervention remain controversial, and mixed outcomes are associated with primary repair. The current literature reports clinical outcomes of good to excellent results in 63-100% of patients undergoing primary SLAP repair (4-9). However, a large percentage of certain

patients, particularly older and overhead throwing athletes, have experienced less than satisfactory results when compared to a younger, non-throwing population (10-12). Further subset analysis of overhead throwing athletes showed a return to previous level varied and lagged behind non-overhead throwing athletes (10-12). Given the significant increase in the percentage of SLAP repairs over the past decade and the increased incidence of unsatisfactory outcomes following repair, emphasis should be placed on factors predicting failure

Corresponding Author: Sean McMillan, Rowan University School of Osteopathic Medicine, Stratford, NJ, USA
Email: mcmillansean@hotmail.com



THE ONLINE VERSION OF THIS ARTICLE
ABJS.MUMS.AC.IR

and revision procedures (13).

Multiple reasons have been cited for failure following repair of SLAP tears including advanced age, occupation, workers' compensation status, patient comorbidities, and concomitant shoulder pathology (13-16). Humeral head abrasion from an inflamed biceps tendon has also been associated with SLAP repair failures (17). Postoperative complications associated with failed SLAP repair include stiffness, pain, and loss of strength (5, 9, 14, 15). Overtightening of the biceps-labrum complex from anteriorly placed anchors during repair has been a noted cause of stiffness, particularly external rotation deficits.

Surgical intervention to address residual symptoms associated with SLAP repairs has risen. Options for treating recurrent or persistent symptoms include revision SLAP repair, biceps tenotomy, and biceps tenodesis (16, 18). Primary revision of failed SLAP repairs has yielded poor results and tenotomy can lead to cosmetic deformity, loss of strength, and residual discomfort (19, 20). Biceps tenodesis may address both the patient's underlying pathology and symptoms, although few studies have been conducted to support this (6, 16, 18).

The purpose of this study was to retrospectively quantify the postoperative improvements in range of motion, pain, and functional outcome scores in patients undergoing arthroscopic biceps tenodesis for the revision of a failed type II SLAP repair. Our hypothesis was that there would be a significant decrease in pain and a significant increase in range of motion and patient reported outcome measures.

Materials and Methods

Institutional Review Board approval was obtained at our institution. We performed a retrospective cohort review of prospectively collected data on patients who underwent arthroscopic biceps tenodesis between 2010-2014 following a failed type II SLAP repair. Failure of a SLAP repair was defined as persistent shoulder pain, decreased shoulder ROM, loss of strength, or loss of function as described by the patient. Symptoms had to persist for at least one year following the index procedure. All patients underwent a course non-surgical management for a minimum of six months prior to tenodesis. Non-surgical management consisted of physical therapy, non-steroidal anti-inflammatories (NSAIDs), activity modification and intra-articular steroid injections. All patients had an MRI prior to the revision procedure to exclude any confounding pathology. Inclusion criteria for the revision tenodesis consisted of failed repair of a type II SLAP lesion which met the criteria listed above. Patients were excluded if they had the following concomitant procedures performed at the time of the index procedure: rotator cuff repair, open capsular shift, glenohumeral resurfacing procedures, or bone block procedures for anterior instability. Patients that exhibited instability or had coexisting rotator cuff pathology were also excluded from the study. Operative reports from the index and the revision procedure were reviewed to document any complications arising in either.

All arthroscopic biceps tenodeses were performed by two sports fellowship trained orthopaedic surgeons. Patients were placed in lateral decubitus position and underwent a diagnostic examination of the glenohumeral space. All suture material from anchor sites and visible debris from the index repair were removed. A luggage tag stitch was placed through the biceps tendon using a suture passer. An intra-articular release of the biceps tendon was performed using arthroscopic scissors at the base of the labral junction. A 4.0-mm shaver was used to contour the remaining biceps stump to the superior labrum. Per the discretion of the senior authors (BB, SM), partial capsular release as well as lysis of adhesions in the rotator interval were performed in all patients using a radiofrequency ablation device. Attention was then taken to the subacromial space where a subacromial bursectomy was performed on all patients. No additional procedures such as acromioplasty or acromioclavicular joint resection were performed. An anterolateral portal was then made and the bicipital groove was dissected out using electrocautery. The superior border of the pectoralis major tendon was identified as well as the biceps tendon in its groove. An 8.5-mm reamer was then used to create a unicortical socket for interference screw fixation at the base of the bicipital groove. Utilizing an 8 X 12-mm interference screw (Arthrex SwiveLock, Naples, Florida, USA), the biceps tendon was fixed into the inferior portion of the bicipital groove superior to the pectoralis tendon. Appropriate tensioning of the tendon was performed using the tag suture.

Post operatively, all patients underwent a standardized rehab protocol. A licensed physical therapist was utilized to supervise the exercises. All patients were placed in a sling for two weeks, and pendulum exercises were initiated on the first day following surgery. Passive to active range of motion exercises were initiated as tolerated four to six weeks postoperatively with emphasis on scapulothoracic and glenohumeral stabilization. Low velocity strength training was initiated at weeks seven through nine. Gradual return to work or sports was allowed at postoperative weeks 10-12 and beyond.

Primary outcomes measured were range of motion (ROM), pain relief, and subjective outcome scores. Outcome measures were assessed preoperatively (prior to revision tenodesis surgery) and at the successive post-revision follow-up visits. Range of motion was measured by an independent examiner prior to and following revision tenodesis using a goniometer. Shoulder ROM was tested in forward flexion, abduction, abduction external rotation, and abduction internal rotation. Subjective outcomes assessed were the American Shoulder and Elbow Surgeons survey (ASES), Visual Analog Score for pain (VAS), and the Short Form 12 (SF-12) (21). Improvement measures (postoperative values minus preoperative values) were constructed for each of the seven outcome measures. In addition, percentage improvements were computed for each of the four ROM outcome measures by dividing the improvement measure by the preoperative measure and multiplying by

100. (This expresses the ROM improvement in degrees as a percentage of the corresponding preoperative ROM measure). A chart review of patient demographics was conducted including age, sex, arm dominance, average time to revision, smoking status, overhead laboring, active military, and worker's compensation status.

Paired sample t-tests as well as Wilcoxon signed rank tests were performed to demonstrate significance of improvement in measures (post-surgery - pre-surgery). Due to the retrospective nature of the study, a post hoc power analysis was performed with the effect size set at 0.05. Statistical analyses were performed with JMP™ Pro 12.1.0. Outlier boxplots of improvement in outcome measures were also generated using JMP™ Pro 12.1.0.

Results

A total of 30 patients met the initial inclusion criteria. Four patients were excluded due to intraoperative findings of rotator cuff pathology. All of the remaining 26 patients were available for the minimum 2-year follow-up. Mean age of the patients was 37 years old (range 26-54), with a gender distribution of 22 males and four females. SLAP injuries involving the dominant arm occurred in 23 of the patients, while three patients had an injury to their non-dominant arm. Of the 26 patients, 20 (77%) were either limited in their ability to work or unable to work following the initial SLAP repair.

Average time between the index procedure and revision procedure was 21 months. Patient demographics were reviewed and outlined in Table 1.

Intraoperative findings during the tenodesis revealed that 38% of patients showed a complete lack of healing of the biceps anchor to the superior glenoid. Synovial proliferation and significant adhesions were noted in the rotator interval with granulomatous changes surrounding all anchor sites [Figure 1]. An average of 2 anchors were

Table 1. Patient Demographics

Patient Demographics	
Avg. Age (yrs.)	37.1
Sex M/F (n)	22/4
Dominant Arm	23/26 (88%)
Avg. Time to Revision (mos.)	20.69
Smoker	9/26 (35%)
Workers Comp.	3/26 (12%)
Overhead Laborer	15/26 (58%)
Age > 30 (yrs.) (n)	23/26 (88%)
Active Duty Military	6/26 (23%)

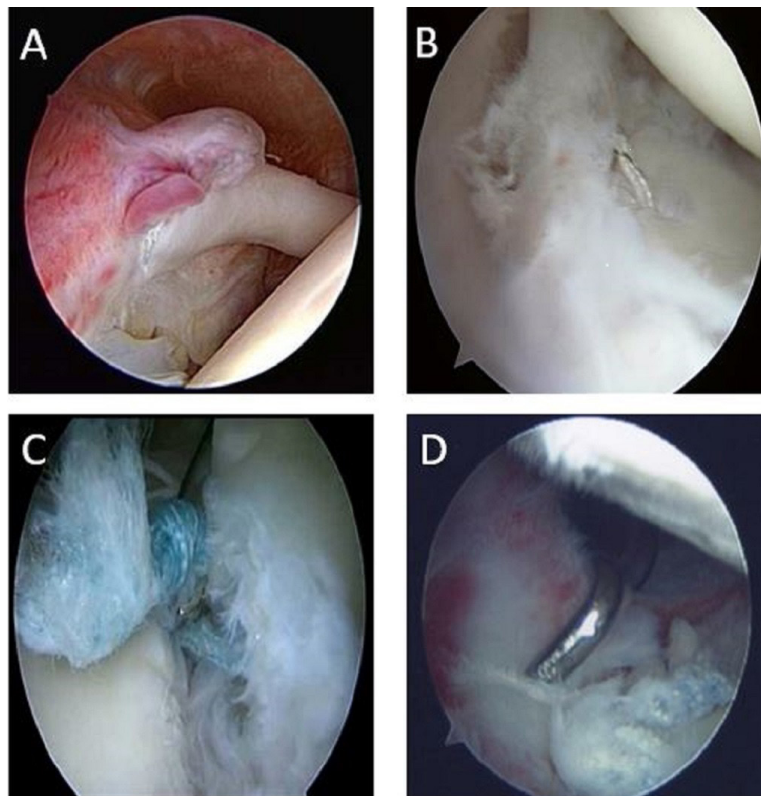


Figure 1. Demonstrates various pain generators associated with a failed Type II SLAP repair. Picture A shows inflamed synovitis encapsulating the suture. Pictures B - D demonstrate loosening of the suture repairs of the labrum with subsequent destruction of the tissue.

Table 2. Intra-Operative Findings from Previous Type II SLAP Repair

Intra-Operative Findings	
Avg. No. of Labral/ Biceps Anchors	2
Synovial Adhesions	23/26 (88%)
Knotted Anchors (n)	23/26 (88%)
Knotless Anchors	3/26 (12%)
Suture Anchors Anterior to the Biceps	(92%) 24/26
Evidence of Labral Healing	62%) 16/26

used with a majority of patients demonstrating anchors anterior to the biceps attachment. Adhesions of the biceps to the rotator cuff were present at all anchor sites with significant scarring noted to the posterosuperior and posteroinferior capsule. Existing chondral damage from loose suture material in the joint was documented [Table 2].

Clinical Outcomes

All revision patients clinically and significantly improved with regards to postoperative pain, ROM, and outcome scores [Table 3; Figure 2]. Significant negative correlation between preoperative ROM and the postoperative ROM improvement was seen in all four planes. Patients who had lower preoperative range of motion showed a significantly greater improvement

Table 3. Patient Outcome Measures

Range of Motion (degrees)		Minimum	Maximum	Mean
Flexion	Preop	110	132	120
	Postop	150	176	163
Abduction	Preop	85	115	103
	Postop	118	152	131
Internal	Preop	24	39	34
	Postop	47	63	56
External	Preop	44	59	52
	Postop	70	85	78
Self-Reported Outcome Measures				
ASES	Preop	31	47	40
	Postop	84	95	89
VAS	Preop	4	9	6.8
	Postop	1	4	2.5
SF12	Preop	38.0	51	44.2
	Postop	50.0	58	54.3

*ASES, American Shoulder and Elbow Surgeons; VAS, Visual Analogue Score (lower numbers indicate decreased pain); SF-12(Short Form-12).

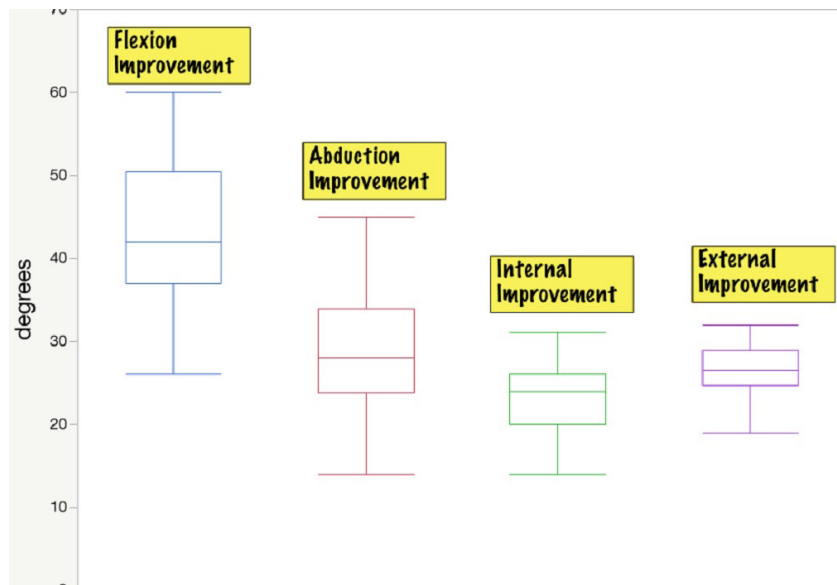


Figure 2. Demonstrates the improved range of motion in all planes of movement after the conversion to a biceps tenodesis with capsular lysis. Forward flexion demonstrated the greatest motion improvement.

Table 4. Patient Outcome Measures: Improvement and Statistical Tests				
	Improvement			r_{improve}
	Mean	t	S	
Range of Motion (degrees)				
Flexion	43°	25.55 †	175.5 †	- 0.52**
Abduction	28°	19.00 †	175.5 †	- 0.40*
Internal	23°	28.60 †	175.5 †	- 0.44*
External	26°	43.34 †	175.5 †	- 0.52**
Self-Reported Outcome Measures				
ASES	49	44.16 †	175.5 †	- 0.77**
VAS	- 4.4	- 18.10 †	- 175.5 †	- 0.75**
SF-12	10	12.80 †	174.5 †	- 0.90**

Improvement (Mean)=Mean Difference between postop and preop values, t=matched pairs t statistic, S=Wilcoxon signed rank test, r_{improve} = Correlation between a patient's preop measure and the patient's improvement measure, significance levels, *= $P<0.05$, **= $P<0.01$, †= $P<0.0001$

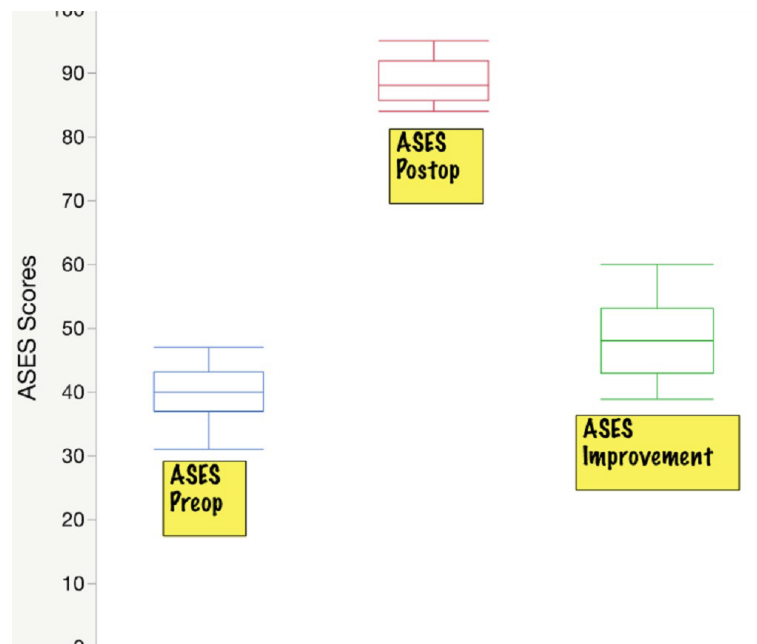


Figure 3. Demonstrates the average pre-operative and post-operative ASES scores of the 26 patients who underwent the revision to a biceps tenodesis after a failed Type II SLAP repair.

[Table 4; Figure 2]. Improvement in self-reported outcome scores also exhibited a negative correlation. Patients reporting inferior preoperative function improved significantly when compared to those with superior preoperative function [Figure 3]. Post hoc analysis of our patient cohort revealed a power of 0.78.

Overall, 16 (85%) of the patients out of work or limited in their work capabilities were able to return to work at or above their pre-SLAP injury status [Table 1].

Four patients total were unable to return to work. Average return to work was six months post revision procedure. All patients noted they would choose revision tenodesis surgery again and indicated overall increased satisfaction with their results versus the index procedure.

Two complications were seen during the two-year follow-up. Repeat surgical procedures were noted in two (7.7%) patients. The first required repair of an os

acromiale fracture that occurred after a fall seven months following tenodesis. The second patient underwent conversion to a total shoulder arthroplasty 30 months after revision for atraumatic arthritis due to chondrolysis.

Discussion

During this study, we sought to quantify the efficacy of arthroscopic biceps tenodesis for the treatment of failed type II SLAP repairs. Our proposed hypothesis about the effectiveness of this surgical procedure was confirmed as every patient (n=26) showed clinical and statistical improvement in each of the four ROM measures as well as three validated outcome measures. To our knowledge this is the second study to directly compare preoperative and postoperative ROM and the only study to show a statistical improvement in all four planes. Furthermore, we were able to show that patients with inferior preoperative ROM and outcome scores improved significantly greater postoperatively than those patients that started out with better function. Return to work was seen in a majority of patients (85%). Three out of the four patients unable to return to work were involved in workers' compensation. Two complications were noted following the revision procedure which required a repeat surgery in this cohort. Of the two repeat surgical procedures during the two-year follow-up period, none were due to a direct failure of the revision tenodesis, however glenohumeral chondrolysis may have been caused by instrumentation.

A review of the literature yields a wide range of success and failure for repairs of type II SLAP lesions (4-12). Primary repair using suture anchors has shown successful outcomes in younger patients presenting with isolated acute type II SLAP tears (7). Unsatisfactory results still occur in up to 37% of patients, with less predictable and inferior outcomes noted in older patients as well as overhead athletes (9, 11, 22). Provencher et al reported a 38% failure rate of SLAP repairs with age greater than 36 the only statistically significant predictor of failure (5). Of these failures, 28% of the patients required a revision procedure with a majority undergoing tenodesis. Katz et al looked at a specific subgroup of patients with a poor outcome after SLAP repair and noted the mean age to be 43 years (9). Other patient factors such as smoking status, arm dominance, diabetes, and mechanism of injury have been studied, but not proven to be of significance in failure rates. Our study found 23 (88%) patients were over the age of 30 with 37 being the average. Tenodesis may have led to a superior outcome as a primary treatment in the majority of our cohort.

Currently, there is no gold standard for the surgical treatment of a failed type II SLAP repair. Conservative treatment has shown poor results with a reported 81% of patients expressing dissatisfaction (9). All of our patients underwent a trial of non-operative management for six months with 0 out of the 26 patients reporting satisfaction. Surgical options are limited and include revision of SLAP repair, biceps tenotomy, and biceps tenodesis. Revision SLAP repair has shown to yield poor results. In the most significant study to date, 12 patients with an average age of 33 were found to have inferior ASES

scores as well as a low return to work rate and return to play rate (19). Tenotomy for type II SLAP lesions has shown overall clinical improvements in an older patient population (>50 years) when directly compared to repair (22). These findings reinforce the notion that in an older population, primary repair should be avoided (22, 23). Complications of biceps tenotomy such as muscle fatigue, muscle weakness, and an unpleasant cosmetic appearance may make other options such as tenodesis more appealing (24).

There are few studies looking at biceps tenodesis for the revision of a failed type II SLAP repair. McCormick et al prospectively looked at a cohort of 42 active-military patients with a mean age of 39 undergoing open subpectoral tenodesis for a failed SLAP repair (18). The authors showed a statistical increase in postoperative ASES scores as well as a statistical improvement in forward flexion and abduction. Return to active duty was noted in 81% of the patients. Gupta et al retrospectively reviewed nine patients undergoing open biceps tenodesis for a failed SLAP and reported primarily on outcome scores (6). The authors reported statistical improvement in ASES, VAS, and SF-12 scores as well as secondary outcome scores. No ROM data was reported, however. Werner et al retrospectively reviewed a cohort of 17 patients undergoing a mix of open or arthroscopic tenodesis with a mean follow-up of two years reporting on postoperative outcome scores and ROM (17). They were able to show satisfactory postoperative ASES scores and ROM, however, statistical improvements could not be demonstrated due to the lack of comparative preoperative outcome scores and ROM data.

Our findings are in accordance with the three previous studies that evaluated biceps tenodesis for the treatment of failed SLAP lesions. Our mean outcome scores were consistent as well as slightly improved over previous studies, and we were able to demonstrate a statistical increase in all four planes of motion. Unique to our study, we established a negative correlation between pre- and postoperative range of motion as well as outcome scores, suggesting that tenodesis may be more beneficial for those suffering worse outcomes following SLAP repair. This may be useful for the treating surgeon during patient selection as well as patient counseling. To our knowledge, this is the only study to demonstrate the effectiveness of an all arthroscopic biceps tenodesis.

There are several potential limitations to our study. First, this was a retrospective study with a small cohort of patients. Due to the relatively small cohort of patients, the study was underpowered as shown in our post hoc power analysis. A total of 47 patients were needed to reach 0.95 power according to our analysis. There was only one treatment arm of the study with no randomization employed. No differentiation was made between SLAP tears arising from a degenerative process versus SLAP tears arising from a traumatic process. In all revision shoulder arthroscopic procedures, the senior authors (BB, SM) employ a lysis of adhesion as well as partial capsular release depending upon the extent of intraoperative scar formation. Of the three studies to describe revision tenodesis, only one reports

on the intraoperative findings of adhesions between the biceps and rotator cuff as well as synovitis in the rotator interval (18). None of the three studies report on concomitant capsular release or extensive lysis of adhesions at the time of revision tenodesis (6, 16, 18). In our study, the extent of capsular release and lysis of adhesions was left to surgeon discretion. These additional procedures certainly could have confounding effects on our postoperative range of motion data. Finally, the revision procedures were done by two different surgeons. While the physicians performed similar procedures intraoperatively, it is possible that some variation existed from patient to patient. Future studies should employ randomization of patients to different treatment arms including revision SLAP repair, tenotomy, and tenodesis. Further analysis comparing outcomes of revision open versus arthroscopic biceps tenodesis could provide useful data regarding the optimum treatment route.

An increasing incidence of arthroscopic repair for type II SLAP lesions has led to a rise in unsatisfactory outcomes. Our study supports the current literature that arthroscopic biceps tenodesis is an effective treatment option for a failed type II SLAP repair.

The clinical improvements noted in patient outcome scores as well as ROM show favorable and consistent results when compared to previous studies. Statistical significance was reached in all categories, and every patient enrolled showed improvement supporting our hypothesis that biceps tenodesis is a reproducible and effective treatment for a failed type II SLAP repair with little complication.

Alexander Kreines DO¹

Manuel Pontes PhD¹

Elizabeth Ford BA¹

Kristen Herbst DO¹

Jeffrey Murray DO¹

Brian Busconi MD²

Sean McMillan DO FAOAO¹

1 Rowan University School of Osteopathic Medicine, Stratford, NJ, USA

2 University of Massachusetts Memorial Medical Center, Worcester, MA, USA

References

- Andrews JR, Carson WG Jr, McLeod WD. Glenoid labrum tears related to the long head of the biceps. *Am J Sports Med.* 1985; 13(5):337-41.
- Snyder SJ, Karzel RP, Del Pizzo W, Ferkel RD, Friedman MJ. SLAP lesions of the shoulder. *Arthroscopy.* 1990; 6(4):274-9.
- Snyder SJ, Banas MP, Karzel RP. An analysis of 140 injuries to the superior glenoid labrum. *J Shoulder Elbow Surg.* 1995; 4(4):243-8.
- Cohen DB, Coleman S, Drakos MC, Allen AA, O'Brien SJ, Altchek DW, et al. Outcomes of isolated type II SLAP lesions treated with arthroscopic fixation using a bioabsorbable tack. *Arthroscopy.* 2006; 22(2):136-42.
- Provencher MT, McCormick F, Dewing C, McIntire S, Solomon D. A prospective analysis of 179 type 2 superior labrum anterior and posterior repairs: outcomes and factors associated with success and failure. *Am J Sports Med.* 2013; 41(4):880-6.
- Gupta AK, Bruce B, Klosterman EL, McCormick F, Harris J, Romeo AA. Subpectoral biceps tenodesis for failed type II SLAP repair. *Orthopedics.* 2013; 36(6):e273-728.
- Kim SH, Ha KI, Kim SH, Choi HJ. Results of arthroscopic treatment of superior labral lesions. *J Bone Joint Surg Am.* 2002; 84(6):981-5.
- Stetson WB, Snyder SJ, Karzel RP, Banas MP, Rahhal SE. Long-term clinical follow-up of isolated SLAP lesions of the shoulder. *Arthroscopy.* 1996; 12(3):351-2.
- Katz LM, Hsu S, Miller SL, Richmond JC, Khetia E, Kohli N, et al. Poor outcomes after SLAP repair: descriptive analysis and prognosis. *Arthroscopy.* 2009; 25(8):849-55.
- Boileau P, Parratte S, Chuinard C, Roussanne Y, Shia D, Bicknell R. Arthroscopic treatment of isolated type II SLAP lesions: biceps tenodesis as an alternative to reinsertion. *Am J Sports Med.* 2009; 37(5):929-36.
- Sayde WM, Cohen SB, Ciccotti MG, Dodson CC. Return to play after type II superior labral anterior-posterior lesion repairs in athletes: a systematic review. *Clin Orthop Relat Res.* 2012; 470(6):1595-600.
- Neuman BJ, Boisvert CB, Reiter B, Lawson K, Ciccotti MG, Cohen SB. Results of arthroscopic repair of type II superior labral anterior posterior lesions in overhead athletes: assessment of return to preinjury playing level and satisfaction. *Am J Sports Med.* 2011; 39(9):1883-8.
- Onyekwelu I, Khatib O, Zuckerman JD, Rokito AS, Kwon YW. The rising incidence of arthroscopic superior labrum anterior and posterior (SLAP) repairs. *J Shoulder Elbow Surg.* 2012; 21(6):728-31.
- Abbot AE, Li X, Busconi BD. Arthroscopic treatment of concomitant superior labral anterior posterior (SLAP) lesions and rotator cuff tears in patients over the age of 45 years. *Am J Sports Med.* 2009; 37(7):1358-62.
- Kim SJ, Lee IS, Kim SH, Woo CM, Chun YM. Arthroscopic repair of concomitant type II SLAP lesions in large to massive rotator cuff tears: comparison with biceps

- tenotomy. *Am J Sports Med.* 2012; 40(12):2786-93.
16. Werner BC, Pehlivan HC, Hart JM, Lyons ML, Gilmore CJ, Garrett CB, et al. Biceps tenodesis is a viable option for salvage of failed SLAP repair. *J Shoulder Elbow Surg.* 2014; 23(8):e179-84.
 17. Byram IR, Dunn WR, Kuhn JE. Humeral head abrasion: an association with failed superior labrum anterior posterior repairs. *J Shoulder Elbow Surg.* 2011; 20(1):92-7.
 18. McCormick F, Nwachukwu BU, Solomon D, Dewing C, Golijanin P, Gross DJ, et al. The efficacy of biceps tenodesis in the treatment of failed superior labral anterior posterior repairs. *Am J Sports Med.* 2014; 42(4):820-5.
 19. Park S, Glousman RE. Outcomes of revision arthroscopic type II superior labral anterior posterior repairs. *Am J Sports Med.* 2011; 39(6):1290-4.
 20. Gill TJ, McIrvine E, Mair SD, Hawkins RJ. Results of biceps tenotomy for treatment of pathology of the long head of the biceps Brachii. *J Shoulder Elbow Surg.* 2001; 10(3):247-9.
 21. Michener LA, McClure PW, Sennett BJ. American shoulder and elbow surgeons standardized shoulder assessment form, patient self-report section: reliability, validity, and responsiveness. *J Shoulder Elbow Surg.* 2002; 11(6):587-94.
 22. Franceschi F, Longo UG, Ruzzini L, Rizzello G, Maffulli N, Denaro V. No advantages in repairing a type II superior labrum anterior and posterior (SLAP) lesion when associated with rotator cuff repair in patients over age 50: a randomized controlled trial. *Am J Sports Med.* 2008; 36(2):247-53.
 23. Alpert JM, Wuerz TH, O'Donnell TF, Carroll KM, Brucker NN, Gill TJ. The effect of age on the outcomes of arthroscopic repair of type II superior labral anterior and posterior lesions. *Am J Sports Med.* 2010; 38(11):2299-303.
 24. Friedman JL, FitzPatrick JL, Rylander LS, Bennett C, Vidal AF, McCarty EC. Biceps tenotomy versus tenodesis in active patients younger than 55 years: is there a difference in strength and outcomes? *Orthop J Sports Med.* 2015; 3(2):1-6.