

RESEARCH ARTICLE

Identification of Radial Nerve in Relationship to Deltoid Tuberosity and Brachioradialis

Kwan Jun Park, MD; Brandon Anthony Romero, MD; Shahryar Ahmadi, MD

Research performed at Department of Orthopaedic Surgery, University of Arkansas for Medical Sciences, Little Rock, Arkansas, USA

Received: 08 January 2019

Accepted: 21 January 2019

Abstract

Background: Several studies have identified the radial nerve in arm using different anatomic landmarks, however, a controversy remains. Deltoid tuberosity (DT) and brachioradialis (BR) are reproducible landmarks that can be used to identify the radial nerve (RN) during fracture surgery.

Methods: Dissection of RN was carried out in 17 fresh frozen adult cadavers. Using a calibrated caliper, we measured the distance between DT and the origin of BR. The distance between DT and where RN becomes lateral in its relationship with the humerus (DT-RN) and the distance between RN and BR (RN-BR) were subsequently measured. The ratio of DT-RN to DT-BR was calculated to see where the nerve lies in relationship to DT-BR.

Results: Average DT-BR was 81.8 (± 14.86) mm, average DT-RN was 48.9 (± 7.83) mm, and average RN-BR was 33.0 (± 10.16) mm. RN was always found posterior to DT and was never found in the proximal third of DT-BR. The nerve was found in the middle third of DT-BR in 14 of 17 cadavers (82.4 %) and in the distal third in 3 out of 17 cadavers (17.6%). 16 of 17 cadavers (94%) had radial nerve in the distal half of DT-BR.

Conclusion: Using the anatomic relationships between RN, DT, and the origin of BR, identification of RN is easily reproducible. These two structures can serve as the stationary landmarks during fracture surgery to find the radial nerve, which can be found in the distal 2/3 of the distance between the deltoid tuberosity and the origin of brachioradialis.

Level of evidence: V

Keywords: Arm, Brachioradialis, Deltoid tuberosity, Humerus, Radial nerve

Introduction

Identifying and protecting the radial nerve intraoperatively are critically important when performing surgeries on the arm. Frequently, the radial nerve injury in the arm is a complication of the humeral shaft fractures due to the proximity of the nerve to the osseous anatomy of the humerus (1-4). The incidence of radial nerve injury during surgical procedures of arm is estimated to be 1.9-3.3% and is as high as 11.5% after repair of non-unions (3, 5, 6).

The radial nerve is the continuation of the posterior cord of brachial plexus and enters the arm through the triangular interval with profunda brachial artery (7). It runs along the spiral groove of the posterior humerus approximately 20 cm from medial epicondyle and 14 cm from lateral epicondyle and pierces the lateral intermuscular septum, entering the anterior compartment of the arm (3, 7, 8).

The knowledge of the location and the course of the

Corresponding Author: Shahryar Ahmadi, Department of Orthopaedic Surgery, University of Arkansas for Medical Sciences, Little Rock, AR, USA
Email: SAhmadi@uams.edu



THE ONLINE VERSION OF THIS ARTICLE
ABJS.MUMS.AC.IR

radial nerve with reference to the humerus and its influence on the operative approaches are of major importance (8). Several studies have attempted to identify the course of the nerve in the arm using different anatomic landmarks, however, a controversy remains over the best way to identify the radial nerve (3, 9-13). Understanding the location would also facilitate choosing an optimal approach for radial nerve exploration in the context of radial nerve palsy (3, 8).

The deltoid tuberosity and the origin of brachioradialis are reproducible landmarks that can be used to identify the radial nerve. The senior author uses these two anatomic structures as the practical superficial landmarks to identify radial nerve during fracture surgery.

To our knowledge, this is the first study that characterized the radial nerve in relationship to the deltoid tuberosity and the origin of brachioradialis.

Materials and Methods

17 upper limbs (16 human cadavers) of fresh frozen adult forequarter specimens were obtained, and the dissection of the radial nerve was carried out in each specimen. None of these cadavers had previous surgeries or trauma to the upper extremity. Each specimen was positioned in supine position with 15 degrees of internal rotation of the arm, and the elbow was fixed at 30 degree of flexion.

We first superficially marked the deltoid tuberosity and the origin of brachioradialis, and drew a line for an incision between the two superficial landmarks [Figure 1]. We dissected down to the fascia and identified the lateral intermuscular septum (LIS). Then the dissection was further carried out to expose proximally to the deltoid tuberosity and distally to the origin of brachioradialis. We then exposed the deltoid

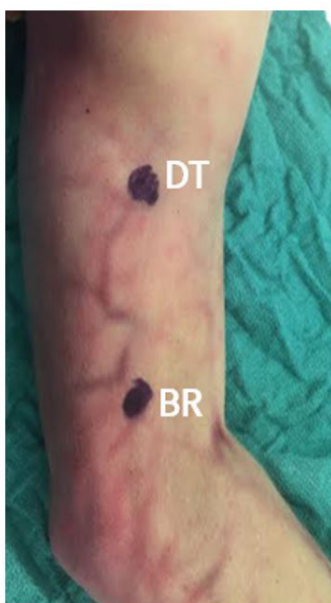

Figure 1. Deltoid Tuberosity and the Origin of Brachioradialis.

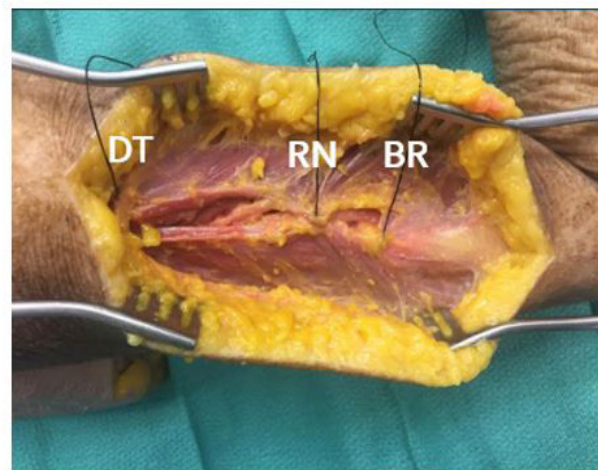
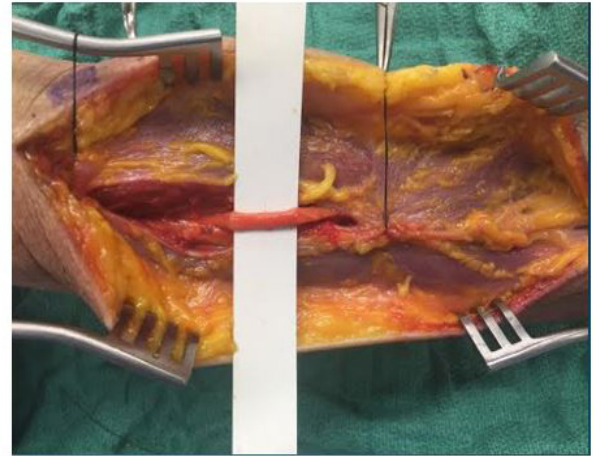


Figure 2a and 2b. Deltoid tuberosity, radial nerve, and the origin of Brachioradialis are identified on a cadaveric specimen. We identified the radial nerve as it pierces the LIS to identify the continuation of the radial nerve.

tuberosity by removing the overlying deltoid and marked it using a suture. A plane was then developed between brachioradialis and brachialis muscle to identify the origin of the brachioradialis off of LIS.

Using a calibrated caliper (Cen-tech Digital Caliper, Camarillo, CA), we measured the distance between the deltoid tuberosity and the origin of brachioradialis (DT-BR). Then we identified the radial nerve as it pierces the LIS to identify the continuation of the radial nerve and dissected proximally towards the posterior aspect of the humerus.

The distance between the deltoid tuberosity and where the radial nerve becomes lateral in its relationship with the humerus (DT-RN) and the distance between the radial nerve and the origin of brachioradialis (RN-BR) were subsequently measured [Figure 2a; 2b].

The ratio of DT-RN to DT-BR was calculated to see

where the nerve lies in relationship to DT-BR in each specimen (proximal 1/3 vs middle 1/3 vs. distal 1/3 or proximal 1/2 vs. distal 1/2 of DT-BR).

A paired, two tailed Student t-test was performed to detect any statistical difference between the right versus left upper limb (Microsoft Excel, Redmond, WA).

Results

There were 9 right upper limbs and 8 left upper limbs from 17 arms. The average age of the cadavers was 63.7 (\pm 13.29) years. The average height was 174.4 (\pm 11.11) cm, and the average weight was 68.0 (\pm 16.38) kg. The average distance from the deltoid tuberosity to the origin of brachioradialis (DT-BR) was 81.8 (\pm 14.86) mm, and the average distance from the deltoid tuberosity to the radial nerve (DT-N) was 48.9 (\pm 7.83) mm. The average distance from the radial nerve to the origin of brachioradialis (N-BR) was 33.0 (\pm 10.16) mm. The statistical analysis of the specimens revealed no statistical difference ($P = 0.78, 0.64, 0.98$, respectively, Table 1).

In all cadaver specimen, the radial nerve was always found posterior to the deltoid tuberosity. In addition, the radial nerve was not found in the proximal third of DT-BR in any of the cadavers. All but one cadavers (94%) had radial nerve in the distal half of DT-BR. The nerve was found in the middle third of DT-BR in 14 out of 17 cadavers (82.4 %) and in the distal third in 3 out of 17 cadavers (17.6%)

Table 1. Our findings in 17 cadaveric upper arm specimen

	Deltoid to BR (mm)	Deltoid to RN (mm)	RN to BR (mm)	Laterality
1	74.43	52.60	21.83	R
2	62.76	39.10	23.66	R
3	77.02	55.10	21.92	R
4	80.15	46.15	34.00	R
5	73.23	47.32	25.91	R
6	76.25	45.25	31.00	R
7	95.02	50.08	44.94	R
8	92.74	56.83	35.91	R
9	113.67	55.76	57.91	R
10	70.99	40.01	30.98	L
11	95.10	46.20	48.90	L
12	60.05	35.08	24.97	L
13	67.23	38.56	28.67	L
14	68.11	46.21	21.9	L
15	93.11	56.56	36.55	L
16	94.58	60.27	34.31	L
17	96.61	59.84	36.77	L
AVG	81.82	48.88	32.95	

Discussion

The point where the radial nerve pierces the LIS is of crucial surgical importance. It has been hypothesized that the intimate relationship of the radial nerve to the LIS may contribute to the neuropraxia resulting from distal humeral shaft fracture (the Holstein-Lewis fracture) and conceivably increase the risk of injury during surgery (1-5, 9, 11, 12). Understanding the relationship between the radial nerve and the anatomic landmarks of the arm allows the surgeon to predict the location of the radial nerve and can aid to minimize the risk of iatrogenic injury during surgical approach to the arm (9). In addition, localizing the position of the radial nerve may facilitate the minimally invasive and percutaneous surgeries in the arm as well as placement of an external fixator (12).

There have been multiple studies that described the anatomic relationship of the radial nerve in relationship to a number of bony landmarks, such as the proximal humerus (17 cm distal), deltoid tuberosity (6 cm distal) the olecranon fossa (12cm proximal), the distal humerus (15-16 cm proximal), the medial epicondyle (20 cm proximal), and the lateral condyle (14 cm proximal) (6, 8-10, 13).

In addition, several studies report the relationship of non-osseous structures to the radial nerve (12, 14). A study by Seigerman et al. reported that the radial nerve was found approximately two fingerbreadths (38.9 mm) proximal to the point of confluence between the long and lateral heads of the triceps and the triceps aponeurosis (12). Chaudry et al. reported that the nerve was found a mean 2.2 to 2.7 cm to the lateral border of the aponeurosis (14).

Fleming et al. and Cox et al. reported the relationship of the radial nerve to the lateral intermuscular septum in the arm using lateral acromion/greater tuberosity and lateral epicondyle as superficial landmarks (9, 11). They reported 95% accuracy of identifying the radial nerve between the junction of the middle and distal thirds of the distance between the lateral acromion to lateral epicondyle (9, 11). However, it is often difficult to distinguish between the acromion and the proximal humerus intraoperatively, especially in patients with greater muscle mass or subcutaneous fat, and the patient's extremity is not usually draped out to the acromion during fracture surgeries of humeral shaft and distal humerus.

Our study is the first study of its kind that documented the course of radial nerve in relationship to the deltoid tuberosity and the origin of the brachioradialis. We find using ratios to identify the radial nerve is more useful than using actual distances from landmarks, due to the variability and the discrepancies in the size and the length of the upper extremity exist in general population. We believe that this method can be used for two most common approaches to humeral shaft/distal humerus, the anterolateral approach and the posterior approach. When performing either the anterolateral or the posterior approach to humerus, the deltoid tuberosity and the origin of the brachioradialis are preserved.

Using our method, the radial nerve is always found at the distal two-thirds of DT-BR: the middle third (82%) and the distal third (18%). Radial nerve was never found at the proximal one-third junction of DT-BR. Similar to the study by Gelberman et al., we also found the deltoid tuberosity to be a reliable and practical anatomic landmark that can be used to determine the level of radial nerve along the posterior aspect of the humerus (6).

Our cadaveric study reports the unique relationship between the radial nerve, the deltoid tuberosity and the origin of brachioradialis, which are local superficial landmarks that are easily accessible during fracture surgeries of the arm. Although the studies that report the radial nerve and its absolute distance from superficial bony landmarks are useful in identifying the nerve's path and in preoperative planning, a large variation of limb lengths exist amongst the general population, and we find proportions or percentages more practical when normalizing our findings to patients of varying heights and sizes (6, 9, 11, 12). In addition, these absolute distance relationships may not be useful when addressing comminuted fractures, nonunions, malunions, and other pathologic conditions (6, 9, 11, 12).

The weaknesses of this study include the limited number of cadavers dissected and the limitations that follow a cadaveric study. However, all the dissections were carried out in fresh specimens and the number specimens are comparable to studies by Fleming et al., Gerwin et al., and Gelberman et al. (6, 8, 11). Further prospective studies in surgical settings would confirm how our findings of radial nerve would correlate

intraoperatively.

In summary, using the anatomic relationships between the radial nerve, the deltoid tuberosity and the origin of brachioradialis, the identification of the radial nerve is easily reproducible. These two superficial structures can serve as the stationary landmarks during fracture surgery to find the radial nerve which can be found in the middle 1/3 or the distal 1/3 of the distance between the deltoid tuberosity and the origin of brachioradialis, using either the posterior or anterolateral approach to the humerus.

Acknowledgements

We would like to express our appreciation to the selfless gift from donor-cadaver-patients.

Compliance with Ethical Standards: The authors of this manuscript have no conflict of interest. Informed consent was not necessary, since this was a cadaveric study.

Kwan Jun Park MD
Shahryar Ahmadi MD
Department of Orthopaedic Surgery, University of Arkansas for Medical Sciences, Little Rock, AR, USA

Brandon Anthony Romero MD
University of Nevada, Reno School of Medicine, Division of Orthopaedic Surgery, Las Vegas, NV, USA

References

1. Shah JJ, Bhatti NA. Radial nerve paralysis associated with fractures of the humerus. A review of 62 cases. *Clin Orthop Relat Res.* 1983; 172(1):171-6.
2. Sonneveld GJ, Patka P, van Mourik JC, Broere G. Treatment of fractures of the shaft of the humerus accompanied by paralysis of the radial nerve. *Injury.* 1987; 18(6):404-6.
3. Carroll EA, Schweppe M, Langfitt M, Miller AN, Halvorson JJ. Management of humeral shaft fractures. *J Am Acad Orthop Surg.* 2012; 20(7):423-33.
4. Walker M, Palumbo B, Badman B, Brooks J, Van Gelderen J, Mighell M. Humeral shaft fractures: a review. *J Shoulder Elbow Surg.* 2011; 20(5):833-44.
5. Shao YC, Harwood P, Grotz MR, Limb D, Giannoudis PV. Radial nerve palsy associated with fractures of the shaft of the humerus: a systematic review. *J Bone Joint Surg Br.* 2005; 87(12):1647-52.
6. Carlan D, Pratt J, Patterson JM, Weiland AJ, Boyer MI, Gelberman RH. The radial nerve in the brachium: an anatomic study in human cadavers. *J Hand Surg.* 2007; 32(8):1177-82.
7. Hoppenfeld S, Buckley R. *Surgical exposures in orthopaedics: the anatomic approach.* 4th ed. Philadelphia: Lippincott Williams & Wilkins; 2009.
8. Gerwin M, Hotchkiss RN, Weiland AJ. Alternative operative exposures of the posterior aspect of the humeral diaphysis with reference to the radial nerve. *J Bone Joint Surg Am.* 1996; 78(11):1690-5.
9. Cox CL, Riherd D, Tubbs RS, Bradley E, Lee DH. Predicting radial nerve location using palpable landmarks. *Clin Anat.* 2010; 23(4):420-6.
10. Bono CM, Grossman MG, Hochwald N, Tornetta P 3rd. Radial and axillary nerves. Anatomic considerations for humeral fixation. *Clin Orthop Relat Res.* 2000; 373(1):259-64.
11. Fleming P, Lenehan B, Sankar R, Folan-Curran J, Curtin W. One-third, two-thirds: relationship of the radial nerve to the lateral intermuscular septum in the arm. *Clin Anat.* 2004; 17(1):26-9.
12. Seigerman DA, Choung EW, Yoon RS, Lu M, Frank MA, Gaines LC, et al. Identification of the radial nerve during the posterior approach to the humerus: a

cadaveric study. J Orthop Trauma. 2012; 26(4):226-8.
13. Uhl RL, Larosa JM, Sibeni T, Martino LJ. Posterior approaches to the humerus: when should you worry about the radial nerve? J Orthop Trauma. 1996;

10(5):338-40.
14. Chaudhry T, Noor S, Maher B, Bridger J. The surgical anatomy of the radial nerve and the triceps aponeurosis. Clin Anat. 2010; 23(2):222-6.