

**LETTER TO THE EDITOR****Conservative Bone Cuts and Technical Hints In  
Cruciate Retaining Total Knee Arthroplasty, a 20  
Years Experience****Dear Editor**

**T**otal knee arthroplasty (TKA) is one of the most successful procedures in modern orthopedic surgery, providing high patient satisfaction rate. As a result, the number of patients undergoing TKA is increasing in number every year and more patients would be inclined to have the operation in near future. The demand for TKA is expected to grow 673% between 2005 and 2030. Knee surgeons are using more advanced techniques of arthroplasty and apply their experience to improve the outcome of the operation and achieving better results (1-3).

Understanding of the knee biomechanics, introduction of better techniques together with more modern prosthesis design and instrumentation plus good experience are reasons for success and popularity of this surgery.

In this paper we aim to share our experience of total knee arthroplasty patients with other knee surgeons. Between 2008 to 2016, 540 total knee arthroplasty were performed with the same knee prosthesis design (Nexgen Zimmer Biomet Warsaw Indiana) in our hospital, mainly by posterior cruciate retaining (CR) type prosthesis even in worst deformed knees when possible. In a few number of patients a posterior cruciate sacrifice (PC) type prosthesis was used. The CR/PS ratio was 97% to 3% (524/16). The number of F/M were 78% to 22% (424/116). R/L ratio was 48% to 52% (258/282). Most of the patients 51% (274) needed tibial insert of size 10. Together with size 12 makes it 80% (431) out of 540 patients.

The use of a CR or PS prosthesis is optional. It mainly depends on the surgeon's choice and experience. In the presence of a PCL deficient knee or damage to the PCL during the operation or in severely deformed knees in which balancing the PCL is difficult, a PS prosthesis should be used. We were able to manage most of our cases using a CR prosthesis even in advanced OA patients with severe deformity, mal-alignment and

bone loss. We believe that CR prosthesis gives the patient more natural sense and better joint movement (4-10).

By careful bone cuts of femur and tibia, it is possible to preserve more bone stock and restore the normal joint line. This in turn normalizes the knee biomechanics and patella tracking which might affect the longevity of the prosthesis and lower revision rate.

Precise ligament balancing is an important issue which must be kept in mind during TKA. Proper ligament balancing is mandatory to prevent early loosening of the components and failure. Dr Kelly Vince has the idea of "feel and touch" for ligament balancing, bone cuts and prosthetic sizing. He believes that the femur controls the knee and proper femoral bone cuts are very important. He now prefers a CR prosthesis after twenty years of using PS knee prosthesis (Personal talks).

Regarding simultaneous bilateral total knee arthroplasty (SBTKA) one should outweigh the risk and benefits of such a major operation.

We don't recommend performing SBTKA routinely in all patients. Our indication for SBTKA is an otherwise fit and healthy individual with no risk factors and average BMI in a severely deformed knees under the age of 70. Operating the knees in too long time intervals jeopardizes the operated knee in severely malaligned knees and soft tissue imbalance or overweight patients. We use a long stem tibia or femur when indicated [Figure 1]. We rarely use a CCK or hinged prosthesis in a primary TKA.

As far as the patella resurfacing is concerned, we don't resurface the patella routinely in TKA. In our experience few problems arised in patients having the patella resurfaced and less problems in non resurfaced patellas. Whether to resurface the patella or not, depends on many factors such as surgeon's preference and experience, the design of prosthesis, and the shape of patella itself. What is more important are the patella



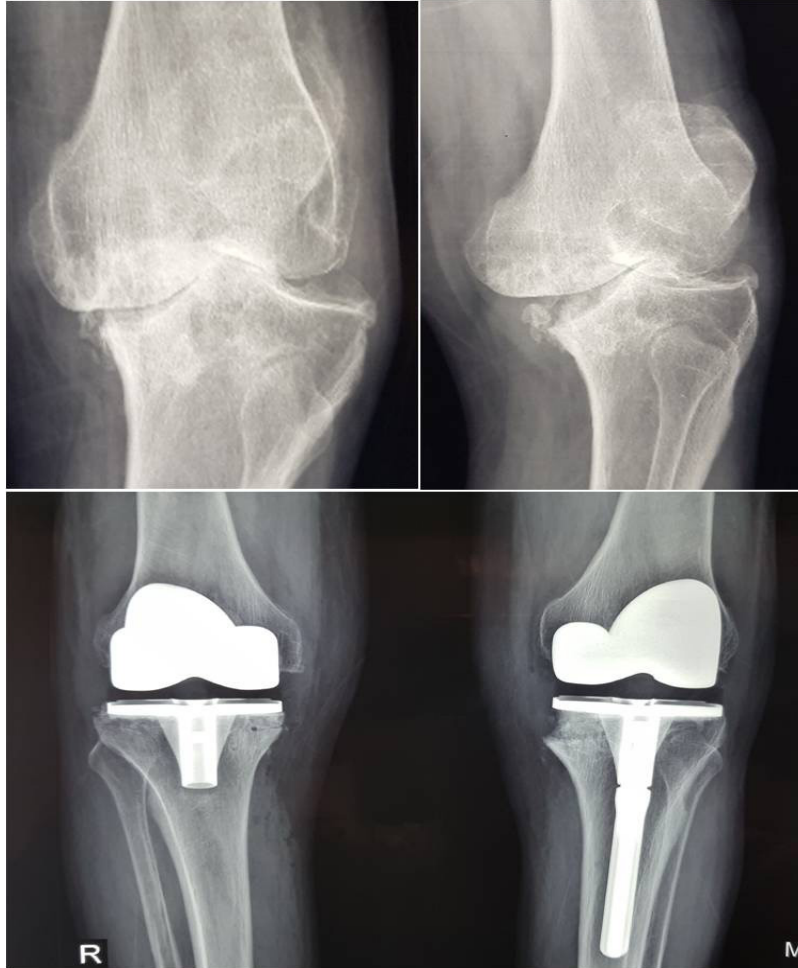


Figure 1. Bilateral total knee arthroplasty; using bone graft from distal femur cut in both side and long stem tibial component in left side.

tracking, soft tissue balance, knee alignment and component position.

We usually perform patellaplasty with shaving all osteophytes and configuring the patella to a near normal shape with good tracking. In this situation most of TKAs do well with no patella resurfacing.

After many years of experience in more than 1000 different cases of knee arthroplasty using single type knee prosthesis (Nexgen Zimmer Biomet Warsaw Indiana) we have some tricks adding to standard technique in performing bone cuts and soft tissue balancing.

#### **Technical hints and bone preparation in total knee arthroplasty**

Even an unexperienced orthopedic surgeon could realize notching of the anterior cortex of the femur while looking at the patient's knee radiograph after total knee arthroplasty. To avoid such an embarrassing problem

a knee surgeon should be careful while performing the femoral cuts. Notching of the anterior cortex might lead to a periprosthetic fracture intraoperatively or later on.

The routine order of doing the femoral cut during TKA is: distal femoral cut in 5 degrees of valgus after insertion of the intramedullary alignment rod. Then sizing of the femur using a caliper and considering of 3 degrees of external rotation of the five in one femoral cutting block. After fixation and securing the cutting block, anterior femoral cut is done first followed by posterior femoral cut and then the posterior and anterior chamfer cuts. Two problems could arise by this conventional order of cuts. First the oscillating saw blade might loosen the fixation pins of the femoral cutting block which could adversely affect other bony cuts, specially the chamfer cuts. This will end up in malpositioning of the femoral component. Second, the surgeon has a blind view of the anterior cortex while performing the anterior cut. As the anterior femur

and soft tissues in the supratrochlear area are in the way. He might end up cutting the anterior cortex of the femur unintentionally.

To avoid this, we have changed the order of the femoral cuts to not only avoid the above mentioned problems but also getting a bigger piece of bone which is the sum of anterior chamfer and part of anterior cortex [Figure 2]. This bone graft could be used to fit larger bone defects instead of using metal wedges which are more expensive and less available [Figure 3].

We start the femoral cuts with the posterior cut first then the posterior and anterior chamfer cuts then the anterior femoral cut under direct vision.

On the tibial side we also are very careful to cut the least amount of bone necessary. The aim is a 10 mm size of insert. We use a stylus, use a saver cut and look at the amount of bone to be cut on top of the tibial cutting block. If in doubt we cut from the top of the cutting block first rather than the slot in the cutting block

then through the slot. We might need to reposition the cutting block to cut less or more bone if necessary. "Furrowing" of the sclerotic areas of bone instead of drilling or more bone resection is another issue that helps better bone preservation and safer bone-cement contact [Figure 4]. Some problems might arise from cutting too much of the tibia which include: the bone stock becomes weaker and more osteoprotic, the tibial size becomes smaller which might be smaller than the smallest size of the tibial base plate available. It might create a mismatch between the size of the tibial and the femoral components. Getting too far down will reach the insertion of PCL and the fibular head.

Other important issues when preparing the tibial side is rotation of the tibia which should be exact. The slot on tibial baseplate trial should point the center of the tibial tuberosity. The baseplate should sit on the anterior cortex of the tibia after removing the osteophytes, Dr Norman Scott, (personal talk); We

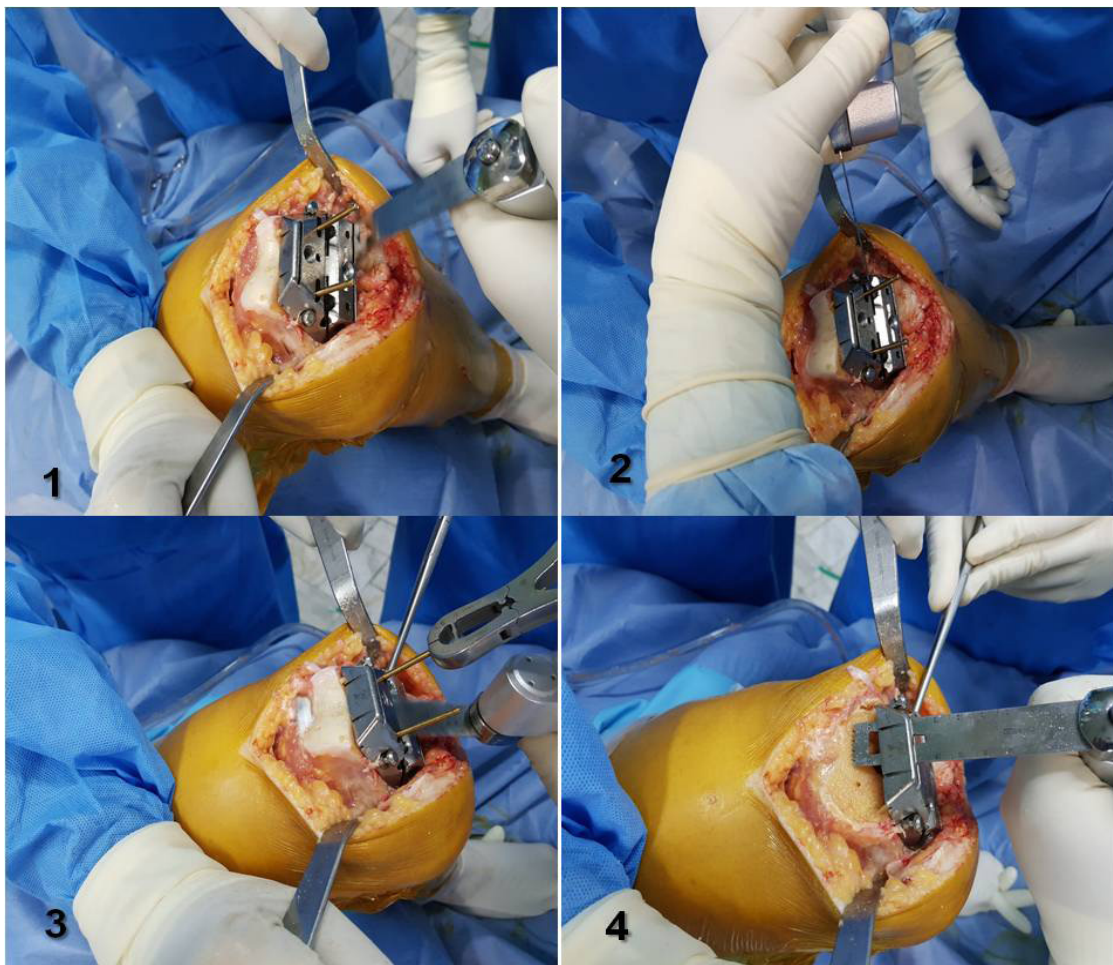


Figure 2. Change the order of distal femoral cut.

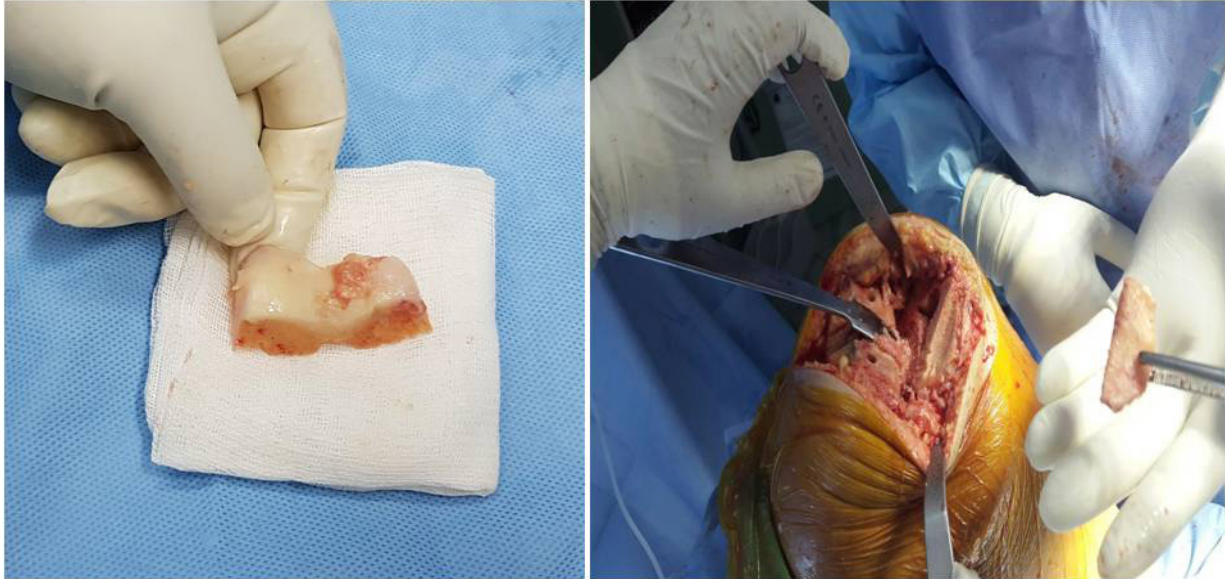

Figure 3. Achieving big piece of bone with the change the order of bone cut and use as a bone graft for tibial defect.

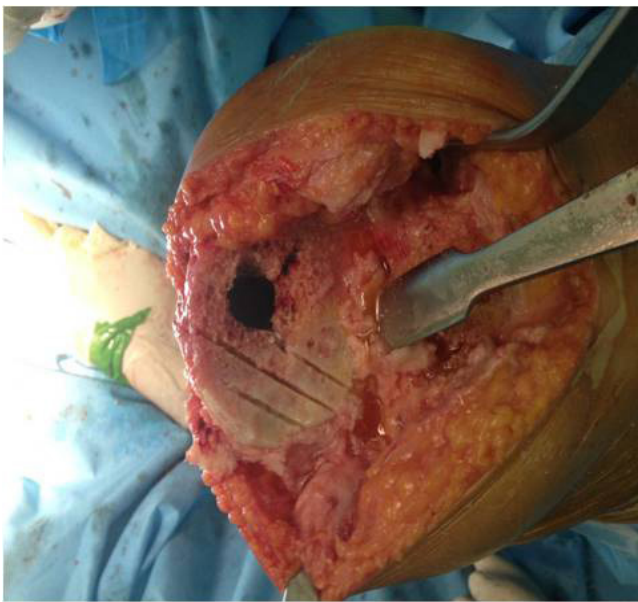

Figure 4. Furrowing of tibia for better contact of bone -cement.

have to double check the tibial cuts to avoid varus or valgus also the posterior slope should point exactly posterior rather than posteromedial or posterolateral.

The tibial base plate should sit central both medio laterally and anteroposteriorly. The butterfly shape of the tibia should look symmetrical when looking from the top. If not centrally located or malrotated should be corrected. The size of the tibial component is also important if too small might sink later on, if too big it will impinge on collateral ligaments causing pain.

In our practice maximum bone preservation and proper soft tissue balance is the aim to achieve better results patient satisfaction and less revision late.

Hadi Makhmalbaf MD  
Omid Shahpari MD  
Orthopedic Research Center, Ghaem Hospital, Mashhad  
University of Medical Science, Mashhad, Iran

---

**References**

---

1. Jorn LP, Johnsson R, Toksvig-Larsen S. Patient satisfaction, function and return to work after knee arthroplasty. *Acta Orthop Scand*. 1999; 70(4):343-7.
2. Kurtz S, Ong K, Lau E, Mowat F, Halpern M. Projections of primary and revision hip and knee arthroplasty in the United States from 2005 to 2030. *J Bone Joint Surg Am*. 2007; 89(4):780-5.
3. Chen AF, Rasouli MR, Vegari DN, Huang RC, Maltenfort MG, Parvizi J. Staged bilateral total knee arthroplasty: time of the second side. *J Knee Surg*. 2015; 28(4):311-4.
4. Sorger JI, Federle D, Kirk PG, Grood E, Cochran J, Levy M. The posterior cruciate ligament in total knee arthroplasty. *J Arthroplasty*. 1997; 12(8):869-79.
5. Pagnano MW, Cushner FD, Scott NW. Role of the posterior cruciate ligament in total knee arthroplasty. *J Am Acad Orthop Surge*. 1998; 6(3):176-87.
6. Brooks P. Seven cuts to the perfect total knee. *Orthopedics*. 2009; 32(9):42848.
7. Sharkey PF, Hozack WJ, Rothman RH, Shastri S, Jacoby SM. Insall award paper. Why are total knee arthroplasties failing today? *Clin Orthop Relat Res*. 2002; 404(1):7-13.
8. Griffin FM, Insall JN, Scuderi GR. Accuracy of soft tissue balancing in total knee arthroplasty. *J Arthroplasty*. 2000; 15(8):970-3.
9. Sikorski JM. Alignment in total knee replacement. *J Bone Joint Surg Br*. 2008; 90(9):1121-7.
10. Plaskos C, Hodgson AJ, Inkpen K, McGraw RW. Bone cutting errors in total knee arthroplasty. *J Arthroplasty*. 2002; 17(6):698-705.